

ORIGINAL ARTICLE

Clinical, electrophysiological, and imaging findings in childhood brachial plexus injury

Katherin E. Portwood¹ | Mehmet S. Albayram² | Sarah Stone¹ | Carla D. Zingariello¹ | John T. Sladky¹ | Harvey Chim³ | Peter B. Kang^{1,4,5,6} 

¹Division of Pediatric Neurology, Department of Pediatrics, University of Florida College of Medicine, Gainesville, Florida, USA

²Department of Radiology, University of Florida College of Medicine, Gainesville, Florida, USA

³Division of Plastic and Reconstructive Surgery, Department of Surgery, University of Florida College of Medicine, Gainesville, Florida, USA

⁴Paul & Sheila Wellstone Muscular Dystrophy Center, University of Minnesota Medical School, Minneapolis, Minnesota, United States

⁵Department of Neurology, University of Minnesota Medical School, Minneapolis, Minnesota, United States

⁶Institute for Translational Neuroscience, University of Minnesota Medical School, Minneapolis, Minnesota, USA

Correspondence

Peter B. Kang, Department of Neurology, University of Minnesota Medical School, 420 Delaware Street SE, MMC 295, Minneapolis, MN 55455, USA.
Email: pkang@umn.edu

Aim: To assess the prognostic capabilities of various diagnostic modalities for childhood brachial plexus injuries (BPIs) and brachial plexus birth injury (BPBI) and postneonatal BPI.

Method: In this single-center retrospective cross-sectional study, we examined children with BPIs diagnosed or confirmed by electrodiagnostic studies between 2013 and 2020, and compared the prognostic value of various components of the electrophysiologic findings, magnetic resonance imaging (MRI) data, and the Active Movement Scale (AMS). We developed scoring systems for electrodiagnostic studies and MRI findings, including various components of nerve conduction studies and electromyography (EMG) for electrodiagnostic studies.

Results: We identified 21 children (10 females and 11 males) aged 8 days to 21 years (mean 8y 6.95mo) who had a total of 30 electrodiagnostic studies, 14 brachial plexus MRI studies, and 10 surgical procedures. Among the diagnostic modalities assessed, brachial plexus MRI scores, EMG denervation scores, and mean total EMG scores were the most valuable in predicting surgical versus non-surgical outcomes. Correspondingly, a combined MRI/mean total EMG score provided prognostic value.

Interpretation: Brachial plexus MRI scores and specific electrodiagnostic scores provide the most accurate prognostic information for children with BPI. Our grading scales can assist a multidisciplinary team in quantifying results of these studies and determining prognosis in this setting.

Childhood brachial plexus injury (BPI) can be subdivided into brachial plexus birth injury (BPBI) and postneonatal BPI;^{1,2} the latter may occur in multitrauma settings³ and in the presence of infection and inflammation. Prognostication for traumatic childhood BPI has been a longstanding dilemma, particularly with regard to determining the need for surgical interventions. Minimalist approaches to prognostic determinations have

been proposed, such as evaluation of voluntary biceps movement 3 months post-injury⁴ and assessment of hand-to-mouth movement at 6 months.⁵ There has been a longstanding controversy regarding the prognostic value of electrodiagnostic studies, which include nerve conduction studies (NCS) and needle electromyography (EMG), in this context.⁶⁻⁸ Concerns regarding the prognostic value of electrodiagnostic studies arise from

This original article is commented on by Bahm on pages 1186–1187 of this issue.

Abbreviations: AMS, Active Movement Scale; BPBI, Brachial plexus birth injury; BPI, Brachial plexus injury; NCS, Nerve conduction studies; PPV, Positive predictive value; PSW, Positive sharp wave.

[†]Current affiliation: Confluence Health, Wenatchee, Washington, USA.

This is an open access article under the terms of the [Creative Commons Attribution-NonCommercial-NoDerivs](https://creativecommons.org/licenses/by-nc-nd/4.0/) License, which permits use and distribution in any medium, provided the original work is properly cited, the use is non-commercial and no modifications or adaptations are made.

© 2022 The Authors. *Developmental Medicine & Child Neurology* published by John Wiley & Sons Ltd on behalf of Mac Keith Press.

factors such as luxury innervation (polyneuronal innervation of muscle fibers) in newborn infants, needle recording areas, and distinct features of infant neuromuscular physiology.⁹ Numerous studies indicate that electrodiagnostic studies are accurate prognostic tools for BPI in childhood, but a few studies suggest otherwise.⁸ It has been proposed that a combination of clinical examination, electrodiagnostic studies, and neuroimaging would be ideal as the strengths of each assessment would compensate for the others' weaknesses.⁸ There are no studies comparing all three of these tools in the literature, and only one that directly compares electrodiagnostic studies with magnetic resonance imaging (MRI) in the context of BPI.¹⁰

To clarify these matters further, we conducted a single-center, retrospective cross-sectional study that compared various components of electrodiagnostic data, neuroimaging data, and clinical outcomes.

METHOD

Patient ascertainment

This retrospective study was conducted in accordance with an institutional review board approved protocol (IRB201901890) with a waiver of consent at University of Florida Health, a tertiary care referral center in north central Florida. The ascertainment period was 1st November 2013 to 29th April 2020; all participants were ascertained from the pediatric electrodiagnostic laboratory at that facility during this period, but data collected before 1st November 2013 was included if relevant. Inclusion criteria were individuals with a diagnosis of BPI, including BPBI and postneonatal BPI, who had one or more electrodiagnostic study during that period. The electrodiagnostic studies were performed by three of the authors (JTS, CDZ, PBK), all of whom are fellowship-trained pediatric electromyographers. We collected clinical, radiographic, and electrodiagnostic data, including NCS and EMG results. For uniformity and ease of generating aggregate scores, all scoring systems described below were designed so that higher numbers denoted milder findings and lower numbers denoted more severe findings. As there is no universally accepted approach to prognostication, the clinical determination of the need for surgery in the participants was used as the final outcome, to distinguish severe from mild cases. We recognize that the array of considerations that contribute to surgical decisions in participants with complex BPI introduces potential confounding variables for the use of surgical decisions as the outcome; however, this approach enables us to include a broader range of participants in our study, including those without intraoperative data.

Active Movement Scale and clinical outcomes

The Active Movement Scale (AMS) is an eight-point ordinal scale developed to quantify upper extremity strength in the setting of BPI that includes observations of spontaneous

What this paper adds

- A new scoring system to quantify results of electrodiagnostic and magnetic resonance imaging (MRI) studies is presented.
- Severity of denervation has good prognostic value for childhood brachial plexus injuries (BPIs).
- Composite electromyography scores have good prognostic value for childhood BPIs.
- Brachial plexus MRI has good prognostic value for childhood BPIs.

and active movement without and against gravity.^{11,12} A score of 4 or lower indicates movement only with gravity eliminated, indicating a poorer prognosis. A score of 5 or higher indicates active movement against gravity and a better prognosis. We collected AMS data retrospectively. Longitudinal average AMS scores were plotted for each participant for upper (C5–C6), middle (C7), and lower (C8–T1) trunk distributions. Average AMS scores were plotted separately for the two surgical participants with longitudinal data (1 and 19). Clinical outcomes, particularly surgical procedures related to the BPIs, were also derived from the medical record. A peripheral nerve surgeon with longstanding expertise in treating BPIs (HC) reviewed AMS and other clinical outcome data for all participants.

MRI scoring

The MRI studies were performed from 2005 to 2019. A neuroradiologist (MSA) reviewed and scored all available MRI of the brachial plexus in the cohort. The imaging findings were scored as follows for the C5 through C8 root levels: 5 = normal; 4 = mildly increased T2 signal, with or without thickening; 3 = increased T2 signal with thickening; 2 = thinning and atrophy; 1 = pseudomeningocele; 0 = avulsion. MRI severity scores were assigned and plotted, with stratification based on distribution among nerve roots C5, C6, C7, C8 over time. The T1 nerve roots were small and difficult to evaluate consistently in the brachial plexus studies used in the current study, especially in infants, thus the T1 level was not scored for MRI. To minimize potential bias, the neuroradiologist was blinded to clinical details of the participants, including which ones ultimately underwent surgery. A mean MRI score for each participant was calculated by averaging the scores of the four root levels.

NCS

NCS data were collected for all 21 participants with a total of 30 studies completed. Antidromic median and ulnar nerve sensory response amplitudes (recording digits II and V

respectively) and median and ulnar motor amplitudes were collected, plotted, and interpreted using published reference ranges for the pediatric population.¹³ As higher amplitudes generally indicate more robust axonal physiology, raw amplitudes were analyzed rather than converting them to scores.

EMG: fibrillation potentials and positive sharp waves

Fibrillation potentials and positive sharp waves (PSWs) on needle EMG examination both indicate denervation, thus were considered together to determine severity of denervation. We created the following denervation score to convert the standard clinical scoring system into one where a higher score indicates better results: 2 = no fibrillation potentials or PSWs; 1 = 1+ or 2+ fibrillation potentials and/or PSWs; and 0 = 3+ or 4+ fibrillation potentials and/or PSWs. The scores were calculated for individual muscles, grouped by innervating nerve roots,¹⁴ and plotted. The scores for fibrillation potentials and PSWs were then averaged to create a single denervation score ranging from 0 to 2 for each nerve root level.

EMG: amplitude and duration

Increased amplitude and duration of motor unit potentials are recognized to indicate the presence of reinnervation of injured nerves. Amplitude and duration were scored separately, where 1 = normal and 0 = increased amplitude or duration. The scores were summed to calculate a single amplitude/duration score ranging from 0 to 2. EMG: recruitment and activation patterns.

Recruitment and activation patterns provide valuable information regarding the degree of reinnervation and axonal continuity. We created the following scoring system: 2 = normal recruitment and activation patterns; 1 = reduced recruitment, including discrete and single units; and 0 = no activated motor units. The scores were calculated and plotted as described above, with the additional stratification of surgical versus non-surgical participants.

Total EMG scores

Aggregate motor unit EMG scores (total EMG scores) were calculated by summing the individual amplitude (0–1), duration (0–1), and recruitment/activation pattern (0–2) scores, then adding them to the average denervation (0–2) score, yielding a total EMG score ranging from 0 to 6 for each nerve root tested per study.

Mean total EMG scores

The mean total EMG score for each participant was calculated as the mean of the total EMG scores at each nerve root.

The range of mean total EMG scores was 0 to 6 also, but each score was assigned to a single participant rather than to an individual nerve root for a given participant.

Statistical analysis

Descriptive statistics were calculated, and graphs were generated using GraphPad Prism 9.0.0 (GraphPad Software, San Diego, CA, USA). Positive predictive values (PPVs) and sensitivities were calculated using the need for surgery as the positive outcome, no surgery as the negative outcome, and a score below a specific threshold serving as a positive test result. A PPV of 100% for either BPBI or postneonatal BPI was considered prognostically accurate for the diagnostic measure in question. In cases of missing electrodiagnostic data for specific root levels, denominators were adjusted to reflect the number of data points available and to ensure the accuracy of mean value calculations; among alternative strategies for handling missing data, imputation would have introduced a potential source of bias and omission would have significantly reduced the statistical power of the study.

RESULTS

Participant cohort

We identified 21 participants aged 8 days to 21 years 5 months (mean 8y 6.95mo, median 7y 4mo, standard deviation 7y 8.47mo), of whom 10 were female and 11 were male; 13 participants had BPBI while eight had postneonatal BPI (Table 1). These participants had a total of 30 electrodiagnostic studies, 14 brachial plexus MRI studies, and 10 surgical interventions, with two of those having pre- and postprocedure AMS data (no participant underwent surgery more than once during the study period) (Figure S1). The 10 individuals who underwent surgeries had participant identification numbers 1, 5, 7, 8, 11, 12, 13, 18, 19, and 20. These procedures included muscle transfer, tendon transfer, nerve transfer, and nerve grafting; neurolysis was not performed on any participants. Three participants received botulinum neurotoxin A injections, but these did not accompany any electrodiagnostic studies and were not counted as surgical procedures.

AMS in non-surgical participants

Non-surgical participants showed a broad range of initial AMS for the upper (Figure S2a), middle (Figure S2b), and lower (Figure S2c) trunks. Overall, seven of nine non-surgical participants with upper trunk AMS data demonstrated improvement at 24 months. For the middle trunk, AMS improvement did not occur for any

TABLE 1 List of participants with onset category, sex, surgical category, and initial Narakas classification

Participant	Onset classification	Sex	Surgical status	Narakas classification
1	Postneonatal	M	Surgical	2
2	Postneonatal	M	Non-surgical	x
3	BPBI	M	Non-surgical	2
4	BPBI	F	Non-surgical	0
5	BPBI	F	Surgical	x
6	Postneonatal	M	Non-surgical	x
7	BPBI	F	Surgical	3
8	BPBI	F	Surgical	1
9	BPBI	F	Non-surgical	0
10	BPBI	M	Non-surgical	0
11	BPBI	M	Surgical	0
12	Postneonatal	M	Surgical	4
13	BPBI	F	Surgical	1
14	Postneonatal	M	Non-surgical	0
15	BPBI	F	Non-surgical	0
16	BPBI	M	Non-surgical	4
17	Postneonatal	M	Non-surgical	0
18	Postneonatal	F	Surgical	2
19	BPBI	F	Surgical	2
20	Postneonatal	M	Surgical	4
21	BPBI	F	Non-surgical	2

Narakas classification: (1) C5, C6 involvement with biceps and deltoid weakness; (2) C5, C6, C7 involvement, with preservation of the long finger flexors; (3) pan-plexus involvement with slight finger flexion only; (4) pan-plexus involvement with or without Horner syndrome. Note that 0 denotes insufficient weakness to meet any of the Narakas classification criteria, and that x denotes insufficient data in the medical record to assign a Narakas classification level. Abbreviations: BPBI, brachial plexus birth injury; F, female; M, male.

participants until 7 months post-injury and three of seven participants demonstrated AMS improvement by 19 months. As many participants had BPBI with classic Erb palsy patterns, improvements were seen primarily in the upper and middle trunks (Figure S2a and S2b), and to a lesser extent in the lower trunk (Figure S2c). Our AMS data for elbow flexion alone demonstrated scores of 5 or higher by 6 months post-injury in five out of 14 non-surgical participants, indicating improved mobility against gravity at that timepoint (Figure S2d). More global upper trunk AMS data demonstrated scores of 5 or higher by 6 months post-injury in six of nine non-surgical participants (Figure S2a).

AMS in participants undergoing surgery

Of the 10 participants requiring surgical interventions, two had longitudinal pre- and postprocedure AMS data (Figure S2e). Participant 1 had nerve surgery on the brachial plexus, displaying AMS improvement around months 2 to 4 after injury. The second surgical participant, 19, had tendon repair without nerve surgery. Participant 19's post-surgical AMS averages worsened over time, perhaps due to muscle displacement that is a component of tendon repair procedures.

MRI assessment of surgical participants

For BPBI, MRI scores lower than 2 were present at C7 and C8 for both surgical participants, yielding a 100% PPV and 100% sensitivity for surgery at that threshold (Figure 1a). Similarly, for postneonatal participants, MRI scores of 2 or lower were present at C7 for all three surgical participants, yielding a 100% PPV for surgery at that threshold (Figure 1b). Mean MRI scores of 2 or lower had a lower PPV of 67% for surgery in BPBI (Figure 1c), but mean MRI scores lower than 3 had a 100% PPV and 100% sensitivity for surgery in postneonatal BPI (Figure 1d). Examples from representative MRIs are shown (Figures S3–S6). Thus, analysis of MRI scores by root levels provide more detailed information and appear to be slightly more precise than mean MRI scores in predicting surgical decisions.

NCS

Sensory nerve action potentials in the median and ulnar distributions were abnormal in many participants, but with no pattern emerging to help with prognosis (Figure S7a and Figure S7b). Sensory nerve action potential patterns did not help detect nerve root avulsion injuries in participants 1, 5, 15, and 20, perhaps because of the concurrent BPIs. Median and ulnar compound motor action potentials were mostly

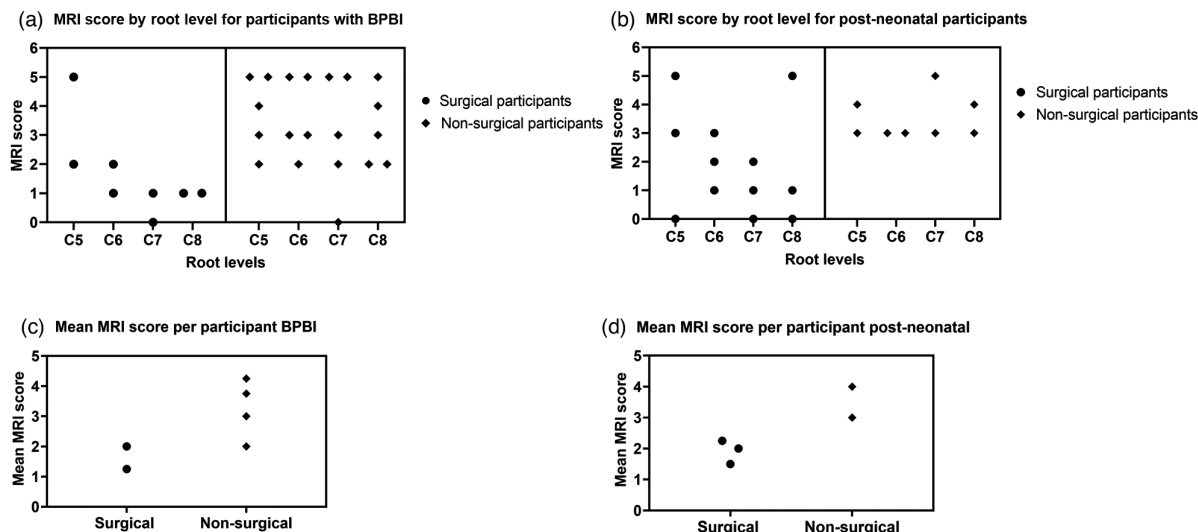


FIGURE 1 Analysis of brachial plexus magnetic resonance imaging (MRI) studies. MRI scores were assigned by individual root levels and plotted for (a) seven participants with brachial plexus birth injury (BPBI) and (b) five participants with postneonatal brachial plexus injury (BPI). Data for participants who required surgery are shown on the left side and data for those who did not are shown on the right side. Mean MRI scores were then calculated for each participant by summing the scores and then dividing by the number of root levels scored. These mean MRI scores were plotted for (c) participants with BPBI and (d) participants with postneonatal BPI, also with surgical participants on the left and non-surgical participants on the right. The scores ranged from 0 (avulsion) to 5 (normal)

normal⁶ (Figure S7c). Neither sensory nor motor amplitudes were prognostic of the need for surgery.

EMG: motor unit amplitude and duration scores

Signs of reinnervation indicate healing, thus should be used with caution to determine initial severity of BPI and prognosis. Accordingly, we found that amplitude and duration scores by themselves had limited capacity to detect the need for surgery (Figures S8 and S9).

EMG: activation and recruitment patterns

Activation and recruitment patterns did not clearly distinguish between surgical and non-surgical outcomes (Figure S10).

Aggregate motor unit EMG scores versus MRI severity scores by trunk

Aggregate motor unit EMG scores had limited capacity to distinguish surgical versus non-surgical participants, primarily at the C5-C7 root levels (Figure S11).

EMG: denervation scores as indicated by fibrillation potentials and PSW

Average denervation scores of 1 or less for any nerve root had a PPV of 100% for participants with BPBI (Figure S12a), and a PPV of 100% for postneonatal cases (Figure S12b).

EMG: total EMG scores (amplitude + duration + activation/recruitment + average denervation scores) and mean total EMG scores

The total EMG score for individual root levels in participants with BPBI showed only partial predictive value and limited sensitivity for surgical interventions (Figure 2a). On the other hand, a total EMG score of 2 or less at C8 in postneonatal BPI showed 100% PPV (Figure 2b). A mean total EMG score of 3 or less had 86% PPV and 75% sensitivity for decisions to pursue surgery in participants with BPBI (Figure 2c), while a mean total EMG score of 3 or less had a 100% PPV and 67% sensitivity for decisions to pursue surgery in participants with postneonatal BPI (Figure 2d).

Mean total EMG scores + mean MRI scores

Summing the EMG and MRI scores for individual participants yielded a composite score for each individual that had 100% PPV when the score was 3 or less for both BPBI (Figure 3a) and postneonatal BPI (Figure 3b), suggesting that there may be prognostic value in analyzing the severity of involvement on both studies together.

DISCUSSION

Our study provides further analysis of the prognostic value of several standard assessments in the setting of childhood BPI, with new scoring systems to help quantify the severity of the findings and a detailed analysis of the relative value of different components of the electrodiagnostic examination.

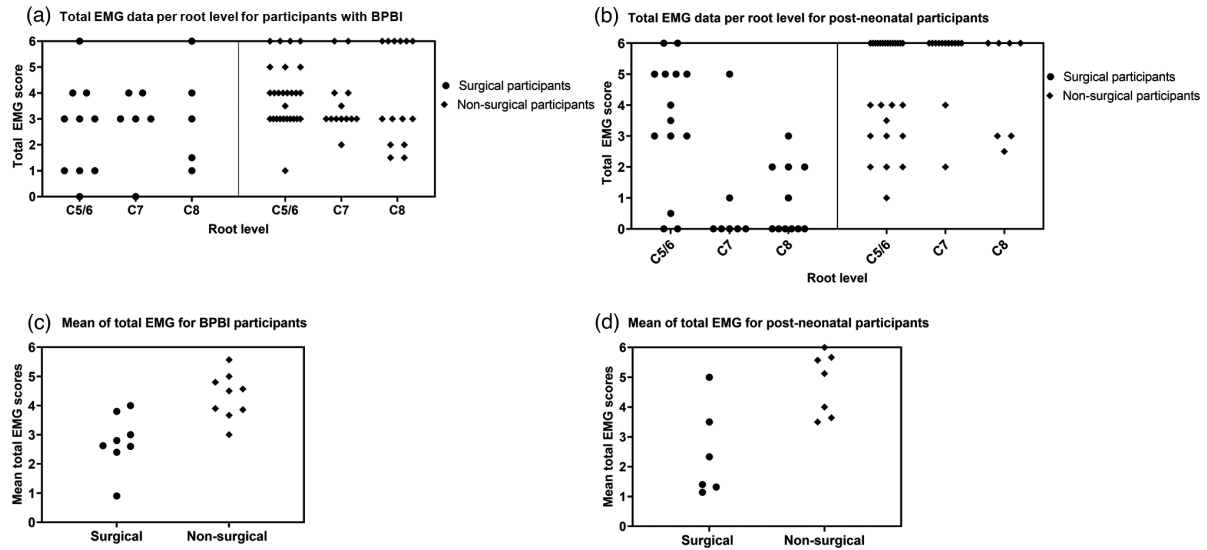


FIGURE 2 Analysis of total electromyography (EMG) scores, calculated as the sum of the amplitude, duration, activation/recruitment pattern, and average denervation scores, with a range of 0 (severe) to 6 (normal). Total EMG scores were assigned by root levels for (a) brachial plexus birth injury (BPBI) and (b) postneonatal brachial plexus injury (BPI) studies. Surgical participants are shown on the left side and non-surgical participants on the right side. Mean total EMG scores were calculated by summing the total EMG scores for individual root levels for each participant and then dividing by the number of root levels assessed. Mean total EMG scores are shown for (c) BPBI and (d) postneonatal BPI studies, also with surgical participants on the left and non-surgical participants on the right

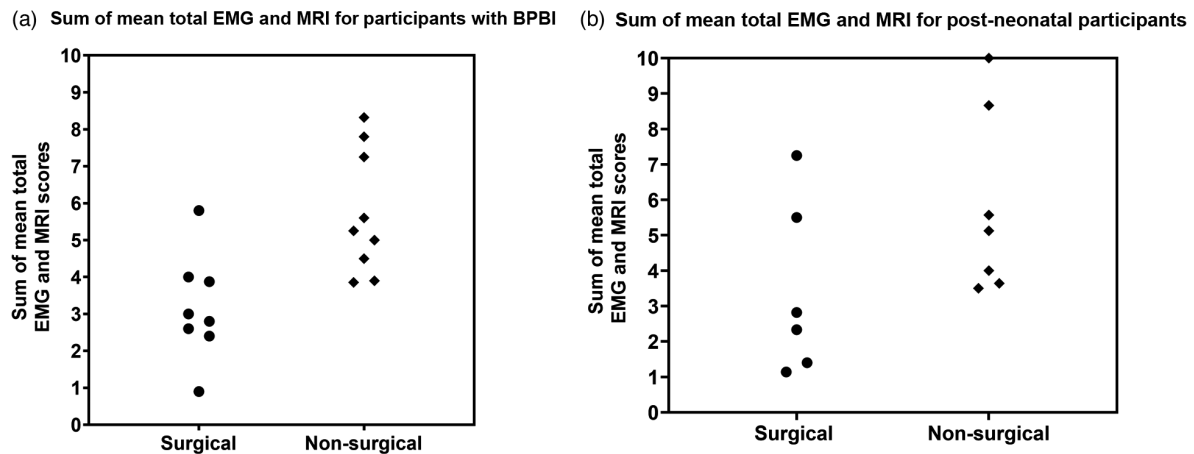


FIGURE 3 Sum of the mean total electromyography (EMG) score and mean magnetic resonance imaging (MRI) score for (a) participants with brachial plexus birth injury (BPBI) and (b) participants with postneonatal brachial plexus injury (BPI), with a total possible score of 11 (a maximum of 6 from the EMG score and a maximum of 5 from the MRI score). Surgical participants are shown on the left side and the non-surgical participants on the right side of each graph

Among clinical scoring systems, the AMS is popular in North America, whereas assessments of active range of motion and the Mallet score are more popular in other regions of the world.¹⁵ Our study suggests that AMS helps assess longitudinal progress but is less useful for prognosis. The presence or absence of voluntary elbow flexion on physical examination has been promoted in the surgical literature as a simple means of determining the need for surgery.^{4,16,17} However, one study found that assessments of shoulder strength asymmetries are important in this regard,¹⁸ while others suggest that both elbow and shoulder movements are more reasonable for overall prognosis¹⁹ and surgical decision-making.²⁰ Various applications of the AMS have been proposed for BPBI prognosis in

particular.²¹ Our findings do not support using elbow flexion AMS alone to determine the need for surgery, indicating instead that more comprehensive use of assessment scales tend to be more accurate. The presence of Horner syndrome predicted the need for surgery in one study.²¹

Our analysis suggests that early MRI may be valuable for prognosis and for guiding surgical decisions, in agreement with a prior study.²² Our numerical scale for degree of BPI severity on MRI studies may be adopted by multidisciplinary teams who are treating these children to help make objective decisions regarding surgical interventions.

Among electrodiagnostic components, denervation on needle EMG was the most accurate individual measure in

the current study for determining the need for surgical intervention, while the mean total EMG score also provided valuable prognostic information. Because of the complexity of interpreting the component and aggregate findings of electrodiagnostic studies, their utility in the setting of BPI continues to be controversial, with skeptics²³ and proponents.²⁴ In some literature, it has been suggested that electrodiagnostic studies are overly optimistic regarding the prognosis for BPBI,^{7,25,26} but not for BPI in older children.²⁷ We did not see consistent signs of excessive optimism on our analyses, perhaps because of the analysis of different components of the data obtained from electrodiagnostic studies.

There is some disagreement among peripheral nerve surgeons regarding the optimal approach to the management of children with BPI.²⁸ Surgical decisions should be considered with a full consideration of potential risks and benefits, in light of complications that are known to occur with such interventions.²⁹ Most would agree that there are potential benefits to early evaluation (3–6wks of age/post-injury) by a multidisciplinary team that ideally includes a pediatric neuromuscular neurologist, rehabilitation physician, occupational therapist, and a peripheral nerve surgeon.⁶ Another study that compared electrodiagnostic studies versus MRI found that electrodiagnostic studies were somewhat superior to MRI in detecting preganglionic lesions; that study was conducted exclusively in a surgical cohort with findings at surgery used as the criterion standard for diagnosis.¹⁰

Strengths of the current study include the development of scoring systems for diagnostic studies that are traditionally interpreted more qualitatively and the separate analyses of specific subsections of the electrodiagnostic examination. Limitations include the small sample size for the postneonatal BPI group which may limit the generalizability of our PPV calculations, the retrospective derivation of AMS scores which limited the number of these scores available for analysis, and the assumption that surgical decisions (including those involving tendon procedures) always reflect the severity of the case. The lack of sensory nerve action potential and compound motor action potential data for nerves representing higher root levels (C5–C7) precludes definitive conclusions regarding the introduction of potential bias in comparing the utility of NCS versus EMG in prognostication for pediatric BPI, and precludes definitive conclusions regarding the relative merits of these two components of electrodiagnostic studies. The number of studies was more robust for electrodiagnostic studies compared to the other measurements as numerous participants had more than one electrodiagnostic study.

We conclude that AMS scores have utility for tracking the clinical course longitudinally, whereas MRI scores, denervation scores on needle EMG, and mean of total EMG scores are the most useful measures to determine prognosis and the need for surgical intervention. The overall 11-point score that incorporates both MRI and electrodiagnostic results also provided helpful prognostic information. Until

additional data become available to refine findings from our study and other studies, both electrodiagnostic studies and MRI should be used in the early assessment of these children whenever possible, and assessed together using the proposed 11-point scoring system to yield more accurate prognostic information.

ACKNOWLEDGMENTS

The authors thank Raghav Kalra for generating the graphical abstract for this manuscript. No external funding was used to support this study. The authors have stated that they had no interests which might be perceived as posing a conflict or bias.

DATA AVAILABILITY STATEMENT

Data not provided in the article due to space limitations may be shared (de-identified) at the request of any qualified investigator for the purposes of replicating procedures and results.

ORCID

Peter B. Kang  <https://orcid.org/0000-0002-4270-7325>

REFERENCES

- Chim H, Kircher MF, Spinner RJ, Bishop AT, Shin AY. Free functioning gracilis transfer for traumatic brachial plexus injuries in children. *J Hand Surg Am* 2014;39(10):1959–66.
- Blaauw G, Muhlig RS, Vredevelde JW. Management of brachial plexus injuries. *Adv Tech Stand Neurosurg* 2008;33:201–31.
- Dorsi MJ, Hsu W, Belzberg AJ. Epidemiology of brachial plexus injury in the pediatric multitrauma population in the United States. *J Neurosurg Pediatr* 2010;5(6):573–7.
- Gilbert A, Brockman R, Carlouz H. Surgical treatment of brachial plexus birth palsy. *Clin Orthop Relat Res* 1991;(264):39–47.
- Wilson TJ, Chang KWC, Yang LJS. Prediction Algorithm for Surgical Intervention in Neonatal Brachial Plexus Palsy. *Neurosurgery* 2018;82(3):335–42.
- Slooff AC. Obstetric brachial plexus lesions and their neurosurgical treatment. *Clin Neurol Neurosurg* 1993;95 Suppl:S73–77.
- van Dijk JG, Malessy MJ, Stegeman DF. Why is the electromyogram in obstetric brachial plexus lesions overly optimistic? *Muscle Nerve* 1998;21(2):260–1.
- van der Looven R, Le Roy L, Tanghe E, van den Broeck C, de Muynck M, Vingerhoets G, et al. Early electrodiagnosis in the management of neonatal brachial plexus palsy: A systematic review. *Muscle Nerve* 2020;61(5):557–66.
- Hesselmans LFGM, Jennekens FGI, Van Den Oord CJM, Veldman H, Vincent A. Development of innervation of skeletal muscle fibers in man: Relation to acetylcholine receptors. *Anat Rec* 1993;236(3):553–62.
- Smith BW, Chang KWC, Yang LJS, Spires MC. Comparative accuracies of electrodiagnostic and imaging studies in neonatal brachial plexus palsy. *J Neurosurg Pediatr* 2018;23(1):119–24.
- Clarke HM, Curtis CG. An approach to obstetrical brachial plexus injuries. *Hand Clin* 1995;11(4):563–80; discussion 580–581.
- Michelow BJ, Clarke HM, Curtis CG, Zuker RM, Seifu Y, Andrews DF. The natural history of obstetrical brachial plexus palsy. *Plast Reconstr Surg* 1994;93(4):675–80; discussion 681.
- Ryan CS, Conlee EM, Sharma R, Sorenson EJ, Boon AJ, Laughlin RS. Nerve conduction normal values for electrodiagnosis in pediatric patients. *Muscle Nerve* 2019;60(2):155–60.
- Antonovich D, Dua A. Electrodiagnostic Evaluation Of Brachial Plexopathies [Internet]. In: StatPearls. Treasure Island (FL): StatPearls

- Publishing; 2021 [cited 2021 May 25]. Available from: <http://www.ncbi.nlm.nih.gov/books/NBK562197/>
15. Pondaag W, Malessy MJA. Outcome assessment for Brachial Plexus birth injury. Results from the iPluto world-wide consensus survey. *J Orthop Res* 2018;36(9):2533–41.
 16. Pondaag W, Malessy MJA. Evidence that nerve surgery improves functional outcome for obstetric brachial plexus injury. *J Hand Surg Eur Vol* 2021;46(3):229–36.
 17. Gilbert A, Pivato G. Obstetrical Palsy: The French Contribution. *Seminars in Plastic Surgery* 2005;19(01):5–16.
 18. Brochard S, Alter K, Damiano D. Shoulder strength profiles in children with and without brachial PLEXUS PALSY. *Muscle Nerve* 2014;50(1):60–6.
 19. Lagerkvist A-L, Johansson U, Johansson A, Bager B, Uvebrant P. Obstetric brachial plexus palsy: a prospective, population-based study of incidence, recovery, and residual impairment at 18 months of age. *Dev Med Child Neurol* 2010;52(6):529–34.
 20. Kawabata H, Masada K, Tsuyuguchi Y, Kawai H, Ono K, Tada R. Early microsurgical reconstruction in birth palsy. *Clin Orthop Relat Res* 1987;(215):233–42.
 21. Shah AS, Kalish LA, Bae DS, Peljovich AE, Cornwall R, Bauer AS, et al. Early Predictors of Microsurgical Reconstruction in Brachial Plexus Birth Palsy. *Iowa Orthop J* 2019;39(1):37–43.
 22. Abbott R, Abbott M, Alzate J, Lefton D. Magnetic resonance imaging of obstetrical brachial plexus injuries. *Childs Nerv Syst* 2004;20(10):720–5.
 23. Abid A. Brachial plexus birth palsy: Management during the first year of life. *Orthop Traumatol Surg Res* 2016;102(1 Suppl):S125–132.
 24. Pitt M, Vredeveld J-W. The role of electromyography in the management of the brachial plexus palsy of the newborn. *Clin Neurophysiol* 2005;116(8):1756–61.
 25. Vredeveld JW, Richards R, Rozeman CA, Blaauw G, Slooff AC. The electromyogram in obstetric brachial palsy is too optimistic: fiber size or another explanation? *Muscle Nerve* 1999;22(3):427–9.
 26. Yilmaz K, Caliřkan M, Oge E, Aydinli N, Tunaci M, Ozmen M. Clinical assessment, MRI, and EMG in congenital brachial plexus palsy. *Pediatr Neurol* 1999;21(4):705–10.
 27. Vredeveld JW, Blaauw G, Slooff BA, Richards R, Rozeman SC. The findings in paediatric obstetric brachial palsy differ from those in older patients: a suggested explanation. *Dev Med Child Neurol* 2000;42(3):158–61.
 28. Belzberg AJ, Dorsi MJ, Storm PB, Moriarity JL. Surgical repair of brachial plexus injury: a multinational survey of experienced peripheral nerve surgeons. *J Neurosurg* 2004;101(3):365–76.
 29. Grossman JAI, Price A, Chim H. Complications in Surgery for Brachial Plexus Birth Injury: Avoidance and Treatment. *J Hand Surg Am* 2018;43(2):164–72.
- ### SUPPORTING INFORMATION
- The following additional material may be found online:
- Figure S1:** Timeline of key events after BPI for each of the 21 participants, including MRI, EMG, and surgical interventions.
- Figure S2:** AMS.
- Figure S3:** Coronal 3D T2-weighted imaging from participant 10.
- Figure S4:** Coronal 3D short tau inversion recovery T2-weighted imaging from participant 10.
- Figure S5:** Axial 3D T2-weighted imaging from participant 7.
- Figure S6:** Axial 3D constructive interference in steady state T2-weighted imaging from participant 19.
- Figure S7:** Nerve conduction study amplitudes.
- Figure S8:** Average EMG motor unit amplitude severity scores.
- Figure S9:** Average EMG motor unit duration severity scores.
- Figure S10:** Average EMG motor unit recruitment and activation scores.
- Figure S11:** Aggregate EMG severity scores.
- Figure S12:** Denervation scores by root level.
- How to cite this article:** Portwood KA, Albayram ME, Stone SA, Zingariello CA, Sladky JO, Chim HA, et al. Clinical, electrophysiological, and imaging findings in childhood brachial plexus injury. *Dev Med Child Neurol*. 2022;64:1254–1261. <https://doi.org/10.1111/dmcn.15255>