



Outcomes of root canal therapy or full pulpotomy using two endodontic biomaterials in mature permanent teeth: a randomized controlled trial

Saeed Asgary¹ · Mohammad Jafar Eghbal¹ · Arash Shahravan² · Eshaghali Saberi³ · Alireza Akbarzadeh Baghban⁴ · Ardavan Parhizkar¹

Received: 31 August 2021 / Accepted: 20 November 2021 / Published online: 2 December 2021
© The Author(s), under exclusive licence to Springer-Verlag GmbH Germany, part of Springer Nature 2021

Abstract

Objective The concept of minimally invasive endodontics recommends less-invasive vital pulp therapy (VPT) modalities over more aggressive traditional endodontic approaches in mature permanent teeth with carious pulp exposure, including irreversible pulpitis (IP) cases. Consequently, VPT needs to be compared with root canal therapy (RCT) in terms of treatment outcomes. This randomized clinical trial compares the results of full pulpotomy using two calcium-silicate cements, i.e., mineral trioxide aggregate (MTA) and calcium-enriched mixture (CEM) cement, with RCT in mature permanent teeth.

Materials and methods A total of 157 carious pulp exposure cases in two academic centers with/without established IP were selected/included/randomly appointed to three study arms; (i) RCT ($n = 51$) as the reference treatment, (ii) pulpotomy with ProRoot MTA (PMTA; $n = 55$), and (iii) pulpotomy with CEM cement (PCEM; $n = 51$) as two alternative VPT treatments. Two-year clinical/radiographic results were the outcomes of interest. Data were statistically analyzed through the analysis of variance, chi-square, Fisher exact test, and Kruskal–Wallis.

Results At 2-year recall, 147 teeth were examined (6.4% dropout). All molars, except for one, were clinically functional/symptom-free, and there was no statistical difference between the three study arms ($p = 0.653$). The radiographic success rates in RCT, PMTA, and PCEM arms were 98%, 100%, and 97.9%, respectively, without statistically significant differences ($p = 0.544$).

Conclusion In the management of mature permanent teeth with/without established IP, all experimental groups exhibited equivalent/comparable results.

Clinical relevance Simple VPT using MTA/CEM can be suggested/recommended as a viable advantageous alternative to RCT for the management of carious pulp exposures with/without sign/symptoms of IP.

Keywords CEM cement · Calcium-enriched mixture · Endodontic · Irreversible pulpitis · Mineral trioxide aggregate · Pulpotomy · Pulp regeneration · Tricalcium silicate · Vital pulp therapy

✉ Saeed Asgary
saasgary@yahoo.com

¹ Iranian Center for Endodontic Research, Research Institute for Dental Sciences, Shahid Beheshti University of Medical Sciences, 1983963113 Tehran, Iran

² Endodontology Research Center, Endodontic Department, Dental School, Kerman University of Medical Sciences, 7618751689 Kerman, Iran

³ Endodontic Department, Oral and Dental Diseases Research Center, Dental School, Zahedan University of Medical Sciences, 9816743463 Zahedan, Iran

⁴ Proteomics Research Center, Department of Biostatistics, School of Allied Medical Sciences, Shahid Beheshti University of Medical Sciences, 1971653313 Tehran, Iran

Introduction

For many years, it had been commonly thought that mature permanent teeth with signs and symptoms of irreversible pulpitis (IP) should be managed with root canal treatment (RCT) or surgical extraction. Case–control/longitudinal studies have shown up to a 98% survival rate with RCT [1, 2]; however, epidemiological/cross-sectional studies have revealed a lower percentage of treatment success (34–76%), which could be due to the poor quality of treatment completed [3, 4]. Endodontology has recently shifted its focus to the preservation of vital pulpal tissues which would shorten the course of treatment and improve the long-term prognosis

for tooth retention/function [5]. Logically, in comparison to tooth extraction, RCT is a more-biological and less-invasive but complex, time-consuming, and more expensive treatment modality; however, in comparison with vital pulp therapy (VPT), it is a less-biological and more-invasive but complex, time-consuming, and more expensive treatment modality [6].

As a minimally invasive approach, VPT includes step-wise excavation of decayed tissues, direct/indirect pulp capping, partial/full pulpotomy, and partial pulpectomy [7–10], and have shown to (i) preserve the vital pulp and maintain its physiological and defensive functions, (ii) remove less hard tissue, and result in an increase in tooth strength/survival, (iii) save time, (iv) reduce cost, (v) resolve pain/discomfort [5], and (vi) form a dentinal bridge protecting the remaining vital pulpal tissue from future irritants [11, 12]. A recently published systematic review and meta-analysis on pulpotomy for carious pulp exposure in permanent teeth has clearly stated, “The success of pulpotomy in managing IP challenges the rhetoric that IP can only be managed by RCT” [13]. The growing body of evidence has encouraged endodontists to change their viewpoints and consider more bio-regenerative treatments [14].

A randomized clinical trial, comparing the outcomes of full pulpotomy with RCT in teeth with IP, revealed that the success rate of full pulpotomy was 86% after 2 years [12]. Moreover, a recent systematic review reported 78% success for pulpotomy in teeth with IP [15]. Another trial compared 4 VPTs (indirect pulp capping, direct pulp capping, miniature pulpotomy, and full pulpotomy) using calcium-enriched mixture (CEM) cement in the management of mature molars, including teeth with IP (less than 30% in each VPT group) and apical periodontitis (AP) (~ 10%), showing high success rates for all tested groups (> 91%) after a 1-year follow-up [16].

Biocompatible/bioactive pulp-covering agents have been used to redirect pulp tissue repair toward regeneration. A minimum of 20 bioactive endodontic cements (BECs) have been introduced to root canal treatments [17]; however, a recent systematic review has recommended mineral trioxide aggregate (MTA), calcium-enriched mixture (CEM) cement, and Biodentine as the first choices for use in VPT [17]. CEM cement is a hydraulic calcium silicate–based biomaterial with comparable endodontic applications and similar success rate with MTA [18]. CEM cement has shown biocompatibility, sealing ability, and dentine-inductive capability as well as antibacterial activity similar to calcium hydroxide [19, 20]. CEM cement is currently deliberated as a promising endodontic biomaterial for use in VPT with IP [12, 16]. The outcomes of a 5-year randomized clinical trial showed that the success rate of full pulpotomy using MTA (PMTA) or CEM cement (PCEM) in the treatment of teeth with/without IP/

AP was comparable (84%, vs. 78%, respectively) [21]. Nevertheless, it has been reported that RCT by endodontists has been significantly more successful than that by general dentists [22]; however, the abovementioned difference has not been investigated for VPTs. Endodontists have started to increasingly accept VPT based on the newly introduced evidence [23]. Nowadays, VPT has entered textbooks; however, there is no sufficient evidence to show the success rates of endodontists group.

The aim of the present randomized clinical trial conducted in a controlled academic setting was to compare the 2-year clinical/radiographic outcomes of PMTA or PCEM with single-visit RCT in mature permanent teeth with carious pulp exposure, including IP cases. The null hypothesis of the current study was that the treatment outcomes of PMTA or PCEM would be equivalent to the highly successful outcomes of RCT in molars with/without clinical signs of IP/AP.

Methods

Design and study approval

This study was a two-center, equivalent trial with a randomized, parallel-grouped, and open-labeled design. The Iranian Ministry of Health and Medical Education (IMHME; Deputy Minister of Research) funded, assigned, and supported this project. Iranian Center for Endodontic Research (ICER) and Research Institute for Dental Sciences (RIDS) of Shahid Beheshti University of Medical Sciences (SBMU), Tehran, Iran, have managed the project. The trial was registered in the Iranian Registry of Clinical Trials (Registration Number IRCT20151226025695N3). It was approved by the Ethics Committee of Research Institute for Dental Sciences (IR.SBMU.RIDS.REC.1395.320) and Shahid Beheshti University of Medical Sciences (IR.SBMU.RETECH.REC.1397.1187). The research protocols were approved by RIDS (29–1395/09/23) and SBMU (10466–1396/04/26). The study was conducted in compliance with the ethical principles of the “Declaration of Helsinki” and “General Ethics Guideline” in Medical Sciences Research (which has a human component) in Iran.

Inclusion/exclusion criteria

Study subjects were recruited from the pool of referred patients to postgraduate “Departments of Endodontics” in Kerman and Zahedan dental schools. All patients had to adhere to the inclusion/exclusion criteria. Written informed consent was obtained from all patients.

Inclusion criteria

- Vital mature permanent molars (1st, 2nd, 3rd) with extremely deep caries where carious lesions were observed through the penetration of caries into the entire thickness of the dentine, without a radio-dense zone;
- With/without history of pain indicating IP;
- With/without clinical/radiographic sign of AP;
- Vitality of the pulp was determined via sensibility test (cold test using cold spray)

*Normal cold testing = no lingering pain to cold stimuli

*Lingering pain for more than 10 s after the elimination of the stimulant indicating IP;

- Pulp exposure during caries removal with clinical observation of bleeding (vital dental pulp);
- Teeth without localized/generalized periodontal diseases (depth of probing \leq 3 mm) or root resorption or detectable pulp chamber/root canal calcification or history of trauma;
- Patients with good oral hygiene and without systemic diseases or physical/intellectual disability;
- Non-pregnant/nursing women;
- 14–60 age range;
- Patients accepting to provide informed consent/be available for recalls.

Exclusion criteria

- Non-vital (without response to sensibility “the cold” test)/ and non-restorable teeth (according to definitions/protocols);
- Uncontrollable pulpal bleeding after 5-min application of 0.2% chlorhexidine and reapplication of 5.25% NaOCl for 30 s;
- Patients unwilling to continue treatment/follow-up.

Preoperative conditions and vitality of the dental pulps were clinically evaluated and recorded: the pain intensity using Numerical Rating Scale, presence of symptomatic AP with positive reaction to percussion test, pulp sensibility results using electric pulp test with ratings from 0 to 9, and cold spray.

Randomization

All subjects were assigned to three study arms (RCT/PMTA/PCEM) with simple randomization. Using a

computer-generated system, randomization was performed online (<http://www.mcrcrct.ir>) before the treatments while the patients/operators were not aware of the group assignment. All the allocated patients received a unique patient identification code. All participants were blinded to the group allocation.

Sample size calculation

Sample size was calculated based on the 2-year outcomes in previous studies [12, 21]; the 2-year success rates of PMTA and RCT were ~94% and 80%, respectively. Considering the effect size of 0.140, $\alpha=0.05$ and $\beta=0.2$ (power=80%), the estimated sample size was 138 (Software: Pass 15 – Version 15.0.5; 2017). Taking 10% dropout per year into consideration, 154 samples were selected for the present trial.

Treatment protocols

Reference treatment (Arm-1): RCT

A 0.2% chlorhexidine mouth-rinse was initially used by each patient. Teeth were anesthetized and isolated with rubber dam. Soft dentin was completely removed and once/if carious pulp exposure was visualized, access cavity was prepared. Working lengths were determined using Root ZX apex locator (J. Morita, Irvine, CA) and then confirmed with a radiograph. Root canal preparation was performed using BioRaCerotary instruments (FKG Dentaire, La Chaux-de-Fonds, Switzerland). The endodontic electric motor (Endo-Mate TC, NSK, Nakanishi Inc., Tokyo, Japan) was adjusted at 600 rpm and 1.5 Ncm. Rotary files were employed to the length of the canals with the recommended sequences/motions according to the manufacturer’s instructions. Root canals were irrigated with 5.25% NaOCl. Using #10 K-file, canal patency was established. Typically, a master apical file ranged to BR4 (35/0.04) or BR5 (40/0.04) for straight and BR4C (35/0.02) for curved canals. After radiographic verification of the master cone, root canals were filled/sealed (AH26) with lateral condensation technique. Using open/closed sandwich techniques, the coronal cavities were filled permanently with glass ionomer (ChemFil, Dentsply, Konstanz, Germany) and light-cured resin-bonded dental composite (Filtek flowable/Z250/Z350, 3 M, ESPE, USA) [24].

Pulpotomy with MTA (Arm-2): PMTA

Similar to the first arm, teeth were disinfected, anesthetized, and isolated; and complete/full pulpotomy was performed. Then, a sterile cotton pellet soaked in 0.2% chlorhexidine was placed into the pulp chamber for 5 min to achieve hemostasis. If hemostasis cannot be achieved, after copious irrigation of the cavity with normal saline,

the procedure was repeated with a sterile cotton pellet soaked in 5.25% NaOCl for 30 s. Next, the blood clot-free pulpal wound was covered with at least 2-mm-thick layer of ProRoot MTA (Dentsply, OK, USA), which was prepared according to the manufacturer's instructions. Coronal cavities were permanently restored within the same treatment session using the same restorative materials considered in RCT group.

Pulpotomy with CEM cement (Arm-3): PCEM

Treatment process of this arm was the same as Arm-2 except for the pulp coverage with CEM cement (BioniqueDent, Tehran, Iran).

Calibration

Postgraduate students with similar expertise/skills contributed in this trial. They attended an orientation course at ICER and were considered qualified for the trial when they successfully passed the final evaluation/exam. One academic staff (i.e., endodontist) from each department agreed to supervise all processes/activities, i.e., accordance of including and excluding criteria, standardization of treatment, assessment of the outcomes, and recording of the data.

Outcome measures and recalls

Analogous to previous trials, having had established the efficacy of RCT and PCEM in mature permanent teeth [12, 25, 26], the primary outcome measures were considered the 2-year clinical/radiographic results, whereas the secondary outcome measure was the pain relief achieved throughout the 7 postoperative days, which the obtained results have already been published [24].

Patients were recalled for clinical/radiographic examination 2 years postoperatively. The outcome of clinical success/failure was determined by the subjective symptoms and objective observation of inflammation/infection. Objective signs, e.g. abscess, swelling, sinus tract, redness, pain, and tenderness to percussion, were initially examined by postgraduate students and then reconfirmed by the supervising academic staff.

Two board-certified endodontists independently evaluated the postoperative radiographs. They used a strict definition of endodontic diseases and reported a positive finding only when absolutely certain. Where disagreement occurred on a case, the final decision was made after discussion by consensus between them. The outcome of radiographic success was classified using a modification of Strindberg's criteria; teeth

with normal contour/width of PDL were deliberated as success, and teeth with periapical radiolucency were reported as failure.

Statistical analysis

In addition, the postoperative pain intensity (recorded by Numerical Rating Scale (NRS)), distribution of severity, survival, and trend in the study arms were measured using one-way/repeated measure ANOVA and Kruskal–Wallis tests. Statistical analysis of data was carried out using analysis of variance (ANOVA), chi-square (χ^2), Fisher's exact, and Kruskal–Wallis tests. There was no unplanned crossover; therefore, the worst case scenario was carried out to handle the intention to treat. Type I error was considered 0.05.

Results

Figure 1 shows the passage of patients through the current trial. One hundred and fifty-seven patients, who had met the inclusion criteria, were recruited in the trial; however, 147 patients completed the 2-year follow-up (Kerman: $n = 81$, Zahedan: $n = 66$, and dropout = 6.4%).

The statistical analyses revealed no significant differences between the study arms with respect to demographic characteristics, i.e., age/age category/gender/marital status/educational status (Table 1).

The three arms of participants were well-balanced with regard to the baseline data, i.e., pain intensity, distribution of teeth/jaw, characteristics of treated teeth, sensibility pulp tests (cold/electric test), periodontal probing, widening of PDL in the preoperative radiograph, and presence of symptomatic IP/AP (Table 2). All the tests initially conducted were repeated for the evaluation of results.

After pulp exposure, most cases in each study arm had normal bleeding; however, 9.8%, 23.6%, and 27.5% of cases in the RCT, PMTA, and PCEM arms demonstrated profound (but controllable) bleeding, respectively (Table 3). In all full pulpotomy cases with excessive bleeding after the 5-min application of chlorhexidine, hemostasis was achieved following a 30-s application of NaOCl (Table 3).

Mean follow-up times were 27.49 ± 5.47 , 26.98 ± 4.91 , and 27.83 ± 5.03 months in the RCT, PMTA, and PCEM arms, respectively, with no statistical significance difference ($p = 0.713$).

The results of sensibility pulp tests at 2-year recall revealed that although only 2 cases in each pulpotomy arms had responded to the cold test, the number of cases responding to electric pulp test in the pulpotomy arms was statistically different ($p = 0.008$) (Table 4). Furthermore,

Fig. 1 CONSORT flow diagram of patients through each stage of randomized controlled trial

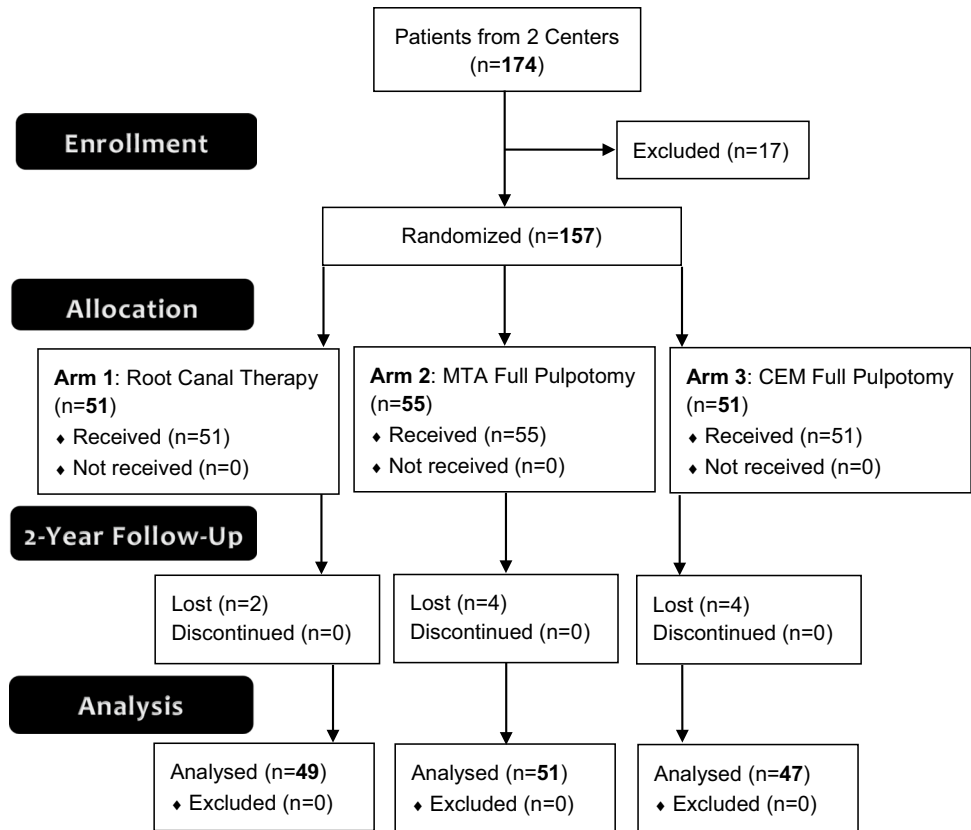


Table 1 Comparison of patient demographics in the three study arms

Demographic	RCT (n=51)	PMTA (n=55)	PCEM (n=51)	Test	p value
Age (mean years ± SE)	32.92 ± 1.29	30.80 ± 1.23	31.35 ± 1.32	ANOVA	0.480
Age category, N (%)					
10 ≤ age ≤ 25	10(19.6)	19(34.4)	13(25.5)		
25 < age ≤ 35	21(41.2)	18(32.7)	22(43.1)		
35 < age ≤ 45	16(31.4)	13(23.6)	11(21.6)	χ ²	0.638
45 < age ≤ 60	4(7.8)	5(9.1)	5(9.8)		
Gender, N (%)					
Male	14(27.5)	21(38.2)	14(27.5)	χ ²	0.384
Female	37(72.5)	34(61.8)	37(72.5)		
Marital status, N (%)					
Single	14(27.5)	25(45.5)	21(41.2)	χ ²	0.141
Married	37(72.5)	30(54.5)	30(58.8)		
Educational level, N (%)					
< 12 years	11(21.6)	8(14.5)	16(31.4)		
= 12 years (diploma)	23(45.1)	23(41.8)	14(27.5)	χ ²	0.064
Associate of science	8(15.7)	2(3.6)	5(9.8)		
Bachelor of science	8(15.7)	17(30.9)	12(23.5)		
Master of science	1(2.0)	5(9.1)	4(7.8)		

RCT root canal therapy, PMTA full pulpotomy with MTA, PCEM full pulpotomy with CEM cement

considering grouping pain severities (i.e., pain-free status, mild, moderate, and severe pain) in different postoperative time intervals, i.e., 6/12/18/24/36 h and 3/4/5/6/7 days, the Kruskal–Wallis test revealed that there were no significant

differences between the study arms ($p=0.496–0.942$). In addition, the distribution of pain severities was comparable between the arms ($p=0.056–0.993$).

Table 2 Baseline characteristics and preoperative conditions in the three study arms

Preoperative factors	RCT (<i>n</i> = 51)	PMTA (<i>n</i> = 55)	PCEM (<i>n</i> = 51)	Test	<i>p</i> value
Pain intensity, 0–9 scale (mean ± SE)	3.71 ± 0.41	4.00 ± 0.42	3.73 ± 0.44	ANOVA	0.857
95% confidence interval (CI) for mean	2.88–4.53	3.16–4.84	2.84–4.61		
Distribution of teeth, <i>N</i> (%)					
Maxilla	26(51.0)	20(36.4)	26(51.0)	χ^2	0.215
Mandible	25(49.0)	35(63.6)	25(49.0)		
First molar	30(58.8)	25(45.5)	29(56.9)	Fisher	0.281
Second molar	20(39.2)	30(54.5)	20(39.2)		
Third molar	1(2.0)	0(0.0)	2(3.9)		
Characteristics of teeth, <i>N</i> (%)					
With occlusal contact	51(100.0)	49(89.1)	49(96.1)	Fisher Fisher	0.055
Without occlusal attrition	47(92.2)	54(98.2)	51(100.0)	χ^2	0.061
Presence of coronal restoration	10(19.6)	8(14.5)	10(19.6)		0.732
Electric pulp testing, (mean ± SE)	4.67 ± 0.28	4.95 ± 0.29	4.69 ± 0.29	ANOVA	0.746
Cold testing (normal response), <i>N</i> (%)	30(58.8)	38(69.1)	33(64.7)	χ^2	0.543
Widening of PDL, <i>N</i> (%)	0(0.0)	1(1.8)	3(5.9)	Fisher	0.216
Symptomatic irreversible pulpitis, <i>N</i> (%)	21(41.2)	17(30.9)	18(35.3)	χ^2	0.543
Symptomatic apical periodontitis, <i>N</i> (%)	6(11.8)	17(30.9)	13(25.5)	χ^2	0.056

RCT root canal therapy, PMTA full pulpotomy with MTA, PCEM full pulpotomy with CEM cement

Table 3 Comparison of interoperative conditions in the three study arms

Interoperative factors	RCT (<i>n</i> = 51)	PMTA (<i>n</i> = 55)	PCEM (<i>n</i> = 51)	Test	<i>p</i> value
Mechanical pulp exposure type, <i>N</i> (%)	0(0.0)	0(0.0)	0(0.0)	NA	NA
Bleeding nature, <i>N</i> (%)					
Not seen	5 [¶] (9.8)	2 [¶] (3.6)	2 [¶] (3.9)	Kruskal Wallis	0.135
Oozing	12(23.5)	18(32.7)	10(19.6)		
Normal	29(56.9)	22(40.0)	25(49.0)		
Profound (but controllable)	5(9.8)	13(23.6)	14(27.5)		
Hemostasis: not achieved, <i>N</i> (%)					
Using chlorhexidine (5 min)	NA [§]	23(41.8)	21(41.2)	χ^2	0.947
Using sodium hypochlorite (30 s)	NA	0(0.0)	0(0.0)	NA	NA

RCT root canal therapy, PMTA full pulpotomy with MTA, PCEM full pulpotomy with CEM cement. [¶]Dental pulp tissue was present; [§]Not applicable

Table 4 Comparison of results of 2-year follow-up in the three study arms

Postoperative factors	RCT (<i>n</i> = 51)	PMTA (<i>n</i> = 55)	PCEM (<i>n</i> = 51)	Test	<i>p</i> value
Cold test, positive response, <i>N</i> (%)	NA [¶]	2(3.9)	2(4.3)	Fisher	1.000
Electric pulp test, positive response, <i>N</i> (%)	NA	10(19.6)	21(44.7)	χ^2	0.008*
Percussion test, positive response, <i>N</i> (%)	1(2.0)	0(0.0)	0(0.0)	Fisher	0.653
Clinical success, <i>N</i> (%)	48(98.0)	51(100.0)	47(100.0)	Fisher	0.653
Radiographic success, <i>N</i> (%)	48(98.0)	51(100.0)	46(97.9)	Fisher	0.544
Overall success, <i>N</i> (%)	48(98.0)	51(100.0)	46(97.9)	Fisher	0.544

RCT root canal therapy, PMTA full pulpotomy with MTA, PCEM full pulpotomy with CEM cement. [¶]Not applicable, *Statistical difference

Clinical success at 2-year follow-up was 98%, 100%, and 100% in the RCT, PMTA, and PCEM arms, respectively, without a statistical difference ($p > 0.05$). The results of the radiographic evaluation showed that only one case in RCT and PCEM arms was classified as an unfavorable outcome

(Table 4). Intention to treat analysis using the worst case scenario confirmed $p = 0.397$ for clinical and $p = 0.279$ for radiographic success.

Discussion

The presented long-term randomized clinical trial has shown that full pulpotomy can be considered a valid treatment option for the management of mature teeth with cariously exposed pulp (with/without IP/AP). In addition, full pulpotomy results with the two endodontic biomaterials, i.e., MTA and CEM cement, are comparable to RCT outcomes. The main goal of VPT or RCT is to prevent/resolve AP, subside/resolve pain/infection, and restore function. When the outcomes of VPT and RCT as two main treatment modalities are statistically comparable, the assessment of health technology will confirm/recommend “the substitution of RCT with VPTs” with respect to the benefits for patients/population [6], which has been revealed by the current study as well as by the recent position statement of the American Association of Endodontists [23]. Furthermore, our previous report has revealed that in terms of pain intensity, distribution of severity, survival, and trend, there were no significant differences between three study arms, reconfirming this substitution strategy [24].

Biomaterials owe their success mainly to their biocompatibility; however, other characteristics of a biomaterial, e.g., bioactivity, should be considered [27]. When a biomaterial is simultaneously biocompatible and bioactive, it may be able to form a tight seal to prevent bacterial recontamination. MTA and CEM cement have (i) shown to create a physical seal, preventing the re-entrance of bacteria and their by-products to the exposed pulp [28], and (ii) exhibited biocompatibility and bioactivity when applied as capping biomaterials, causing a biological seal via deposition of hydroxyapatite-like structures on the interface between the biomaterial and pulpal tissues [29]. Different studies have reported biocompatibility/bioactivity for MTA and CEM as two commonly used biomaterials for VPTs [21, 30–34].

A recent systematic review has reported that the most current evidence on the treatment outcomes of VPT in such teeth are based on single-arm trials; therefore, and in order to further support the adoption of full pulpotomy in current practice, they suggested that the best design is the comparison of VPT with RCT in randomized clinical trials [35]. Additionally, a recent systematic review has concluded that VPTs, specifically full pulpotomy, have exhibited a high success rate in managing carious pulp exposure of cases with IP and can be a suitable potential substitute for RCT [13, 36]. Researchers have strongly suggested that large/high-quality/well-designed/adequately powered randomized controlled trials are a necessity to universally change the clinical practice. Furthermore, researchers have recently proposed that cost-effective analysis should be the center of focus rather

than the effectiveness analysis for evaluating the benefits of alternative treatments [13]. It is established that full pulpotomy has a reasonable price in comparison to RCT [6, 12, 37]. Consequently, the current project was performed/executed to reach the necessary pool of evidence in this regard.

Hemostasis is recommended for VPT procedures; a recent systematic review has revealed that time for hemostasis in different studies on VPT varies from 1 to 10 min [38]. The obtained results of the current study showed that hemostasis was not achieved in ~41% of cases after 5-min application of chlorhexidine; however, hemostasis occurred in all cases following the subsequent application of NaOCl. It has been traditionally claimed that the prolonged/profuse bleeding in VPT, as a sign of inflammation, is a negative factor for successful outcomes [39]. An old review has stated that if pulpal hemorrhage cannot be controlled in < 10 min, the inflammation has progressed into the radicular pulp and therefore, VPTs should be shifted to pulpectomy/RCT [39]. Another study proposed that “2 min” is the time for achieving hemostasis to discriminate reversible pulpitis from IP [40]. However, these studies have not been based on histological findings in human teeth. Most patients in our pulpotomy arms exhibited 2-year successful outcomes; thus, it seems that time needed for hemostasis as well as the type of pulpal wound lavage solutions (NaOCl/chlorhexidine/saline) had no effect on the success rate of the treatment. Similarly, several investigations have shown that the time needed for hemostasis had no statistically significant effect on the pulpotomy outcomes [32, 41]. Besides, a recent systematic review has highlighted the insignificant/unimportant role of the bleeding time on unfavorable outcomes [38]. Currently, the best evidence does not support any association between the pulpal bleeding time, the inflammatory status of the pulp, and the indication for pulpotomy vs. pulpectomy. However, the relationship between time needed for hemostasis and treatment outcomes is still unclear, and the duration/intensity of bleeding, time for hemostasis, and application of hemostatic agents in VPT need to be more investigated in future trials [42].

Our results showed that 35% and 23% of the enrolled patients were diagnosed with symptomatic IP and symptomatic AP, respectively. The American Association of Endodontists (AAE; 2013) defines IP as a clinical diagnosis based on the subjective and objective findings, which discloses that the vital pulp is incapable of healing and that RCT is indicated. Moreover, based on the “AAE Guide to Clinical Endodontics (2013),” mature permanent teeth with IP should be treated with RCT, whereas VPTs were contraindicated. However, in addition to the promising outcomes of our trial, several clinical studies/trials have reported successful results for the VPT management of mature permanent teeth with signs/symptoms of IP even with AP [5, 13, 15–17, 21, 24–26, 35, 39, 40, 43–45]. There is firm evidence that

severely inflamed pulpal connective tissue has great regenerative ability [46]. Therefore, the growing portfolio of evidence simply indicates that VPTs are suitable/proper treatment of mature permanent teeth with IP/AP. In their recent position, the AAE has stated that VPTs can be deliberated as suitable treatments for mature permanent teeth when proper diagnosis and appropriate evaluations have been conducted [23].

In the view of “current best evidence,” endodontology rigorously needs to reclassify the nomenclatures of pulpal pathosis. Since there is no consistent association between clinical signs/symptoms (i.e., pulp sensibility testing) and actual histopathology of diseased pulp, researchers have suggested that the general term *pulpitis* is a more acceptable diagnostic term, as *pulpitis* includes both reversible/irreversible forms [47]. This reclassification by the AAE may cause dental professionals, i.e., academic/non-academic endodontists and general practitioners, to feel confident and consequently choose VPT for the management of incoherently named *irreversible pulps*. Several countries across the world have already conducted trials on similar cases [48, 49]; thus, it seems that VPT can soon become popular/beneficial worldwide. However, some clinicians, especially non-academic ones, resist performing VPTs routinely for patients due to the individual resistance to every change that is new and not yet universally embraced, a natural human behavior [50]. This response can be reformed/reasoned by setting up professional development workshops, getting academics involved, and guiding research. Once this line of treatment is considered a universal guideline, there may be other objections, predominantly related to clinician payment/conflict of interest, which is ethically objectionable and may require a supervision/stewardship system after the establishment of treatment guidelines. Many studies have concluded that balancing the payment for clinicians’ services could generate motives and lead them to treat more appropriately [51]. Beside the regulatory systems, adherence to the principles of professionalism should encourage care providers to adopt procedures, which may be financially detrimental to them but beneficial for patients.

Furthermore, the outcomes of the present randomized clinical trial revealed that age/gender/marital status/educational level/distribution of teeth and jaw/characteristics of treated teeth/intensity of preoperative pain/results of sensibility pulp tests/preoperative PDL widening had no effect on the success. However, these results may be different if the sample size is huge. Nevertheless, endodontic literature supports the cause-and-effect relation between the absence/presence of microorganisms (due to apical/coronal leakage) with treatment success/failure, respectively [52, 53].

The results of sensibility pulp tests revealed that the cold test was not able to determine the pulp vitality of pulpotomized teeth after the 2-year recall, whereas electric pulp

test showed to be able to detect the vitality in 21% of cases. This result may be an important finding that can be further evaluated in future studies; however, the accuracy of these tests might not be valid for the determination of pulp status/vitality [54]. These tests should be literally replaced by pulp vitality tests (pulse oximetry/rapid dipstick method) to obtain accurate diagnosis of pulp status [55, 56]. On other hand, the negative response of such teeth with no coronal pulp can be categorized as a false response or may be referred to as pulp necrotic cases in which the corresponding lesions could not be created or detected on periapical radiographs.

Pulp healing is not expected to occur when pulpal wound is reinfected; consequently, the “surprising victory” of VPTs in studies throughout the last decade is likely to be indebted to effective sealing ability of BECs [19]. Additionally, in terms of the absence of inflammation and presence of thicker dentinal bridge, BECs (e.g., MTA/CEM cement) have demonstrated excellent performance in comparison to calcium hydroxide [30]. More than 20 BECs have been introduced to the profession and many controversies persist regarding the required tests for the evaluation of their safety for clinical application. Undoubtedly, controlled clinical trials remain the best pathway to approve of a treatment modality. A recent review of clinical trials has recommended MTA, Biodentine, and CEM cement as the first choices for VPTs [21]. However, the main limitation of clinical trials is the difficulty of long-term follow-ups; nevertheless, our study managed to end-up with < 7% dropout at 27-month follow-up, which expresses a promising result.

Since early 2020 and with the reoccurring outbreaks of the COVID-19 infection, endodontics has faced unprecedented serious challenges, especially in treatment protocols. The economic pressure and financial constraints of individuals to undertake required treatments and the intensification of patients’ fear for seeking proper/appropriate medical services, specifically endodontics as dental emergency, are important issues to be addressed by scientific community in the corresponding field. In terms of patient-related short- and long-term outcomes, prompt reduction in pain intensity has reportedly occurred after full pulpotomy using MTA/CEM cement [45]. Moreover, our results exhibited fascinating 2-year treatment outcomes for full pulpotomy as a minimally invasive approach. In addition, full pulpotomy, as a simple biotechnological approach, is cost-effective/time-saving, opposed to conventional RCT [6]. It seems that VPT can concurrently address the previously mentioned issues effectively. Thus, we, as academics, have a new mission: to publish further long-term results, get more international academics/colleagues on board, and develop/apply VPT as new biotechnology in endodontics.

Conclusion

Pulpotomy using MTA/CEM cement can be considered a valid treatment option in mature permanent teeth with cariously exposed pulp.

Acknowledgements The authors would like to thank all patients who took part in this randomized clinical trial. The trial was approved and supported by the Deputy Minister of Research, Iranian Ministry of Health and Medical Education and this is greatly acknowledged. The authors also want to thank Kerman and Zahedan Dental Schools that participated in this trial and all scientific/administrative people involved in the clinical/organizational works.

Funding The project was approved and supported by the Deputy Minister of Research, Iranian Ministry of Health and Medical Education.

Declarations

Ethics approval All procedures performed in this trial were in accordance with the ethical standards of the institutional and/or national research committee and approved by Ethics Committee of Research Institute for Dental Sciences (IR.SBMU.RIDS.REC.1395.320) and Shahid Beheshti University of Medical Sciences (IR.SBMU.RETECH.REC.1397.1187). The study was conducted in compliance with the ethical principles of the “Declaration of Helsinki” and “General Ethics Guideline” in Medical Sciences Research (which has a human component) in Iran.

Consent to participate Informed consent was obtained from all individual participants included in the study.

Conflict of interest Dr. Asgary is the inventor of CEM cement (Endodontic Filling Material; USA, 7,942,961, 2011 May 17). All other authors declare that there are no conflict of interest regarding the publication of this paper.

References

- Moazami F, Sahebi S, Sobhnamayan F, Alipour A (2011) Success rate of nonsurgical endodontic treatment of nonvital teeth with variable periradicular lesions. *Iran Endod J* 6:119–124
- Friedman S, Mor C (2004) The success of endodontic therapy—healing and functionality. *J Calif Dent Assoc* 32:493–503
- Asgary S, Shadman B, Ghalamkarpour Z, Shahravan A, Ghoddusi J, Bagherpour A, Akbarzadeh Baghban A, Hashemipour M, Ghasemian Pour M (2010) Periapical status and quality of root canal fillings and coronal restorations in Iranian population. *Iran Endod J* 5:74–82
- Siqueira JF Jr, Roca IN, Riche FN, Provenzano JC (2008) Clinical outcome of the endodontic treatment of teeth with apical periodontitis using an antimicrobial protocol. *Oral Surg Oral Med Oral Pathol Oral Radiol Endod* 106:757–762. <https://doi.org/10.1016/j.tripleo.2008.06.007>
- Wolters WJ, Duncan HF, Tomson PL, Karim IE, McKenna G, Dorri M, Stangvaltaite L, van der Sluis LWM (2017) Minimally invasive endodontics: a new diagnostic system for assessing pulpitis and subsequent treatment needs. *Int Endod J* 50:825–829. <https://doi.org/10.1111/iej.12793>
- Yazdani S, Jadidfar MP, Tahani B, Kazemian A, Dianat O, Alim Marvasti L (2014) Health technology assessment of CEM pulpotomy in permanent molars with irreversible pulpitis. *Iran Endod J* 9:23–29
- Asgary S, Nourzadeh M, Eghbal MJ (2016) Miniature pulpotomy of symptomatic mature permanent teeth: a report of two cases. *Iran Endod J* 11:75–78. <https://doi.org/10.7508/iej.2016.01.015>
- Asgary S, Fazlyab M, Sabbagh S, Eghbal MJ (2014) Outcomes of different vital pulp therapy techniques on symptomatic permanent teeth: a case series. *Iran Endod J* 9:295–300
- Asgary S, Kemal Caliskan M (2015) Vital pulp therapy of a mature molar with concurrent hyperplastic pulpitis, internal root resorption and periradicular periodontitis: a case report. *Iran Endod J* 10:284–286. <https://doi.org/10.7508/iej.2015.03.015>
- Eggmann F, Gasser TJW, Hecker H, Amato M, Weiger R, Zaugg LK (2021) Partial pulpotomy without age restriction: a retrospective assessment of permanent teeth with carious pulp exposure. *Clin Oral Investig*. <https://doi.org/10.1007/s00784-021-04007-2>
- Mousavi SA, Ghoddusi J, Mohtasham N, Shahnasari S, Paymanpour P, Kinoshita J (2016) Human pulp response to direct pulp capping and miniature pulpotomy with MTA after application of topical dexamethasone: a randomized clinical trial. *Iran Endod J* 11:85–90. <https://doi.org/10.7508/iej.2016.02.002>
- Asgary S, Eghbal MJ, Ghoddusi J (2014) Two-year results of vital pulp therapy in permanent molars with irreversible pulpitis: an ongoing multicenter randomized clinical trial. *Clin Oral Investig* 18:635–641. <https://doi.org/10.1007/s00784-013-1003-6>
- Li Y, Sui B, Dahl C, Bergeron B, Shipman P, Niu L, Chen J, Tay FR (2019) Pulpotomy for carious pulp exposures in permanent teeth: a systematic review and meta-analysis. *J Dent* 84:1–8. <https://doi.org/10.1016/j.jdent.2019.03.010>
- Leong DJX, Yap AU (2021) Vital pulp therapy in carious pulp-exposed permanent teeth: an umbrella review. *Clin Oral Investig*. <https://doi.org/10.1007/s00784-021-03960-2>
- Zafar K, Nazeer MR, Ghafoor R, Khan FR (2020) Success of pulpotomy in mature permanent teeth with irreversible pulpitis: a systematic review. *J Conserv Dent* 23:121–125. https://doi.org/10.4103/JCD.JCD_179_19
- Asgary S, Hassanizadeh R, Torabzadeh H, Eghbal MJ (2018) Treatment outcomes of 4 vital pulp therapies in mature molars. *J Endod* 44:529–535. <https://doi.org/10.1016/j.joen.2017.12.010>
- Parirokh M, Torabinejad M, Dummer PMH (2018) Mineral trioxide aggregate and other bioactive endodontic cements: an updated overview - part I: vital pulp therapy. *Int Endod J* 51:177–205. <https://doi.org/10.1111/iej.12841>
- Chen Y, Chen X, Zhang Y, Zhou F, Deng J, Zou J and Wang Y (2019) Materials for pulpotomy in immature permanent teeth: a systematic review and meta-analysis. *BMC Oral Health* 19:227. <https://doi.org/10.1186/s12903-019-0917-z>
- Utneja S, Nawal RR, Talwar S, Verma M (2015) Current perspectives of bio-ceramic technology in endodontics: calcium enriched mixture cement - review of its composition, properties and applications. *Restor Dent Endod* 40:1–13. <https://doi.org/10.5395/rde.2015.40.1.1>
- Adel M, Nima MM, Shivaie Kojoori S, Norooz Oliaie H, Naghavi N, Asgary S (2012) Comparison of endodontic biomaterials as apical barriers in simulated open apices. *ISRN Dent* 2012:359873. <https://doi.org/10.5402/2012/359873>
- Asgary S, Eghbal MJ, Bagheban AA (2017) Long-term outcomes of pulpotomy in permanent teeth with irreversible pulpitis: a multi-center randomized controlled trial. *Am J Dent* 30:151–155
- Alley BS, Kitchens GG, Alley LW, Eleazer PD (2004) A comparison of survival of teeth following endodontic treatment performed by general dentists or by specialists. *Oral Surg Oral Med Oral*

- Pathol Oral Radiol Endod 98:115–118. <https://doi.org/10.1016/j.tripleo.2004.01.004>
23. American Association of Endodontists (2021) AAE position statement on vital pulp therapy. *J Endod* 47:1340–1344. <https://doi.org/10.1016/j.joen.2021.07.015>
 24. Eghbal MJ, Haeri A, Shahravan A, Kazemi A, Moazami F, Mozayeni MA, Saberi E, Samiei M, Vatanpour M, Akbarzade Baghban A, Fazlyab M, Parhizkar A, Ahmadi M, Akbarian Rad N, Bijari S, Bineshmarvasti D, Davoudi P, Dehghan R, Dehghani M, Ebrahimi H, Emami N, Farajian N, Fereidooni R, Ghobadi G, Ghodrati M, Gohari A, Hashemi A, Hosseini M, Karami E, Kheirabadi N, Kozegari S, Labaf Ghasemi H, Majidi A, Malekzadeh P, Mehrabi V, Mohammadi M, Moradi Eslami L, Noghani A, Omatali N, Pourhatami N, Rahbani Nobar B, Rahmani S, Shafaq P, Soofitabadi S, Teimoori S, Vatandoost F, Asgary S (2020) Postendodontic pain after pulpotomy or root canal treatment in mature teeth with carious pulp exposure: a multicenter randomized controlled trial. *Pain Res Manag* 2020:5853412. <https://doi.org/10.1155/2020/5853412>
 25. Asgary S, Eghbal MJ, Fazlyab M, Baghban AA, Ghoddsi J (2015) Five-year results of vital pulp therapy in permanent molars with irreversible pulpitis: a non-inferiority multicenter randomized clinical trial. *Clin Oral Investig* 19:335–341. <https://doi.org/10.1007/s00784-014-1244-z>
 26. Asgary S, Eghbal MJ, Ghoddsi J, Yazdani S (2013) One-year results of vital pulp therapy in permanent molars with irreversible pulpitis: an ongoing multicenter, randomized, non-inferiority clinical trial. *Clin Oral Investig* 17:431–439. <https://doi.org/10.1007/s00784-012-0712-6>
 27. Chen FM, Liu X (2016) Advancing biomaterials of human origin for tissue engineering. *Prog Polym Sci* 53:86–168. <https://doi.org/10.1016/j.progpolymsci.2015.02.004>
 28. Zarean P, Zarean P, Ravaghi A, Zare Jahromi M, Sadrameli M (2020) Comparison of MTA, CEM cement, and Biodentine as coronal plug during internal bleaching: an in vitro study. *Int J Dent* 2020:8896740. <https://doi.org/10.1155/2020/8896740>
 29. Hosseinzade M, Soflou RK, Valian A and Nojehdehian H (2016) Physicochemical properties of MTA, CEM, hydroxyapatite and nano hydroxyapatite-chitosan dental cements. *Biomedical Research* (0970–938X) 1:27(2)
 30. Asgary S, Eghbal MJ, Parirokh M, Ghanavati F, Rahimi H (2008) A comparative study of histologic response to different pulp capping materials and a novel endodontic cement. *Oral Surg Oral Med Oral Pathol Oral Radiol Endod* 106:609–614. <https://doi.org/10.1016/j.tripleo.2008.06.006>
 31. Naghavi N, Ghoddsi J, Sadeghnia HR, Asadpour E, Asgary S (2014) Genotoxicity and cytotoxicity of mineral trioxide aggregate and calcium enriched mixture cements on L929 mouse fibroblast cells. *Dent Mater J* 33:64–69. <https://doi.org/10.4012/dmj.2013-123>
 32. Nosrat A, Asgary S, Eghbal MJ, Ghoddsi J, Bayat-Movahed S (2011) Calcium-enriched mixture cement as artificial apical barrier: a case series. *J Conserv Dent* 14:427–431. <https://doi.org/10.4103/0972-0707.87218>
 33. Haghgoo R, Asgary S, Montazeri R (2018) Histopathological evaluation of primary teeth after pulp capping with calcium-enriched mixture and bioactive glass. *Iran Endod J* 13:457–460. <https://doi.org/10.22037/iej.v13i4.20970>
 34. Celik BN, Mutluay MS, Arikan V, Sari S (2019) The evaluation of MTA and Biodentine as a pulpotomy materials for carious exposures in primary teeth. *Clin Oral Investig* 23:661–666. <https://doi.org/10.1007/s00784-018-2472-4>
 35. Cushley S, Duncan HF, Lappin MJ, Tomson PL, Lundy FT, Cooper P, Clarke M, El Karim IA (2019) Pulpotomy for mature carious teeth with symptoms of irreversible pulpitis: a systematic review. *J Dent* 88:103158. <https://doi.org/10.1016/j.jdent.2019.06.005>
 36. Santos JM, Pereira JF, Marques A, Sequeira DB and Friedman S (2021) Vital pulp therapy in permanent mature posterior teeth with symptomatic irreversible pulpitis: a systematic review of treatment outcomes. *Medicina* 57:573. <https://doi.org/10.3390/medicina57060573>
 37. Sadaf D (2020) Success of coronal pulpotomy in permanent teeth with irreversible pulpitis: an evidence-based review. *Cureus* 12:e6747. <https://doi.org/10.7759/cureus.6747>
 38. Zanini M, Hennequin M, Cousson PY (2019) Which procedures and materials could be applied for full pulpotomy in permanent mature teeth? A systematic review. *Acta Odontol Scand* 77:541–551. <https://doi.org/10.1080/00016357.2019.1614217>
 39. Aguilar P, Linsuwanont P (2011) Vital pulp therapy in vital permanent teeth with cariously exposed pulp: a systematic review. *J Endod* 37:581–587. <https://doi.org/10.1016/j.joen.2010.12.004>
 40. Ricucci D, Siqueira JF Jr, Li Y, Tay FR (2019) Vital pulp therapy: histopathology and histobacteriology-based guidelines to treat teeth with deep caries and pulp exposure. *J Dent* 86:41–52. <https://doi.org/10.1016/j.jdent.2019.05.022>
 41. Alqaderi HE, Al-Mutawa SA, Qudeimat MA (2014) MTA pulpotomy as an alternative to root canal treatment in children's permanent teeth in a dental public health setting. *J Dent* 42:1390–1395. <https://doi.org/10.1016/j.jdent.2014.06.007>
 42. Asgary S, Parhizkar A (2021) Importance of 'time' on 'haemostasis' in vital pulp therapy - letter to the editor. *Eur Endod J* 6:128–129. <https://doi.org/10.14744/ej.2020.82574>
 43. Linsuwanont P, Wimonsutthikul K, Pothimoke U, Santiwong B (2017) Treatment outcomes of mineral trioxide aggregate pulpotomy in vital permanent teeth with carious pulp exposure: the retrospective study. *J Endod* 43:225–230. <https://doi.org/10.1016/j.joen.2016.10.027>
 44. Alqaderi H, Lee CT, Borzangy S, Pagonis TC (2016) Coronal pulpotomy for cariously exposed permanent posterior teeth with closed apices: a systematic review and meta-analysis. *J Dent* 44:1–7. <https://doi.org/10.1016/j.jdent.2015.12.005>
 45. Asgary S, Eghbal MJ (2010) The effect of pulpotomy using a calcium-enriched mixture cement versus one-visit root canal therapy on postoperative pain relief in irreversible pulpitis: a randomized clinical trial. *Odontology* 98:126–133. <https://doi.org/10.1007/s10266-010-0127-2>
 46. Schmalz G, Widbill M, Galler KM (2020) Clinical perspectives of pulp regeneration. *J Endod* 46:S161–S174. <https://doi.org/10.1016/j.joen.2020.06.037>
 47. Lin LM, Ricucci D, Saoud TM, Sigurdsson A, Kahler B (2020) Vital pulp therapy of mature permanent teeth with irreversible pulpitis from the perspective of pulp biology. *Aust Endod J* 46:154–166. <https://doi.org/10.1111/aej.12392>
 48. Parinyaprom N, Nirunsittirat A, Chuveera P, Na Lampang S, Srisuwan T, Sastraruji T, Bua-On P, Simprasert S, Khoipanich I, Sutharaphan T, Theppimarn S, Ue-Srichai N, Tangtrakooljaroen W, Chompu-Inwai P (2018) Outcomes of direct pulp capping by using either ProRoot mineral trioxide aggregate or Biodentine in permanent teeth with carious pulp exposure in 6- to 18-year-old patients: a randomized controlled trial. *J Endod* 44:341–348. <https://doi.org/10.1016/j.joen.2017.10.012>
 49. Caliskan MK, Guneri P (2017) Prognostic factors in direct pulp capping with mineral trioxide aggregate or calcium hydroxide: 2- to 6-year follow-up. *Clin Oral Investig* 21:357–367. <https://doi.org/10.1007/s00784-016-1798-z>
 50. Oreg S (2003) Resistance to change: developing an individual differences measure. *J Appl Psychol* 88:680–693. <https://doi.org/10.1037/0021-9010.88.4.680>

51. Field MJ, Lo B (2009) Conflict of interest in medical research, education, and practice. National Academies Press, Washington DC
52. De Moor R, Hommez G (1984) (2000) The importance of apical and coronal leakage in the success or failure of endodontic treatment. *Rev Belge Med Dent* 55:334–344
53. Tan SY, Yu VSH, Lim KC, Tan BCK, Neo CLJ, Shen L, Messer HH (2020) Long-term pulpal and restorative outcomes of pulpotomy in mature permanent teeth. *J Endod* 46:383–390. <https://doi.org/10.1016/j.joen.2019.11.009>
54. Mejare IA, Axelsson S, Davidson T, Frisk F, Hakeberg M, Kvist T, Norlund A, Petersson A, Portenier I, Sandberg H, Tranaeus S, Bergenholtz G (2012) Diagnosis of the condition of the dental pulp: a systematic review. *Int Endod J* 45:597–613. <https://doi.org/10.1111/j.1365-2591.2012.02016.x>
55. Farid H, Khan FR, Pasha L, Shinwari MS (2015) Are pulp sensibility tests still sensible? *J Ayub Med Coll Abbottabad* 27:874–877
56. Duncan HF, BJORNDAL L, van der Sluis L, Rechenberg DK, Simon S, Cooper PR, Ricucci D, Galler K (2019) Third European Society of Endodontology (ESE) research meeting: ACTA, Amsterdam, The Netherlands, 26th October 2018: Deep caries and the exposed pulp: current and emerging therapeutic perspectives. *Int Endod J* 52:135–138. <https://doi.org/10.1111/iej.13059>

Publisher's note Springer Nature remains neutral with regard to jurisdictional claims in published maps and institutional affiliations.