



## Case report

## Serum KL-6 elevation in a uveitis patient with Behçet's disease treated with adalimumab



Takashi Ono<sup>a,b,\*</sup>, Takuya Iwasaki<sup>a</sup>, Yukiko Terada<sup>c</sup>, Kentaro Abe<sup>a</sup>, Jinhee Lee<sup>a</sup>, Manabu Mochizuki<sup>a</sup>, Kazunori Miyata<sup>a</sup>

<sup>a</sup> Miyata Eye Hospital, Miyazaki, Japan

<sup>b</sup> Department of Ophthalmology, Graduate School of Medicine, The University of Tokyo, Tokyo, Japan

<sup>c</sup> Department of Ophthalmology, Tokyo Metropolitan Geriatric Hospital, Tokyo, Japan

## ARTICLE INFO

## Keywords:

Adalimumab  
KL-6  
Behçet's disease  
Interstitial lung disease  
Uveitis

## ABSTRACT

**Purpose:** To report a case of uveitis with Behçet's disease in which serum levels of Krebs von den Lungen (KL)-6, a marker of interstitial lung disease, were elevated during treatment with adalimumab and returned to baseline after discontinuation of the agent.

**Observations:** A 67-year-old man complaining of vision disturbance was referred to our hospital. The patient had a history of recurrent episodes of bilateral uveitis and oral ulcers, and had been diagnosed with Behçet's disease. While uveitis activity was not well controlled under administration of oral prednisolone and cyclosporin, cataract of the right eye developed and required surgery. Biweekly administration of adalimumab 40 mg was therefore initiated with prednisolone at 15 mg/day. Uveitis became well controlled and cataract surgery was successfully carried out for the right eye. However, serum KL-6 gradually elevated to 1002 U/ml by 6 months after adalimumab initiation and 1277 U/ml at 9 months. Because serum KL-6 > 1000 U/ml has been reported to predict interstitial lung disease, we discontinued adalimumab and started cyclosporine at 100 mg/day. Serum KL-6 gradually decreased and returned to baseline levels, no interstitial lung disease developed and exacerbation of uveitis was avoided.

**Conclusions and importance:** This case implies the clinical importance of monitoring serum KL-6 in patients with non-infectious uveitis being treated with adalimumab.

## 1. Introduction

Uveitis is a sight-threatening disease unless treated adequately. Administration of systemic corticosteroids and immunosuppressive agents is standard in the management of ocular inflammatory diseases, including uveitis.<sup>1</sup> More recently, biologics such as tumor necrosis factor (TNF)- $\alpha$  inhibitors have been recommended by expert panels as a new option for the management of ocular inflammatory disorders.<sup>2</sup> Adalimumab is a TNF- $\alpha$  inhibitor, and its efficacy and safety in patients with non-infectious uveitis have been demonstrated by international clinical trials.<sup>3–5</sup> Significant effects of adalimumab on Behçet's disease have also been reported.<sup>6,7</sup> However, biologics can cause a variety of adverse side effects, such as infection and lymphoma. Another important complication caused by TNF- $\alpha$  inhibitors is interstitial lung disease, which has been reported in patients with psoriasis and rheumatoid arthritis.<sup>8,9</sup>

Krebs von den Lungen (KL)-6 is a mucopolysaccharide produced by

type 2 pneumocytes, and has been used as a specific serum marker of interstitial lung disease.<sup>10–12</sup> Values higher than 500 U/ml suggest the possibility of interstitial pneumonia and values higher than 1000 U/ml are considered to indicate active interstitial pneumonia.<sup>13</sup> Although the usefulness and reliability of serum KL-6 monitoring during treatment with anti-TNF- $\alpha$  agents has been suggested in patients with rheumatoid arthritis,<sup>14</sup> no cases describing the monitoring of serum KL-6 in patients with uveitis on anti-TNF- $\alpha$  agents appear to have been reported. Here, we report the case of Behçet's disease treated using adalimumab, in which serum KL-6 levels were monitored during the therapy. Serum KL-6 levels elevated during treatment and returned to baseline soon after cessation of adalimumab.

## 2. Case

A 67-year-old man complained of decreased vision in both eyes and was referred to our eye hospital. He had been treated for uveitis in the

\* Corresponding author. Miyata Eye Hospital, 6-3, Kuraharacho, Miyakonojo, Miyazaki, 885-0051, Japan.

E-mail address: [taono-ky@umin.ac.jp](mailto:taono-ky@umin.ac.jp) (T. Ono).

<https://doi.org/10.1016/j.ajoc.2020.100660>

Received 24 April 2019; Received in revised form 1 September 2019; Accepted 9 March 2020

Available online 13 March 2020

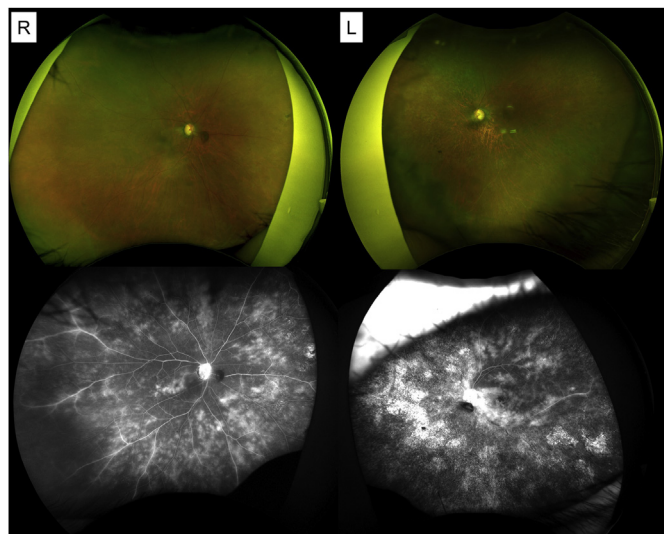
2451-9936/© 2020 The Authors. Published by Elsevier Inc. This is an open access article under the CC BY-NC-ND license

(<http://creativecommons.org/licenses/by-nc-nd/4.0/>).

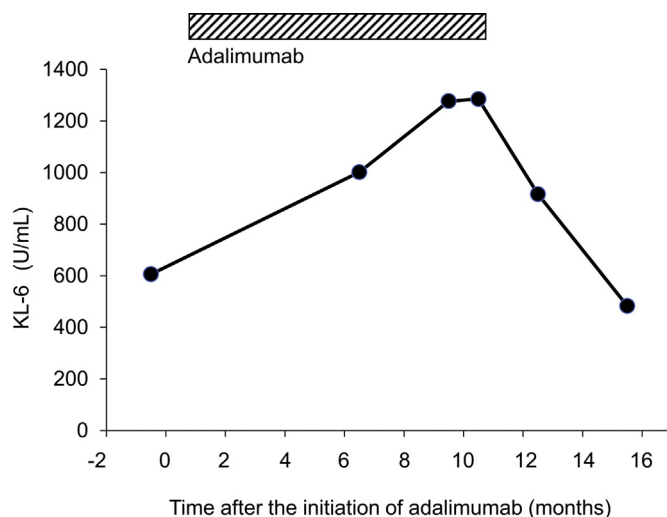
left eye by a local ophthalmologist two years earlier. He also had past histories of infectious pneumonia, gout, sinusitis, and osteoarthritis of the knee.

At the initial presentation, best-corrected visual acuity (BCVA) was 1.5 in the right eye and 0.05 in the left eye, and intraocular pressure was 8 mmHg bilaterally. Slit-lamp examination disclosed 2+ cells, 2+ flare in the anterior chamber of both eyes. Angle hypopyon was observed on gonioscopic examination of the left eye. Ophthalmoscopic examinations disclosed 1+ vitreous opacities and retinal vasculitis in both eyes and neovascularization around the optic disc and degenerative changes in the macular area of the left eye. Fluorescein angiography (FA) showed diffuse, fern-like dye leakage in both eyes and macular degeneration in the left eye. Systemic examinations yielded essentially normal results and excluded infectious diseases. The patient was positive for HLA-B51, but negative for HLA-A26. The patient had experienced recurrent episodes of oral ulceration, but no genital ulcers or cutaneous lesions. Based on these findings, the patient was diagnosed with incomplete-type Behçet's disease according to the Japanese diagnostic criteria.<sup>15</sup>

Betamethasone instillation (0.1%) and 40 mg/day of oral prednisolone were initiated and the dose of prednisolone was gradually decreased. When prednisolone was reduced to 5 mg/day, he developed macular edema in the right eye and erythema nodosum in the skin. Cyclosporin (150 mg/day) was added, and uveitis became inactive for one year thereafter. However, uveitis eventually exacerbated even with prednisolone (15 mg/day) and cyclosporine (150 mg/day), and the patient developed a cataract in the right eye. BCVA decreased to 0.9 in the right eye and 0.01 in the left eye (Fig. 1). Because of the poorly controlled uveitis and the necessity for cataract surgery in the right eye, administration of adalimumab was considered for the patient, and routine systemic examinations were performed in preparation for administration of biologics. Hematological examinations showed no abnormalities other than a slightly high serum concentration of KL-6, at 606 U/ml. He had no finding of tuberculosis or interstitial pneumonia in terms of either clinical manifestations or computed tomography (CT). We then initiated adalimumab treatment, administering 80 mg as an initial dose, and thereafter biweekly 40 mg together with prednisolone (15 mg/day), instead of cyclosporine. Soon after this therapy conversion, uveitis activity became well controlled and cataract surgery with implantation of an intraocular lens was successfully performed at 6 months after adalimumab initiation.

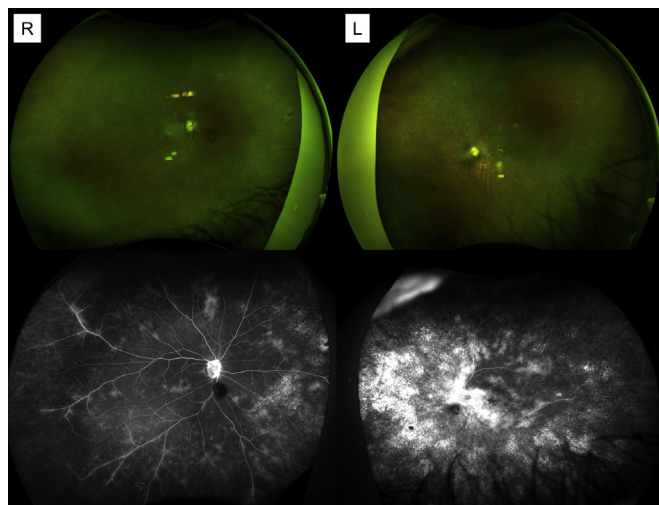


**Fig. 1.** Fundus photos and fluorescein angiography of the patient before starting treatment with adalimumab. Fluorescein angiography shows bilateral severe, broad retinal vasculitis and swelling of the optic disc.



**Fig. 2.** Changes to serum KL-6 in the patient treated with adalimumab. Serum KL-6 was elevated after initiating treatment with adalimumab. Serum KL-6 continued to elevate during treatment and decreased after discontinuation.

After adalimumab was initiated, systemic examinations to monitor adverse effects of adalimumab including serum KL-6 were periodically performed. The level of serum KL-6 gradually elevated to 1002 U/ml at 6 months after adalimumab initiation and 1277 U/ml at 9 months (Fig. 2). The patient showed no abnormal respiratory symptom and chest CT scan was normal although laboratory test showed that white blood cell count was elevated to 10,400 cells/mm<sup>3</sup>. We decided to discontinue adalimumab and convert to the previous therapy of cyclosporine (100 mg/day) four months after cataract surgery, because of the possible risk of interstitial lung disease developing in patients with high serum KL-6. Uveitis activity was kept stable even after converting adalimumab to cyclosporine (Fig. 3). BCVA improved to 1.5 in the right eye and 0.08 in the left eye. Serum levels of KL-6 returned to the baseline level, at 483 U/ml 5 months after cessation of adalimumab (Fig. 2). White blood cell count decreased to normal and findings on follow-up chest CT showed no interstitial pneumonia.



**Fig. 3.** Fundus photos and fluorescein angiography of the patient 1 month after treatment with adalimumab. Fluorescein angiography showed that bilateral retinal vasculitis was decreased compared to before treatment with adalimumab.

### 3. Discussion

This report describes elevated serum KL-6 levels in a patient with Behçet's disease during biweekly adalimumab administration, and these elevated levels of serum KL-6 normalized following discontinuation of adalimumab without interstitial lung disease developing. To the best of our knowledge, this is the first report to describe a transient elevation of serum KL-6 in a case of uveitis treated with TNF- $\alpha$  inhibitor.

KL-6 is a sialylated carbohydrate antigen of Mucin 1, secreted from bronchiolar epithelial cells, bronchial gland cells, and type 2 alveolar epithelial cells. Clinically, elevation of serum KL-6 has been observed in patients with lung injuries where proliferation or regeneration of type 2 alveolar epithelial cells takes place.<sup>16</sup> Ohnishi et al. reported KL-6 as a highly sensitive and specific predictor of interstitial lung disease.<sup>17</sup> Yanaba et al. revealed that mean KL-6 concentration was increased by 20% after 1 year of treatment with adalimumab for psoriasis.<sup>8</sup> Another report in patients with rheumatoid arthritis described elevation of serum KL-6 with fibrotic progression in the lung at nine months after initiation of adalimumab, i.e., an increase of serum KL-6 in 22.2% of patients.<sup>18</sup> Additionally, KL-6 values could also increase with use of infliximab, other TNF- $\alpha$ -inhibiting biologics, without clinical pulmonary events.<sup>8,19</sup> In the current patient, serum KL-6 was increased by more than 200% at 6 months after adalimumab initiation. Taken together, serum KL-6 may increase at around 6–12 months after adalimumab initiation, if an increase is going to occur. Although the current patient did not develop interstitial pneumonia, discontinuation of adalimumab based on results from serum KL-6 monitoring might have prevented the development of interstitial pneumonia in this patient.

The baseline level of serum KL-6 in the current patient was relatively high and this was considered related to the medical history of pneumonia. Adalimumab was given to the patient despite the relatively high serum KL-6 level for the following reasons: 1) conventional treatment with prednisolone and cyclosporine had not achieved good control of uveitis activity; 2) only the eye with useful vision had developed a cataract and required cataract surgery; 3) despite the relatively high level of serum KL-6, the patient had no symptoms of pneumonia or abnormalities on CT examination of the lungs. In fact, surgical interventions such as cataract surgery are known to cause severe inflammatory reactions soon after surgery.<sup>20</sup> In this patient, uveitis activity was well controlled by adalimumab and cataract surgery was successfully performed without severe inflammatory reactions. However, serum KL-6 gradually elevated and increased to over 1000 U/ml (Fig. 2). Some previous reports have demonstrated spontaneous decreases in elevated serum KL-6 without cessation of TNF- $\alpha$  inhibitors.<sup>14,19</sup> In the current case, however, serum KL-6 levels kept increasing and reached over 1000 U/ml, which is the level predicting interstitial pneumonia.<sup>13</sup> The decision was therefore made to discontinue adalimumab. The kinetics of serum KL-6 indicate a significant association between the elevation of serum KL-6 and adalimumab, although the precise mechanisms by which TNF- $\alpha$  inhibitors induce serum KL-6 elevation have not been well investigated. The present case thus implies the clinical importance of monitoring serum KL-6 in patients with non-infectious uveitis being treated with adalimumab and other TNF- $\alpha$ -inhibiting biologics.

### Funding

No funding or grant support was received in association with this study.

### Authorship

All authors attest that they meet the current ICMJE criteria for

authorship.

### Patient consent

Written informed consent was obtained from the subject prior to the collection of any data.

### Declaration of competing interest

None of the authors have any financial disclosures related to this submission.

### References

- Jabs DA, Rosenbaum JT, Foster CS, et al. Guidelines for the use of immunosuppressive drugs in patients with ocular inflammatory disorders: recommendations of an expert panel. *Am J Ophthalmol.* 2000;130(4):492–513.
- Levy-Clarke G, Jabs DA, Read RW, et al. Expert panel recommendations for the use of anti-tumor necrosis factor biologic agents in patients with ocular inflammatory disorders. *Ophthalmol.* 2014;121(3):785–796 e783.
- Benitah NR, Sobrin L, Papaliodis GN. The use of biologic agents in the treatment of ocular manifestations of Behçet's disease. *Semin Ophthalmol.* 2011;26(4-5):295–303.
- Suhler EB, Adan A, Brezin AP, et al. Safety and efficacy of adalimumab in patients with noninfectious uveitis in an ongoing open-label study: visual III. *Ophthalmol.* 2018;125(7):1075–1087.
- Nguyen QD, Merrill PT, Jaffe GJ, et al. Adalimumab for prevention of uveitic flare in patients with inactive non-infectious uveitis controlled by corticosteroids (VISUAL II): a multicentre, double-masked, randomised, placebo-controlled phase 3 trial. *Lancet.* 2016;388(10050):1183–1192.
- Interlandi E, Leccese P, Olivieri I, et al. Adalimumab for treatment of severe Behçet's uveitis: a retrospective long-term follow-up study. *Clin Exp Rheumatol.* 2014;32(4 Suppl 84):S58–S62.
- Mushtaq B, Saeed T, Situnayake RD, et al. Adalimumab for sight-threatening uveitis in Behçet's disease. *Eye (Lond).* 2007;21(6):824–825.
- Yanaba K, Umezawa Y, Sakakihara R, et al. Infliximab and adalimumab, unlike ustekinumab, increase serum KL-6 levels in Japanese patients with psoriasis. *J Dermatol.* 2015;42(8):828–829.
- Nakashita T, Ando K, Kaneko N, et al. Potential risk of TNF inhibitors on the progression of interstitial lung disease in patients with rheumatoid arthritis. *BMJ Open.* 2014;4(8):e005615.
- Ishikawa N, Hattori N, Yokoyama A, et al. Utility of KL-6/MUC1 in the clinical management of interstitial lung diseases. *Respir. Investig.* 2012;50(1):3–13.
- Oguz EO, Kucuksahin O, Turgay M, et al. Association of serum KL-6 levels with interstitial lung disease in patients with connective tissue disease: a cross-sectional study. *Clin Rheumatol.* 2016;35(3):663–666.
- Fathi M, Barbasso Helmers S, Lundberg IE. KL-6: a serological biomarker for interstitial lung disease in patients with polymyositis and dermatomyositis. *J Intern Med.* 2012;271(6):589–597.
- Doishita S, Inokuma S, Asashima H, et al. Serum KL-6 level as an indicator of active or inactive interstitial pneumonitis associated with connective tissue diseases. *Intern Med.* 2011;50(23):2889–2892.
- Hayashi M, Yanaba K, Umezawa Y, et al. Impact of anti-tumor necrosis factor- $\alpha$  agents on serum levels of KL-6 and surfactant protein-D in patients with psoriasis. *J Dermatol.* 2017;44(9):1063–1066.
- Shimizu T, Ehrlich GE, Inaba G, et al. Behçet disease (Behçet syndrome). *Semin Arthritis Rheum.* 1979;8(4):223–260.
- Takamura A, Hirata S, Nagasawa H, et al. A retrospective study of serum KL-6 levels during treatment with biological disease-modifying antirheumatic drugs in rheumatoid arthritis patients: a report from the Ad Hoc Committee for Safety of Biological DMARDs of the Japan College of Rheumatology. *Mod Rheumatol.* 2013;23(2):297–303.
- Ohnishi H, Yokoyama A, Kondo K, et al. Comparative study of KL-6, surfactant protein-A, surfactant protein-D, and monocyte chemoattractant protein-1 as serum markers for interstitial lung diseases. *Am J Respir Crit Care Med.* 2002;165(3):378–381.
- Takahashi K, Nakamura H, Takenouchi K, et al. Serum KL-6 elevation and possible pulmonary involvement in patients with rheumatoid arthritis treated with biological agents. *J Nippon Med Sch.* 2014;81(6):364–371.
- Harigai M, Takamura A, Atsumi T, et al. Elevation of KL-6 serum levels in clinical trials of tumor necrosis factor inhibitors in patients with rheumatoid arthritis: a report from the Japan College of Rheumatology Ad Hoc Committee for Safety of Biological DMARDs. *Mod Rheumatol.* 2013;23(2):284–296.
- Llop SM, Papaliodis GN. Cataract surgery complications in uveitis patients: a review article. *Semin Ophthalmol.* 2018;33(1):64–69.