

Case Report

Dissecting peripheral superior cerebellar artery aneurysms: Report of two cases and review of the literature

Eric S. Nussbaum, Archie Defillo, Andrea Zelensky, Richard Stoller, Leslie Nussbaum

National Brain Aneurysm Center, St. Joseph's Hospital, St. Paul, MN, USA

E-mail: *Eric S. Nussbaum - Inussbaum@comcast.net; Archie Defillo - adefillo@healtheast.org; Andrea Zelensky - amzelensky@healtheast.org; Richard Stoller - rstoller@healtheast.org; Leslie Nussbaum - Inussbaum@comcast.net

*Corresponding author

Received: 13 April 11

Accepted: 17 May 11

Published: 28 May 11

This article may be cited as:

Nussbaum ES, Defillo A, Zelensky A, Stoller R, Nussbaum L. Dissecting peripheral superior cerebellar artery aneurysms: Report of two cases and review of the literature. *Surg Neurol Int* 2011;2:69.

Available FREE in open access from: <http://www.surgicalneurologyint.com/text.asp?2011/2/1/69/81731>

Copyright: © 2011 Nussbaum ES. This is an open-access article distributed under the terms of the Creative Commons Attribution License, which permits unrestricted use, distribution, and reproduction in any medium, provided the original author and source are credited.

Abstract

Background: Only a limited number of dissecting aneurysms of the peripheral cerebellar arteries have been previously described, and very few of these cases involve the superior cerebellar artery (SCA). Due to the rarity of these lesions, there is little consensus regarding prognosis and management. We describe our experience with two cases of complex peripheral SCA dissecting aneurysms and review the existing literature on this fascinating entity.

Case Description: Two patients, both with SCA dissecting aneurysms not amenable to endovascular treatment underwent microsurgical clipping, one with the associated removal of a tentorial meningioma. In each procedure a combined subtemporal, presigmoidal approach was performed. Surgical clips were utilized to reconstruct the aneurysms, and both patients were discharged without complication. Surgical management of complex distal SCA fusiform aneurysm is challenging and options include wrap/clip reconstruction, proximal occlusion, trapping, and distal outflow occlusion. When possible, preservation of the parent artery is preferred to mitigate the risk of brainstem infarction. If proximal occlusion or trapping are employed, we have advocated for the use of combined distal revascularization techniques to prevent permanent ischemic damage of the brainstem and cerebellar hemisphere.

Conclusions: Peripherally dissecting aneurysm of the SCA is an uncommon entity. Management of these lesions is best handled by an experienced neuro-endovascular team combined with a neurovascular surgeon skilled in skull base approaches.

Key Words: Dissecting aneurysm, distal outflow occlusion, presigmoidal approach, subtemporal approach, superior cerebellar artery

Access this article online

Website:

www.surgicalneurologyint.com

DOI:

10.4103/2152-7806.81731

Quick Response Code:

INTRODUCTION

Only a limited number of dissecting aneurysms of the peripheral cerebellar arteries have been previously described, and very few of these cases involve the superior

cerebellar artery (SCA). Due to the rarity of these lesions, there is little consensus regarding prognosis and management. We describe our experience with two cases of complex peripheral SCA dissecting aneurysms and review the existing literature on this fascinating entity.

CASE REPORTS

Case 1

A 60-year-old woman who developed intermittent diplopia underwent MRI scan revealing a tentorial meningioma as well as aneurysms of the posterior communication artery, right vertebral artery, and peripheral superior cerebellar artery. The tentorial meningioma tumor was located in the posterior aspect of the cerebellopontine angle and causing compression of the brainstem along the course of the 4th cranial nerve, and the complex, partially thrombosed dissecting aneurysm of the SCA was situated just proximal to the entry of the 4th nerve into the free edge of the tentorium. Angiography revealed a partially thrombosed wide-necked aneurysm not amenable to endovascular intervention. Microsurgical clipping and simultaneous tumor removal were recommended.

A combined subtemporal, presigmoidal approach was performed. A wide bone removal of the middle cranial fossa was necessary to reach the tentorial incisura allowing exposure of the tumor. Due to the associated brainstem compression from the tumor, the meningioma was debulked first, and then the aneurysm was addressed. Interestingly, on reaching the SCA there was obvious hemosiderin staining of the arachnoid surrounding the aneurysm dome, indicating a previous rupture. During microsurgical dissection, it was confirmed that this aneurysm was thick-walled and partially thrombosed [Figure 1a and b]. The aneurysm was reconstructed with a single clip placed well up on the aneurysm dome to avoid compromise of the parent artery. Intra-operative angiogram demonstrated complete obliteration of the aneurysm with normal flow through the SCA and distal branches. Post-operatively, apart from transient hyponatremia and hyperglycemia, the patient did well without complication.

Case 2

A 70-year-old woman with hypertension, hyperlipidemia, and a history of smoking presented with a peripheral fusiform SCA aneurysm found incidentally during a routine MRI investigation due to “black out” symptoms. The aneurysm was located 2 cm from the SCA origin, and measured 7 mm in maximal diameter [Figure 2a and b]. After a thorough discussion of treatment options, the patient elected to undergo a combined subtemporal, presigmoidal approach. On the lateral aspect of the brainstem, the aneurysm was exposed along with the parent artery and two major efferent branches. One of these branches, the largest one, was superiorly directed and a double, smaller branch, presented inferiorly around the aneurysm fundus. It was necessary during microsurgical dissection to detach the aneurysm dome from the tentorial undersurface as well as from the 4th cranial nerve. Multiple clips were used to reconstruct the aneurysm without intra-operative complication. Intra-operative angiogram confirmed reconstruction of

the fusiform aneurysm with preservation of distal flow [Figure 3a-c]. The patient tolerated the procedure well and was extubated and returned to the intensive care unit in stable condition. She was discharged home on the fourth post-operative day without new deficit.

DISCUSSION

Aneurysms of the vertebrobasilar system comprise fewer than 10% of all intracranial saccular aneurysms.^[8] Non-mycotic peripheral aneurysm formation is particularly rare. The overall incidence of peripherally located aneurysms in the anterior cerebral artery distribution is between 7% and 9%, followed by 2%-7% for the middle cerebral artery location, and only 5% for the posterior circulation.^[2,3,7,12,13] In the posterior circulation, peripherally located aneurysms have been described in the SCA, anterior inferior cerebellar artery (AICA), and posterior inferior cerebellar artery (PICA).^[3,14,15] A recent report from our center addressed the surgical management of complex dissecting PICA aneurysms using a novel technique of remote distal outflow occlusion.^[9]

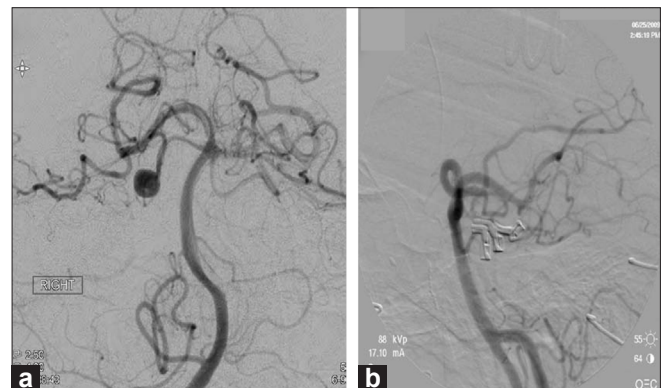


Figure 1: (a) Pre-operative and (b) intra-operative angiographic images demonstrating a dissecting, partially thrombosed aneurysm with a saccular component arising from the mid portion of the right SCA, 2 cm from its origin followed by aneurysm reconstruction with preservation of distal flow

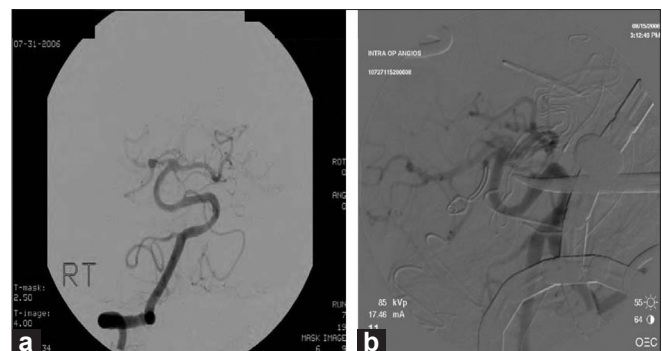

Figure 2: (a) Preoperative angiographic image demonstrating an anteriorly-directed broad-based dissecting aneurysm arising from the right SCA roughly 1.5 cm beyond the SCA origin from the basilar artery. (b) Intra-operative image confirms normal flow in the SCA with obliteration of the aneurysm

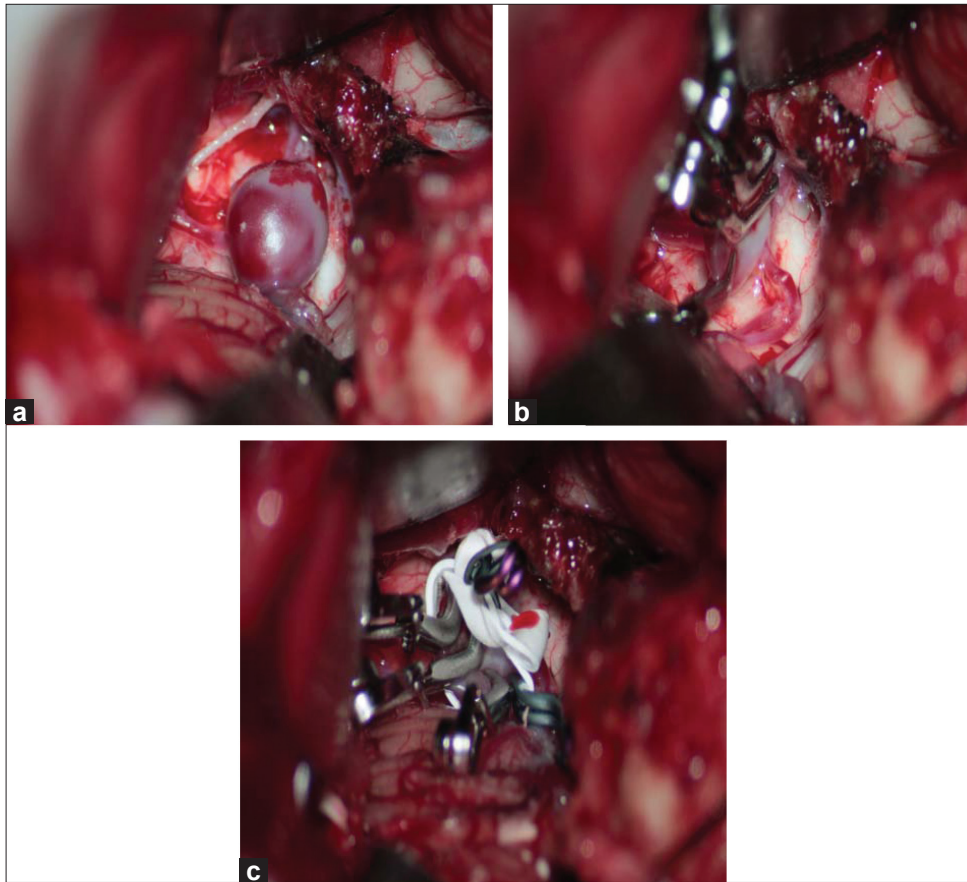


Figure 3: (a) The SCA artery, aneurysm dome, two major efferent branches, and the dissected fourth nerve running superiorly, (b) clips reconstructing the artery leaving a bulbous area at the aneurysm base to preserve flow, (c) gortex wrapping of the clipped complex

Peripheral SCA aneurysms can be either true saccular lesions or dissecting aneurysms. Saccular aneurysms of the distal SCA have been described most commonly involving the cortical or hemispheric segment at the level of the superior vermian branches.^[5] In contrast, SCA dissecting, or fusiform, aneurysms are described more commonly in the cerebellomesencephalic and pontomesencephalic arterial segments.^[1,4]

When presenting with subarachnoid hemorrhage (SAH), the diagnosis of a dissecting aneurysm of the SCA can be difficult, requiring serial angiograms to identify progressive change in the affected vascular segment. Araki *et al.*, described a case of a SCA dissecting aneurysm only revealing a slightly enlarged lesion at the anterior pontine segment on the admission angiogram. A second angiogram similarly failed to define the lesion. A third angiogram on 16th day of admission revealed a saccular aneurysm-like lesion arising at that region where the intraluminal pooling was noticed.^[1]

Surgical options for the management of dissecting SCA aneurysms include wrap/clip reconstruction, proximal occlusion, trapping, and distal outflow occlusion.^[9] When possible, preservation of the parent artery is preferred to mitigate the risk of brainstem infarction by preserving

flow through proximal perforators. When proximal occlusion or trapping are used, we have advocated for the use of combined distal revascularization techniques to prevent permanent ischemic damage of the brainstem and cerebellar hemisphere due to unpredictable collateral supply.^[9,11]

Surgical management of complex distal SCA aneurysms is challenging. These aneurysms are handled best at centers with neurovascular surgeons comfortable with complex revascularization options as well as a variety of skull base techniques including subtemporal transtentorial for aneurysms arising from the anterior and lateral pontomesencephalic segment, subtemporal or occipital transtentorial for aneurysms arising from the cerebellomesencephalic segment, and infratentorial supracerebellar for aneurysms arising from the distal or hemispheric branch of the SCA.^[6,11] In addition, these centers can offer endovascular options including coil embolization of narrow, mostly saccular aneurysms, stent-supported coil placement for wider, fusiform, necked aneurysms, and parent vessel occlusion.^[9,10]

CONCLUSION

Peripheral, dissecting aneurysm of the SCA is very

uncommon. We describe two such cases that were treated successfully with direct surgical reconstruction. Our experience supports the potential for parent vessel preservation in this setting. When vascular occlusion is contemplated, revascularization of the distal arterial territory should be considered to decrease the risk of ischemic injury.

REFERENCES

1. Araki T, Jijiwara H, Murata H, Sampei T, Taki W. Subarachnoid hemorrhage due to ruptured dissecting aneurysm of peripheral superior cerebellar artery. *No Shinkei Geka* 2002;30:1345-51.
2. Dechaume JP, Aimard G, Michel D, Bret P, Desgeorges M, Lapras C, et al. Aneurysm of the Pericallosal artery. A series of 12 cases. *Neurochirurgie* 1973;135-50.
3. Gacs G, Vinuela F, Fox AJ, Drake CG. Peripheral aneurysms of the cerebellar arteries. *J Neurosurg* 1983;58:63-8.
4. Iko M, Kazekawa K, Aikawa H, Onizuka M, Tanaka A. Case of ruptured superior cerebellar artery dissection treated by endovascular embolization. *Brain Nerve* 2007;59:72-5.
5. Itoyama Y, Uemura S, Hamada J, Man-tani A, Ushio Y. Aneurysm arising from the cortical branch of the superior cerebellar artery: Case report. *No Shinkei Geka* 1990;18:867-70.
6. Kubota S, Ohmori S, Tatara N, Nagashima C. A ruptured peripheral, superior cerebellar artery aneurysm: A case report and a review of the literature as to surgical approaches. *No Shinkei Geka* 1994;22:279-83.
7. Locksley HB. Report on the cooperative study of intracranial aneurysm and subarachnoid hemorrhage. Section V, Part I. Natural history of subarachnoid hemorrhage, intracranial aneurysms and arteriovenous malformations. Based on 6368 cases in the cooperative study. *J Neurosurg* 1966;25:219-39.
8. Matricali B, Seminara P. Aneurysm arising from the medial branch of the superior cerebellar artery. *Neurosurgery* 1986;18:350-2.
9. Nussbaum ES, Madison MT, Goddard JK, Lassig JP, Janjua TM, Nussbaum LA. Remote distal outflow occlusion: A novel treatment option for complex dissecting aneurysms of the posterior inferior cerebellar artery. Report of 3 cases. *J Neurosurg* 2009;111:78-83.
10. Nussbaum ES, Madison MT, Goddard JK, Lassig JP, Nussbaum LA. Peripheral intracranial aneurysms: Management challenges in 60 consecutive cases. *J Neurosurg* 2009;110:7-13.
11. Nussbaum ES, Madison MT, Myers ME, Goddard JK, Janjua TM. Dissecting aneurysms of the posterior inferior cerebellar artery: Retrospective evaluation of management and extended follow-up review in 6 patients. *J Neurosurg* 2008;109:23-7.
12. Pertuiset B. Aneurysm of the middle cerebral artery. In: Pia WH, Langmaid C, Zierski J, editors. *Cerebral aneurysms: Advances in diagnosis and therapy*. New York: Springer-Verlag; 1979. p. 115-6.
13. Pia HW. Aneurysm of the posterior cerebral artery. In: Pia HW, Langmaid C, Zierski J, editors. *Cerebral aneurysms: Advances in diagnosis and therapy*. New York: Springer-Verlag; 1979. p. 1123-7.
14. Pozzati E, Tognetti F, Padovani R, Gaist G. Superior cerebellar artery aneurysms. Case report. *J Neurosurg Sci* 1980;24:85-8.
15. Yoshimoto T, Kayama T, Kodama N. Distribution of intracranial aneurysms. In: Suzuki J, editor. *Cerebral aneurysms*. Tokyo: Neuron; 1979. p. 14-9.