

CASE REPORT

A case of basal cell carcinoma of the nictitating membrane in a dog

Roxanne M. Rodriguez Galarza, Stephanie M. Shrader, Jennifer W. Koehler & Eva Abarca

Department of Clinical Sciences, College of Veterinary Medicine, Auburn University, Auburn, AL, USA.

Correspondence

Eva Abarca, Vetsuisse, Bern University, Länggassstrasse 128, CH-3012 Bern, Switzerland. Tel: +41 031 631 23 15; Fax: +41 031 631 22 75; E-mail: eva.abarca@vetsuisse.unibe.ch

Funding Information

No sources of funding were declared for this study.

Received: 25 January 2016; Revised: 23 July 2016; Accepted: 18 September 2016

Clinical Case Reports 2016; **4**(12): 1161–1167

doi: 10.1002/ccr3.728

Introduction

Neoplasia of the conjunctiva, as well as of the nictitating membrane (NM), is uncommon in the dog; however, the following neoplasms have been reported: melanomas, melanocytoma, adenocarcinomas, squamous cell carcinomas, mast cell tumors, papillomas, hemangiomas, hemangiosarcomas, lymphomas, myoepitheliomas extramedullary plasmacytomas, canine transmissible venereal tumors, malignant peripheral nerve sheath tumors, and basal cell carcinoma [1–16]. A recent retrospective paper studying 127 dogs with tumors of the NM showed that the most common tumor was adenocarcinoma (85%) followed by adenoma of the NM gland (14.2%) and squamous cell carcinoma (0.8%) [15].

Basal cell tumors (BCT) represent a heterogeneous group of epithelial neoplasms that arise without squamous and adnexal differentiation [17]. BCTs are the most common type of skin tumor in the cat and are less common in the dog [18–22]. Basal cell carcinoma (BCC) in dogs, cats, and people is currently defined as a low-grade neoplasm arising from the basal cells of either the inter-follicular epidermis or the hair follicles and may represent a neoplastic transformation of stem cells [23–26]. Primary

Key Clinical Message

A case of a basal cell carcinoma (BCC) of the nictitating membrane (NM) in a 9-year-old female spayed dachshund is reported. Computed tomography and resection of the NM followed by cryosurgery was performed. Although uncommon, BCC should be considered as a differential diagnosis for tumors of the NM.

Keywords

Canine, dog, eye, third eyelid, tumor.

BCC of mucous membranes is extremely rare [27]. In people, very few reports exist of primary BCC of the conjunctiva or caruncle [28–35]. Basal cell carcinoma arising from the NM is an uncommon finding in veterinary medicine, and there is a paucity of reports documenting BCC in the NM, including a BCT of the NM in a horse [36]. A recent report presented histopathological and immunohistochemical features of atypical epithelial tumors of the canine NM including two cases of basal cell adenocarcinomas [14]. This case report provides a detailed description of the clinical, imaging, histological, and immunohistochemical characteristics of a basal cell carcinoma from the NM in a dog.

Case Report

History and signalment

A 9-year-old female, spayed, long-haired Dachshund was referred to the Ophthalmology Service at Auburn University College of Veterinary Medicine (AUCVM) following a 2- to 3-week history of bilateral mydriasis and ocular discharge from the right eye (OD). The dog had been treated with neomycin/polymyxin/dexamethasone ophthalmic

ointment (q8 hr; Alcon Laboratories, Ft Worth, TX, USA) for 1 week with a partial positive response.

Ophthalmic examination

A complete ophthalmic examination was performed on both eyes (OU). Moderate blepharospasm and mild mucoid discharge were detected OD. Vision was normal OU (with normal menace and dazzle responses). Pupillary light reflexes (direct and indirect) were present but markedly decreased in both eyes due to severe iris atrophy. Tear production, as determined by tear test (Schirmer Tear Test Strips; Schering-Plough Animal Health, Kenilworth, NJ, USA), was 16 mm/min OD and 20 mm/min OS. Diffuse illumination of the adnexa revealed no abnormalities OS, while severe chemosis and inflammation of the palpebral conjunctiva and NM were noted OD. Retraction of the right NM revealed an irregular, pink, multilobulated mass affecting the bulbar, and medial aspect of the NM (Fig. 1A). At that time, it was difficult to determine whether the mass infiltrated the ventral orbit.

Slit-lamp biomicroscopy (Kowa SL-14, Kowa Company, Ltd., Tokyo, Japan) was used for the examination of the anterior segment. The cornea and anterior chamber OU were grossly unremarkable. Fluorescein test (Akorn Inc., Buffalo Grove, IL, USA) was negative OU. There was nuclear sclerosis and severe iris atrophy in both eyes. One drop of proparacaine 0.5% solution (Bausch & Lomb Pharmaceuticals Inc., Tampa, FL, USA) was applied to each eye. Intraocular pressures, obtained with applanation tonometry (Tonopen XL; Reichert Technologies, Depew, NY, USA), were 9 mmHg OD and 11 mmHg OS. The posterior segment and funduscopy were normal in both eyes.

Although palpation of mandibular lymph nodes was normal, a fine needle aspirate from the right mandibular lymph node was performed; the lymph node was

considered to be mildly reactive via cytologic evaluation. No abnormalities were noted on the rest of the physical examination. An incisional biopsy of the right NM mass was also performed following application of one drop of proparacaine 0.5% solution (Bausch & Lomb Pharmaceuticals Inc., Tampa, FL, USA). The biopsy was obtained using Westcott tenotomy scissors and was subsequently fixed in 10% neutral-buffered formalin (NBF).

The patient was discharged with neomycin/polymyxin/bacitracin ophthalmic ointment (Akron, Inc., Lake Forest, IL, USA) to be applied OD every 8 h until histopathology results were received.

Histopathology from incisional biopsy

Incisional biopsy sections were of an unencapsulated, well-demarcated, multilobular neoplastic mass composed of basal cells seated within a moderately dense fibrovascular stroma. Based on the cellular morphology, the neoplasm was diagnosed as a presumptive basal cell tumor. Due to the lack of natural borders and the size of the tissue fragments, it was difficult to determine whether the neoplasm represented a benign process such as a meibomian epithelioma or a malignant process, such as a basal cell carcinoma. There was no evidence of sebaceous or squamous differentiation in the examined sections.

Anesthesia, imaging, and surgery

Based on the histopathologic diagnosis and potential neoplastic invasion of the orbit and globe, a computed tomography (CT) was performed. The patient was sedated with dexmedetomidine (10 µg/kg IM; Dexdomitor[®], Zoetis, Florham Park, NJ, USA) and hydromorphone (0.1 mg/kg IM; West Ward, Eatontown, NJ, USA).

Transverse CT images of the head were obtained pre- and postcontrast with 5.0-mm slices in bone and soft algorithms. Dorsal images were obtained postcontrast

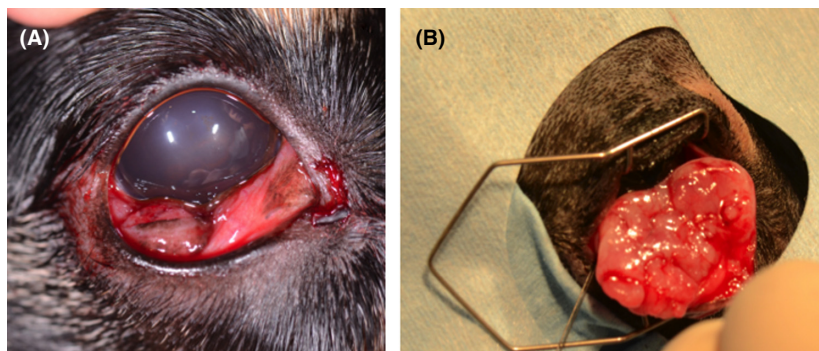


Figure 1. (A) Image of the right eye at presentation. Note conjunctival hyperemia and irregular mass behind nictitating membrane. (B) Lateral canthotomy allowing for exposure of NM and entirety of mass.

with 3.0-mm slices and 1.0-mm slices through the region of interest. CT imaging showed a relatively well-defined, soft tissue attenuating, contrast enhancing, $1.1 \times 2.0 \times 1.6$ cm ovoid mass in the cranioventral aspect of the right orbit causing mild caudolateral displacement of the globe (Fig. 2A and B). Invasion of orbital structures was not observed. The retropharyngeal and mandibular lymph nodes were within normal limits.

Based on the CT results, the decision was made to perform resection of the NM. Anesthetic induction was achieved with propofol (4 mg/kg IV; Propoflo, Abbott Animal Health, North Chicago, IL, USA) to effect. General anesthesia was maintained after endotracheal intubation with inhalant isoflurane 1–2% in oxygen (Isoflo; Abbott Animal Health, North Chicago, IL, USA). After surgical preparation of the ocular surface and adnexa, a lateral canthotomy was performed to visualize and expose the tumor (Fig. 1B). After exposing the tumor, the entire NM and visible mass were resected followed by the application of cryotherapy via a double freeze thaw method, as an adjunctive therapy. The canthotomy incision was then closed in two layers using 6-0 polyglactin 910 (Vicryl, Ethicon; Johnson and Johnson, New Brunswick, NJ, USA) and 5-0 nylon (Ethilon, Ethicon; Johnson and Johnson, New Brunswick, NJ, USA).

The eye was treated postsurgically with neomycin/polymyxin/bacitracin OD q6 hr, diclofenac sodium 0.1% OD q8 hr (Pack Pharmaceuticals, LLC, Buffalo Grove, IL, USA), lubrication OD q6 hr (Lubrifresh PM; Major Pharmaceuticals, MI, USA), oral carprofen (2.2 mg/kg PO q12 hr for 10 days, Rimadyl tablets; Zoetis, Florham Park, NJ, USA), and cephalexin (30 mg/kg PO q12 hr for 10 days, Cephalexin Capsules, Teva Pharmaceuticals USA, Sellersville, PA, USA).

The mass and associated NM were fixed in 10% NBF and submitted for histopathologic evaluation.

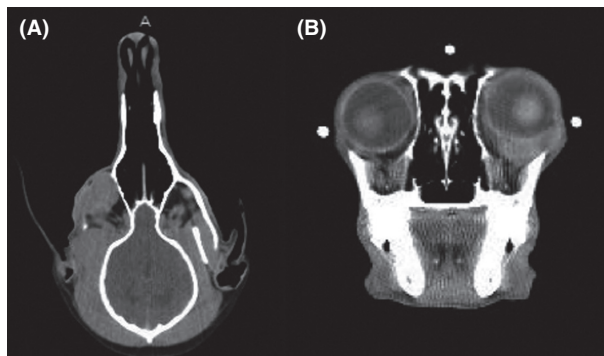


Figure 2. (A, B) Dorsal and transverse CT images of the skull. Note well-defined, soft tissue attenuating $1 \times 2 \times 1.6$ cm ovoid mass causing caudodorsal displacement of globe.

Final histopathology

The NM with a $2.4 \times 1.5 \times 1.4$ cm multilobulated, well-demarcated mass was received for histopathologic evaluation. On cut section, the mass was pale-tan and firm with foci of hemorrhage. Sections were composed of an unencapsulated, well-demarcated, multilobular, densely cellular neoplastic mass that markedly expanded and effaced the submucosa (Fig. 3). The mass was composed of sheets, lobules, and trabeculae of peripheral basal cells seated within a moderately dense fibrovascular stroma, as

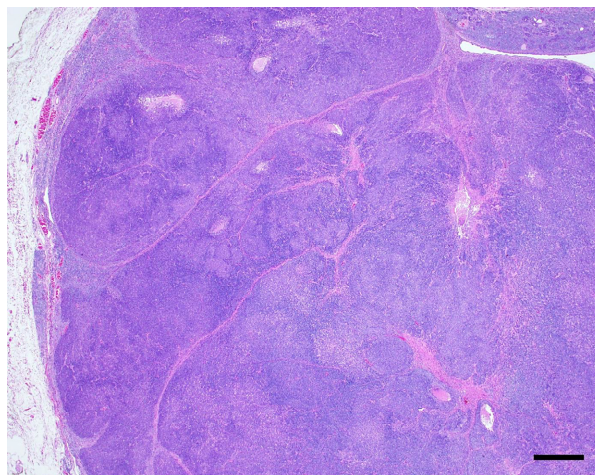


Figure 3. Photomicrograph showing the subgross morphology of the tumor. This is an unencapsulated, well-demarcated, multilobular, densely cellular neoplastic mass that markedly expands and effaces the submucosa. H&E. Bar = 500- μ m.

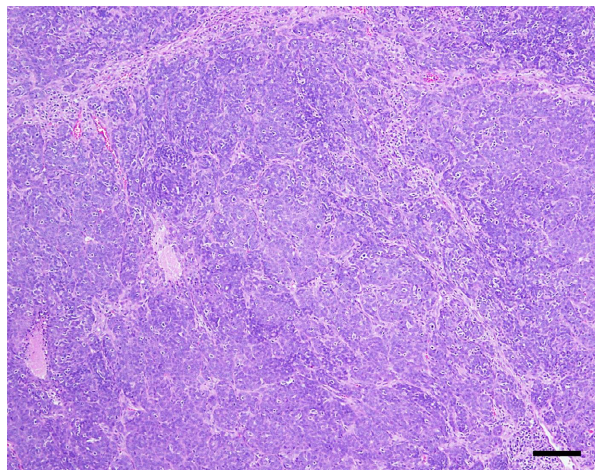


Figure 4. Photomicrograph showing cellular organization within the tumor. The neoplastic basal cells are arranged in sheets, lobules, and trabeculae within a moderately dense fibrovascular stroma, H&E. Bar = 100- μ m.

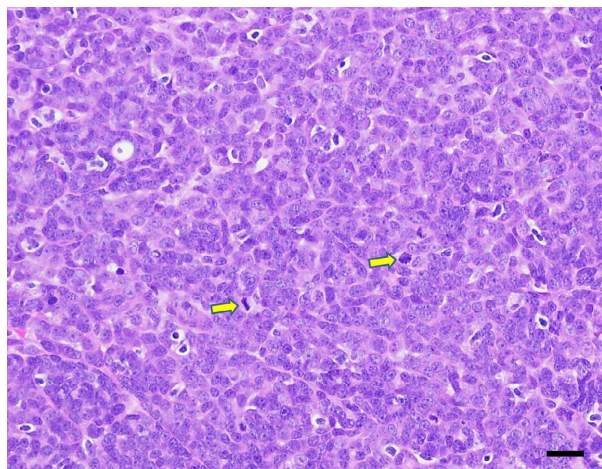


Figure 5. Photomicrograph showing cellular morphology. In general, the neoplastic cells have scant amounts of eosinophilic cytoplasm, ill-defined cytoplasmic borders, round to ovoid euchromatic nuclei, and typically a single small basophilic nucleolus. There is mild to moderate anisocytosis and anisokaryosis with frequent mitoses (arrows). H&E. Bar = 20- μ m.

observed in the previous incisional biopsy (Fig. 4). The majority of the neoplastic cells had scant amounts of eosinophilic cytoplasm, ill-defined cytoplasmic borders, round to ovoid euchromatic nuclei, and typically a single small basophilic nucleolus (Fig. 5). Multifocally, clusters of neoplastic cells had moderate amounts of pale-eosinophilic, finely granular or wispy cytoplasm, poorly delineated cellular borders, ovoid or elongate nuclei, stippled chromatin, and a single prominent magenta nucleolus. Anisocytosis and anisokaryosis were mild to moderate. There were 25 mitotic figures in ten consecutive 400x fields with occasional bizarre mitoses. Lymphoplasmacytic aggregates and variably sized foci of hemorrhage and necrosis were present throughout the mass with numerous infiltrating foamy macrophages, often laden with hemosiderin or cellular debris. Individual necrotic and apoptotic cells were frequently observed. Along the periphery of the mass, immediately adjacent to the NM cartilage, was islands of basal cells that had a similar tinctorial quality as those cells described in the mass; however, these basal cells were occasionally arranged around ductules (presumed nictitans gland ductules). The neoplastic cells had strong, diffuse cytoplasmic immunolabeling for pan-cytokeratin (AE1/AE3; 1 in 50 dilution; Dako[®], Carpinteria, CA), weak to moderate, often non-specific immunolabeling for SMA (1 in 50 dilution; Dako[®], Carpinteria, CA), and minimal, finely granular cytoplasmic immunolabeling for Pax-5 (1 in 15 dilution; Dako[®], Carpinteria, CA); the cells lacked immunolabeling for Ber-EP4 (1 in 200 dilution; Dako[®], Carpinteria, CA)

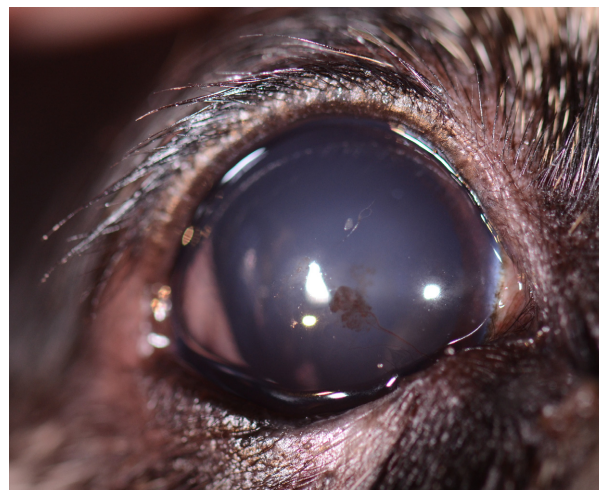

Figure 6. Image of the right eye 20 months following presentation. Note lack of NM, slight nasal entropion and superficial nasal corneal neovascularization and pigmentation.

and cytokeratin-18 (CK-18; 1 in 100 dilution; Abcam[®], Cambridge, MA).

Outcome

The patient presented for evaluation 20 months after surgery with no reported ocular disease or use of topical medications (Fig. 6). A complete ophthalmic examination was performed OU. Examination of the adnexa OD revealed mild nasal entropion and absence of the NM. Tear production, as determined by tear test (Schirmer Tear Test Strips; Schering-Plough Animal Health, Kenilworth, NJ, USA), was 22 mm/min OD and 19 mm/min OS. Biomicroscopy (Kowa SL-14, Kowa Company, Ltd., Tokyo, Japan) of the anterior segment showed minimal superficial corneal neovascularization in the nasal quadrant OD, with negative fluorescein test (Akorn Inc., Buffalo Grove, IL, USA) OU. Tear breakup time was 12 sec OD and 10 sec OS. Intraocular pressures, obtained with rebound tonometry (TonoVet[®] Icare Finland Oy, Helsinki, Finland), were 12 mmHg OD and 13 mmHg OS. The posterior segment and funduscopy were normal in both eyes. The periorbital rim, mandibular lymph nodes, and global retropulsion were normal with no evidence of local recurrence 20 months after surgical excision.

Discussion

This case report describes the clinical, imaging, histological, and immunohistochemical characteristics of a BCC of the NM in a dog. Primary BCC of mucous membranes is extremely rare and often arise in areas of long-term sun

exposure [27]. In humans, very few reports exist of primary BCC of the conjunctiva or caruncle [28–35]. In the veterinary literature, there was only one report of a basal cell tumor involving the third eyelid of a horse [36]. More recently, a retrospective case report evaluated the histopathologic and immunohistochemical features of atypical epithelial tumors of NM in seven dogs where two of the cases were diagnosed as basal cell adenocarcinoma [14]. History, clinical findings, and follow-up were not available for any of the cases.

Basal cell carcinomas (BCCs) occasionally may be difficult to distinguish from squamous cell carcinomas (SCCs) that have large areas of basaloid differentiation. Although they are typically readily classified on the basis of H&E morphology, in human medicine, there are several immunolabels that can be used to differentiate BCCs and SCCs [37]. Epithelial membrane antigen (EMA) is a large cell surface mucin glycoprotein expressed by most glandular and ductal epithelial cells and some hematopoietic cells. BCCs tend to be negative for EMA, in contrast to SCCs that have substantial EMA immunoreactivity. Ber-EP4 is a monoclonal antibody that reliably labels epithelial tissues but does not react with mesothelial cells [38]. Additionally, human BCCs are typically positive for this marker, unlike SCCs. Smooth muscle actin (SMA) is a monoclonal antibody that is intended for laboratory use in the qualitative identification of smooth muscle actin protein. SMA is documented to be expressed in a significant number of human cutaneous BCTs; SCCs are generally negative for SMA. B-cell lymphoma 2 (BCL-2) is another commonly used immunolabel in human pathology that can help differentiate BCCs and SCCs. With this marker, BCCs are typically diffusely positive while SCCs generally lack immunoreactivity; however, focal positivity has been reported [39]. In the present case, SMA and Ber-EP4 immunolabels were utilized; however, results were ambiguous, just as the immunolabels used in the two previously reported by Miyazaki *et al.* [14]. The neoplasm was positive for SMA (expected with BCC) but negative for Ber-EP4 (also expected to be positive in BCC). Enigmatic SMA and Ber-EP4 immunolabeling in this neoplasm may reflect a lack of appropriate cross-reactivity in canine tissues or differences in protein expression patterns between canine and human BCCs and SCCs. Although immunolabeling in this case was inconclusive, the morphologic characteristics of this neoplasm support the final diagnosis of basal cell carcinoma.

As previously described, primary BCC of the ocular surface (including conjunctiva, NM, and caruncle) is extremely rare in both human and veterinary ophthalmology [14, 34, 36]. In humans, the main therapeutic approach for primary BCC of the caruncle is complete excision with tumor-free surgical margins. Adjuvant

therapy such as cryotherapy, radiotherapy, or chemotherapy may be administered when deemed necessary, as in patients with inadequate surgical margins, local recurrence, or those that had orbital invasion [35]. In the current case, no signs of orbital invasion were noted on the CT examination. Therefore, surgical excision of the NM followed by cryotherapy was planned.

Prognosis for humans with primary BCC or the conjunctiva or caruncle is generally good, although in some cases, an unfavorable course is observed. Aggressiveness is related mainly to local recurrence and invasion of the orbit [34, 35]. Because long-term follow-up of veterinary patients with BCC has not been documented, biologic behavior of these tumors is unknown [14, 36]. In the present case, no signs of local recurrence were observed twenty months after surgery. However, in human ophthalmology, recurrences have been described even years after complete excision, making long-term follow-up mandatory [28, 34, 40].

In dogs, the NM gland produces 30–57% of the tear film [41–43]. Removal of NM has been associated with changes in the tear film pH, breakup time, and keratoconjunctival epithelium, as well as excessive exposure of the ocular surface and secondary entropion with trichiasis [44–46]. Close monitoring of the ocular surface should be considered important during follow-up after NM removal. In the present case, examination of the patient revealed normal tear production and tear breakup time. However, the patient developed slight medial entropion and trichiasis that resulted in mild corneal neovascularization. Because of this, lubrication was recommended (Gen-teal[®] Novartis, East Hanover, NJ).

To the authors' knowledge, although previously reported, this is the first detailed report of a BCC involving the NM of a dog that includes clinical presentation, advanced imaging, diagnosis, treatment, and outcome. Although uncommon, basal cell carcinoma should be considered as a differential diagnosis for tumors of the NM. These cases should be monitored long-term for complications associated with removal of the NM as well as recurrence of BCC.

Conflict of Interest

None declared.

Authorship

RR: collected data, was involved in patient care and wrote manuscript. SMS and JWK: performed the histological examination, and was a major contributor in writing the manuscript. EA: was involved in drafting the manuscript, were a major contributor in writing and revising

it critically. All authors read and approved the final manuscript.

References

- Collins, B. K., L. L. Collier, and M. A. Miller. 1993. Biologic behavior and histologic characteristics of canine conjunctival melanoma. *Prog. Vet. Comp. Ophthalmol.* 3:135–140.
- Collier, L. L., and B. K. Collins. 1994. Excision and cryosurgical ablation of severe periocular papillomatosis in a dog. *J. Am. Vet. Med. Assoc.* 204:881–883. discussion 4–5.
- Buyukmihci, N., and A. A. Stannard. 1981. Canine conjunctival angiokeratomas. *J. Am. Vet. Med. Assoc.* 178:1279–1282.
- Hallstrom, M. 1970. Mastocytoma in the third eyelid of a dog. *J. Small Anim. Pract.* 11:469–472.
- Lavach, J. D., and S. P. Snyder. 1984. Squamous cell carcinoma of the third eyelid in a dog. *J. Am. Vet. Med. Assoc.* 184:975–976.
- Liapis, I. K., and L. Genovese. 2004. Hemangiosarcoma of the third eyelid in a dog. *Vet. Ophthalmol.* 7:279–282.
- Peiffer, R. L. Jr, J. Duncan, and T. Terrell. 1978. Hemangioma of the nictitating membrane in a dog. *J. Am. Vet. Med. Assoc.* 172:832–833.
- Wilcock, B., and R. Jr Peiffer. 1988. Adenocarcinoma of the gland of the third eyelid in seven dogs. *J. Am. Vet. Med. Assoc.* 193:1549–1550.
- Saunders, L. Z., and L. F. Rubin. 1975. *Ophthalmic pathology of animals: an atlas and reference book.* Karger, Basel, Germany.
- Johnson, B. W., A. H. Brightman, and H. E. Whitely. 1988. Conjunctival mast cell tumor in two dogs. *J. Am. Anim. Hosp. Assoc.* 24:439–442.
- Wiggans, K. T., K. A. Skorupski, C. M. Reilly, S. A. Frazier, R. R. Dubielzig, and D. J. Maggs. 2014. Presumed solitary intraocular or conjunctival lymphoma in dogs and cats: 9 cases (1985–2013). *J. Am. Vet. Med. Assoc.* 244:460–470.
- Milo, J., and E. Snead. 2014. A case of ocular canine transmissible venereal tumor. *Can. Vet. J.* 55:1245–1249.
- Vom Hagen, F., G. Romkes, O. Kershaw, and J. C. Eule. 2015. Malignant peripheral nerve sheath tumor of the third eyelid in a 3-year-old Rhodesian Ridgeback. *Clin. Case Rep.* 3:50–56.
- Miyazaki, A., K. Yonemaru, A. Hirata, T. Yanai, and H. Sakai. 2015. Histopathological and immunohistochemical features of atypical epithelial tumours of the gland of the third eyelid in seven dogs. *J. Comp. Pathol.* 152:299–303.
- Dees, D. D., C. S. Schobert, R. R. Dubielzig, and T. J. Stein. 2015. Third eyelid gland neoplasms of dogs and cats: a retrospective histopathologic study of 145 cases. *Vet. Ophthalmol.* 19:138–143.
- Bondoc, A., T. Izawa, S. Hirata, T. Hasegawa, M. Kuwamura, H. Golbar, *et al.* 2014. Myoepithelioma of the gland of the third eyelid in a dog. *J. Comp. Pathol.* 151:186–189.
- Simeonov, R. S. 2010. The author responds. *Vet. Clin. Pathol.* 39:133–134.
- Bostock, D. E. 1986. Neoplasms of the skin and subcutaneous tissues in dogs and cats. *Br. Vet. J.* 142:1–19.
- Miller, M. A., S. L. Nelson, J. R. Turk, L. W. Pace, T. P. Brown, D. P. Shaw, *et al.* 1991. Cutaneous neoplasia in 340 cats. *Vet. Pathol.* 28:389–395.
- Carpenter, J., L. Andrews, and J. Holzworth 1987. Tumors and tumor-like lesions. Pp. 406 *in* Jean Holzworth, ed. *Diseases of the cat: medicine and surgery.* WB Saunders: Philadelphia.
- Rothwell, T. L., C. R. Howlett, D. J. Middleton, D. A. Griffiths, and B. C. Duff. 1987. Skin neoplasms of dogs in Sydney. *Aust. Vet. J.* 64:161–164.
- Finnie, J. W., and D. E. Bostock. 1979. Skin neoplasia in dogs. *Aust. Vet. J.* 55:602–604.
- Yamamoto, O., and M. Asahi. 1999. Cytokeratin expression in trichoblastic fibroma (small nodular type trichoblastoma), trichoepithelioma and basal cell carcinoma. *Br. J. Dermatol.* 140:8–16.
- Kurzen, H., L. Esposito, L. Langbein, and W. Hartschuh. 2001. Cytokeratins as markers of follicular differentiation: an immunohistochemical study of trichoblastoma and basal cell carcinoma. *Am. J. Dermatopathol.* 23:501–509.
- Carucci, J., and D. Leffell. 2008. *Basal cell carcinoma, 7th ed.* McGraw-Hill, New York, USA.
- Epidermal Tumors. 2008. *Skin diseases of the dog and cat.* Blackwell Science Ltd; Ames, Iowa, USA. Pp. 559–603.
- Margo, C. E., and K. Waltz. 1993. Basal cell carcinoma of the eyelid and periocular skin. *Surv. Ophthalmol.* 38:169–192.
- Ostergaard, J., J. Boberg-Ans, J. U. Prause, and S. Heegaard. 2005. Primary basal cell carcinoma of the caruncle with seeding to the conjunctiva. *Graefes Arch. Clin. Exp. Ophthalmol.* 243:615–618.
- Meier, P., I. Sterker, and T. Meier. 1998. Primary basal cell carcinoma of the caruncle. *Arch. Ophthalmol.* 116:1373–1374.
- Apte, P. V., V. H. Talib, and S. D. Patil. 1975. Basal cell carcinoma of conjunctiva. *Indian J. Ophthalmol.* 23:33–34.
- Aftab, M., and S. P. Percival. 1973. Basal cell carcinoma of the conjunctiva. *Br. J. Ophthalmol.* 57:836–837.
- Husain, S. E., J. R. Patrinely, L. E. Zimmerman, and R. L. Font. 1993. Primary basal cell carcinoma of the limbal conjunctiva. *Ophthalmology* 100:1720–1722.
- Cable, M. M., D. B. Lyon, M. Rupani, C. S. Matta, and A. A. Hidayat. 2000. Case reports and small case series: primary basal cell carcinoma of the conjunctiva with intraocular invasion. *Arch. Ophthalmol.* 118:1296–1298.
- Fino, P., M. G. Onesti, P. Fioramonti, A. Romanzi, and N. Scuderi. 2013. First reported case of primary basal cell carcinoma of the right caruncle: a case report and review of the literature. *In vivo* 27:535–539.

35. Ugurlu, S., M. A. Ekin, and A. A. Altinboga. 2014. Primary basal cell carcinoma of the caruncle: case report and review of the literature. *Ophthalmic .Plast. Reconstr. Surg.* 30:e62–e64.
36. Baril, C. 1973. Basal cell tumour of third eyelid in a horse. *Can. Vet. J.* 14:66–67.
37. Miller, R. T. 2004. Immunohistochemistry in the differential diagnosis of cutaneous basal cell carcinoma and squamous cell Carcinoma. ProPath. Dallas, Texas, USA.
38. Ordonez, N. G. 1998. Value of the Ber-EP4 antibody in differentiating epithelial pleural mesothelioma from adenocarcinoma. The M.D. Anderson experience and a critical review of the literature. *Am. J. Clin. Pathol.* 109:85–89.
39. Torlakovic, E., A. Slipicevic, C. Robinson, J. F. DeCoteau, G. C. Alfsen, M. Vyberg, et al. 2006. Pax-5 expression in nonhematopoietic tissues. *Am. J. Clin. Pathol.* 126:798–804.
40. Lee, C. L., S. L. Hsu, and C. H. Chang. 2010. Primary ocular caruncular basal cell carcinoma in a Chinese patient. *Kaohsiung J. Med. Sci.* 26:562–566.
41. Moore, C., B. Frappier, and L. Linton. 1996. Distribution and course of ducts of the canine third eyelid gland: effects of two surgical replacement techniques. *Veterinary and Comparative Ophthalmology, USA.*
42. Helper, L. 1970. The effect of lacrimal gland removal on the conjunctiva and cornea of the dog. *J. Am. Vet. Med. Assoc.* 157:72–75.
43. Kaswan, R., and C. Martin. 1985. Surgical correction of third eyelid prolapse in dogs. *J. Am. Vet. Med. Assoc.* 186:183.
44. Saito, A., Y. Watanabe, and T. Kotani. 2004. Morphologic changes of the anterior corneal epithelium caused by third eyelid removal in dogs. *Vet. Ophthalmol.* 7:113–119.
45. Saito, A., Y. Izumisawa, K. Yamashita, and T. Kotani. 2001. The effect of third eyelid gland removal on the ocular surface of dogs. *Vet. Ophthalmol.* 4:13–18.
46. Barnett, K. 1978. Diseases of the nictitating membrane of the dog. *J. Small Anim. Pract.* 19:101–108.