

Effective assessment of low times MET amplification in pleural effusion after epidermal growth factor receptor-tyrosine kinase inhibitors (EGFR-TKIs) acquired resistance

Cases report

Chang-guo Wang, MM, Da-xiong Zeng, MD, Jian-an Huang, MD, Jun-hong Jiang, MD*

Abstract

Rationale: The mechanism of the first-generation epidermal growth factor receptor-tyrosine kinase inhibitors (EGFR-TKIs) acquired resistance included T790M mutation, cellular-mesenchymal to epithelial transition factor (MET) or EGFR amplification, PIK3CA mutation, and transformation to small cell lung cancer. MET amplification accounted for only about 5% of the resistance cases.

Patients concerns: Few report detected MET amplification in pleural effusion. Here, we reported 2 lung adenocarcinoma cases with MET amplification in pleural effusion rapidly responded to crizotinib after EGFR-TKIs acquired resistance.

Diagnoses: Biopsy via bronchoscopy, next-generation sequencing (NGS) in pleural effusion.

Interventions: EGFR-TKIs (Icotinib), MET inhibitor crizotinib.

Outcomes: After a progression-free survival of 9 months and 23months, respectively, both cases progressed accompanying with pleural effusion. Results of NGS in pleural effusion showed MET amplification (2–3 times) in both cases. The 2 patients were treated with a MET inhibitor crizotinib and rapidly responded.

Conclusion: MET amplification in pleural effusion could predict a perfect response to crizotinib after EGFR-TKIs acquired resistance, even only a low times gene amplification.

Abbreviations: EGFR = epidermal growth factor receptor, NGS = next-generation sequencing, TKIs = tyrosine kinase inhibitors.

Keywords: acquired resistance, EGFR-TKIs, lung cancer, cellular-mesenchymal to epithelial transition factor amplification, pleural effusion

1. Introduction

Development of molecular therapeutics brought benefits to lung cancer patients with driver mutations. To date, epidermal growth factor receptor (EGFR) tyrosine kinase inhibitors (TKIs) has

become first-line choice for treatment of lung adenocarcinoma harboring TKIs sensitive EGFR mutation.^[1] However, majority of these patients inevitably experienced acquired resistance in <1 year.^[2] The mechanism of the first-generation EGFR-TKIs acquired resistance included T790M mutation, cellular-mesenchymal to epithelial transition factor (MET) or EGFR amplification, etc.^[3] So, rebiopsy might be a better choice before subsequent treatment in patients with EGFR-TKIs acquired resistance.

Pleural effusion occurred in 7% to 15% lung cancer patients. For advanced stage patients, pleural effusion could be obtained repeatedly and less invasively compared with rebiopsy.^[4–6] Here, we reported 2 lung adenocarcinoma cases with MET amplification in pleural effusion rapidly responded to crizotinib after EGFR-TKIs acquired resistance. This study was approved by the research ethics committee of the First Affiliated Hospital of Soochow University. Informed consent was obtained from each patient. Tumor responses were evaluated every 2 months according to the Response Evaluation Criteria in Solid Tumors (RECIST 1.1) using chest imaging (computed tomography [CT] scan). As described in RECIST 1.1, objective tumor responses included complete response (CR), partial response (PR), stable disease (SD), and progressive disease (PD).

2. Case presentation

2.1. Case 1

A 73-year-old man with no smoking history presented with cough for 1 year was admitted in our department. Imaging studies

Editor: Prashant Thakkar.

CW and DZ have contributed equally to this study.

This study was supported by Jiangsu Province Special Program of Medical Science (BE 2016672), Program of Key Talents of Medical Science in Jiangsu Province (QNRC2016745), Suzhou Municipal Application Basic Research Project (SYS201530), the Clinical Key Speciality Project of China, the Clinical Medicine Center of Suzhou (No. SZZX201502), Suzhou Key Laboratory for Respiratory Medicine (No. SZS201617).

The authors report no conflicts of interest.

Department of Respiratory and Critical Care, First Affiliated Hospital of Soochow University, Suzhou, P.R. China.

* Correspondence: Jun-hong Jiang, Department of Respiratory Medicine, the First Affiliated Hospital of Soochow University, Suzhou, 215006, P.R. China (e-mail: jiang20001969@163.com).

Copyright © 2018 the Author(s). Published by Wolters Kluwer Health, Inc. This is an open access article distributed under the terms of the Creative Commons Attribution-Non Commercial License 4.0 (CCBY-NC), where it is permissible to download, share, remix, transform, and buildup the work provided it is properly cited. The work cannot be used commercially without permission from the journal.

Medicine (2018) 97:1(e9021)

Received: 7 April 2017 / Received in final form: 9 November 2017 / Accepted: 10 November 2017

<http://dx.doi.org/10.1097/MD.0000000000009021>

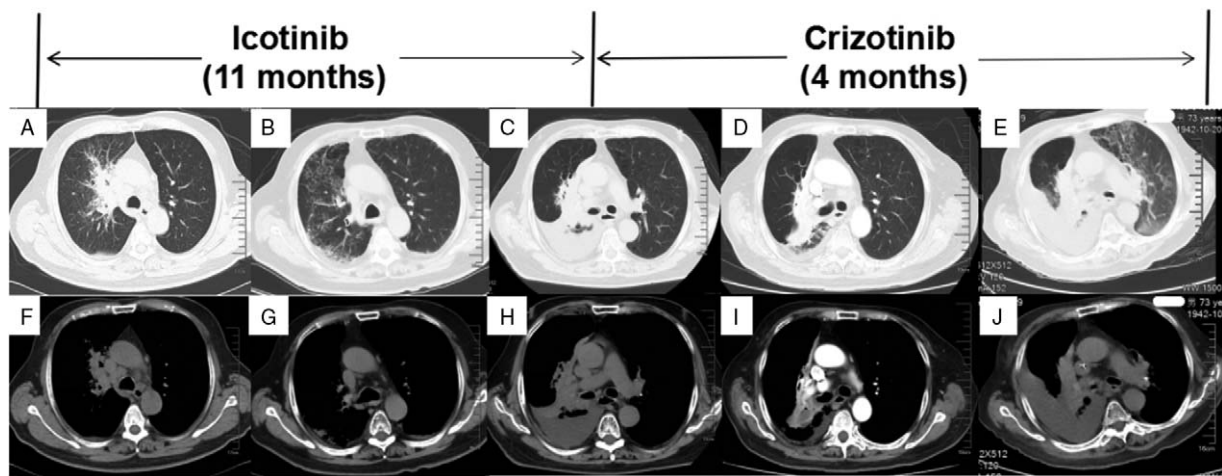

Figure 1. CT scan of lung windows and mediastinal windows in case 1 after Icotinib treatment and after Crizotinib treatment. CT=computed tomography.

showed a mass in the right upper lung with mediastinal lymph nodes enlargement (Fig. 1A and F). Bronchoscopy showed a neoplasm in the right upper lobe of lung and the biopsy demonstrated lung adenocarcinoma (micropapillary pattern). Further examinations, including head magnetic resonance imaging (MRI) and bone emission computed tomography (ECT) were normal. Then the patient was diagnosed as lung adenocarcinoma (IIIB stage). Performance status score is 3. The EGFR mutation test was performed and the exon 19 deletion was detected (67%). So, the patient was started on EGFR-TKIs (Icotinib, 125 mg, tid, orally). Although an initial clinical benefit was observed, symptoms did rapidly worsen 11 months later. A CT scan showed a progressive lung mass with pleural effusion (Fig. 1C and H). So, the next-generation sequencing (NGS) of pleural effusion was performed and only MET gene amplification (2 times) was detected. Based on the presence of the MET amplification, crizotinib (a potent competitive MET inhibitor, 250mg bid, orally) was initiated. Then the symptoms of the patient were improved. Moreover, CT scan performed at 2 months after crizotinib treatment showed that the mass and pleural effusion reduced significantly (Fig. 1D and I). However, the patient showed progressive disease after 4 months.

The CT scan showed enlargement of mass and the increasing of pleural effusion (Fig. 1E and K).

2.2. Case 2

A 50-year-old never-smoker woman, experiencing cough and dyspnea for 2 years, underwent a CT scan, which showed a mass in the left lung (Fig. 2A and F). Bone ECT showed multiple bone lesions. Bronchoscopy showed a neoplasm in the left upper lobe of lung and the biopsy demonstrated lung adenocarcinoma (lepidic pattern). So the patient was diagnosed as lung adenocarcinoma (IV stage), and received 4 cycle chemotherapy (Pemetrexed+Carboplatin). But the disease progressed after chemical therapy. Then the EGFR mutation was detected in previous biopsy tissue and result showed exon 19 deletion (76%). So, the patient received EGFR-TKI (Icotinib 125 mg, tid, orally) treatment. After a 23-month (progression free survival) PFS, disease progressed with enlarged mass in the left lung accompanying with increased pleural and pericardial effusion (Fig. 2C and H). Then the NGS (pleural effusion) assay was performed and the MET gene amplification (3 times) was detected. Based on these,

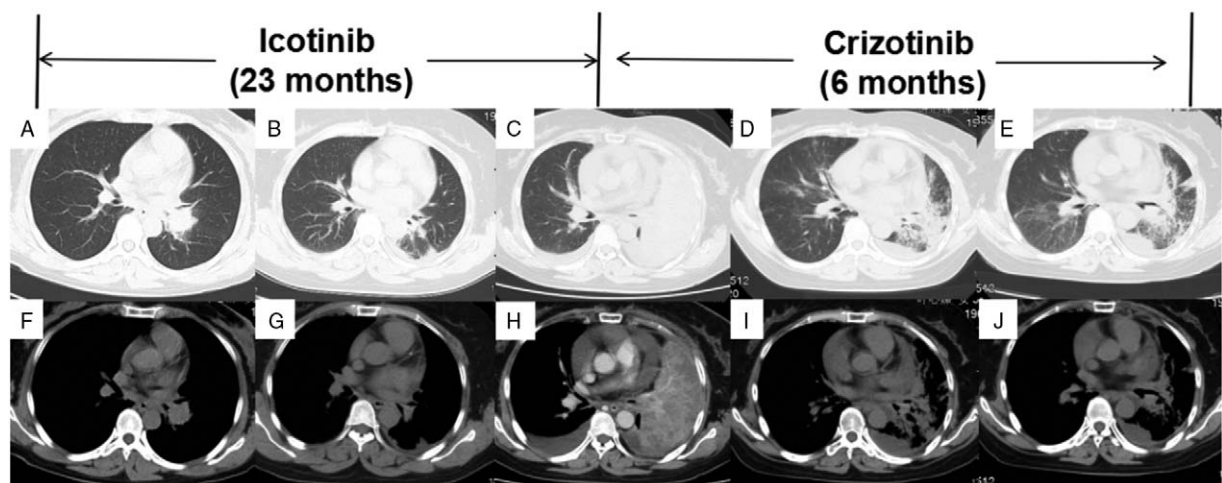


Figure 2. CT scan of lung windows and mediastinal windows in case 2 after Icotinib treatment and after Crizotinib treatment. CT=computed tomography.

crizotinib was initiated (250 mg bid, orally). One week later, the symptoms and life quality of the patient was improved. CT scan performed 1 month later showed a significant decrease in mass and a marked reduce in pleural and pericardial effusion (Fig. 2D and I). The CT scan at 6 months after crizotinib showed a persist decrease of mass (Fig. 2E and K).

3. Discussion

Various mechanisms of EGFR-TKIs resistance were reported. T790M mutation, accounting for approximately 60% of the resistance cases, is presently the most common acquired resistance mechanism for first-generation EGFR-TKIs.^[1–2] But, neither of our cases was detected T790M mutation. On the contrary, we detected a rare mutation (MET amplification) in these 2 cases. MET amplification is another mechanism of EGFR-TKIs resistance by activating bypass signaling through receptor tyrosine kinase, accounting for 5% to 10% of EGFR-TKIs acquired resistance.^[3] Furthermore, some other mechanism was also observed, including EGFR amplification, PIK3CA mutation, and transformation to small cell lung cancer.^[2] So, repeated biopsy and identifying molecular changes might benefit before subsequent treatment in lung cancer patients with EGFR-TKIs acquired resistance.

Pleural effusion is a familiar complication in advanced stage lung cancer patients. In some patients with worse personal performance, repeated biopsy became difficult. So, pleural effusion might be a substitute choice for detection of driver gene. A previous study has shown the usage of pleural effusion in multiplexed molecular profiling in lung cancer patients by pyrosequencing or reverse-transcriptase polymerase chain reaction.^[6] Although this report showed 2 cases of MET amplification in pleural effusion, they neither indicated the concordance with matched tissue samples in the 2 cases, nor did they reveal the drugs selection or progression free survival. Moreover, they detected MET amplification using polymerase chain reaction, which was different from our methods (NGS). In our study, we gave the 2 patients crizotinib treatment after NGS results, and both of them got rapid response to crizotinib. These results indicated the efficiency of MET amplification detection in pleural effusion.

Some histological features of adenocarcinoma were associated with genotype. For example, EGFR-mutated adenocarcinoma is characterized by lepidic pattern, micropapillary pattern, and hobnail cell type. Our 2 cases were lepidic pattern and micropapillary pattern, respectively, according to the tumor

tissue biopsy. However, the rebiopsy results only show metastatic adenocarcinoma without histological structure features, as these were determined via pleural effusion, not tumor tissue. This might be the weakness of liquid biopsy. But, the genotype could be implicated via NGS combined liquid biopsy.

NGS facilitates the sequencing of millions to billions of short fragments of DNA in parallel instead of 1 DNA fragment at a time (Sanger sequencing), allowing concurrent analysis of many genes/exons in a single assay.^[8] The NGS assay is capable of detecting the full range of mutation types on minute specimens, including fine needle aspiration rinse, plasma, pleural effusion, and bronchoalveolar lavage.^[6,7] Many mutations have been detected by NGS in pleural effusion after EGFR-TKIs resistance was reported, including T790M, ALK, KRAS, etc.^[8,9] However, there has no report previously showing MET amplification in pleural effusion using NGS. Our study not only showed the MET amplification in pleural effusion using NGS, but also demonstrated the clinical role in assessment response to crizotinib. So, it was feasible to assess the MET amplification and response to crizotinib using NGS in pleural effusion.

References

- [1] Su S, Wu YL. Clinical trials of tyrosine kinase inhibitors for lung cancer in China: a review. *J Hematol Oncol* 2017;10:147.
- [2] Yu HA, Arcila ME, Rekhtman N, et al. Analysis of tumor specimens at the time of acquired resistance to EGFR-TKI therapy in 155 patients with EGFR-mutant lung cancers. *Clin Cancer Res* 2013;19:2240–7.
- [3] Feng Y, Thiagarajan PS, Ma PC. MET signaling: novel targeted inhibition and its clinical development in lung cancer. *J Thorac Oncol* 2012;7:459–67.
- [4] Sun W, Yuan X, Tian Y, et al. Non-invasive approaches to monitor EGFR-TKI treatment in non-small-cell lung cancer. *J Hematol Oncol* 2015;8:95.
- [5] Mao C, Yuan JQ, Yang ZY, et al. Blood as a substitute for tumor tissue in detecting EGFR mutations for guiding EGFR TKIs treatment of nonsmall cell lung cancer: a systematic review and meta-analysis. *Medicine (Baltimore)* 2015;94:e775.
- [6] Akamatsu H, Koh Y, Kenmotsu H, et al. Multiplexed molecular profiling of lung cancer using pleural effusion. *J Thorac Oncol* 2014;9:1048–52.
- [7] Inamura K, Ninomiya H, Ishikawa Y, et al. Is the epidermal growth factor receptor status in lung cancers reflected in clinicopathologic features? *Arch Pathol Lab Med* 2010;134:66–72.
- [8] Buttitta F, Felicioni L, Del Grammaastro M, et al. Effective assessment of egfr mutation status in bronchoalveolar lavage and pleural fluids by next-generation sequencing. *Clin Cancer Res* 2013;19:691–8.
- [9] Wei S, Lieberman D, Morrisette JJ, et al. Using “residual” FNA rinse and body fluid specimens for next-generation sequencing: an institutional experience. *Cancer Cytopathol* 2016;124:324–9.