

## Case Report

# Eggshell apex abnormalities associated with *Mycoplasma synoviae* infection in layers

Eun-Ok Jeon<sup>1</sup>, Jong-Nyeo Kim<sup>1</sup>, Hae-Rim Lee<sup>1</sup>, Bon-Sang Koo<sup>1</sup>, Kyeong-Cheol Min<sup>1</sup>, Moo-Sung Han<sup>1</sup>, Seung-Baek Lee<sup>1</sup>, Yeon-Ji Bae<sup>1</sup>, Jong-Suk Mo<sup>1</sup>, Sun-Hyung Cho<sup>1</sup>, Chang-Hee Lee<sup>2</sup>, In-Pil Mo<sup>1,\*</sup>

<sup>1</sup>Avian Disease Laboratory, College of Veterinary Medicine, Chungbuk National University, Cheongju 361-763, Korea

<sup>2</sup>Aviagen, Huntsville, AL 35805, USA

Eggs exhibiting eggshell apex abnormalities (EAA) were evaluated for changes in shell characteristics such as strength, thickness, and ultrastructure. *Mycoplasma synoviae* (MS) infection was confirmed by serological assay along with isolation of MS from the trachea and oviduct. Changes in eggshell quality were shown to be statistically significant ( $p < 0.01$ ). We also identified ultrastructural changes in the mammillary knob layer by Scanning Electron Microscopy. While eggs may seem to be structurally sound, ultrastructural evaluation showed that affected eggs do not regain their former quality. In our knowledge, this is the first report describing the occurrence of EAA in Korea.

**Keywords:** eggshell abnormalities, eggshell ultrastructure, *Mycoplasma synoviae*, scanning electron microscopy

*Mycoplasma synoviae* (MS) is a type of avian pathogenic mycoplasma found worldwide that causes subclinical or clinical infections in chickens. This microorganism is known to incur significant economic loss to the poultry industry due to respiratory distress, synovitis, airsacculitis, and reduced egg production [8]. The scale of economic damage caused by MS has been a subject of debate [3,12] until recently when the possibility of natural or experimental MS infection in chickens causing eggshell apex abnormalities (EAA) was confirmed. The occurrence of EAA verifies the direct impact of MS on productivity in the poultry industry. EAA due to MS can be defined as a weakened state of the egg that promotes the development of cracks and breaks. The top cone of the egg undergoes characteristic changes such as roughening of the shell surface, thinning of the shell, and increased translucency [4]. While cases of EAA have been frequently reported in

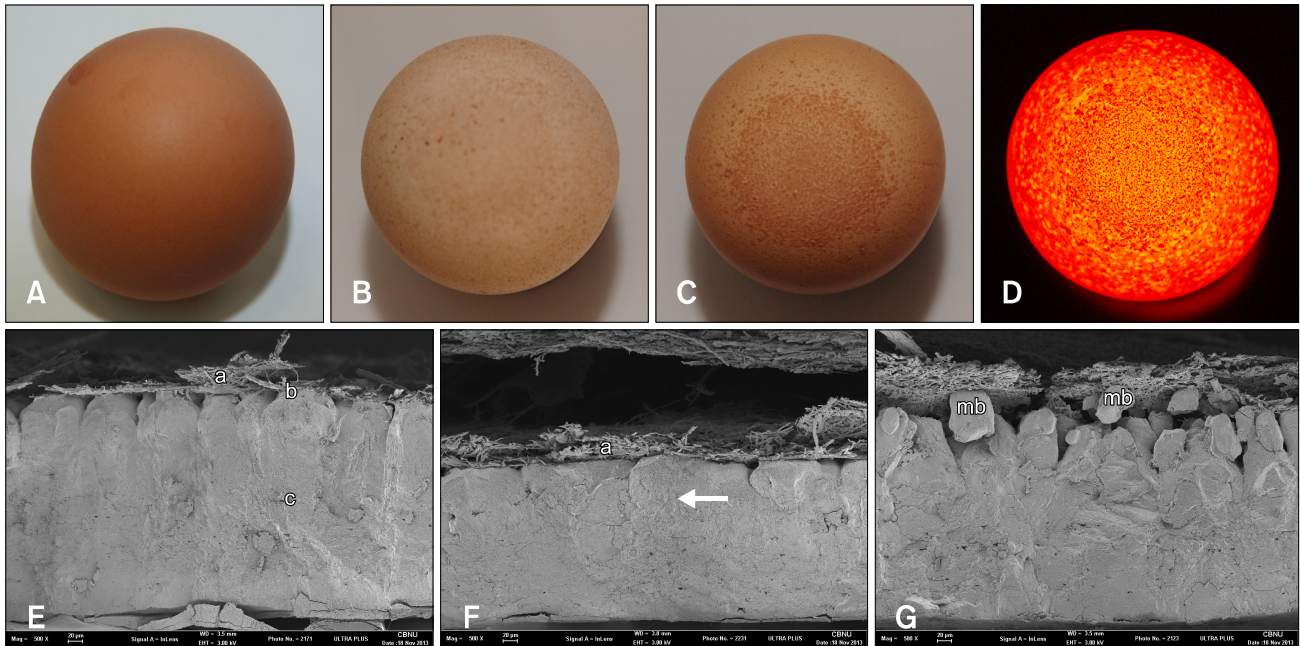
Germany, Australia, and the Netherlands [2,6], this condition has not been observed in Korea. In the present study, MS associated with EAA was isolated from layers and a serologic analysis was performed. Changes in egg quality and ultrastructure were also observed over a prolonged period of time from the initial stages of infection until molting.

Shell abnormalities were observed from eggs produced by 55-week-old Hyline brown layers of the SH farm located in Gyeonggi-do that were submitted to the Avian Disease Laboratory of Chungbuk National University (Korea) for diagnosis. Rough and dark patches of various sizes with different densities were found on the blunt end of the eggs. A clear demarcation zone separating the patches from the normal part of the shell was clearly identified when a light was held up to the eggs. Discoloration, specks, and cracks were also observed in the eggs with EAA (panels A-D in Fig. 1).

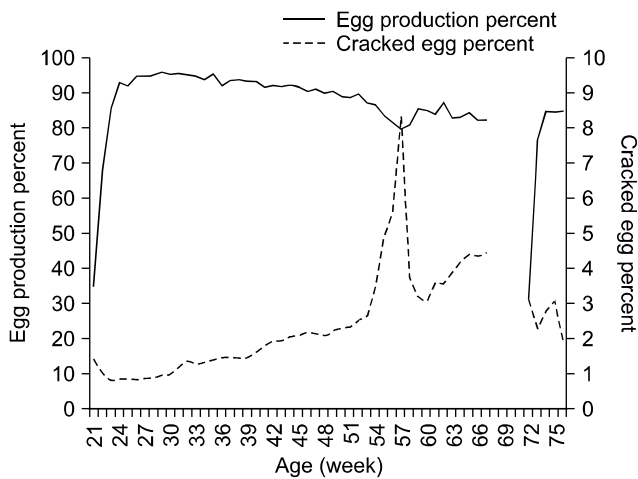
Egg production rates of 54-week-old layers from the SH farm where EAA was observed decreased from 86% to 79% during a 3-week period. Cracked egg rates also increased from 2.6% to 8.3%, reaching a peak along with increased mortality at 57-week-old age (Fig. 2). While changes of eggshell quality may be attributed to non-infectious factors [13], an experimental analysis was conducted to confirm the existence of infection. Factors such as sudden changes in egg production or concentration of specific lesions on the apex of the eggs strongly suggest the possibility that egg quality has been altered by infectious agents.

Eggshell samples were obtained from 55-week-old chickens that produced eggs with EAA and 77-week-old chickens in which EAA was not observed after molting that resided at the SH farm. The serum samples were screened for antibodies specific for reproductive diseases

\*Corresponding author: Tel: +82-43-261-3356; Fax: +82-43-267-3150; E-mail: moip@cbu.ac.kr



**Fig. 1.** Gross (A ~ D) and ultrastructural (E ~ G) images of eggs either eggshell apex abnormalities (EAA)-positive (B ~ D, F, and G) or -negative (A and E) collected from layers on the SH farm with *Mycoplasma synoviae* (MS) infection. Note the presence of rough and dark areas on the surface of the eggs (B ~ D). A demarcated zone was clearly present in the eggshell (D) with increased light penetration on the blunt end when illuminated with a flashlight. Scanning electron microscope (SEM) images of an unaffected eggshell (E) clearly showed the inner membrane (a), mammillary knob layer (b), and part of the palisade layer (c). Shells of eggs with EAA (F and G) lacked a mammillary knob layer and only part of the palisade layer was present (arrow). Additionally, larger and more irregular membrane bodies (mb) were observed. A size bar is present at the bottom of each SEM image.



**Fig. 2.** Changes of egg production rate and cracked egg rate for the layer farm with EAA. A significant drop in egg production and increased cracked egg rate were present for layers between 52 weeks and 57 weeks old. Production was not recorded for birds between 68 weeks and 71 weeks old because of molting.

to evaluate the possibility of infection. A hemagglutination inhibition test was conducted to monitor for avian influenza (AI), Newcastle disease (ND), and egg drop syndrome (EDS) according to Office International des

Epizooties (OIE; France) standards. The titers of antibodies against AI, ND, and EDS fell well under vaccine-induced titers. Commercial ELISA kits (IDEXX Laboratories, USA) were used to screen for infectious bronchitis (IB), *Mycoplasma gallisepticum* (MG) infection, and MS infection. An additional rapid serum agglutination test was also conducted to survey for MG and MS infection using antigens provided by the Animal and Plant Quarantine Agency (Korea).

MS-specific antibody titers measured by the ELISA were  $13,563 \pm 5,945$  for the 55-week-old layers and  $6,053 \pm 2,709$  for the 77-week-old layers. These data indicated that the layers were infected by wild-type MS and reflected the fact that MS vaccines are not routinely administered in Korea. Anti-MG antibody was not detected by ELISA. An IB-specific ELISA was also conducted for 60 serum samples. The mean antibody titers for 55-week-old layers and 77-week-old layers were  $5,871 \pm 1,981$  and  $5,777 \pm 2,744$ , respectively. Considering the fact that the flocks were vaccinated with IB oil emulsion vaccines before reaching the egg-laying age, the level of titer showed infection by wild-type IB did not occur [9].

To confirm infection by isolating wild-type MS, sterilized cotton swabs were collected from the choanal cleft, trachea, and oviduct. MS was cultured in Mycoplasma

broth (BD, USA) as previously described by Catania *et al.* [2]. Samples for which the Mycoplasma broth color changed (yellow) were subjected to PCR for amplification of the *vlhA* gene [7]. DNA was extracted using a Viral Gene Spin kit (iNtRON Biotechnology, Korea). PCR-positive samples were submitted for gene sequence analysis (Cosmogenetech, Korea). MS was isolated from the respiratory tract of 41 birds among a total of 60 layers sampled at the age of 55 weeks. Additionally, 20 birds were selected from the 55-week-old layers to isolate MS from both the isthmus and uterus. Only one bird was MS-positive for both the isthmus and uterus. At the age of 77 weeks, 60 birds that did not produce eggs with EAA were surveyed for MS and 35 were found to be MS-positive in the respiratory tract. Among the 20 birds selected for MS isolation from the oviduct, none were positive. Samples from both groups (55 weeks or 77 weeks old) were cultured in blood agar medium (Hanil Komed, Korea). All cultures produced negative results.

Oviduct tissue samples were obtained from the infundibulum, magnum, isthmus, and uterus. The samples were processed by general methods for histologic examination [11] and subjected to hematoxylin and eosin (H&E) staining (Sigma-Aldrich, USA). No significant findings including evidence of inflammation were observed.

Previous studies revealed that pathologic lesions may be absent in the oviduct despite the presence of eggshell abnormalities, especially in cases of primary MS infections [4,5]. *vlhA* gene sequence analysis results showed that the strains (KM985992) isolated from the SH farm were identical, lacking 39 nucleotides (nt 133 ~ 171) compared with the EAA strain (FJ495803) previously documented by Feberwee *et al.* [5]. The isolated strains also had 100% resemblance with the enrofloxacin intermediate-resistant KC832815 strain previously isolated from broilers by Lysnyansky *et al.* [10].

To verify EAA, eggshell quality was evaluated for eggs collected from 55- and 77-week-old layers of the SH farm. The eggshells were tested for strength, thickness, and

ultrastructure integrity. Scanning electron microscope (SEM) samples were prepared as previously described by Feberwee *et al.* [4] using Karnovsky fixative. The shells were fixed for 1~2 weeks. A statistical analysis was conducted using Fisher's least significant difference test. A *p* value less than 0.05% was considered statistically significant. The average shell thickness of EAA eggs from 55-week-old birds was  $0.34 \pm 0.05$  mm. These data were compared that for eggs from both 77-week-old birds without signs of EAA and the negative control group of 54- and 64-week-old birds sampled from Hyline layer farm located in Gyeonggi-do without MS infection or EAA that produced eggs with a shell thickness ranging from 0.40 to 0.42 mm. Results of the analysis demonstrated that decreased shell thickness of the EAA eggs was statistically significant ( $p < 0.01$ ). Similar results were recovered from the eggshell strength tests. The strength of the shells of eggs from 55-week-old birds with EAA ( $26.95 \pm 6.15$  N/cm<sup>2</sup>) was low compared to that of eggs produced by 77-week-old birds without EAA as well as negative control chickens without MS infection or EAA ( $34.55 \sim 36.95$  N/cm<sup>2</sup>). Shell strength of the EAA eggs was significantly decreased ( $p < 0.01$ , Table 1).

To evaluate shell ultrastructure, SEM was performed. A loss of mammillary knob layer detail was observed for EAA eggs. These findings coincide with data from Feberwee *et al.* [4]. In addition to assessment of the mammillary knob layers, evaluation of mammillary alterations was conducted. The majority of lesions fell into the three categories proposed by Bunk and Balloun [1]. Specific changes such as the presence of mammillary bodies, multinucleation, waves in the nucleation zone, and deformation mammillary knobs (cavernous tips) were observed in the EAA eggs of 55-week-old birds (panels E-G in Fig. 1). Specific EAA-associated lesions were also present in the ultrastructure of non-EAA eggs produced by 77-week-old birds, which did not display any gross lesions. In contrast, shell thickness and strength of the non-EAA eggs from 77-week-old birds were normal.

In conclusion, MS infection of 55-week-old birds from

**Table 1.** Comparison of egg quality according to shell strength and thickness of either eggs with EAA from 55-week-old birds and ones without EAA from either 77-week-old birds or uninfected normal birds

MS infection	Age (week) (presence of EAA)	Measurements*	
		Eggshell breaking strength (N/cm <sup>2</sup> )	Eggshell thickness (mm)
Infected	55 (Yes)	$26.95 \pm 6.15^a$ (n = 18)	$0.34 \pm 0.05^a$ (n = 58)
	77 (No)	$34.55 \pm 11.49^b$ (n = 20)	$0.40 \pm 0.06^b$ (n = 20)
Uninfected	54 (No)	$36.95 \pm 8.75^b$ (n = 30)	$0.40 \pm 0.02^b$ (n = 20)
	64 (No)	$36.26 \pm 10.23^b$ (n = 30)	$0.42 \pm 0.03^b$ (n = 30)

\*Geometric mean  $\pm$  SD; statistically significant differences within each column are indicated by different lowercase superscript letters.

the SH farm that produced eggs with EAA was confirmed by serologic tests and MS isolation. Egg quality evaluation and SEM also demonstrated the existence of pathologic changes. The current case study describes the first domestic EAA cases in Korea and revealed the fact that eggs which appeared to recover from EAA are still defective at the ultrastructure level. Further studies are required to fully understand the correlation between MS oviduct infection and EAA.

### Conflict of Interest

There is no conflict of interest.

### References

1. **Bunk MJ, Balloun SL.** Ultrastructure of the mammillary region of low puncture strength avian eggshells. *Poult Sci* 1978, **57**, 639-647.
2. **Catania S, Bilato D, Gobbo F, Granato A, Terregino C, Iob L, Nicholas RA.** Treatment of eggshell abnormalities and reduced egg production caused by *Mycoplasma synoviae* infection. *Avian Dis* 2010, **54**, 961-964.
3. **Dufour-Gesbert F, Dheilley A, Marois C, Kempf I.** Epidemiological study on *Mycoplasma synoviae* infection in layers. *Vet Microbiol* 2006, **114**, 148-154.
4. **Feberwee A, de Wit JJ, Landman WJM.** Induction of eggshell apex abnormalities by *Mycoplasma synoviae*: field and experimental studies. *Avian Pathol* 2009, **38**, 77-85.
5. **Feberwee A, Morrow CJ, Ghorashi SA, Noormohammadi AH, Landman WJM.** Effect of a live *Mycoplasma synoviae* vaccine on the production of eggshell apex abnormalities induced by a *M. synoviae* infection preceded by an infection with infectious bronchitis virus D1466. *Avian Pathol* 2009, **38**, 333-340.
6. **Gole VC, Chousalkar KK, Roberts JR.** Prevalence of antibodies to *Mycoplasma synoviae* in laying hens and possible effects on egg shell quality. *Prev Vet Med* 2012, **106**, 75-78.
7. **Jeffery N, Gasser RB, Steer PA, Noormohammadi AH.** Classification of *Mycoplasma synoviae* strains using single-strand conformation polymorphism and high-resolution melting-curve analysis of the *vlhA* gene single-copy region. *Microbiology* 2007, **153**, 2679-2688.
8. **Jordan FTW.** Avian mycoplasma and pathogenicity - a review. *Avian Pathol* 1975, **4**, 165-174.
9. **Lee HR, Kim JM, Kim JH, Kim CM, So HH, Lee DW, Ha BD, Hong SC, Mo IP.** Serological survey for the major viral diseases in the layers. *Korean J Poult Sci* 2010, **37**, 361-372.
10. **Lysnyansky I, Gerchman I, Mikula I, Gobbo F, Catania S, Levisohn S.** Molecular characterization of acquired enrofloxacin resistance in *Mycoplasma synoviae* field isolates. *Antimicrob Agents Chemother* 2013, **57**, 3072-3077.
11. **MacOwan KJ, Randall CJ, Jones HGR, Brand TF.** Association of *Mycoplasma synoviae* with respiratory disease of broilers. *Avian Pathol* 1982, **11**, 235-244.
12. **Mohammed HO, Carpenter TE, Yamamoto R.** Economic impact of *Mycoplasma gallisepticum* and *M. synoviae* in commercial layer flocks. *Avian Dis* 1987, **31**, 477-482.
13. **Roberts JR.** Factors affecting egg internal quality and egg shell quality in laying hens. *J Poult Sci* 2004, **41**, 161-177.