

## CASE REPORT

# Successful treatment of refractory donor-specific-human leukocyte antigen-antibody-induced primary graft-failure with daratumumab: A case report

Vadim Lesan<sup>1</sup>  | Ketevani Melivadze<sup>1</sup> | Johannes Hein<sup>1</sup> | Manfred Ahlgrimm<sup>1</sup> | Stefan Schunk<sup>2</sup> | Moritz Bewarder<sup>1</sup>  | Konstantinos Christofyllakis<sup>1</sup> | Joerg Thomas Bittenbring<sup>1</sup> | Lorenz Thurner<sup>1</sup> 

<sup>1</sup>Department of Hematology and Oncology, Internal Medicine I, Saarland University Medical School, Homburg, Germany

<sup>2</sup>Department of Nephrology, Saarland University Medical School, Homburg, Germany

## Correspondence

Vadim Lesan, Internal Medicine I, Saarland University Medical School, Homburg, Saar, Germany.

Email: [Vadim.Lesan@uks.eu](mailto:Vadim.Lesan@uks.eu)

## Abstract

Donor-specific anti-human leukocyte antigen (HLA) antibodies represent a main cause of primary graft failure specifically in the setting of haploidentical stem cell transplantation. Newer therapy strategies including daratumumab could overcome some of these limitations. We describe the case of a patient with refractory acute myeloid leukemia. A haploidentical allogeneic stem cell transplantation was therefore initiated. HLA-antibodies testing revealed a high titer of donor-specific antibodies. First desensitization therapy failed, resulting in primary graft failure. A second desensitization regimen including plasmapheresis, intravenous gammaglobulins, and daratumumab resulted in good engraftment. Daratumumab is a promising and effective desensitization option in high-risk allo-sensitized patients undergoing haploidentical stem cell transplantation.

## KEYWORDS

acute leukemia, antibodies, engraftment

## 1 | BACKGROUND

Donor-specific anti-human leukocyte antigen (HLA) antibodies (DSA) represent the main cause of primary graft failure specifically in the haploidentical setting [1]. Therefore, detection of relevant titers of DSA (mean fluorescence index [MFI] > 2000) shall be included in donor selection as engraftment failure can be as high as 75% [2]. Desensitization therapies include plasmapheresis or immune adsorption for the removal of DSA from the bloodstream, B-cell depletion by rituximab for prevention of the production of new DSA, and intravenous

gammaglobulins (IVIg) for the suppression of DSA-mediated effects [1]. Despite these means, refractory graft failure can still occur in a high number of patients, especially when DSA MFI > 20.000 at transplantation [2].

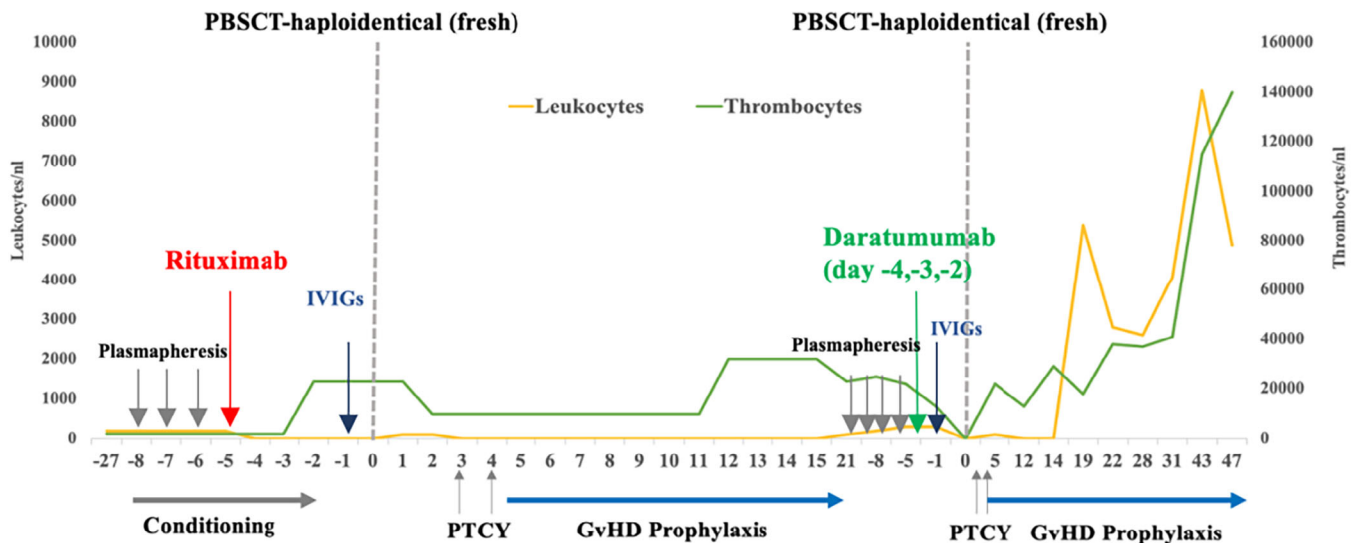
## 2 | CASE PRESENTATION

Here we describe a 64-year-old female patient with high-risk acute myeloid leukemia (AML) with inv [3](q21q26), corresponding to a MECOM rearrangement beside mutations in *BCOR* and *CPL*. The patient had refractory disease on day 21 after “7+3” induction chemotherapy with daunorubicin and cytarabine [3]. In light of the

**Abbreviations:** DSA, donor-specific anti-human leukocyte antigen antibodies; G-CSF, granulocyte colony-stimulating factor; IVIG, intravenous gammaglobulins; MFI, mean fluorescence index; MMF, mycophenolate mofetil; PTCY, post-transplant cyclophosphamide.

This is an open access article under the terms of the [Creative Commons Attribution-NonCommercial-NoDerivs](https://creativecommons.org/licenses/by-nc-nd/4.0/) License, which permits use and distribution in any medium, provided the original work is properly cited, the use is non-commercial and no modifications or adaptations are made.

© 2024 The Author(s). eJHaem published by British Society for Haematology and John Wiley & Sons Ltd.



PTCY: post-transplant cyclophosphamide  
 PBSCT: peripheral blood stem cell transplantation

**FIGURE 1** Transplant conditioning including graft versus host disease (GVHD) prophylaxis, platelet and leukocyte counts over time.

**TABLE 1** Mean fluorescence index of anti-human leukocyte antigen (HLA)-antibodies and donor-specific anti-HLA-antibodies.

| Timepoint | Anti-HLA class I | Anti-HLA class II | Anti-HLA-A*01:01 | Anti-HLA-B57:01 |
|-----------|------------------|-------------------|------------------|-----------------|
| Day -28   | 22.170           | 20.548            | n.a              | n.a             |
| Day -4    | 21.624           | n.a               | n.a              | n.a             |
| Day 0     | 2.993            | 9.095             | n.a              | n.a             |
| Day 10    | 13.000           | 1.803             | 9.000            | 2.508           |
| Day 19    | 13.077           | 2.003             | 3.695            | 2.068           |
| Day 32    | 7.658            | 2.211             | Negative         | Negative        |
| Day 35    | 2.604            | Negative          | Negative         | Negative        |
| Day 0     | 2.223            | Negative          | n.a              | n.a             |
| Day 6     | 1.769            | Negative          | n.a              | n.a             |
| Day 13    | 1.566            | Negative          | n.a              | n.a             |
| Day 15    | Negative         | Negative          | n.a              | n.a             |

very poor prognosis, a sequential conditioning regimen with FLAMSA-Venetoclax followed by Treosulfan/Fludarabine with a haploidentical donor (5/10) and post-transplant cyclophosphamide (PTCY) was planned (Figure 1) [4]. During the conditioning regimen, the results of the HLA-antibodies revealed a high titer of donor-specific antibodies with an MFI of more than 20,000 U/L (Table 1). As such three sessions of plasmapheresis were performed followed by the administration of rituximab (375 mg/m<sup>2</sup> on day -5) and IVIGs (0.4 mg/kg on day -1). This combination therapy resulted in a reduction of relevant DSA of HLA-I class from 22,170 to 2993 on day 0 and we proceeded to transplant peripheral blood stem cells (16 × 10<sup>6</sup> CD34+/kg of recipient body weight). PTCY was given at full dose (50 mg/kg) on day +3 and +4, with mycophenolate mofetil (MMF) and tacrolimus as graft versus host disease prophylaxis and granulocyte colony-stimulating factor

(G-CSF) support from day +5. Despite the above-mentioned measures, the HLA-I DSA rose to an MFI of 13,000. The patient developed primary graft failure with a maximum leukocyte count of 100/μl on day 28. The bone marrow examination showed a hypoplastic bone marrow, without any blast persistence, but with residual plasma cells. The chimerism was entirely of recipient origin. Infectious reasons for graft failure including Parvovirus B19 and Cytomegalovirus-reactivation were ruled out. As such, a refractory humoral graft rejection by recurring-rising DSA was diagnosed. For reasons of urgency, we decided on a re-transplantation with the same haploidentical donor. The second desensitization regimen included four sessions of plasmapheresis combined with immunoadsorption, daratumumab (8 mg/kg on day -4 and -3, 16 mg/kg on day -2), and IVIGs (0.4 mg/kg on day -1), with the result of DSA HLA-I of 2223 MFI and no relevant

HLA-II DSA on day 0 (Table 1). We did not use an irradiated donor buffy coat since no HLA-II DSA was present. A dose of  $15.7 \times 10^6$  CD34+/kg of recipient body weight fresh peripheral blood stem cells were transplanted. Echocardiography showed normal left ventricular function, but because of previous cumulative doses, reduced PTCY (40 mg/kg) was given. The GvHD prophylaxis included MMF and Tacrolimus and was initiated together with G-CSF on day +5 (Figure 1). The neutrophils engrafted on day +18 after the 2nd transplantation. Because of delayed thrombopoiesis and the difficult history, we added a short course of Eltrombopag (day +18 to day +32). Platelet engraftment was achieved on day +24. The bone marrow aspiration showed complete cytological, cytogenetical, and molecular remission with full donor chimerism. No signs of GvHD or viral reactivations were observed during the whole treatment period. On day +35 after the second bone marrow transplantation DSA MFI remained negative.

### 3 | DISCUSSION AND CONCLUSIONS

Despite intensive desensitization therapy combination, patients with high DSA titers have lower neutrophil engraftment rates [2]. This could be either due to insufficient elimination of DSAs from the bloodstream (plasmapheresis with or without immunoadsorption) or due to insufficient inhibition of DSA production. DSA production is a function of plasma cells that, as our case shows, can be impressively resistant to chemotherapy including high-dose PTCY.

Desensitization strategies including rituximab could be insufficient since plasma cells normally don't retain CD20 expression, due to the switch from B-cell transcription factors BCL-6 and PAX5 to BLIMP1 and IRF4 [5]. As such, novel strategies including therapies targeting plasma cells are being increasingly reported [6]. Daratumumab, an anti-CD38 antibody, successfully reduced the refractory DSAs in patients with B-acute lymphoblastic leukemia and ABO incompatible solid organ transplantation [6, 7]. The presence of CD38 on immature hematopoietic cells could theoretically lead to engraftment failure. This could be one important concern in the setting of haploidentical allogeneic stem cell transplantation.

Here we present the case of a successful re-desensitization with daratumumab-based combination therapy in the haploidentical allogeneic stem cell transplantation setting. Daratumumab preceded by plasma exchange and followed by IVIGs resulted in neutrophil and platelet engraftment in our patient before day 28.

One limitation of our case is that we did not test for the complement fixation capability of the DSAs with the C1q assay. Despite this fact, it is well recognized that DSA > 20,000 MFI at the diagnosis poses the highest risk for graft failure, irrespective of the C1q status [1, 8]. C1q uses a solid-phase immunoassay and detects only complement-fixing HLA-specific antibodies. Other cell-based assays including standard complement-dependent cytotoxicity crossmatch and flow cytometry crossmatch were described as useful tools to detect DSA [9].

Another limitation of our case was that the pretransplant DSA testing was performed relatively late. Early testing of DSA allows timely

identification of the best donor [2]. This is particularly important in the setting of haploidentical bone marrow transplantation. Finally, we acknowledge that the desensitization effect seen in our case could be due to previous rituximab administration and not exclusively due to daratumumab.

In conclusion, daratumumab is a promising and effective desensitization option in high-risk allo-sensitized patients undergoing haploidentical stem cell transplantation. This approach might be meaningful for refractory cases, but we acknowledge that more experience is needed before inclusion into recommendations.

#### AUTHOR CONTRIBUTIONS

Vadim Lesan collected the data and wrote the manuscript; Ketevani Melivadze and Johannes Hein collected the data and reviewed the manuscript; Manfred Ahlgrimm, Stefan Schunk, Moritz Bewarder, and Konstantinos Christofyllakis reviewed the manuscript; Joerg Thomas Bittenbring and Lorenz Thurner reviewed and wrote the manuscript. All authors read and approved the final manuscript.

#### ACKNOWLEDGMENTS

Not applicable.

#### CONFLICT OF INTEREST STATEMENT

The authors declare no conflict of interest.

#### FUNDING INFORMATION

The authors received no specific funding for this work.

#### DATA AVAILABILITY STATEMENT

Not applicable.

#### ETHICS STATEMENT

The authors have confirmed ethical approval statement is not needed for this submission.

#### PATIENT CONSENT STATEMENT

The authors have confirmed patient consent statement is not needed for this submission.

#### CLINICAL TRIAL REGISTRATION

The authors have confirmed clinical trial registration is not needed for this submission.

#### ORCID

Vadim Lesan  <https://orcid.org/0000-0002-2600-2122>

Moritz Bewarder  <https://orcid.org/0000-0003-0926-6895>

Lorenz Thurner  <https://orcid.org/0000-0002-8167-2989>

#### REFERENCES

1. Ciurea SO, Al Malki MM, Kongtim P, Zou J, Aung FM, Rondon G, et al. Treatment of allosensitized patients receiving allogeneic transplantation. *Blood Adv.* 2021;5(20):4031–43. Available from: <https://pubmed.ncbi.nlm.nih.gov/34474478/>

2. Ciurea SO, Thall PF, Milton DR, Barnes TH, Kongtim P, Carmazzi Y, et al. Complement-binding donor-specific anti-HLA antibodies and risk of primary graft failure in hematopoietic stem cell transplantation. *Biol Blood Marrow Transplant*. 2015;21(8):1392–98.
3. Rowe JM. The “7+3” regimen in acute myeloid leukemia. *Haematologica*. 2022;107(1):3–3. Available from: <https://haematologica.org/article/view/10484>
4. Döhner H, Wei AH, Appelbaum FR, Craddock C, DiNardo CD, Dombret H, et al. Diagnosis and management of AML in adults: 2022 recommendations from an international expert panel on behalf of the ELN. *Blood*. 2022;140(12):1345–77. Available from: <https://dx.doi.org/10.1182/blood.2022016867>
5. Robillard N, Wuillème S, Moreau P, Béné MC. Immunophenotype of normal and myelomatous plasma-cell subsets. *Front Immunol*. 2014;5:137. Available from: [/pmc/articles/PMC3978250/](https://pmc/articles/PMC3978250/)
6. Li X, Zhu H, Sui T, Zhao X, Deng Q. A case of daratumumab-induced significant decrease in donor-specific HLA antibodies and remission induction before haploidentical stem cell transplantation in a refractory B-ALL patient. *Cell Transplant*. 2022;31:9636897221132502. Available from: <https://pubmed.ncbi.nlm.nih.gov/36278404/>
7. Spica D, Junker T, Dickenmann M, Schaub S, Steiger J, Rüfli T, et al. Daratumumab for treatment of antibody-mediated rejection after ABO-incompatible kidney transplantation. *Case Rep Nephrol Dial*. 2020;9(3):149–57. Available from: <https://dx.doi.org/10.1159/000503951>
8. Crocchiolo R. Toward a definition of immunological risk for patients with anti-HLA antibodies before stem cell transplantation. Accessed Mar 3, 2024. Available from: <https://www.bloodtransfusion.it/bt/article/view/630/490>
9. Bramanti S, Calafiore V, Longhi E, Mariotti J, Crespiatico L, Sarina B, et al. Donor-specific anti-HLA antibodies in haploidentical stem cell transplantation with post-transplantation cyclophosphamide: risk of graft failure, poor graft function, and impact on outcomes. *Biol Blood Marrow Transplant*. 2019;25(7):1395–406. Available from: <http://www.aastctjournal.org/article/S1083879119301454/fulltext>

**How to cite this article:** Lesan V, Melivadze K, Hein J, Ahlgrimm M, Schunk S, Bewarder M, et al. Successful treatment of refractory donor-specific-human leukocyte antigen-antibody-induced primary graft-failure with daratumumab: A case report. *eJHaem*. 2024;5:863–66. <https://doi.org/10.1002/jha2.936>