

Pseudoaneurysm of the portal vein as a rare source of gastrointestinal bleeding in pregnancy: a case report

Reza Javadrasshid¹, Sarah Mozafarpour², Shohreh Sadrarami³, Javd Jalili⁴, Bita Sepehri⁵

¹Assistant Professor, Department of Radiology, Imam Reza Hospital, Tabriz University of Medical Sciences, Tabriz, Iran

²Medical Student Research Center, Isfahan University of Medical Sciences, Isfahan, Iran

³Resident of Radiology, Department of Radiology, Imam Reza Hospital, Tabriz University of Medical Sciences, Tabriz, Iran

⁴Resident of Radiology, Department of Radiology, Imam Reza Hospital, Tabriz University of Medical Sciences, Tabriz, Iran

⁵Fellowship of Gastroenterology, Department of Gastroenterology, Imam Reza Hospital, Tabriz University of Medical Sciences, Tabriz, Iran

ABSTRACT

A 28-year-old, 32 week pregnant primigravida woman with a past history of increased blood pressure presented with RUQ pain as well as sudden onset of hematemesis. This case illustrates the occurrence of a rare complication (rupture of portal vein pseudoaneurysm inside the biliary system), appearing as upper gastrointestinal bleeding in a pregnant woman. The cause of the rupture is presumably pregnancy-related. We would like to emphasize the presence of pseudoaneurysm of the portal vein as a rare source of gastrointestinal bleeding in pregnancy.

Keywords: Portal vein pseudoaneurysm, Gastrointestinal bleeding, Pregnancy, ERCP.

(Please cite as: **Javadrasshid R, Mozafarpour S, Sadrarami S, Jalili J, Sepehri B. Pseudoaneurysm of the portal vein as a rare source of gastrointestinal bleeding in pregnancy: a case report. Gastroenterol Hepatol Bed Bench 2012;5(4):213-216.**)

Introduction

Pseudoaneurysm of portal vein is a rare complication which has previously been reported in one case not associated with pregnancy. We report the first case of portal vein pseudoaneurysm which has occurred in pregnancy.

Case report

A 28-year-old primigravida 32 week pregnant woman admitted due to sudden onset of hematemesis. She was conscious and oriented to person, place and time. Her blood pressure and heart

rate on admission were 100/80 mm/Hg and 110 bpm, respectively.

Physical examination showed mild tenderness over epigastric region and right upper quadrant, positive tilt test, and uterine height 32 cm consistent with 32 weeks of pregnancy. No other significant clinical signs were detected.

She had a documented prenatal care; She had been normotensive during first and second trimester of pregnancy. During recent month, she had experienced occasional epigastric and right upper quadrant (RUQ) pain which had been subsided by ranitidine. She had also a history of hypertension which successfully had been controlled.

Following primary supportive care, emergency endoscopy was performed which revealed active

Received: 18 June 2012 Accepted: 11 September 2012

Reprint or Correspondence: Shohreh Sadrarami, MD
Department of Radiology, Imam Reza Hospital, Tabriz
University of Medical Sciences, Tabriz, Iran
E-mail: sadrarami.sh@gmail.com

hemobilia and fresh blood flow from major papilla; No obvious upper gastrointestinal (GI) lesion was noted. The maternal hepatic function tests, prothrombin time, and platelet counts were normal.

Ultrasonography showed dilated common biliary duct (CBD) and mild dilatation of intrahepatic bile ducts (especially left sided). Some relatively mobile echogenic foci were detected within gallbladder and dilated CBD indicative of biliary sludge balls or fine stone or clot. No hepatic parenchymal abnormality and also no free abdominal fluid were noted.

On the second day of admission, she developed uncontrollable hypertension accompanied by fetal distress. Therefore, prompt termination of the pregnancy was performed by cesarean section (the mother and her infant survived).

Following C/S the patient developed hematemesis, hemochezia and jaundice. Urgent endoscopic retrograde cholangiopancreatography (ERCP) was performed which revealed a dilated CBD and a cystic contrast filling area (Figure 1); no stone or other lesions had been detected. Surprisingly, subtle fresh bleeding from major papilla orifice was noted which was compatible with probable hemorrhagic choleducal cyst.

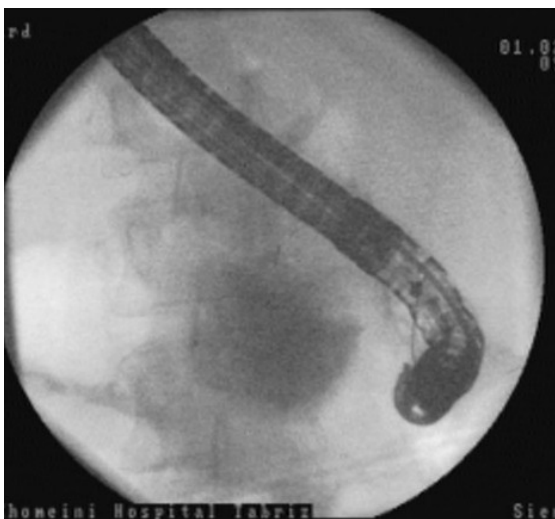


Figure 1. ERCP revealed a dilated CBD and a cystic contrast filling.

Therefore, an urgent abdominal CT scan (single slice unit, Siemens Somatom Balance) was performed, which demonstrated obviously enhanced cystic lesion anterior to left portal vein as well as dilation of extra and intrahepatic biliary duct; some relative hyperdense filling defects were detected within gallbladder and CBD. The patient with primary diagnosis of pseudoaneurysm was referred for CT-angiography. CT-angiography (64 slice unit, Siemens Somatom Sensation) revealed faint staining of pseudoaneurysm in late arterial phase, without obvious connection with left hepatic artery branches (Figure 2).

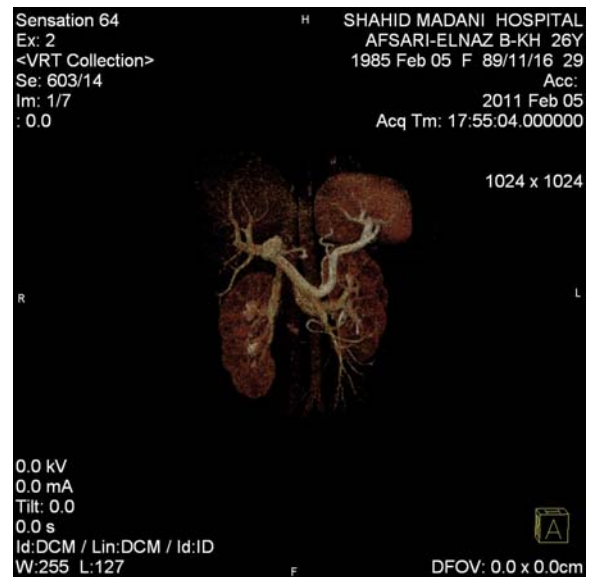


Figure 2. CT-angiography revealed faint staining of pseudoaneurysm in late arterial phase, without obvious connection with left hepatic artery branches.

The lesion showed remarkable enhancement in portal phase; fine connection was detected between the lesion and one of anterior segmental branches of left portal vein. Based on these findings, transcatheter angiographic embolization was suggested for treatment, but the patient developed severe upper and lower GI hemorrhage and hypovolemic shock within 5 hours. Following successful resuscitation, she was taken directly to the operating room with a presumptive diagnosis of

intraperitoneal hemorrhage. In the operating room, first the left hepatic artery was completely ligated but the bleeding was not controlled and selective left lobectomy and cholecystectomy were performed.

The patient was discharged fifteen days after operation with good general condition and normal hepatobiliary enzymatic values.

histopathological findings revealed mild fibrosis, thick wall vessels, inflammatory cells in portal area with some hemorrhage in liver tissue fragments. The cut section of gallbladder tissue was full of blood clot and the wall was atrophic which is consistent with chronic cholecystitis.

Two brown fragments of soft tissue were consistent with hematoma and fibrofatty fragment compatible with pseudoaneurysm.

Discussion

We herein reported a 28-year-old 32-week pregnant primigravida with a past history of increased blood pressure, presented with RUQ pain as well as sudden onset of hematemesis.

As we know, the initial cause for a pregnant patient having such symptoms is eclampsia with hepatic involvement (1). The terms toxemia of pregnancy and pregnancy-induced hypertension have been used synonymously with preeclampsia/eclampsia. A number of other pathophysiologic alterations exist in the preeclampsia/eclampsia syndrome. The hypertension is characteristically labile. Placental hypoperfusion, possibly related to diminish intravascular volume, may be the initiating event in this condition. When these patients develop bleeding and disturbed liver function, the HELLP syndrome should come to the mind. In 1982, Weinstein introduced the acronym HELLP to describe a syndrome observed in severe preeclampsia consisting of RUQ pain, hemolysis, elevated liver function tests, and low platelet counts (2). But, in our case other findings, such as normal PLT count was not compatible with HELLP syndrome.

The pathology of the liver in toxemia of pregnancy has a highly variable spectrum. The histopathology describes fibrin plugs or strands in the sinusoids and hepatic arterioles with resultant areas of periportal necrosis. Liver biopsies revealed periportal or focal parenchymal lesions with large fibrin deposits. In some cases, a hematoma may develop; however, the process may resolve, and the hepatic lesion may heal spontaneously without complete progression to hepatic hemorrhage (2). Spontaneous hepatic hemorrhage of pregnancy (SHHP) is associated with the HELLP syndrome (1). The diagnosis of SHHP due to the aforementioned pathology should be suspected in women with preeclampsia/eclampsia who develop a syndrome of epigastric and right upper quadrant pain with evidence of intraperitoneal hemorrhage. This may occur before delivery or after spontaneous or cesarean section delivery. When hemorrhage follows delivery, one might suppose that the sudden decrease in intra-abdominal pressure or the stress of uterine contracture and the Valsalva maneuver, or both, may have encouraged the rupture. Sudden episodes of hypertension also may be a factor in the rupture of the subcapsular hematoma (3).

Although the current case had normal laboratory data (coagulation parameters, platelets count), clinical symptoms and imaging's findings were consistent with HELLP. Blood smear was not studied for chistocytes in our case. Its presence would be additional confirmatory evidence for the HELLP syndrome (1). As mentioned, histological study of our case (mild fibrosis, thick wall vessels, fibrofatty changes and inflammatory cells in portal area, parenchymal hematoma) confirmed liver parenchymal involvement in HELLP (hematoma).

Although pathologies of hepatic artery have been reported in pregnancy, the presence of portal vein pseudoaneurysm is a unique finding in our case (4). To our knowledge, this is the first reported case of a portal vein pseudoaneurysm presenting as a complication from preeclampsia syndrom.

Few cases of secondary portal vein pseudoaneurysm exist in the literature. One case in 2007 was reported as a complication of pancreaticoduodenectomy. The authors of this article have highlighted the role of MDCT (multi-detector computerized tomography) for correct diagnosis. MDCT angiography has become the preferred imaging modality for evaluation of nontraumatic emergent abdominal vascular complications. High spatial resolution volumetric image data can be obtained at a single breath hold, and perfusion in adjacent organs can be evaluated. In postoperative patients, CT angiography has the advantage of demonstrating anatomy and potential postsurgical complications. Given these advantages, the MDCT holds great promise in the evaluation of gastrointestinal bleeding, and its utility is currently under investigation (5).

In the present case, the upper gastrointestinal endoscopy was helpful in that it revealed the source of bleeding as being the biliary system. But MDCT played an integral role in localizing the site of hemorrhage.

The last but not the least point worth to be mentioned here is the initial presentation symptoms.

Several case reports have been described the same clinical and imaging findings in aneurysmal and pseudoaneurysmal rupture of the common hepatic artery into the biliary tract (6,7). In 1976 the authors believed when aneurysms of the hepatic artery became symptomatic, they might present a triad of upper abdominal pain, gastrointestinal bleeding, and obstructive jaundice (8). One study has reported a hepatic aneurysm as a cause of hemobilia (9).

Therefore, a site-specific diagnosis is important in determining the most appropriate therapy and significantly impact morbidity and mortality. Clinical assessment, endoscopy, scintigraphy, MDCT, abdominal angiography, and surgery are part of the workup as dictated by the pattern and rate of bleeding (10).

In summary, we have described an unusual case of gastrointestinal hemorrhage resulting from portal venous pseudoaneurysm ruptured into biliary system. The related cause is thought to be pregnancy; MDCT angiography played a critical role in localizing the site of hemorrhage. This modality shows promise as an effective tool in the radiographic assessment of unusual gastrointestinal hemorrhage.

References

1. Stain SC, Woodburn DA, Stephens AL, Katz M, Wagner WH, Donovan AJ. Spontaneous hepatic hemorrhage associated with pregnancy. Treatment by hepatic arterial interruption. *Ann Surg* 1996; 224:72-78.
2. Lindheimer MD, Katz AI. Hypertension in pregnancy. *N Engl J Med* 1985; 313:675-80.
3. Weinstein L. Syndrome of hemolysis, elevated liver enzymes, and low platelet count: a severe consequence of hypertension in pregnancy. *Am J Obstet Gynecol* 1982; 142:159-167.
4. Al Hilli FA. Primary dissecting hepatic artery aneurysm in pregnancy. *Cardiovasc Pathol* 2001; 10:99-101.
5. Burke CT, Park J. Portal vein pseudoaneurysm with portoenteric fistula: an unusual cause for massive gastrointestinal hemorrhage. *Semin Intervent Radiol* 2007; 24:341-45.
6. Collier RL, Fox TA. Aneurysm of the hepatic artery as an unusual cause of obstructive jaundice. *Henry Ford Hosp Med J* 1966;14:421-27.
7. Vernadakis S, Christodoulou E, Treckmann J, Saner F, Paul A, Mathe Z. Pseudoaneurysmal Rupture of the Common Hepatic Artery into the Biliodigestive Anastomosis. A Rare Cause of Gastrointestinal Bleeding. *JOP* 2009; 10:441-44.
8. Croom RD 3rd, Frantz PT, Thomas CG Jr, Hothem AL. Aneurysms of the hepatic artery. *South Med J* 1976; 69:1013-16.
9. Santiago Delpín EA. Aneurysms and hemobilia. *Surgery* 1990;107:120.
10. Van den Steen G, Michielsen P, Van Outryve M, Corthouts B, De Backer A. Asymptomatic aneurysm of the hepatic artery. Management options. *Acta Gastroenterol Belg* 2003; 66:298-302.