



Scheuermann's Disease: Radiographic Pathomorphology and Association with Clinical Features

Tomer Bezalel^{1,2}, Eli Carmeli³, Leonid Kalichman²

¹Maccabi Health Care Services, Posture Clinic, Maccabi Hashalom, Tel Aviv, Israel

²Department of Physical Therapy, Recanati School for Community Health Professions, Faculty of Health Sciences at Ben-Gurion University of the Negev, Beer-Sheva, Israel

³Department of Physical Therapy, Faculty of Social Welfare and Health Sciences, Haifa University, Haifa, Israel

Study Design: Cross-sectional analytical study.

Purpose: To evaluate the spinal radiological features in patients with Scheuermann's disease and the association between the thoracic kyphosis angle and clinical presentation.

Overview of the Literature: Scheuermann's disease is the most common cause of hyperkyphosis of the thoracic and thoracolumbar spine in adolescents; however, literature is limited in this area.

Methods: Data regarding 150 successive X-ray images of 95 males and 55 females diagnosed with Scheuermann's disease were retrieved from the digital archives of the Maccabi Healthcare Services in Tel Aviv. Data included thoracic kyphosis angle (T3–T12), cervical lordosis (C2–C7), lumbar lordosis (L1–S1), sacral slope (SS), number and location of the anterior wedged vertebrae (AWV, minimum 5°), and C7 plumb line. Other data included age, sex, height, family history, Risser sign, self-perceived body image (rated by the Numeric Rating Scale [NRS]), and back pain during the previous week (rated by the Numeric Pain Rating Scale [NPRS]).

Results: Significant positive associations were observed between the Cobb angle of thoracic kyphosis and age ($r=0.186$, $p=0.023$), cervical lordosis ($r=0.263$, $p<0.001$), lumbar lordosis ($r=0.576$, $p<0.001$), SS ($r=0.236$, $p<0.004$), T10–T12 Cobb angle ($r=0.319$, $p<0.001$), and number of AWV ($r=0.519$, $p<0.001$). The highest frequency of vertebral wedging was noted in T7 (68%), followed by T8 (65%) and T9 (44%). The NPRS showed a significant association only with SS ($r=0.219$, $p=0.014$). Significant positive associations were observed between the NRS for self-perceived body image, the thoracic kyphosis ($r=0.494$, $p<0.001$), and the number of AWV ($r=0.361$, $p<0.001$).

Conclusions: Thoracic kyphosis was significantly associated with cervical and lumbar lordosis, SS, T10–T12 Cobb angle, and AWV number. Pain was not substantial; however, self-perceived body image, the most common complaint of patients with Scheuermann's disease, was high and significantly associated with thoracic kyphosis and the number of AWV.

Keywords: Scheuermanns kyphosis; Cross-sectional studies; Spine; Kyphosis; Self-perceived body image

Introduction

Scheuermann's disease is the most common cause of hyperkyphosis of the thoracic and thoracolumbar spine that affects adolescents. After idiopathic scoliosis, Scheuermann's disease is the most common developmental disorder

perkyphosis of the thoracic and thoracolumbar spine that affects adolescents. After idiopathic scoliosis, Scheuermann's disease is the most common developmental disorder

Received Jan 20, 2018; Revised Jun 6, 2018; Accepted Jul 1, 2018

Corresponding author: Leonid Kalichman

Department of Physical Therapy, Recanati School for Community Health Professions, Faculty of Health Sciences, Ben-Gurion University of the Negev, P.O.B. 653, Beer Sheva, 84105, Israel

Tel: +972-52-2767050, Fax: +972-8-6477683, E-mail: kleonid@bgu.ac.il, kalichman@hotmail.com

der in patients with a spine deformity [1]. The prevalence of Scheuermann's kyphosis reportedly ranges from 0.4% to 8% across the population [2,3], although its true incidence is likely understated since it is often overlooked or attributed to poor posture [4]. The male-to-female ratio among those diagnosed with Scheuermann's kyphosis varies from 1:2 [5] to 1:1 [6], 2:1 [7], and 7.3:1 [8]. In a recent study conducted on 11,436 patients, the prevalence of this disease in males was almost twice that in females. The estimated prevalence rates in males and females on the basis of heritability, threshold, and regression coefficient for sex were 4% and 2%, respectively [9].

Scheuermann's disease was initially described in 1920 by Scheuermann [8] as a rigid thoracic and thoracolumbar kyphosis associated with wedging of vertebral bodies occurring in late childhood. This definition has evolved over the years, and in 1964, Sorensen [2] proposed a new definition using specific criteria of three or more adjacent apical vertebrae that are individually wedged by an angle of 5° or more. Conversely, other authors advocated different criteria. In 1987, Ali et al. [10] stated that two or more adjacent apical vertebrae were adequate for the diagnosis, whereas Sachs et al. [11] reduced the requirement to at least one vertebra wedged at a minimum of 5° and a thoracic kyphosis angle >45° between T3 and T12.

In addition to the number of wedged vertebrae and the Cobb angle of thoracic kyphosis, various radiographic characteristics of Scheuermann's disease have been described. When the spine is balanced in the sagittal plane, the vertical axis of the C7 vertebral body should lie within two centimeters of the sacral promontory. However, in patients with Scheuermann's disease, the spine tends to be negatively balanced in comparison with the general population. The vertical axis of the C7 vertebral body lies behind the sacral promontory [4]. The C7 plumb line is an indicator of the sagittal balance but does not reflect the relative position of the thoracic and lumbar spine; that is, the transitional zone, which can show significant abnormality in patients with Scheuermann's disease. The transitional zone between the thoracic and lumbar spine includes the T10–L2 vertebrae and is normally slightly lordotic (0° to 10°) [12,13].

Scheuermann's disease is characterized by vertebral body wedging, vertebral endplate irregularity, diminished anterior vertebral growth, Schmorl's nodes, narrowing of the intervertebral disk spaces, and premature disk degeneration [7]. Scheuermann's kyphosis develops prior to

puberty after the ossification of the vertebral ring apophysis, becoming the most prominent during the adolescent growth spurt as a structural kyphotic deformity of the thoracic or thoracolumbar spine [13]. The disease usually emerges between late juvenile and 16 years of age, commonly between the ages of 12 and 15 years [13]. The esthetic appearance/deformity of the back is the most common complaint and typically the primary cause for younger patients seeking medical attention [5]. Unfortunately, the likelihood of progression of a kyphotic curve of any given severity is presently unknown [14]. In addition to spinal deformity, these patients often experience tightness of the anterior shoulder girdle as well as the hamstring and iliopsoas muscles [15].

One of the early clinical signs of Scheuermann's disease is anterior rounded shoulders and occasionally anterior flexion contracture of the shoulder joint that leads to limited shoulder flexion [1]. Pain, when present, is usually mild and is triggered by prolonged periods of sitting or exercise, and it is generally located near the apex of the deformity. Frequently, the pain subsides with the cessation of growth. Occasionally, low back pain may be associated with spondylolisthesis, with an increased incidence in patients with Scheuermann's disease [16].

A literature search of Scheuermann's kyphosis reveals numerous shortcomings and gaps in scientific evidence. The etiology, prevalence, male-to-female ratio, and even the diagnostic criteria remain ambiguous, as detailed above. Moreover, previous studies consisted almost entirely of radiographic findings and made no attempts to correlate radiographic findings with clinical symptoms. With the introduction of digital radiography in recent years, a more accurate depiction of the radiological signs of Scheuermann's disease can be achieved. Therefore, in the present study, we aimed to evaluate the radiological pathomorphological features of the spine and the association between the thoracic kyphosis angle and the clinical presentation by assessing pain and self-perceived body image in patients with Scheuermann's disease.

We proposed two hypotheses. First, we hypothesized that there was a significant positive correlation between the thoracic kyphosis angle and the lumbar and cervical lordosis angles. Second, we postulated that a high Cobb angle of the thoracic kyphosis was associated with high levels of pain and self-perceived body image.

Materials and Methods

1. Study design

This cross-sectional analytical study was approved by the Ethical (Helsinki) Committee of the Maccabi Healthcare Services and the Thesis Committee of the Ben Gurion University of the Negev in Israel (no., 0014-16-BBL).

2. Sample

One hundred and fifty successive X-ray images of male and female patients diagnosed with Scheuermann's disease between 2009 and 2016 who were treated at the Maccabi Hashalom Posture Clinic were retrieved from the digital archives of the Maccabi Health Care Services in Tel Aviv, Israel. None of the patients were surgically treated; however, 21 patients were treated using a brace. Therefore, the study sample was considered as representative of the general population of patients with Scheuermann's disease. All patients were diagnosed by board-certified orthopedic surgeons according to the definitions by Sachs et al. [11] and referred for conservative treatment in the posture clinic. The X-ray images were obtained by specially trained technicians at the radiology departments of the Maccabi Health Care Services Centers. Lateral-view X-ray images of the whole spinal column were captured in standing position, with the patient's arms straight in a 90° shoulder flexion. Patients were instructed to stand naturally, placing equal weight on both feet.

3. Imaging data collection

The following data were collected from full spinal radiographs (Fig. 1). (1) The thoracic kyphosis angle (T3–T12) was measured using a modified Cobb method. The thoracic Cobb angle was measured from the T3 superior endplate to the T12 inferior endplate, with the upper line drawn at the superior endplate of T3 and the lower line drawn at the inferior endplate of T12. (2) The cervical lordosis (C2–C7) was measured from the C2 inferior endplate to the C7 inferior endplate using a modified Cobb method. (3) The lumbar lordosis (L1–S1) was measured using a modified Cobb method. The lumbar Cobb angle was measured from the L1 superior endplate to the S1 superior endplate, with the upper line drawn at the superior endplate of L1 and the lower line drawn at the superior

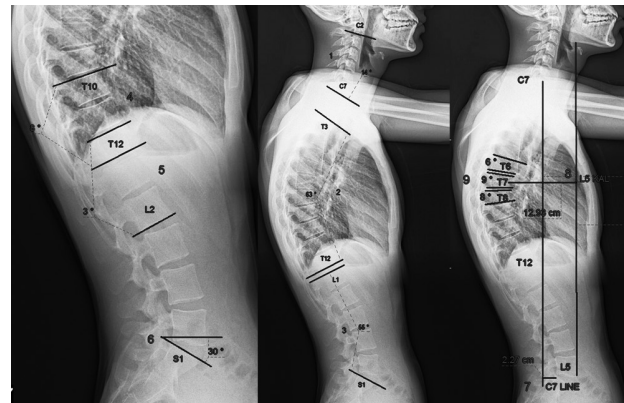


Fig. 1. Radiographic measurements. 1, cervical lordosis angle; 2, thoracic kyphosis angle; 3, lumbar lordosis angle; 4, T10–T12 Cobb angle; 5, T12–L2 Cobb angle; 6, sacral slope angle; 7, C7 plumb line; 8, L5-kyphosis apex line; 9, number and location of the anteriorly wedged vertebrae.

endplate of the sacrum (S1). (4) The sacral slope (SS) corresponded with the angle between the sacral plate and the horizontal plane. As a positional parameter, SS varied with the pelvis positioning. (5) The transitional zone (T10–T12 and T12–L2) was measured using a modified Cobb method. The transitional zone angle was measured from the T10 superior endplate to the T12 inferior endplate and from the T12 superior endplate to the L2 inferior endplate. (6) The number and location of the anterior wedged vertebrae (AWV) only $>5^\circ$, consistent with the definition of Sachs et al. [11] and the magnitude of wedging. The wedging of the vertebrae was examined using a modified Cobb method. The anterior wedging angle was measured from the superior endplate to the inferior endplate. The thoracic segment was determined by counting the number of vertebrae from L5. (7) The C7 plumb line was measured as the distance between the vertical axis of the C7 vertebral body and the sacral promontory. The C7 plumb line was measured by drawing a vertical line downward from the center of the C7 vertebral body and subsequently counting the distance between this line and the postero-superior part of the sacral promontory. (8) The thoracolumbar relative position: We evaluated the feasibility of a new radiological line for measuring the distance between the vertical axis of the L5 anterior vertebral body, the anterior border of the thoracic kyphosis apex vertebral body, and the L5 kyphosis apex line (L5-KAL). The L5-KAL is a new radiological line that has not yet been reported in the literature that evaluates the relative position between the thoracic and lumbar spine. This relative position in

patients with Scheuermann's disease can be potentially associated with the clinical features of pain, health-related quality of life, and self-perceived body image. The validity and reliability of the L5-KAL as well as its association with clinical findings will be evaluated in future studies.

4. Reliability of X-ray readings

The X-ray images were examined by a physical therapist (TB), an expert in posture and spinal deformity evaluation and treatment, with >16 years of experience evaluating spinal X-ray images. The first 15 X-ray images were examined twice, 2 weeks apart. The radiological parameters were measured for intra-rater reliability that revealed the following: 0.98 for the thoracic kyphosis angle, 0.98 for cervical lordosis, 0.96 for lumbar lordosis, 0.93 for SS, 0.98 for the T10–T12 Cobb angle, 0.99 for the T12–L2 Cobb angle, 0.94 for the number of AWV, and 0.99 for the C7 plumb line and the L5 KAL line. These ranges of intraclass correlation coefficient indicated excellent reproducibility.

5. Clinical data collection

The following data were collected from the medical files of the patients: age, sex, height (measured in a natural standing position by a Seca altimeter; Seca, Hamburg, Germany), family history (positive/negative), pediatric

developmental disorders (positive/negative), Risser sign (0–5, derived from the anteroposterior view of the pelvis), self-perceived body image (rated by the Numeric Rating Scale [NRS] from 0 to 10 [from satisfied to very dissatisfied with appearance] and the previous week's back pain rated by the Numeric Pain Rating Scale [NPRS]). A similar method of self-perceived body image was validated in other areas of medicine [17]. In addition, the NPRS was previously shown to be a valid and reliable tool for assessing pain in Scheuermann's patients [3,18].

6. Statistical analysis

All statistical analyses were performed using SPSS ver. 17.0 for Windows (SPSS Inc., Chicago, IL, USA). Means and standard deviations for age, height, thoracic kyphosis, cervical lordosis, lumbar lordosis, SS, pain, and body image were separately calculated for each sex using descriptive statistics. One-way analysis of variance was used for comparing continuous variables (age, height, thoracic kyphosis, cervical lordosis, lumbar lordosis, SS, pain, and body image) between the males and females, whereas Pearson's chi-square test was used for comparing the number of AWV and Risser sign between males and females.

Table 1. Demographic and clinical characteristics of the studied sample

Characteristic	Males (N=95)	Females (N=55)	Comparison ^{a)}		Comparison ^{b)}	
			F	<i>p</i> -value	χ^2	<i>p</i> -value
Age (yr)	15.49±2.46	1 6.73±11.66	0.990	0.321		
Height (m)	1.67±0.08	1.57±0.08	49.259	<0.001		
Thoracic kyphosis (°)	60.72±8.17	57.58±9.21	4.661	0.032		
Cervical lordosis (°)	23.87±14.27	21.51±12.70	1.006	0.318		
Lumbar lordosis (°)	63.46±9.81	11.15±60.2	3.483	0.064		
Sacral slope (°)	33.69±6.94	32.11±5.79	2.014	0.158		
Pain (Numeric Pain Rating Scale)	2.96±3.01	2.94±3.12	0.002	0.963		
Body image (Numeric Rating Scale)	5.24±3.40	4.13±3.85	2.857	0.093		
Categorical variables						
Anterior wedged vertebrae (median percentiles 25/75)	3 (2, 4)	3 (2, 4)			7.63 (6)	0.266
Risser sign (median percentiles 25/75)	4 (3, 5)	3 (1, 4)			19.12 (5)	0.002

Values are presented as mean±standard deviation or number, unless otherwise stated. Statistically significant differences (*p*<0.05) marked in bold. N, number of X-rays.

^{a)}Results of one-way analysis of variance (d.f.=1). ^{b)}Results of Pearson chi-square.

Results

The study sample included 95 males (mean age, 15.49±2.47 years) and 55 females (mean age, 16.73±11.66 years) (Table 1). The age difference between males and females was not noted to be significant ($p=0.321$). On average, the males were taller than the females (1.67±0.08 m versus 1.57±0.08 m; $p<0.001$) and the Risser sign in males (median, 4; quartiles, 3–5) was higher than that in females (median, 3; quartiles, 1–4; $p=0.002$). Sixty-three out of the 126 patients (50.00%) reported a positive family history of spinal deformities (at least for two generations), and 16 patients (12.69%) reported pediatric developmental disorders. The Cobb angle of thoracic kyphosis in males (60.72°±8.18°; range, 46°–83°) was greater than in females (57.58°±9.21°; range, 46°–86°; $p=0.032$). The associations

of the Cobb angle of thoracic kyphosis and age, height, and radiological parameters are presented in Table 2. Significant positive associations were observed between the Cobb angle of thoracic kyphosis and age ($r=0.186$, $p=0.023$), cervical lordosis ($r=0.263$, $p<0.001$), lumbar lordosis ($r=0.576$, $p<0.001$), SS ($r=0.236$, $p<0.004$), T10–T12 Cobb angle ($r=0.319$, $p<0.001$), L5-KAL ($r=0.445$, $p<0.001$), and number of AWV ($r=0.519$, $p<0.001$). No associations were found between the Cobb angle of thoracic kyphosis, T12–L2 Cobb angle, and C7 plumb line.

There was a median of 3 AWV (quartiles, 2–4) in both the male and the female patients. The average AWV numbers were 3.35 and 2.92 in males and females, respectively. The frequencies of AWV and the associated thoracic Cobb angles are presented in Table 3. The most frequent finding was the presence of two AWV (32.0%), followed by three AWV (31.3%). Only 4% of the patients had one AWV, and six and seven AWV were less frequent (3.3% and 2.0%, respectively). A significantly positive correlation was found between the number of AWV and the Cobb angle of thoracic kyphosis ($r=0.519$, $p<0.001$). Interestingly, the proportion of patients with one or two AWV was higher among the females than the males, whereas the proportion of patients with three or more AWV was higher among the males than the females. For example, two AWV were found in 41.81% and 26.32% of the females and the males, respectively, whereas three AWV were observed in 23% and 35.79% of the females and the males, respectively.

The prevalence of wedged vertebrae according to the spinal level and the average Cobb angle of the wedged vertebrae at each level are presented in Fig. 2. The AWV were most frequently observed in T7 (68%), followed by T8 (65%) and T9 (44%), whereas the AWV were least fre-

Table 2. Results of Pearson correlation analyses (univariate) between thoracic kyphosis and age, sex, height, and radiological parameters

Variable	Thoracic kyphosis	
	<i>r</i>	<i>p</i> -value
Age (yr)	0.186	0.023
Height (m)	0.128	0.153
Cervical lordosis (°)	0.263	<0.001
Lumbar lordosis (°)	0.576	<0.001
Sacral slope (°)	0.236	<0.004
T10–T12 Cobb angle (°)	0.319	<0.001
T12–L2 Cobb angle (°)	0.118	0.150
C7 line (cm)	0.032	0.696
L5-kyphosis apex line (cm)	0.445	<0.001
Anterior wedged vertebrae	0.519	<0.001

Statistically significant differences ($p<0.05$) marked in bold.

Table 3. Frequencies of AWVs associated with the thoracic Cobb angle

No. of AWVs	Average Cobb angle (°)	Total (N=150)	Females (N=55)	Males (N=95)
1	2 (2.1)	55.00	6 (4.0)	4 (7.2)
2	25 (26.3)	55.14	48 (32.0)	23 (41.8)
3	34 (35.7)	59.02	47 (31.3)	13 (23.0)
4	13 (13.6)	61.68	19 (12.7)	6 (10.9)
5	15 (15.7)	65.63	22 (14.7)	7 (12.7)
6	4 (4.2)	68.40	5 (3.3)	1 (1.8)
7	2 (2.1)	75.33	3 (2.0)	1 (1.8)

Values are presented as number (%).
AWV, anterior wedged vertebrae.

quently observed in T4 and L1 (4% for both). The average Cobb angle of the AWV varied between 6.16° and 7.64°, with no significant differences among the spinal levels. The average Cobb angles of T10–T12 and T12–L2 were 10.52° (range, 29° to -9°) and -2.82° (range, 25° to -26°), respectively.

Pain was not substantial in the study cohort (NPRS,

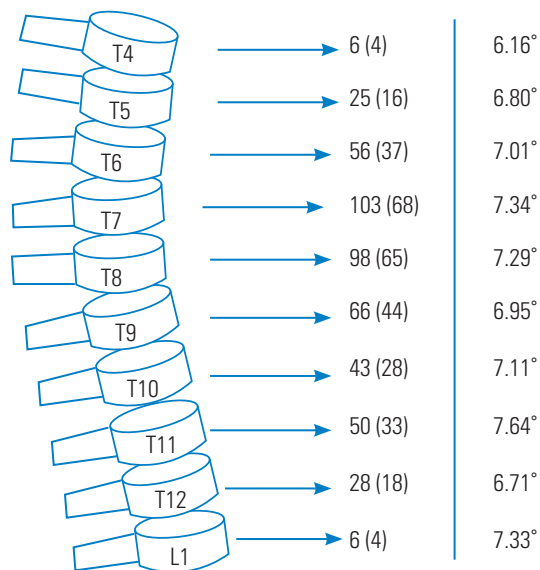


Fig. 2. Prevalence of wedged vertebrae according to the spinal level and average Cobb angle of the wedged vertebra at each level. The middle column displays the absolute number and percentage of anterior wedged (Cobb angle $\geq 5^\circ$) vertebrae. The right column displays the average anterior wedging at each spinal level. Values are presented as number (%).

2.96 \pm 3.01 in males and 2.94 \pm 3.12 in females). The self-perceived body image, determined by the NRS, albeit relatively high compared with the level of pain, was not significantly different between the males (5.24 \pm 3.39) and the females (4.13 \pm 3.85). The analysis of the associations between the clinical parameters (pain and self-perceived body image) and the radiological parameters is presented in Table 4. No significant associations were found between the NPRS and the radiological parameters except SS ($r=0.219$, $p=0.014$). Significant positive associations were observed between the self-perceived body image on the basis of the NRS and the thoracic kyphosis ($r=0.494$, $p<0.001$), the number of AWV ($r=0.361$, $p<0.001$), and the L5-KAL ($r=0.251$, $p=0.004$). Age showed a significant positive association with self-perceived body image on the basis of the NRS ($r=0.253$, $p=0.004$) and a negative association with pain on the basis of the NPRS ($r=0.329$, $p<0.001$).

Discussion

This cross-sectional study included 150 patients with Scheuermann's disease who were treated in a posture clinic at the second-largest healthcare provider in a central district of Israel. Provided that the study cohort included only patients referred for specialized physical therapy treatment, the present study was representative of patients with Scheuermann's disease in Israel. In this study, since 63.33% of the patients were males and 36.66%

Table 4. Results of Pearson correlation analyses (univariate) between clinical parameters (pain and self-perceived body image), age and radiological parameters

Variable	Pain (Numeric Pain Rating Scale)		Self-perceived body image (Numeric Rating Scale)	
	<i>r</i>	<i>p</i> -value	<i>r</i>	<i>p</i> -value
Age (yr)	-0.329	<0.001	0.253	0.004
Thoracic kyphosis (°)	0.057	0.524	0.494	<0.001
Cervical lordosis (°)	0.148	0.103	0.168	0.640
Lumbar lordosis (°)	0.02	0.826	0.155	0.083
Sacral slope (°)	0.219	0.014	0.110	0.902
T10–T12 Cobb angle (°)	0.440	0.627	0.118	0.185
T12–L2 Cobb angle (°)	0.480	0.592	0.860	0.335
C7 line (cm)	0.137	0.125	0.320	0.723
L5-kyphosis apex line (cm)	0.140	0.875	0.251	0.004
Anterior wedged vertebrae	0.116	0.196	0.361	<0.001

Statistically significant differences ($p<0.05$) marked in bold.

were females, the male-to-female ratio of 1.72:1 provides further support for the consensus male-to-female ratio of 2:1 reported by Murray et al. [7], who conducted a 32-year follow-up study of 67 patients with Scheuermann's disease, and Damborg et al. [9], who performed a survey study of 943 twins diagnosed with Scheuermann's disease. Conversely, other studies of patients with Scheuermann's disease treated with the Milwaukee brace reported male-to-female ratios of 1:2 [5] or 1:1 [6]. One possible explanation of this variability is that females may be more willing to wear a brace for the Scheuermann's kyphosis.

The normal angle of thoracic kyphosis (T3–T12) ranges between 25° and 45° as measured using the Cobb method on a standing lateral radiograph, with the arms at 45° below the horizontal plane [12]. In the present study, the thoracic kyphosis angles were $60.72 \pm 8.18^\circ$ and $57.58 \pm 9.21^\circ$ in males and females, respectively, which were slightly lower than those reported by Hosman et al. [19] ($78.7 \pm 8.9^\circ$) and Lowe and Kasten [4] (85°; range, 75°–105°). The subjects in two previous studies had severe Scheuermann's disease and were candidates for surgery [4,19]. Interestingly, in normal subjects, the kyphosis angle is slightly greater in females than in males [12].

Normal limits of cervical lordosis range from -20° to -35° for the C2–C7 vertebrae [20]. Normal lumbar lordosis considerably varies, with normal values ranging from -30° to -80° [21]. The transitional zone between the thoracic and lumbar spine includes the T10–L2 vertebrae, which are normally slightly lordotic (0° to 10°) [11,12]. Patients with Scheuermann's disease frequently demonstrate a compensatory hyperlordosis of the lumbar and cervical spine [22]. We also found mild, albeit significant, positive correlations between thoracic kyphosis and cervical lordosis, consistent with the findings by Hardacker et al. [23] and Erkan et al. [24]. They determined that cervical and thoracic sagittal curves appeared to compensate each other. In contrast, Helsing et al. [25] found no such correlation; however, all the subjects in their study were children. We also found a moderate positive correlation between thoracic kyphosis and lumbar lordosis. The lumbar deformity is usually flexible and expressed in the anterior translation of the lumbar section (i.e., swayback), which is very common in patients with Scheuermann's disease [15] and can be dramatically influenced by the relative position of the thoracic and lumbar spine (transitional zone) [26].

This is the first study that specifically describes the

number and prevalence of AWV in patients with Scheuermann's disease (Table 3, Fig. 2). The patients with one AWV comprised only 4% of the study cohort, with an average thoracic Cobb angle of 55°. We, therefore, agree with the definition of Scheuermann's disease by Sachs et al. [11], which states that at least one wedged vertebra with a minimum angle of 5° and a thoracic kyphosis of $>45^\circ$ (T3–T12) is present in patients with Scheuermann's disease. We also observed a positive association between the number of AWV and the average thoracic kyphosis angle. Most of the patients ($>60\%$) had two or three AWV, whereas patients with one, six, or seven AWV were very rare ($<4\%$ each). Interestingly, the female patients with Scheuermann's kyphosis had an average of one or two AWV, whereas the male patients with Scheuermann's kyphosis had an average of three to seven AWV (Table 3).

In their segmental analysis of thoracic kyphosis, Bernhardt and Bridwell [12] found that the vertebral Cobb angle increased incrementally with each segment, starting from T1 to the apex of the kyphosis, centering around T6–T7 (with an average kyphosis angle of approximately 5° in several segments [T4–T8]). In the present study, the general pattern was similar; however, the most frequent AWV were T7 (68%), T8 (65%), and T9 (44%). The segmental Cobb angle ranged between 6.16° and 7.64°. The vertebrae with the highest average Cobb angle were T11 (7.64°), T7 (7.34°), and L1 (7.33°). These findings represent the classical thoracic pattern of Scheuermann's disease [21]. Conversely, the highest average Cobb angles in T11 and L1 were found in individuals with the less common form of type 2 Scheuermann's kyphosis (thoracolumbar pattern or 'apprentice kyphosis,' 10%–15% of all patients with Scheuermann's disease). Type 2 kyphosis is characterized by AWV in the thoracolumbar area and is the most likely type to progress in adulthood [27].

We found a moderate positive correlation between the Cobb angle of thoracic kyphosis and the L5-KAL. No statistically significant association was noted between the thoracic kyphosis and the C7 plumb line. The C7 plumb line is a standard radiological line used in the analysis of the sagittal balance. When the spine is balanced in the sagittal plane, the vertical axis of the C7 vertebral body should lie within 2 cm from the sacral promontory. Patients with Scheuermann's disease tend to be negatively balanced compared with the general population. In these patients, the vertical axis of the C7 vertebral body lies behind the sacral promontory. In some patients with full

compensation between the thoracic kyphosis and the lumbar lordosis, the C7 plumb line can be normal despite a severe thoracic hump and an apparent body image compromise. The L5-KAL illustrates the balance between the lumbar spine vertebrae and the apex of the thoracic vertebrae. The positive associations of the L5-KAL with the thoracic kyphosis and the NRS, which reflects the self-perceived body image, illustrate the advantage of L5-KAL over the standard C7 plumb line in kyphotic patients. We, therefore, suggest L5-KAL for the evaluation of the relative position between the thoracic and lumbar spine for assessing the progression of Scheuermann's disease. This new method was developed on the basis of our clinical experience and has not been described in the literature.

The transitional zone (T10–T12 and T12–L2), first reported by Bernhardt and Bridwell [12], is an important consideration for the diagnosis of Scheuermann's disease and aids in estimating the risk of kyphosis progression. In their study conducted on normal subjects, the authors found that the mean Cobb angle of kyphosis in T10–T12 was 5.5°, ranging from –3° lordosis to 20° kyphosis. They also found that the mean Cobb angle of lordosis in T12–L2 was –3°, ranging from –23° lordosis to 13° kyphosis [12]. In the present study, the mean Cobb angle of kyphosis in T10–T12 was 10.52°, ranging from –9° lordosis to 29° kyphosis, whereas the mean Cobb angle of lordosis in T12–L2 was –2.82°, ranging from –26° lordosis to 25° kyphosis. These results illustrate the difference in the sagittal balance between normal subjects and patients with Scheuermann's disease, as exemplified by this important transitional zone. The mild positive association between the T10–T12 Cobb angle and thoracic kyphosis demonstrates the direct association between these two areas, since T10–T12 represents the lower part of the thoracic kyphosis curve. Conversely, we found that the T12–L2 Cobb angle, which represents the upper part of the lumbar lordosis, was not associated with thoracic kyphosis. On the basis of our experience, this zone is very sensitive to changes in the sagittal plane, especially during sports activities, and can play an important role in predicting the risk of kyphosis progression.

The mild positive association between the SS and the thoracic kyphosis is in agreement with the findings of Peleg et al. [28], who found that the sacrum was significantly more horizontally oriented in the patients with Scheuermann's disease compared with the control subjects. We agree with their conclusions that alteration

in spinal biomechanics due to a horizontally oriented sacrum may be a significant contributing factor for the development of Scheuermann's kyphosis [28]. One reason for a high degree of SS in patients with Scheuermann's disease may be the compensation of the pelvis caused by lumbar hyperlordosis.

Although the pain was not substantial in the study cohort (NPRS, <3 out of 10 in both the males and the females). In contrast, a self-perceived body image, assessed by the NRS, was relatively high in both the males (5.24±3.39) and the females (4.13±3.85). Significant positive associations were found between the self-perceived body image and the radiological markers of Scheuermann's disease, including the thoracic kyphosis angle, number of AWV, and L5-KAL. These findings concur with those of Bradford et al. [5], who concluded that spinal deformity and its esthetic appearance, not pain, were the most common complaints and the primary reason for younger patients seeking medical attention. Moreover, Ogilvie and Sherman [16] suggested that pain in patients with Scheuermann's disease, when present, was generally mild and precipitated by prolonged periods of sitting or exercise and was frequently located near the apex of the deformity. Generally, the pain experienced by these patients subsides with the cessation of growth. In their 32-year follow-up study, Murray et al. [7] reported that patients with Scheuermann's disease endured more pain than the control group. The pain symptoms, however, did not interfere with the activities of daily living or employment. Similarly, a recent study by Ristolainen et al. [3] indicated that patients with Scheuermann's disease had a higher risk of back pain than the controls.

We propose that self-perceived body image, which has been underestimated by numerous studies, is nonetheless a very important issue for patients with Scheuermann's disease, most of whom are in puberty or post-pubertal age. Numerous studies examining the psychological impact of scoliosis and kyphosis indicate that patients with scoliosis have a negative body image perception, are more likely to report being less healthy, are more worried that their body was abnormally developing, and exhibit a greater concern regarding the quality of peer relationships [29,30]. In our experience, these concerns are also valid for patients with Scheuermann's kyphosis; therefore, future studies conducted on these patients should take into account and thoroughly examine this parameter.

Conclusions

The present cross-sectional analytical study presenting the detailed radiological and clinical examination of patients with Scheuermann's disease found that the thoracic kyphosis angle was significantly greater in males ($60.72^\circ \pm 8.18^\circ$) than in females ($57.58^\circ \pm 9.21^\circ$) and was significantly associated with cervical and lumbar lordosis, SS, the T10–T12 Cobb angle, the L5-KAL, and the number of AWV. We also found a positive correlation between the thoracic kyphosis angle and the L5-KAL. Positive associations of the L5-KAL with the thoracic kyphosis and the self-perceived body image, determined by the NRS, demonstrated the advantages of L5-KAL as a parameter over the standard C7 plumb line in kyphotic patients. Additional longitudinal studies investigating the utility of L5-KAL in other sample populations are required to validate this tool and assess its utility in monitoring the progression of spinal deformity in patients with Scheuermann's disease.

Pain was not significant in the study sample, whereas self-perceived body image was the most common complaint of patients with Scheuermann's disease (5.24 ± 3.39 in males and 4.13 ± 3.85 in females). The self-perceived body image was significantly associated with the thoracic kyphosis angle, the number of AWV, and the L5-KAL. These findings suggest that clinicians who treat patients with Scheuermann's disease based on radiological indices should also assess self-perceived body image, a parameter that is considered to be crucial in these patients. Further studies examining the etiology of Scheuermann's disease, risk factors, progression, and markers are vital for the early detection of the disease. Studies on the association between the clinical and radiological features are also crucial.

Conflict of Interest

No potential conflict of interest relevant to this article was reported.

ORCID

Tomer Bezalel: <https://orcid.org/0000-0002-5183-7885>

Eli Carmeli: <https://orcid.org/0000-0002-1704-112X>

Leonid Kalichman: <https://orcid.org/0000-0003-2987-4396>

Author Contributions

Tomer Bezalel: preparation of research plan, data collection, data interpretation, and drafting the manuscript; Eli Carmeli: preparation of research plan, data interpretation, and reviewing the manuscript; Leonid Kalichman: preparation of research plan, data analysis, and reviewing the manuscript; and all authors reviewed and approved the final version of the manuscript.

References

- Holt RT, Dopf CA, Isaza JE. Adult kyphosis. In: Frymoyer JW, editor. *The adult spine: principles and practice*. Philadelphia (PA): Lippincott Williams & Wilkins; 1997. p. 1537-8.
- Sorensen KH. *Scheuermann's juvenile kyphosis: clinical appearances, radiography, aetiology and prognosis*. Copenhagen: Munksgaard; 1964.
- Ristolainen L, Kettunen JA, Heliövaara M, Kujala UM, Heinonen A, Schlenzka D. Untreated Scheuermann's disease: a 37-year follow-up study. *Eur Spine J* 2012;21:819-24.
- Lowe TG, Kasten MD. An analysis of sagittal curves and balance after Cotrel-Dubousset instrumentation for kyphosis secondary to Scheuermann's disease: a review of 32 patients. *Spine (Phila Pa 1976)* 1994;19:1680-5.
- Bradford DS, Moe JH, Montalvo FJ, Winter RB. Scheuermann's kyphosis and roundback deformity: results of Milwaukee brace treatment. *J Bone Joint Surg Am* 1974;56:740-58.
- Montgomery SP, Erwin WE. Scheuermann's kyphosis: long-term results of Milwaukee braces treatment. *Spine (Phila Pa 1976)* 1981;6:5-8.
- Murray PM, Weinstein SL, Spratt KF. The natural history and long-term follow-up of Scheuermann kyphosis. *J Bone Joint Surg Am* 1993;75:236-48.
- Scheuermann HW. Kyphosis dorsalis juvenilis. *Z Orthop Chir* 1921;41:305-7.
- Damborg F, Engell V, Nielsen J, Kyvik KO, Andersen MO, Thomsen K. Genetic epidemiology of Scheuermann's disease. *Acta Orthop* 2011;82:602-5.
- Ali RM, Green DW, Patel TC. Scheuermann's kyphosis. *Curr Opin Pediatr* 1999;11:70-5.
- Sachs B, Bradford D, Winter R, Lonstein J, Moe J, Willson S. Scheuermann kyphosis: follow-up of

- Milwaukee-brace treatment. *J Bone Joint Surg Am* 1987;69:50-7.
12. Bernhardt M, Bridwell KH. Segmental analysis of the sagittal plane alignment of the normal thoracic and lumbar spines and thoracolumbar junction. *Spine (Phila Pa 1976)* 1989;14:717-21.
 13. Bick EM, Copel JW. The ring apophysis of the human vertebra; contribution to human osteogeny. II. *J Bone Joint Surg Am* 1951;33-A:783-7.
 14. Otsuka NY, Hall JE, Mah JY. Posterior fusion for Scheuermann's kyphosis. *Clin Orthop Relat Res* 1990;251:134-9.
 15. Somhegyi A, Ratko I. Hamstring tightness and Scheuermann's disease: commentary. *Am J Phys Med Rehabil* 1993;72:44.
 16. Ogilvie JW, Sherman J. Spondylolysis in Scheuermann's disease. *Spine (Phila Pa 1976)* 1987;12:251-3.
 17. Larsson P, John MT, Nilner K, List T. Reliability and validity of the Orofacial Esthetic Scale in prosthodontic patients. *Int J Prosthodont* 2010;23:257-62.
 18. Weiss HR, Dieckmann J, Gerner HJ. Effect of intensive rehabilitation on pain in patients with Scheuermann's disease. *Stud Health Technol Inform* 2002;88:254-7.
 19. Hosman AJ, Langeloo DD, de Kleuver M, Anderson PG, Veth RP, Slot GH. Analysis of the sagittal plane after surgical management for Scheuermann's disease: a view on overcorrection and the use of an anterior release. *Spine (Phila Pa 1976)* 2002;27:167-75.
 20. Gore DR, Sepic SB, Gardner GM. Roentgenographic findings of the cervical spine in asymptomatic people. *Spine (Phila Pa 1976)* 1986;11:521-4.
 21. Been E, Kalichman L. Lumbar lordosis. *Spine J* 2014;14:87-97.
 22. Jansen RC, van Rhijn LW, van Ooij A. Predictable correction of the unfused lumbar lordosis after thoracic correction and fusion in Scheuermann kyphosis. *Spine (Phila Pa 1976)* 2006;31:1227-31.
 23. Hardacker JW, Shuford RE, Capicotto PN, Pryor PW. Radiographic standing cervical segmental alignment in adult volunteers without neck symptoms. *Spine (Phila Pa 1976)* 1997;22:1472-80.
 24. Erkan S, Yercan HS, Okcu G, Ozalp RT. The influence of sagittal cervical profile, gender and age on the thoracic kyphosis. *Acta Orthop Belg* 2010;76:675-80.
 25. Hellsing E, Reigo T, McWilliam J, Spangfort E. Cervical and lumbar lordosis and thoracic kyphosis in 8, 11 and 15-year-old children. *Eur J Orthod* 1987;9:129-38.
 26. Jiang L, Qiu Y, Xu L, et al. Sagittal spinopelvic alignment in adolescents associated with Scheuermann's kyphosis: a comparison with normal population. *Eur Spine J* 2014;23:1420-6.
 27. Blumenthal SL, Roach J, Herring JA. Lumbar Scheuermann's: a clinical series and classification. *Spine (Phila Pa 1976)* 1987;12:929-32.
 28. Peleg S, Dar G, Steinberg N, Masharawi Y, Hershkovitz I. Sacral orientation and Scheuermann's kyphosis. *Springerplus* 2016;5:141.
 29. Sapountzi-Krepia DS, Valavanis J, Panteleakis GP, Zangana DT, Vlachojiannis PC, Sapkas GS. Perceptions of body image, happiness and satisfaction in adolescents wearing a Boston brace for scoliosis treatment. *J Adv Nurs* 2001;35:683-90.
 30. Payne WK 3rd, Ogilvie JW, Resnick MD, Kane RL, Transfeldt EE, Blum RW. Does scoliosis have a psychological impact and does gender make a difference? *Spine (Phila Pa 1976)* 1997;22:1380-4.