

# Jain point: A new safe portal for laparoscopic entry in previous surgery cases

Nutan Jain, Sweta Sareen,  
Swati Kanawa,  
Vandana Jain,  
Sunil Gupta, Sonika Mann  
Vardhman Infertility  
and Endoscopy Centre,  
Muzaffarnagar, Uttar Pradesh,  
India

**Address for correspondence:**  
Dr. Nutan Jain,  
Vardhman Infertility  
and Endoscopy Centre,  
A-36, South Civil  
Lines, Mahavir Chowk,  
Muzaffarnagar - 251 001,  
Uttar Pradesh, India.  
E-mail: jainnutan@gmail.com

Received: 29.09.2015  
Review completed: 05.10.2015  
Accepted: 22.02.2016

## ABSTRACT

**INTRODUCTION:** The present study was performed to assess the safety and feasibility of a new laparoscopic entry site in cases suspected of adhesions due to previous surgery. **MATERIALS AND METHODS:** It is a retrospective study undertaken at a tertiary care referral center for advanced gynecological laparoscopic surgery from January 2011 to December 2014. **RESULTS:** In 624 patients with a history of previous abdominal surgeries, the laparoscopic entry site was through a newly devised point. It is a point in the left paraumbilical region at the level of umbilicus, in a straight line drawn vertically upward from a point 2.5 cm medial to anterior superior iliac spine. Intra-abdominal adhesions were found in 487 (78.0%) patients, and umbilical adhesions in 404 (64.7%) patients with past abdominal surgeries. **CONCLUSION:** There were no significant entry-related, intra-operative, or postoperative complications with the use of this entry point. It is also suitable as a main working port during the course of surgery.

**KEY WORDS:** Laparoscopy, palmer's point, periumbilical adhesions, primary port

## INTRODUCTION

As advances in laparoscopic skills and instrumentation evolve, increasingly complex procedures are being performed, yet most complications are associated with primary access. Gaining access into the abdomen has been the challenging issue in terms of complications. Access is associated with injuries to the gastrointestinal tracts and major blood vessels, and at least 50% of these occur prior to commencement of the intended surgery.<sup>[1]</sup> Risk increases in cases with previous surgery. Postsurgical adhesions occur in 70–95% of patients undergoing major gynecologic surgery.<sup>[2,3]</sup> The overall incidence of major injuries at the time of entry is 1.1/1000.<sup>[4]</sup> Bowel injuries have occurred in 0.7/1000 laparoscopies<sup>[4]</sup> and major vascular injuries in 0.4/1000 laparoscopies.<sup>[4]</sup> Despite considerable advances in endoscopic techniques and instrumentation, inadvertent and potentially avoidable entry injuries continue to occur.

Routinely, primary trocar is placed at umbilical level, but an alternate entry site is recommended when umbilical placement of a primary trocar is deemed hazardous, like in cases with previous abdominal surgery. The

present study aims to introduce a new access point as a safe primary port in previous abdominal surgery cases. Further, in the text, we would refer to this new point as the "Jain point," a nomenclature fondly coined by fellows and trainees in our center. The Jain point is located in the left paraumbilical region at the level of umbilicus, in a straight line drawn vertically upward from a point 2.5 cm medial to anterior superior iliac spine (ASIS).

The universally preferred point of entry in previous surgery cases is the Palmer's point developed by Palmer.<sup>[5]</sup> Palmer's point lies 3 cm below the left subcostal margin in the mid-clavicular line. Many authors have described it as arguably the safest alternative insertion site for peritoneal access in women

This is an open access article distributed under the terms of the Creative Commons Attribution-NonCommercial-ShareAlike 3.0 License, which allows others to remix, tweak, and build upon the work non-commercially, as long as the author is credited and the new creations are licensed under the identical terms.

**For reprints contact:** reprints@medknow.com

**How to cite this article:** Jain N, Sareen S, Kanawa S, Jain V, Gupta S, Mann S. Jain point: A new safe portal for laparoscopic entry in previous surgery cases. *J Hum Reprod Sci* 2016;9:9-17.

### Access this article online

Quick Response Code:



### Website:

www.jhronline.org

### DOI:

10.4103/0974-1208.178637

having undergone earlier abdominal surgeries.<sup>[6-8]</sup> Palmer's point is a safe access port, but it is not used much during the later course of surgery due to its anatomically higher location. While Jain point being lower and lateral in position, can be used as the main operating port throughout the surgery. Jain point has been consistently found to be free of adhesions in this study. Moreover, Jain point can be used for safe access even in patients with previous splenic or gastric surgery, hepatosplenomegaly, portal hypertension, and gastropancreatic masses which have to be excluded when using Palmer's point.<sup>[9]</sup>

The area between the anterior axillary line and the mid-clavicular line, between the Palmer's point and up to an inch beneath the umbilicus is an area in which the 5-mm trocar can be placed safely without the risk of vascular injury [Figure 1].

## MATERIALS AND METHODS

Data of patients with a history of previous abdominal or pelvic surgery who underwent laparoscopic surgery at our center from January 2011 to December 2014 were collected. The history and previous operative notes were carefully recorded. Patients' age, body mass index (BMI), indication of previous surgery (gynecologic or nongynecologic), mode of previous surgery (open or laparoscopic), and incision of previous surgery were tabulated.

Prior surgical incisions included midline vertical incisions, paramedian incisions, and laparoscopic ports. Other incisions included open appendectomy incision (McBurney's or gridiron or Lanz incision), open cholecystectomy incision (upper right subcostal and Kocher's incision), incisions for renal surgeries, and nonclassical incisions such as previous drain sites, colostomy sites, bizarre vertical incisions extending from epigastrium up to pubic symphysis in prior surgery for intestinal obstruction, septicemia, and

other complex pathologies. Two patients had suffered burst abdomen in previous surgery and very thick multiple scars over the abdomen due to delayed, prolonged healing.

Cases with multiple surgeries were counted only once when tabulating data for indication of surgery and type of incision. For instance, if patient had undergone laparotomy with right paramedian incision and a cesarean section with Pfannenstiel incision, only right paramedian incision was considered, as probability of having paraumbilical adhesions are more with this type of surgery and incision. This was done in order to avoid inflation of data.

Complications were defined as events that significantly prolonged or altered the planned procedure, delayed discharge, or lead to a prolongation of convalescence. Complications directly related to the entry technique that occurred intraoperatively, and discovered either immediately or up to 2 weeks postoperatively, were recorded.

## Technique

### Preoperative preparation

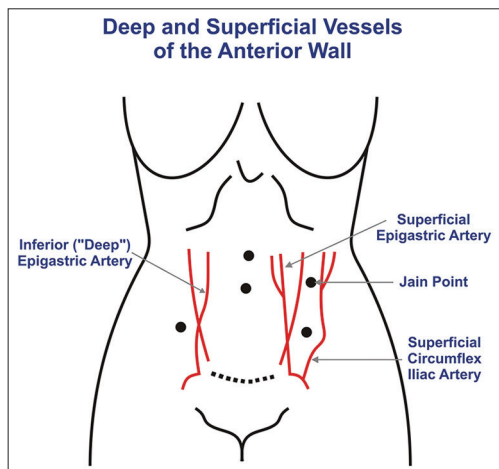
The preoperative preparation comprised low residual diet for 48 h prior to surgery and mechanical bowel preparation in all previous open surgery cases. The stomach was emptied of secretions and air by the use of orogastric tube by anesthetist, after endotracheal intubation.

### Surgical technique

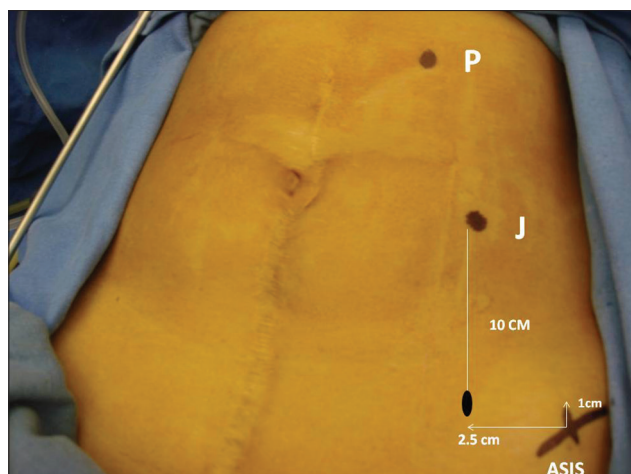
First and foremost, the whole abdomen is inspected, and all incision sites are carefully noted. Then the upper abdomen is palpated for hepatosplenomegaly. Jain point is marked at the level of umbilicus (paraumbilical) on the left side where usually the operating surgeon stands. Jain point is placed in a straight line drawn vertically upward from a lower point which is 2.5 cm medial to ASIS [Figure 2]. Pneumoperitoneum is created through Jain point via Veress needle [Figure 3].

### Veress needle insertion

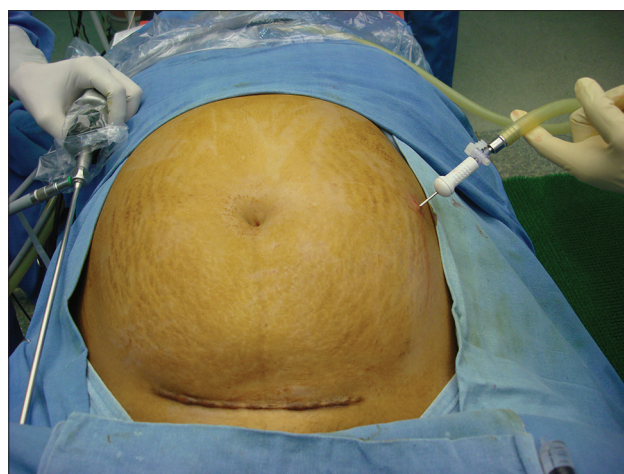
We keep the patient in supine position and have the table height adjusted for the surgeon. Place the left hand over the left middle quadrant around the Jain point, make the skin taut between the index and middle finger, and enter the Veress needle in a straight direction. It is important to hold the Veress needle in such a manner to control the length of the needle going inside the abdominal wall in the first go. This length is estimated by patient's BMI and abdominal wall fat as assessed on inspection of the abdomen. The abdominal wall is not elevated for Veress needle entry. All safety checks for Veress needle entry such as aspiration, saline injection, reaspiration, and drop test are done.<sup>[10]</sup> we routinely use long Veress needle for overweight patients with central obesity. Then, CO<sub>2</sub> insufflation is started. The most important test is the low initial Veress needle



**Figure 1:** Jain point in relation to abdominal wall blood supply



**Figure 2:** Palmer's point (P), Jain point (J), and anterior superior iliac spine. Patient has midline vertical scar extending from xiphisternum to just above pubic symphysis. Palmer's point is in midclavicular line, 3 cm below subcostal margin. Jain point lies in the left paraumbilical region, in a straight line drawn vertically upward from a point 2.5 cm medial and 1 cm above anterior superior iliac spine



**Figure 3:** Veress needle entry at Jain point. Patient has previous transverse incision

intra-peritoneal pressure, which should not be more than 8 mmHg for initial 10 seconds, as also supported by Vilos.<sup>[11]</sup> After confirming safe entry by above all tests of Veress needle, the intra-peritoneal pressure is transiently raised to 25 mmHg and 5 mm trocar is inserted through the Jain point when the total volume of CO<sub>2</sub> insufflation is around 3–4 L [Figure 4]. This transient high-pressure pneumoperitoneum in horizontal position produces greater splinting of abdominal wall, so allows a safer trocar insertion and does not compromise patient's cardiopulmonary functions. Once the 5 mm trocar is safely in, we introduce a 5 mm, 0° telescope, then we routinely do a 360° inspection of abdominal cavity to check for adhesions. The basic aim of making entry from Jain point is to avoid abdominal and umbilical adhesions. After confirming safe entry, the entry for the 10 mm 30° telescope is optimized according to the mandate of the case. This entry can be anywhere between the umbilicus and xiphisternum according to the pelvic pathology, size of masses, and adhesion sites. It is safe to introduce the 10 mm port under the direct visual guidance of 5 mm telescope introduced through Jain point.

After introducing the 10 mm port, safe abdominal entry of the 5 mm trocar through Jain point is also confirmed. Then lower right and left ports are inserted 2.5 cm medial and 1 cm above the ASIS under vision. The distance of the left lower port from the Jain point is around 10–12 cm. This distance of 10–12 cm gives a good ergonomic working, and these become the main operating ipsilateral ports.

## RESULTS

Of the total 2834 laparoscopic cases done between January 2011 and December 2014, 624 cases had previous

one or multiple surgeries. The mean patients' age was 33.5 years (range: 14–70 years) and mean BMI was 24.48 kg/m<sup>2</sup> (range: 12.9–46.9 kg/m<sup>2</sup>).

The previous surgery cases, which we have dealt, include wide variety of cases with 86.37% cases (539 out of 624) of gynae indication and 13.63% cases (85 out of 624) of general surgery. In the gynae group, 54.4% (293 out of 539) had previous laparotomy, and 45.6% (246 out of 539) had previous laparoscopic procedures. In the laparotomic approach, cesarean sections were the most common, i.e., 53.5% (157 out of 293). These previous cesarean sections were encountered in 40.7% (64 out of 157) cases for secondary infertility and 35.03% cases (55 out of 157) for total laparoscopic hysterectomy. Previous cesarean cases showed an alarming rate of adhesions, abdominal wall adhesions were present in 89% cases, and total adherence of the uterus itself to the anterior abdominal wall was noted in 11% cases. The advent of the technique of single layer closure and leaving the visceral and parietal peritoneum unstitched could have led to greater adhesions. Next most common indication was previous ectopic pregnancy either by laparotomy (13.65%, i.e., 40 out of 293) or by laparoscopy (19.9%, i.e., 49 out of 246). This was a formidable group for adhesions as laparotomy was usually done in ruptured ectopic cases with intraperitoneal hemorrhage. In this indication, laparoscopy cases were still better for adhesion score. Endometriosis, as is shown in the table, with very extensive obliteration of pouch of Douglas and endometriomas has been a very frequent surgery with the previous open approach as well as laparoscopy bizarre adhesions have been noted, in repeat laparoscopy. Myomectomy again had a very advanced adhesion score. Adhesions at entry point were noted in both open and laparoscopic myomectomy. Cases with previous surgery for infectious pathologies such as genital Koch's and septic abortion were also encountered with lots of intra-abdominal

and pelvic adhesions. The other indications where we did laparoscopy were in cases of previous pelvic floor repairs and microsurgical tubo tubal reanastomosis. Hence, we employed the Jain point in wide variety of cases with different and practically all types of scars in upper and lower abdomen and multiple scars.

In nongynae cases, 67.1% cases (57 out of 85) cases had previous surgery by open route and 37.3% (28 out of 75) cases by laparoscopic route. Maximum were gall bladder removals, appendectomy, and few with previous mesh hernia repairs. Mesh hernia repairs pose specific challenge, and previous notes need to be studied carefully. Many cases of intestinal obstruction which were done in childhood and due to abdominal Koch's have also been dealt. These have long vertical incisions extending from high up in abdomen going down up to pubic symphysis. Many of the cases had bowel perforations, and multiple drain sites noted over the abdomen. We have also experienced two cases of Hirschsprung disease and two cases of high imperforate anus which were managed in infancy by colostomy and then colon pull through procedure. Hence, in nongynae group, we dealt extensive

pathologies with high potential of intra-abdominal adhesions [Table 1 and Pie Diagrams 1-4].

A total of 209 (33.5%) patients had midline or paramedian incisions, 120 (19.2%) had Pfannenstiel incisions, 242 (38.8%) had laparoscopic ports, and 53 (8.5%) had other incisions [Table 2]. Of 624 subjects, 177 (28.4%) had more than one previous surgery, either open or laparoscopic or both [Table 3]. As we earlier stated that these cases were counted only once for the surgery, which had more chance of adhesions.

Intra-abdominal adhesions were found in a significant majority, i.e., 487 (78.0%) of previous surgery cases. Adhesions in the umbilical region were found in 404 (64.7%) patients with previous abdominal surgeries [Figure 5]. No significant entry-related complications were reported in the present study with the use of Jain point as primary port. There were no injuries to superficial or deep vessels of anterior abdominal wall. There was no hematoma formation at the port site. No vascular or intestinal injury was encountered intraoperatively. All patients were discharged within 24–48 h of surgery as per the hospital

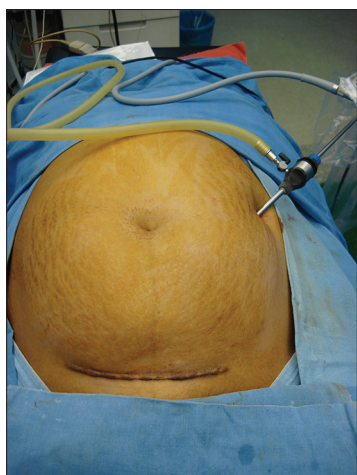

Figure 4: Primary port at Jain point

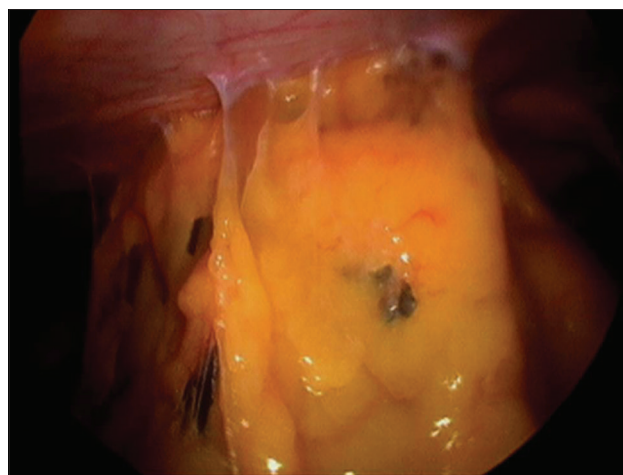
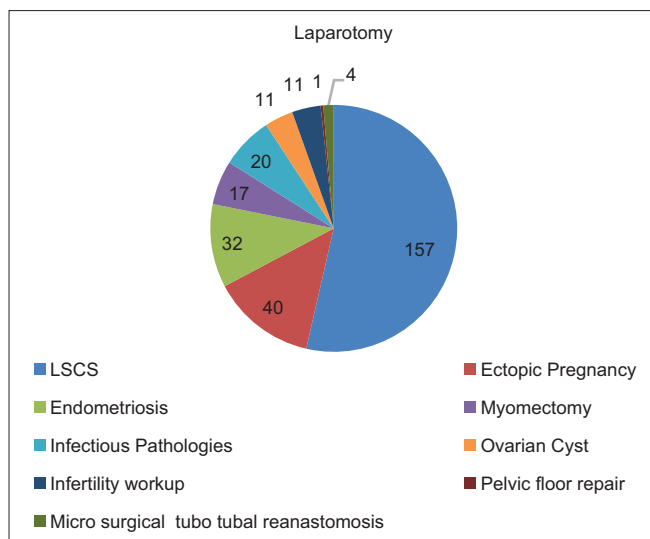


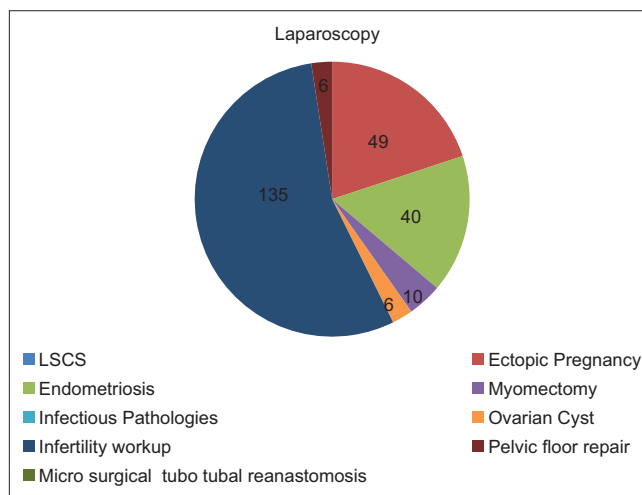
Figure 5: Postsurgical omental adhesion in umbilical region

Table 1: Patients' profile depending on type and indication of previous abdominal surgery

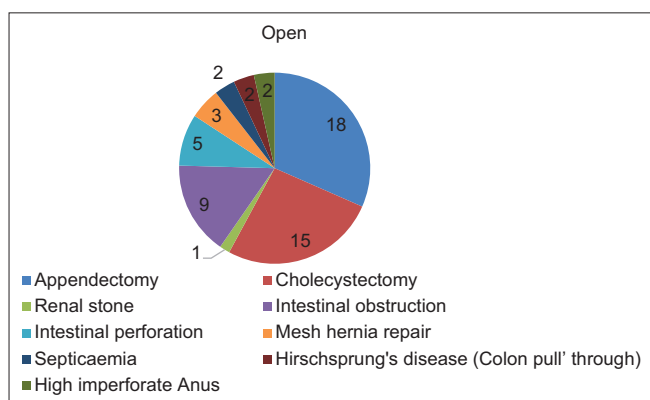
Indications of previous surgery	Previous gynae surgeries		Indications of previous surgery	Previous nongynae/surgeries	
	Laparotomy	Laparoscopy		Open	Laparoscopy
Lower segment cesarean section	157	0	Appendectomy	18	14
Ectopic pregnancy	40	49	Cholecystectomy	15	12
Endometriosis	32	40	Renal stone	1	0
Myomectomy	17	10	Intestinal obstruction	9	0
Infectious pathologies	20	0	Intestinal perforation	5	0
Ovarian cyst	11	6	Mesh hernia repair	3	2
Infertility workup	11	135	Septicaemia	2	0
Pelvic floor repair	1	6	Hirschsprung's disease	2	0
			Colon pull' through		
Microsurgical tubo tubal reanastomosis	4	0	High imperforate anus	2	0
Total	293	246	Total	57	28



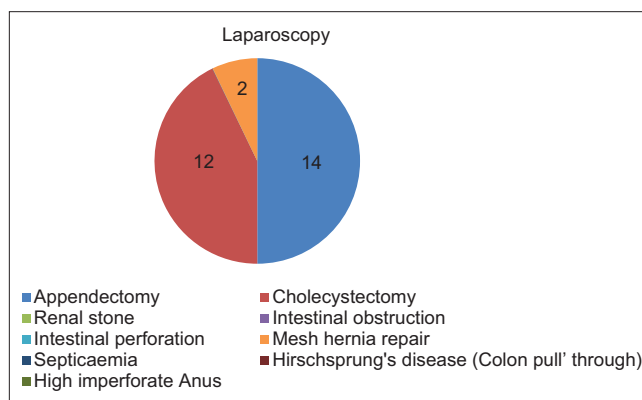
**Pie Diagram 1:** Patient profile based on type and indications of previous open gynaecological surgery



**Pie Diagram 2:** Patient profile based on type and indications of previous laproscopic gynaecological surgery



**Pie Diagram 3:** Patient profile based on type and indications of previous open non gynaecological surgery



**Pie Diagram 4:** Patient profile based on type and indications of previous laproscopic non gynaecological surgery

**Table 2: Patients' profile depending on type of previous surgical incision**

Type of prior surgical incision	Year				Total
	2014	2013	2012	2011	
Midline and paramedian incisions	62	55	50	42	209
Pfannenstiel incision	35	30	28	27	120
Laparoscopic port	60	54	78	50	242
Other incisions	16	13	11	13	53
Total	173	152	167	132	624

protocol. No patient needed any extra hospital stay due to any entry-related issues.

## DISCUSSION

A primary port is the first entry site through which a laparoscope is introduced. The most important and potentially dangerous first step in laparoscopy is the safe and successful insertion of a primary port since half the

complications with laparoscopy occur even before the start of the intended procedure.<sup>[1]</sup> Injuries may occur by advancing the instruments toward the posterior abdominal wall and encountering anatomically normal but distended bowel (Type 1 injuries) or due to visceral adhesions to the anterior abdominal wall (Type 2 injuries).

The reported incidence of intra-abdominal adhesions after laparotomy ranges between 30% and 90%.<sup>[12-14]</sup> Even patients with one previous laparoscopic procedure have been found to have both omentum and bowel adhesions beneath the umbilicus and port sites due to valsalva or accidental suturing. Royal College of Obstetricians and Gynecologists guideline on preventing entry-related gynecological laparoscopic injuries states: "The umbilicus may not, therefore, be the most appropriate site for primary trocar insertion following previous abdominal surgery."<sup>[15]</sup> For this reason, alternative primary approaches to laparoscopic surgery have been introduced for use in patients with a history of laparotomy.<sup>[16-19]</sup>

**Table 3: Patients' profile depending on number of previous abdominal surgeries**

Number of previous abdominal surgeries	Year (%)				Total (%)
	2014	2013	2012	2011	
One	110 (63.4)	107 (70.39)	135 (80.83)	95 (71.91)	447 (71.6)
Two	38 (1.96)	27 (17.76)	25 (14.97)	28 (21.21)	118 (18.91)
Three	15 (8.67)	10 (6.57)	05 (2.29)	07 (5.30)	37 (5.9)
Four	07 (4.04)	05 (3.28)	02 (1.19)	02 (1.51)	16 (2.5)
Five	03 (1.73)	03 (1.97)	0	0	06 (0.96)
Total	173	152	167	132	624

To avoid injuries, we can either use alternate entry site avoiding umbilicus or can use modified techniques such as – open technique, direct trocar entry, disposable shielded trocar, and optical trocar access through umbilicus. Probably the safest initial entry site in high-risk patients is the left upper quadrant (LUQ) known as Palmer's point, first described in 1931 by Palmer, which lies 3 cm below the left costal border in midclavicular line.<sup>[5]</sup> This technique is recommended for obese as well as very thin patients and in patients where intra-peritoneal adhesions are being suspected it is essential at this site, to decompress the stomach using nasogastric suction and then introduction of the Veress needle perpendicularly to the skin without lifting the abdominal wall. After the establishment of the pneumoperitoneum, trocars of 5 mm may be introduced at the same site as the Veress, followed by additional trocar/cannula systems inserted under direct vision, as per the requirement of the case.

A clear advantage of Veress needle and trocar insertion at this location is that the abdominal wall is consistently thin, even in obese patients. Another advantage is that no major retroperitoneal vessels lie directly below Palmer's point when instruments are placed perpendicular to the skin surface in the axial plane. But various authors, Giannios<sup>[21]</sup> and Howard *et al.*,<sup>[20]</sup> they have cautioned regarding the angle of entry of long laparoscopic instruments during the course of surgery due to proximity of retroperitoneal structure like left kidney, which we found commonly located below palmer's point. So they proposed to enter Veress/trocar at 45° angle to horizontal plane, especially in thin patients. Comparing the vertebral position of abdominal organs also, we are in a safe zone at Jain point at around L<sub>4</sub> vertebral level, where stomach (T<sub>10</sub> to L<sub>1</sub>), left kidney (T<sub>12</sub> to L<sub>3</sub>), and spleen (T<sub>10</sub> to L<sub>1</sub>) lie out of the way.

Palmer's point should be avoided in patients known to have hepatosplenomegaly, portal hypertension, history of previous gastric or spleen surgery, or probable gastropancreatic mass. Here, the Jain point makes a difference that initial entry through Jain point can be performed in above cases too. The other limitation of

palmer's point is that we cannot use it as an operative port during further course of surgery due to its higher location while Jain point is used as a working port during the whole surgery.

Moreover, at Palmer's point, it can be more difficult to penetrate the peritoneum with the Veress needle than it is at the umbilicus. To overcome this problem, some surgeons advocate using a subcostal approach or even going through the lowest (9<sup>th</sup>) intercostal space. LUQ is invariably free of adhesions irrespective of previous incisions, but there is a risk of creating an iatrogenic pneumothorax and also injuring neurovascular bundle and stomach.<sup>[22,23]</sup> In one retrospective study, left ninth intercostal space was used for Veress needle entry and left subcostal space for placement of primary trocar. A total of 54.9% cases had umbilical adhesions. Out of 504 cases, one case had bowel injury by Veress insertion, and no other significant entry-related injury was encountered.<sup>[24]</sup>

In another study, the middle upper abdomen was used for insufflation and primary cannula insertion in patients with a history of gynecologic cancer or at least, one laparotomy. The reported complications ranged from superficial serosal damage to complete perforation of stomach and small intestine and injury to blood vessels.<sup>[25]</sup>

Other workers across the globe have also explored alternative techniques at primary port locations. An open umbilical method "Hasson technique" first described in 1991 by Hasson to avoid bowel and vascular injuries was supposed to be beneficial in obese patients, very thin patients, and in cases who had previous one or more laparotomy with midline vertical incision where chances of adhesion are much more. The technique involves incising the skin, subcutaneous tissue, fascial layer then holding this fascial layer with sutures to stabilize the cannula followed by entry into the abdomen and preventing gas leak with cone-shaped sleeve. As this is not a blind procedure like Veress needle entry, it prevents the vascular injury but the risk of entering the lumen of adherent bowel is still not eliminated. The other benefits include avoiding preperitoneal insufflation, gas embolism, and correct anatomical repair of abdominal wall incision after the surgery. However, the major limiting factor is greater time needed for port placement and maintenance of pneumoperitoneum. In even experienced hands, it takes about 3–10 min. However, still, long-standing controversy remains about safety profile and there is conflicting evidence between studies Penfield,<sup>[27]</sup> noted a 0.06% incidence of bowel injury mostly partial thickness. Hasson<sup>[26]</sup> reported his experience on 5284 women where 21 patients had minor wound infection, 4 had minor hematoma, 1 developed umbilical hernia, and 1 had an injury to small bowel. Moreover, Hasson technique does

not give full safety against bowel injuries though it obviates vascular injuries. If bowel is so densely adherent to the umbilicus then it is exposed to the risk of inadvertent injury while making the primary 10 mm umbilical entry; hence, Jain point technique moves the primary entry site away from major vessel or bowel, as it is in the left paraumbilical area. It totally avoids major vessel injury and being so lateral avoids bowel adhesions also.

Direct trocar entry technique was introduced by Dingfelder in 1978, which eliminates Veress needle complications such as failed pneumoperitoneum, preperitoneal insufflation, and gas embolism. It is fast as it is a one-step pneumoperitoneum. However, being a blind procedure, it does not eliminate the risk of bowel and vascular injuries.<sup>[28]</sup>

In 1984, disposable shielded “safety” trocar were introduced to the market, the manufacturer claimed that this trocar system works in a way that when it enters the abdominal cavity, the sharp edge retracts and the shield springs so that it avoids contact of the tip of the trocar with intra-abdominal content. However, there will be a moment when this trocar enters into the peritoneal cavity and before its retraction, it will be in contact with abdominal contents. This brief moment is sufficient to produce injury, especially with its very sharp end. A retrospective study documented 30% of serious injuries caused by laparoscopic entry, and two deaths out of seven deaths caused by laparoscopic entry injury.<sup>[29]</sup> This led the Food and Drug Administration to directly write to the manufacturers to eliminate safety claims from the label of shielded trocars.<sup>[30]</sup>

As the complications during laparoscopic entry continued to occur, to improve primary access safety, disposable optical trocars (Endopath optiview trocar and visiport optical trocars) were introduced in 1994. These instruments have a 0° laparoscope loaded in hollow trocar with the distal crystal tip which transects abdominal tissue layers and transmits entry images during insertion. These visual entry instruments retain a push through trocar and cannula design where the insertion requires considerably more penetration force with no mechanism to offset overshoot.<sup>[32]</sup> To overcome this problem, Dr. Ternamian in 1997, introduced a reusable endotip visual cannula which had less requirement of penetration force with controlled visual entry.<sup>[31]</sup> Optical Veress needle is a 2.1 mm visual Veress needle, which has a 1.2 mm micro laparoscope, is also available to make the initial Veress needle guided entry in previous surgery cases.<sup>[33]</sup> However, in this visual access system, it is essential for the operator to clearly recognize tissue plane transition on the monitor during entry and appreciate the importance of not applying perpendicular force otherwise, you have to

face unintended injury. Optical trocar system can still result in serious injuries such as vascular injuries to aorta, vena cava or iliac vessels, significant bleeding from other sites, bowel perforations, liver laceration and stomach perforation, and mortality also.<sup>[34]</sup> It is true that we can visualize, the bowel loops through peritoneum but to avoid injury of very densely adherent bowel loop is still a challenge, and we have repeatedly found that Jain point is free of bowel loops. Overall visual entry trocars are nonsuperior to other trocars since they do not avoid visceral and vascular injuries. Hence, we have selected a point of entry where chances of bowel adhesion are least and also does not require expensive and sophisticated trocar and Veress needle. It is not only the instrument but also it is a point of the abdomen where we have not seen adherent bowel loops.

The present study explores the possibility of an ergonomically lower point which is safe in previous surgery cases and further on usable as a working port for pelvic surgeries. Furthermore, it is a normal routine reusable trocar that does not require any sophisticated optical trocar or Veress needle or an endotip cannula or a micro laparoscope. No significant entry-related injury was encountered during the use of Jain point in the present study. Jain Point, due to its more lateral location, it avoids intra-abdominal adhesions of the midline vertical and paramedian incision sites. Moreover, being lower than palmer’s point, it avoids the stomach, spleen, left kidney, and pancreas injury risk. It is free of any major blood vessel traversing beneath it. Being on the left side, it avoids all other adhesions which could be due to appendiceal, ileocecal, gall bladder, liver pathologies, etc., which are routinely encountered in general surgery cases.

We propose Jain point due to its simplicity of access, no need of any special technique or instrument. It gives complete safety against major vessel injury. In our series, we did not find bowel adhesions at this site, so gives benefit for the avoidance of hollow viscous injury (stomach and bowel). It continues to be used all through the surgery right from gaining entry in the abdominal cavity to being used as major operating port. Moreover, Jain point is amenable to minor variations when the mandate of the case so demands. A mirror reflection of Jain point can be used from the right side, like in microsurgery cases, where left ports are generally 3 mm; or in cases where previous left paramedian incisions are extensively placed; or in cases where colostomy or drain sites, burns and keloids preclude its use on left side. We have used Jain point from the right side in above indications.

## CONCLUSION

It is important for surgeons to be well versed in more than one safe laparoscopic access method and be knowledgeable

in different entry techniques, as our patients have different medical or surgical needs. Careful access selection, thorough knowledge of abdominal and pelvic anatomy, and meticulous attention to surgical technique during laparoscopic port entry can significantly reduce inadvertent injury and improve patient safety. With our continued entry through Jain point in the various type of cases as we have described, it has been found that despite previous infectious pathologies such as Koch's, septicemia, previous multiple bowel, and pelvic surgery, Jain point has been found to be free of bowel adhesions. There was no major vessel injury. Due to the abdominal wall blood supply, bleeding at the site by Veress needle or trocar entry has also not been found. The Jain point derives its safety from the fact that it is more lateral; hence, it avoids intra-abdominal adhesions at previous incision sites. Being lower down at paraumbilical position, it is ergonomic to be used as operating port later on in the surgery. Since it is much lower than the subcostal margin, it can very well be used in cases of hepatosplenomegaly, portal hypertension, and upper abdomen vertical or Kocher's incisions. It is universally suitable for all body types. Jain point promises to be a safe portal for laparoscopic entry in cases with a history of previous surgery. Further use by other high volume endoscopy units will give a critical appraisal of its safe profile.

### Acknowledgment

The authors would like to extend their appreciation and thanks to Mr. Vishram Singh and Miss. Anamika for their dedicated support and help during the compilation of this study.

### Financial support and sponsorship

Nil.

### Conflicts of interest

There are no conflicts of interest.

## REFERENCES

- Jansen FW, Kapiteyn K, Trimbo-Kemper T, Hermans J, Trimbo JB. Complications of laparoscopy: A prospective multicentre observational study. *Br J Obstet Gynaecol* 1997;104:595-600.
- Liakakos T, Thomakos N, Fine PM, Dervenis C, Young RL. Peritoneal adhesions: Etiology, pathophysiology, and clinical significance. Recent advances in prevention and management. *Dig Surg* 2001;18:260-73.
- Ellis H. The magnitude of adhesion related problems. *Ann Chir Gynaecol* 1998;87:9-11.
- Krishnakumar S, Tambe P. Entry complications in laparoscopic surgery. *J Gynecol Endosc Surg* 2009;1:4-11.
- Palmer R. Safety in laparoscopy. *J Reprod Med* 1974;13:1-5.
- Childers JM, Brzechffa PR, Surwit EA. Laparoscopy using the left upper quadrant as the primary trocar site. *Gynecol Oncol* 1993;50:221-5.
- Roy GM, Bazzurini L, Solima E, Luciano AA. Safe technique for laparoscopic entry into the abdominal cavity. *J Am Assoc Gynecol Laparosc* 2001;8:519-28.
- Corson SL, Brooks PG, Soderstrom RM. Safe technique for laparoscopic entry into the abdominal cavity. *J Am Assoc Gynecol Laparosc* 2002;9:399.
- Tulikangas PK, Nicklas A, Falcone T, Price LL. Anatomy of the left upper quadrant for cannula insertion. *J Am Assoc Gynecol Laparosc* 2000;7:211-4.
- Teoh B, Sen R, Abbott J. An evaluation of four tests used to ascertain Veres needle placement at closed laparoscopy. *J Minim Invasive Gynecol* 2005;12:153-8.
- Vilos GA. The ABCs of a safer laparoscopic entry. *J Minim Invasive Gynecol* 2006;13:249-51.
- Brill AI, Nezhat F, Nezhat CH, Nezhat C. The incidence of adhesions after prior laparotomy: A laparoscopic appraisal. *Obstet Gynecol* 1995;85:269-72.
- Weibel MA, Majno G. Peritoneal adhesions and their relation to abdominal surgery. A postmortem study. *Am J Surg* 1973;126:345-53.
- Szomstein S, Lo Menzo E, Simpfendorfer C, Zundel N, Rosenthal RJ. Laparoscopic lysis of adhesions. *World J Surg* 2006;30:535-40.
- Royal College of Obstetricians and Gynaecologists. Green-top guideline no. 49. Preventing entry-related gynaecological laparoscopic injuries. London: RCOG; 2008.
- Varma R, Gupta JK. Laparoscopic entry techniques: Clinical guideline, national survey, and medicolegal ramifications. *Surg Endosc* 2008;22:2686-97.
- Tulikangas PK, Robinson DS, Falcone T. Left upper quadrant cannula insertion. *Fertil Steril* 2003;79:411-2.
- Chang FH, Chou HH, Lee CL, Cheng PJ, Wang CW, Soong YK. Extraumbilical insertion of the operative laparoscope in patients with extensive intraabdominal adhesions. *J Am Assoc Gynecol Laparosc* 1995;2:335-7.
- Kumakiri J, Takeuchi H, Sato Y, Kitade M, Kikuchi I, Shimanuki H, et al. A novel method of ninth-intercostal microlaparoscopic approach for patients with previous laparotomy. *Acta Obstet Gynecol Scand* 2006;85:977-81.
- Howard FM, El-Minawi AM, DeLoach VE. Direct laparoscopic cannula insertion at the left upper quadrant. *J Am Assoc Gynecol Laparosc* 1997;4:595-600.
- Giannios NM, Gulani V, Rohlck K, Flyckt RL, Weil SJ, Hurd WW. Left upper quadrant laparoscopic placement: Effects of insertion angle and body mass index on distance to posterior peritoneum by magnetic resonance imaging. *Am J Obstet Gynecol* 2009;201:522.e1-5.
- Reich H. New laparoscopic techniques. In: Sutton C, Diamond M, editors. *Endoscopic Surgery for Gynaecologists*. London: WB Saunders; 1993. p. 31.
- Kumar S. Veress needle insertion through left lower intercostal space for creating pneumoperitoneum: Experience with 75 cases. *J Minim Access Surg* 2012;8:85-9.
- Agarwala N, Liu CY. Safe entry techniques during laparoscopy: Left upper quadrant entry using the ninth intercostal space – A review of 918 procedures. *J Minim Invasive Gynecol* 2005;12:55-61.
- Lee CL, Huang KG, Jain S, Wang CJ, Yen CF, Soong YK. A new portal for gynecologic laparoscopy. *J Am Assoc Gynecol Laparosc* 2001;8:147-50.
- Hasson HM. Open laparoscopy as a method of access in laparoscopic surgery. *Gynaecol Endosc* 1999;8:353-62.
- Penfield AJ. Critical decisions in 22 years of outpatient laparoscopy. *J Am Assoc Gynecol Laparosc* 1994;1:528-9.
- Dingfelder JR. Direct laparoscope trocar insertion without prior pneumoperitoneum. *J Reprod Med* 1978;21:45-7.
- Saville LE, Woods MS. Laparoscopy and major retroperitoneal vascular injuries (MRVI). *Surg Endosc* 1995;9:1096-100.
- Wellis T. Shielded trocars and needles used for abdominal access during laparoscopy. Rockville, MD: Department of Health and Human Services; 1996.



31. Ternamian AM. A second-generation laparoscopic port system: Endo TIP. *Gynecol Endosc* 1999;8:397-401.
32. Angelini L, Lirici MM, Papaspyropoulos V, Sossi FL. Combination of subcutaneous abdominal wall retraction and optical trocar to minimize pneumoperitoneum-related effects and needle and trocar injuries in laparoscopic surgery. *Surg Endosc* 1997;11:1006-9.
33. Riek S, Bachmann KH, Gaiselmann T, Hoernstein F, Marzusch K. A new insufflation needle with a special optical system for use in laparoscopic procedures. *Obstet Gynecol* 1994;84:476-8.
34. Sharp HT, Dodson MK, Draper ML, Watts DA, Doucette RC, Hurd WW. Complications associated with optical-access laparoscopic trocars. *Obstet Gynecol* 2002;99:553-5.