

Total Laparoscopic Hysterectomy for Large Uterus

Rakesh Sinha, Meenakshi Sundaram,
Smita Lakhotia, Chaitali Mahajan,
Gayatri Manaktala, Parul Shah

Beams Hospital, Mumbai - 400 052, India

ABSTRACT

Aim: In this review, we assessed the feasibility of total laparoscopic hysterectomy (TLH) in cases of very large uteri weighing more than 500 grams. We have analyzed whether it is possible for an experienced laparoscopic surgeon to perform efficient TLH for large myomatous uteri regardless of the size, number and location of the myomas. **Design:** Retrospective review (Canadian Task Force Classification II-1) **Setting:** Dedicated high volume Gynecological laparoscopy centre. **Patients:** 173 women with symptomatic myomas who underwent TLH at our center. There were no exclusion criteria based on the size number or location of myomas. **Intervention:** TLH and modifications of performing the surgery by ligating the uterine arteries prior, myomectomy followed by hysterectomy, direct morcellation after uterine artery ligation. **Results:** 72% of patients had previous normal vaginal delivery and 28% had previous cesarean section. Average clinical size of the uterus was 18 weeks (10, 32). The average weight of the specimen was 700 grams (500, 2240). The average duration of surgery was 107 min (40, 300) and the average blood loss was 228 ml (10, 3200). **Conclusion:** TLH is a technically feasible procedure. It can be performed by experienced surgeons for large uteri regardless of the size, number or location of the myomas.

Key words: Large uterus, multiple fibroids, total laparoscopic hysterectomy

DOI: 10.4103/0974-1216.51908

INTRODUCTION

Total laparoscopic hysterectomy (TLH) is currently accepted as a safe, efficient way to manage benign uterine pathology, and is an acceptable alternative to standard abdominal hysterectomy.^[1] The term laparoscopic hysterectomy is used to define various types of hysterectomy with a laparoscopic access to the abdominal cavity.^[2] Laparoscopic hysterectomy (LH), defined as the laparoscopic ligation of the major vessels supplying the uterus by electrocautery desiccation, suture ligation, or staples was first performed in 1988.^[3] Today, LH is a safe and feasible technique to manage benign uterine pathology as it offers minimal postoperative discomfort, shorter hospital stay, rapid convalescence, and early return to the activities of daily living.^[4] The rationale for TLH is to convert abdominal hysterectomy into a laparoscopic procedure and thereby reduce trauma and morbidity.^[5]

Address for correspondence:

Meenakshi Sundaram,
Beams Hospital, 674, 16th Cross Road,
Behind Khar Gymkhana, Khar (West), Mumbai - 400052,
India. E-mail: drmeena25@yahoo.com

Most studies set an upper limit for uterine size, usually 15 to 16 weeks' gestation or weight more than 500 grams as large uterus.^[6] It was suggested that very enlarged uteri should be treated by laparotomy. The difficulties with enlarged uteri are limited access to uterine vascular pedicles depending on size and location of myomas, and high risk of complications such as haemorrhage. Other concerns of laparoscopic management of large uteri are the risk of bowel and urinary tract injury due to poor exposure, difficulty extracting the uterus, and duration of the procedure. To overcome these limitations, TLH in cases of enlarged uteri should be modified and made feasible in all cases. In this article we have discussed the feasibility of TLH in 173 women with uteri more than or equal to 500 grams and the technical modifications we have adopted for the procedure.

MATERIALS AND METHODS

173 women who underwent TLH in our centre in the last seven years (January 2001- December 2008) were enrolled in the study. Main indications for Total laparoscopic hysterectomy were symptomatic leiomyomas or abnormal

uterine bleeding. Women with other pathology like adnexal mass or endometriosis were excluded from the study. The clinical size of the uterus varied from ten weeks to maximum 32 weeks. All patients underwent pelvic ultrasound examination and basic blood investigations. Patients were kept on a liquid diet 2 days before the procedure and a laxative was given 12 hours before the surgery to empty the bowel. Antibiotic prophylaxis was given to all women included in the study. Subcutaneous low-dose heparin and a sequential compression device were also given to all patients for prophylaxis against possible thromboembolic episodes.

Operative procedure

All the surgeries were performed under general anesthesia with the patient in modified lithotomy position.^[6] The Veress needle was inserted at the Palmer's point in all patients. In some studies the Veress needle is placed supraumbilically in the case of very large uteri.^[7] The Palmer's point^[9] (a point 3 cm below the left costal margin in the midclavicular line) is a safe zone in all patients other than those with splenomegaly.

After insufflations with carbondioxide, a 5-mm trocar is inserted blindly in the left upper quadrant lateral to the inferior epigastric vessels at the level of or above the upper limit of the uterus. If the uterus is large, the Veress and the 5-mm port may be placed at the Palmer point. A 5-mm telescope is introduced through this port and the uterus with the adnexa is evaluated. The 10-mm port is inserted under vision at the supraumbilical site or higher depending on the size of the uterus. Entry under vision avoids damage to major vessels directly beneath the insertion site and also has the added advantage that the port can be placed at a variable point, depending on the size of the uterus. This not only helps the surgeon to obtain a good operative field but also allows smooth manipulation of the instruments above the uterus. We generally perform the surgery with three five mm accessory ports: the port placed initially in the left lateral upper quadrant is used as the first accessory port. The second port is placed under vision in the right lateral upper quadrant and the third port is placed in the left lateral lower quadrant. If necessary, in the case of very large uteri, a fourth port is placed in the right lateral lower quadrant [Figure 1].

The pelvis and the abdomen are inspected and any other pathology (endometriotic lesions, adhesions, ovarian pathology etc), if present, is tackled first. The course of the ureters is traced out at the start of the procedure. The size, site and the number of myomas are assessed

[Figures 2-4]. Manipulation of the uterus with a uterine manipulator maybe very difficult in a large uterus. We prefer to insert a five mm myoma spiral into the uterus for manipulation. In cases of previous normal delivery where there are no bladder adhesions, we start the hysterectomy with ligation of the uterine pedicles as the first step.^[10]

The uterovesical fold of peritoneum is identified and opened from the round ligaments on either side. The bladder is dissected down completely so that the uterine vessels on either side can be clearly seen. A window is created in the broad ligament close to the uterine vessels. This helps visualization of the posterior aspect and prevents accidental suture placement through bowel loops. The ascending branch of the uterine artery is identified close to the isthmus. The uterine vessels are ligated at this level close to the uterus by transfixation using 1-0 delayed absorbable suture material [Figure 5]. Dissecting the uterovesical fold and pushing the bladder down moves the ureters laterally and decreases the risk of including them in the suture. We prefer to use the contralateral ports for suturing. The right midquadrant port and the left lower quadrant port are ergonomically apt for suturing. The vasculature of the uterus is thus secured and this is evidenced by the color change in the fundus, which becomes pale [Figures 6-7]. The cornual pedicles are then dessicated and cut either using bipolar diathermy or the harmonic ultracision. The ligated uterine pedicles are cut. The uterosacrals and cardinal ligaments are dessicated and cut. The vaginal vault is opened from one side. The position of the myoma spiral is then changed so that the opposite side pedicles can be taken. The cornual, uterine, and uterosacral aspects of the other side are taken in a similar way and the vaginal vault is opened. The specimen is detached completely. If both ovaries need to be removed, the infundibulopelvic ligaments are desiccated and cut, and the ovaries are delivered vaginally. The vaginal vault is then sutured with No. 1 delayed absorbable interrupted figure-of-eight sutures. In cases of previous caesarean sections where the bladder is densely adherent, we start from the left cornual structures. The uterovesical fold is opened and the bladder is dissected down by the lateral approach. A definitive plane can be identified between the cervix and the bladder by this approach and the bladder is dissected down. The uterine vessels are then ligated on either side and the dissection is completed.

The specimen is retrieved by Morcellation through the left upper quadrant 5-mm port, which is converted to 15-mm port. The 15 mm port is closed with port closure needle (Reza Grancee) under vision. The rest of the ports

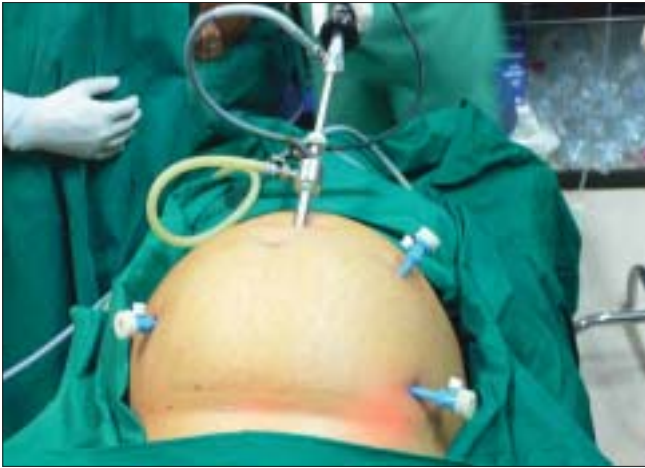

Figure 1: Port positioning for TLHI

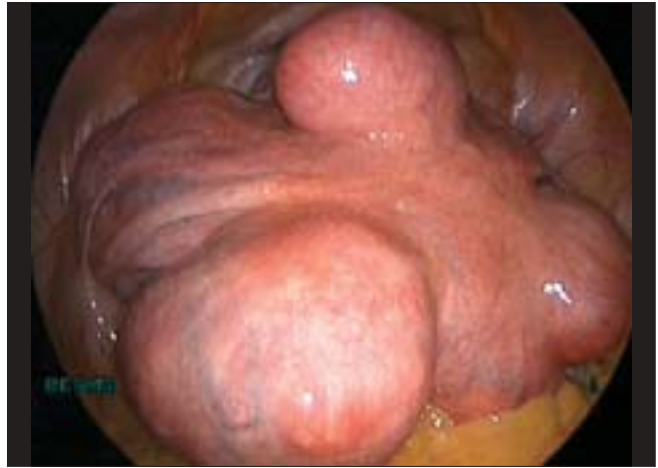

Figure 2: Large uterus with multiple fibroids

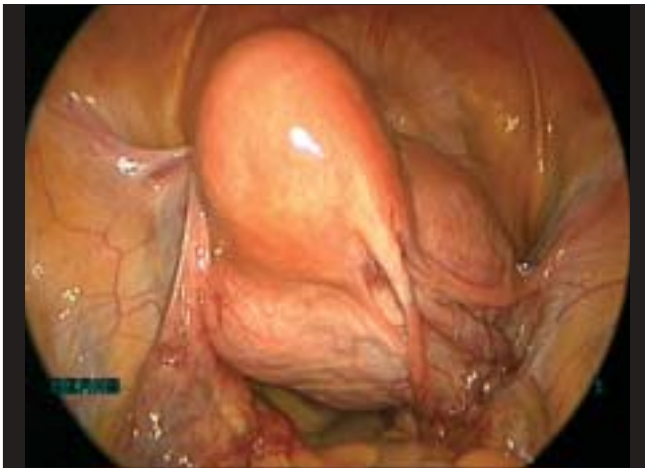

Figure 3: Uterus with cervical fibroid

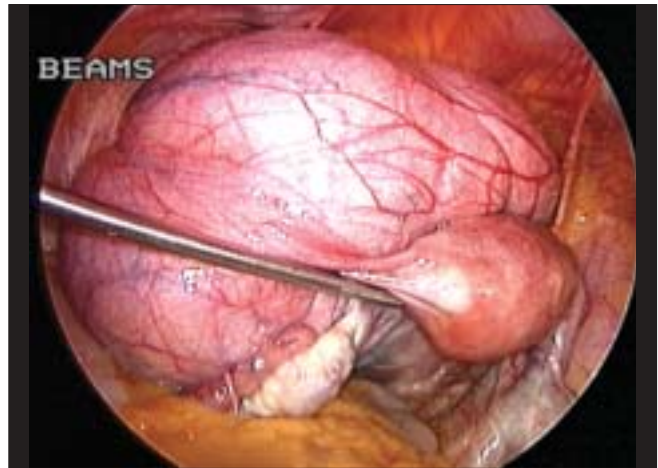


Figure 4: Uterus with broad ligament fibroid

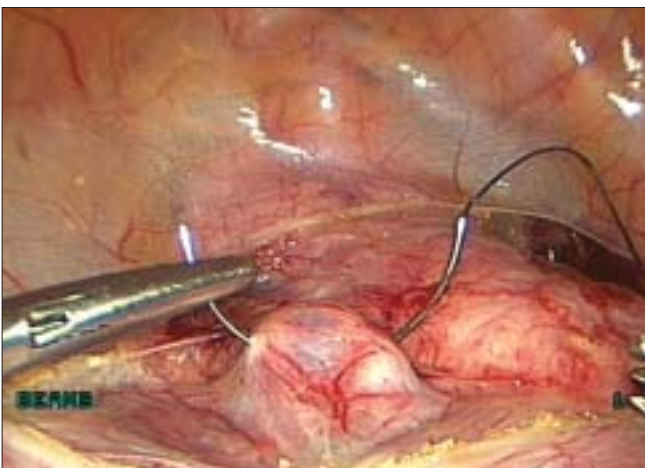


Figure 5: Uterine artery ligation

are closed with subcuticular sutures using No 3-0 delayed absorbable suture.

This standard technique of total laparoscopic hysterectomy is performed in most cases. However in the case of very large myomas that render the procedure very difficult, certain modifications to the above technique are adopted. Myomectomy may be done prior to the hysterectomy so as to create space for the procedure. In case of large cervical fibroids, uterine artery ligation may be done at its origin from the internal iliac in order to reduce the blood loss. The anterior leaf of the broad ligament is opened by making an incision lateral to the uterus in the triangle enclosed by the round ligament, the external iliac artery and the infundibulopelvic ligament. The uterine artery is identified

and then ligated by means of intracorporeal suturing with No 1 Vicryl. The uterus is seen to turn pale following the

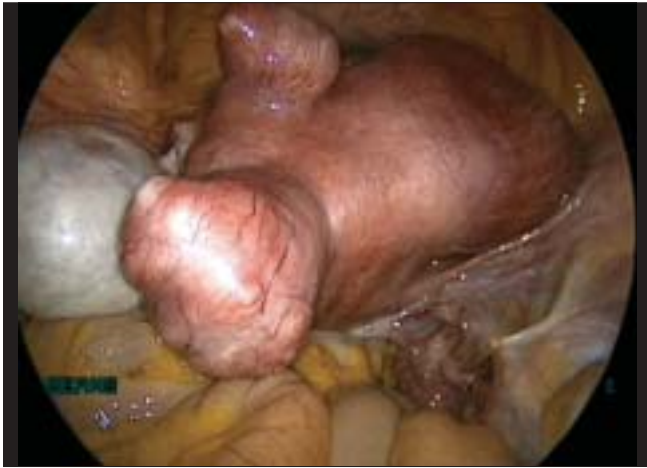

Figure 6: Uterus before devascularisation

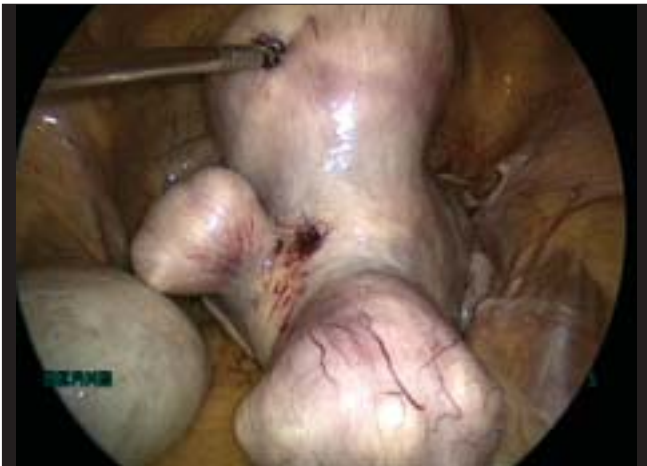

Figure 7: Uterus after devascularisation

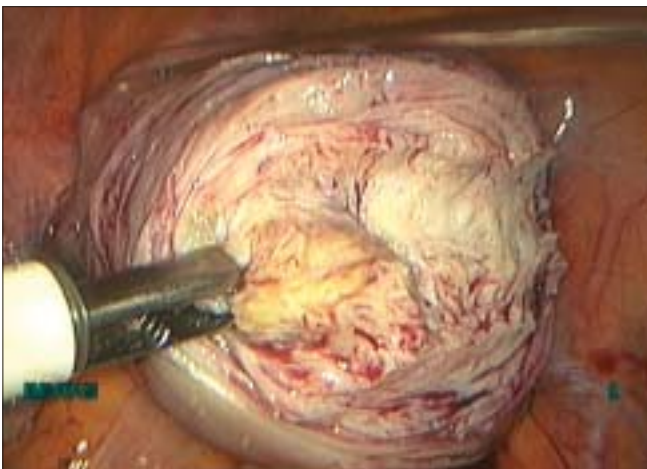


Figure 8: Morcellation while still attached

bilateral ligation of the uterine vessels and the blood loss is considerably reduced.

In large uteri, it may be difficult to debulk the uterus completely due to limitations in space and inaccessibility to uterosacrals. In such cases, we first do a supracervical hysterectomy after securing the uterine pedicles. Once the uterus is debulked, we go ahead and remove the cervix. In some cases we perform direct morcellation of the uterus after uterine artery ligation in order to debulk the specimen [Figure 8]. Once the bulk of the uterus has been morcellated, there is enough space for performing the final stages of the procedure, namely the desiccation and division of the uterosacral ligaments and colpotomy. The separated cervix is then delivered vaginally. Bleeding does not pose a problem as the ovarian and uterine vessels have been desiccated and cut. The vagina is closed with intracorporeal interrupted sutures with No 1 Vicryl.

The duration of the surgery was calculated from the insertion of the Veress needle till the placement of the last skin suture. The total blood loss is calculated. No irrigation is used throughout the procedure until the calculation of the total blood loss. Peritoneal lavage is given with normal saline solution and 500 ml of normal saline is left in the peritoneal cavity. The specimen is weighed. The catheter is removed after six hours and liquids are started after peristalsis is established. The patient is discharged the following day and called for follow-up after seven days.

Data analysis

Analysis was done using SPSS for Windows, Version 14.0 (SPSS, Inc., Chicago, IL). Results are expressed as mean (minimum, maximum). 173 women who underwent hysterectomy for large uterus (more than 500 grams) were included in the study. TLH was successfully performed in all women. The mean age of women was 45 years. The main symptoms of women were menorrhagia (63%), mass abdomen (30%), pain abdomen (5%), multiple complaints (2%). 72% of women had previous normal delivery and 28% had previous caesarean section. Ligating the uterine arteries earlier was more feasible in women without previous caesarean section as bladder mobilization was not difficult. Clinical size of the uterus ranged from 10 weeks to 32 weeks with the mean clinical size being 18 weeks. The hemoglobin levels in all women were above 9 g/dL. All specimen were retrieved by morcellation. The mean weight of the specimen was 700 grams (500, 2240).

Total duration of surgery was 107 min (40, 300) and Morcellation time was 32 min (10, 120).

Average total blood loss was 228 ml (10, 3200).

The data reveal that there was a significant decrease in blood loss and need for blood transfusion in women who underwent earlier ligation of uterine vessels. Nine women underwent blood transfusion in view of blood loss being more than 750 ml. Three women underwent supracervical hysterectomy followed by removal of cervix. Two women underwent Morcellation while the specimen was still attached after uterine ligation. One woman with previous caesarean section and dense bladder adhesions had bladder injury which was detected intraoperatively and sutured laparoscopically. Urinary catheter was kept for one week and woman recovered uneventfully. One woman had serosal rectal tear which was sutured laparoscopically. Woman was kept nil oral for three days and on liquids for three days. Two women had delayed complication of ureteric fistula and rectovaginal fistula. Ureteric fistula occurred in a patient with large cervical fibroid. The fistula was repaired laparoscopically by ureteroneocystostomy. Rectovaginal fistula was repaired by temporary colostomy and then reanastomosis at a later date.

DISCUSSION

Laparoscopic hysterectomy has been the subject of many controversial comments especially when it comes to large uterus. Compared with abdominal hysterectomy, however, compelling evidence indicates that laparoscopy provides specific benefits.^[11]

The main conclusion that comes from our study is that TLH is a feasible and safe technique in cases of enlarged uteri, which permits efficient avoidance of laparotomy incision in most of the procedures with evident benefits for the women. Our study indicates that there is a lower rate of intraoperative complication laparoscopically compared to studies of hysterectomy done by open laparotomy.^[12]

Literature suggests that greatly enlarged uteri should be treated by laparotomy. Most studies set an upper limit for uterine size, usually 15 to 16 weeks gestation.^[7] A multicenter randomized clinical trial^[13] in 1998 compared LH with total abdominal hysterectomy (TAH). Myoma uterus was the indication for hysterectomy in most cases in this trial. The largest uterus in the LH group was 1550 g; the greatest blood loss was in the TAH group and was 3000 mL. The mean blood loss was significantly less for the LH group than the TAH group.

Therefore, no evidence exists that the average blood loss is less if one does TAH rather than LH.

In case of large uteri, there is distortion of normal anatomy especially the ureters and the uterine vessels. In the case of lateral wall myomas that arise below the entry of the uterine vessels, the ureter is pushed outwards and almost raised onto the superior surface of the myoma. The uterine vessels are raised high up almost to the level of the ovarian vessels. Lateral wall myomas that arise above the level of the uterine vessels push the ureter outwards and downwards. Large anterior wall and cervical myomas flatten the bladder, which can get raised high up on the anterior uterine surface. A major concern is that such distortions as well as the poor exposure may increase the risk of bladder, ureteric and bowel injury. This is compounded by the technical difficulty involved in extracting the uterus and the skill that is necessary to suture the uterine vessels. Therefore it has often been suggested that grossly enlarged uteri are a contraindication for total laparoscopic hysterectomy.

Before attempting to perform TLH in women with huge uteri, several modifications to current technique are suggested. Poor access and exposure are the main concerns, and can be overcome by few modifications in hysterectomy technique. First, the optical trocar is placed supraumbilically to facilitate proper visualization. The use of myoma spiral increases the mobility of the uterus and frequent changes in its positioning can help access to all pedicles.

Another concern is the risk of hemorrhage, which in cases of very enlarged uteri can be increased due to difficult exposure. We have minimized the blood loss by ligating the uterine pedicle as the first step in the hysterectomy procedure.

There are several options available to the laparoscopic surgeon for securing the pedicles including bipolar diathermy, harmonic ultracision, vessel-sealing device, endoscopic suturing techniques, or staples.^[14] Complications such as hemorrhage, bladder injuries, and ureteric injuries are directly or indirectly related to the method of securing the vascular pedicles. The author has described the use of laparoscopic reusable clamps for all the pedicles in his earlier publication, which adopts the basic principles of TAH.^[14] The clamp is a versatile instrument that can be used to secure a vascular pedicle in other operative procedures such as salpingectomy, salpingo-oophorectomy, and appendectomy.

Given adequate training in laparoscopic surgery and with proper technique, TLH can be performed successfully in most women with very enlarged uteri, with no increase in complication rates and short-term recovery. In skilled hands, these patients could benefit all the advantages

related to minimally invasive approach such as minimal blood loss, short hospital stay, prompt recovery, obtaining a satisfactory result. From our data, there is no reason any longer to consider enlarged uteri a contraindication to TLH; and in accordance with other authors' opinion, laparoscopy should be considered instead of laparotomy in all cases irrespective of the size of the uterus.

REFERENCES

1. Nezhat F, Nezhat C, Gordon S, Wilkins E. Laparoscopic versus abdominal hysterectomy. *J Reprod Med* 1992;37:247-50.
2. Harding S. Laparoscopic hysterectomy. *Br J Hosp Med* 1997;57:512-4.
3. Reich H. Laparoscopic hysterectomy. *Surg Laparosc Endosc* 1992;2:85-8.
4. Reich H, Roberts L. Laparoscopic hysterectomy in current gynaecological practice. *Rev Gynecol Pract* 2003;3:32-40.
5. Boike GM, Elfstrand EP, DelPriore G, Schumock D, Holley HS, Lurain JR. Laparoscopically assisted vaginal hysterectomy in a university hospital: Report of 82 cases and comparison with abdominal and vaginal hysterectomy. *Am J Obstet Gynecol* 1993;168:1690-701.
6. Wattiez A, Soriano D, Fiaccavento A, Canis M, Botchorishvili R, Pouly J, *et al.* Total laparoscopic hysterectomy for very enlarged uteri. *J Am Assoc Gynecol Laparosc* 2002;9:125-30.
7. Wattiez A, Soriano D, Fiaccavento A, Canis M, Botchorishvili R, Pouly J, *et al.* Total laparoscopic hysterectomy for very enlarged uteri. *J Am Assoc Gynecol Laparosc* 2002;9:125-30.
8. Sinha R, Hegde A. Safe entry techniques during laparoscopy. *J Minim Invasive Gynecol*. 2005;12: 463– 465.
9. Rakesh Sinha, MD, Meenakshi Sundaram, MD, DNB*, Yogesh A. Nikam *et al.* Total Laparoscopic Hysterectomy with Earlier Uterine Artery Ligation. *J Minim Invasive Gynecology*.2008 :15; 3: 355-359
10. Phipps JH, John M, Nayak S. Comparison of laparoscopically assisted vaginal hysterectomy and bilateral salpingo-oophorectomy with conventional abdominal hysterectomy and bilateral salpingo-oophorectomy. *Br J Obstet Gynaecol* 1993;100:698-700.
11. David-Montefiore E, Rouzier R, Chapron C, Daraï E; Collegiale d'Obstétrique et Gynécologie de Paris-Ile de France. Surgical routes and complications of hysterectomy for benign disorders: a French prospective observational study in French university hospitals. *Hum Reprod* 2007;22: 260-5.
12. Summitt RL Jr, Stovall TG, Steege JF, Lipscomb GH. A multicentered randomized comparison of laparoscopic assisted vaginal hysterectomy and abdominal hysterectomy in abdominal hysterectomy candidates. *Obstet Gynaecol* 1998;92:321-6.
13. Phipps JH. Thermometry studies with bipolar diathermy during hysterectomy. *Gynaecol Endosc* 1994;3:5-7.
14. Sinha RY, Warty N. A safer laparoscopic hysterectomy: laparoscopic hysterectomy using clamps; a new concept. *Gynaecol Endosc* 2000;9:293-9.
15. Salmanli N, Maher P. Laparoscopically-assisted vaginal hysterectomy for fibroid uteri weighing at least 500 grammes. *Aust N Z J Obstet Gynaecol* 1999;39:182-4.

Source of Support: Nil, Conflict of Interest: None.