

A giant rheumatoid nodule of the cubital fossa: A mimicker of malignancy

Sofia-Chrysovalantou Zagalioti¹, Eliza Stavride², Antonia Bintoudi²

¹General Practitioner, Papageorgiou Hospital, Thessaloniki, ²Department of Radiology, Papageorgiou Hospital, Thessaloniki, Greece

ABSTRACT

Rheumatoid nodules (RNs) are the most common extraarticular manifestation in patients with rheumatoid arthritis, appearing in up to 30%. They are typically localized subcutaneously in pressure points or joints, such as the extensor surface of the elbow. But when they have atypical localizations, they provide a confusing differential diagnosis including the possibility of a malignancy. Herein, we report a 53-year-old female patient with known rheumatoid arthritis who presented with a painless mass in the right cubital fossa. The uncommon site and the presence of cortical disruption made us proceed to computed tomography-guided biopsy to exclude the presence of a malignancy. Biopsy established the RN diagnosis.

Keywords: Cubital fossa, guided biopsy, rheumatoid arthritis, rheumatoid nodule, subcutaneous nodule

Introduction

Rheumatoid arthritis is a chronic inflammatory synovial disease. It is characterized by extraarticular manifestations including sites such as the skin, the eye, the heart, the lungs, the kidneys, and nervous and gastrointestinal system. Rheumatoid nodules (RNs) are the most common systematic manifestation and they are present in up to 30% of patients.^[1]

RNs typically arise from the subcutaneous tissues^[2] and can also adhere to the periosteum, the tendons, or the bursae. There are few reported cases of intramuscular nodules and osseous involvement mimicking infiltration.^[3-5] We present a case of a 53-year-old woman who presented with a right cubital fossa mass.

Case History

A 53-year-old woman presented to the Magnetic Resonance Imaging (MRI) department of our hospital for evaluation of a soft tissue mass in her right cubital fossa. She had been diagnosed with rheumatoid arthritis 5 years ago. The lump was painless for a whole year and it was progressively growing for at least 6 months. The patient was treated with methotrexate (7.5 mg once daily) for the rheumatoid arthritis for just 1 year and went on with homeopathic remedy.

No plain radiography, neither ultrasound were performed prior to the MRI request. The MRI was the first modality of evaluation [Figures 1-3] followed by a computed tomography (CT)-guided biopsy to establish the diagnosis. The patient and the institution have granted written permission to the authors to publish this case report.

Discussion

The primary care physician's role is pivotal as he/she is the first health provider to evaluate the clinical comorbidities of chronic

Address for correspondence: Dr. Sofia-Chrysovalantou Zagalioti, Papageorgiou Hospital, Ring Road N. Efkarpia 56403, Thessaloniki, Greece.
E-mail: sofia_zag@yahoo.com

Received: 16-04-2020

Revised: 10-06-2020

Accepted: 26-06-2020

Published: 25-08-2020

Access this article online

Quick Response Code:



Website:
www.jfmpc.com

DOI:
10.4103/jfmpc.jfmpc_641_20

This is an open access journal, and articles are distributed under the terms of the Creative Commons Attribution-NonCommercial-ShareAlike 4.0 License, which allows others to remix, tweak, and build upon the work non-commercially, as long as appropriate credit is given and the new creations are licensed under the identical terms.

For reprints contact: WKHLRPMedknow_reprints@wolterskluwer.com

How to cite this article: Zagalioti SC, Stavride E, Bintoudi A. A giant rheumatoid nodule of the cubital fossa: A mimicker of malignancy. J Family Med Prim Care 2020;9:4434-6.

diseases in a patient. Therefore, the primary care physician should be familiar with the evaluation of such conditions as well as their management.

Herein, we report a patient with known rheumatoid arthritis who presented with a single, nontender soft tissue mass in the right cuboid fossa. MRI scan revealed a well-defined, ovoid, intramuscular mass. The lesion was isointense to muscles on T1-weighted images [Figure 1 a-c] with increased signal intensity on short-TI inversion recovery images [Figure 2 a-c]. The mass was partly intramuscular, within the supinator muscle and the rest of the mass laid between brachioradialis and brachialis [Figures 1 and 2].

Biceps brachii tendon is encapsulated at its course before the attachment on the radial tuberosity. Early cortex destruction of the radius, suggesting bone invasion was also present [Figures 1 a, b, 2 a, b, 3 a, b]. No obvious vessel or neural involvement was confirmed. After intravenous contrast agent administration, central necrosis and peripheral vivid enhancement was demonstrated [Figure 3 a-c].

These nodules are mostly situated adjacent to tendons, at areas with high mechanical pressure points such as the foot and the extensor elbow area. However, the cubital fossa is neither a

high pressure nor an extensor area. Because of the uncommon location of the lesion and the radius invasion, the differential diagnosis first included a malignancy such as synovial sarcoma and secondary, the RN. Thus, we had to proceed to a CT-guided biopsy to establish the diagnosis.^[6]

Blood exams revealed increasing rheumatoid factor (27 IU/dL) and anticyclic citrullinated peptide antibodies (23 IU/dL). Several risk factors have been proposed regarding the presence of an RN in patients with diagnosed rheumatoid arthritis, including prolonged methotrexate treatment^[7], and smoking. Our patient was a smoker for many years prior to diagnosis.^[8]

RNs frequently occur as firm, single or multiple skin-colored masses and they can vary in size. In our case, there were no skin-related changes, probably because the nodule was not located close to the skin.

Pathophysiology hypothesis suggests that an initial repetitive trauma causing local vascular damage leads to subsequent neoangiogenesis, increased interleukin production, and RN formation.^[2] Therefore, the most common locations are pressure points or joints, such as the extensor surface of the elbows and the Achilles tendon. RNs are usually asymptomatic;

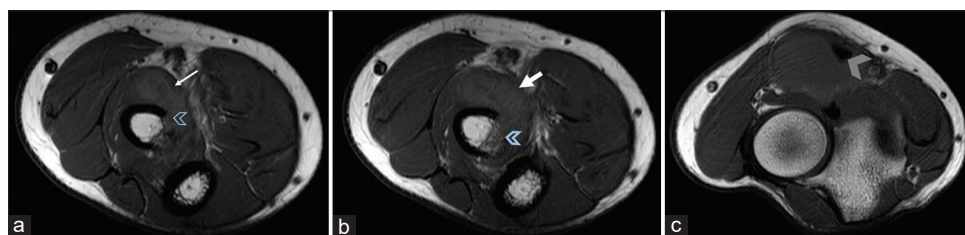


Figure 1 (a-c): Axial T1-weighted MR images of the right elbow showing an isointense, well-defined mass (white arrow) within the supinator muscle and osseous involvement (open blue arrowhead). Encapsulated distal biceps brachii tendon (gray arrowhead)

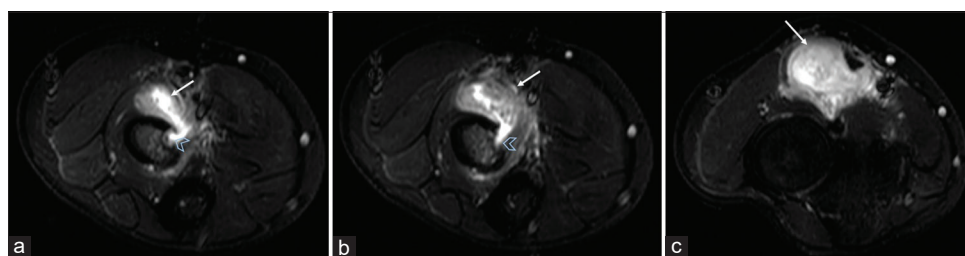


Figure 2 (a-c): Axial STIR MR images of the right elbow showing a heterogeneous mass with high signal intensity (white arrow) in the anterior compartment, infiltrating the radius (open blue arrowhead)

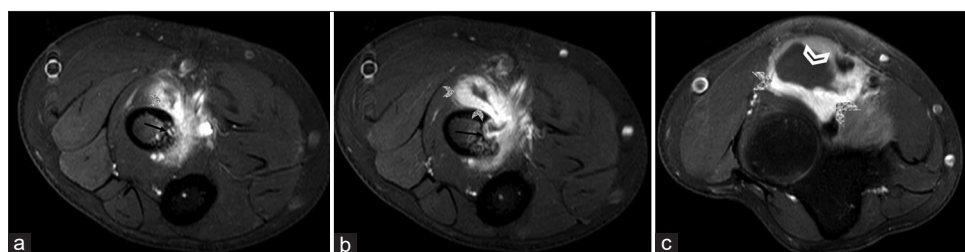


Figure 3 (a-c): Axial, post-contrast T1-weighted fat-suppressed MR images of the right elbow showing vivid peripheral enhancement (gray arrowhead) and central necrosis (open arrowhead). Bone involvement is also noted (black arrow)

however, they may become painful if neural involvement is present.

Histologically, the RN has a central necrotic area, that is surrounded by an inflammatory layer, composed of histiocytes in a palisade and around them by a granulomatous zone structured by fibrous tissue.^[9] The same enhancement and histological pattern were noted in our case.

The differential diagnosis for soft tissue palpable masses includes primary mesenchymal soft tissue tumors, metastases, and in the case of known rheumatoid arthritis, RN as well.^[9] In our case, a biopsy was performed to exclude the malignancy. Two samples were taken and the histopathological evaluation showed granulation tissue with the presence of lymphocytes, plasma cells, and fibrous tissue. Therefore, the biopsy established the diagnosis of RN.

Surgical excision was performed a year later due to cosmetic concerns of the patient, as it remained asymptomatic. There are three options of treatment for the RN. Surgical excision is preferred in cases where the mass is painful, when it reduces the function of the corresponding joint, and when there is a cosmetic complaint of the patient. Other possible treatments that reduce the size of the nodule are the steroid injections and disease-modifying antirheumatic drugs such as rituximab.^[10]

In conclusion, although RNs are the most common extraarticular manifestations of rheumatoid arthritis, in everyday practice, it might be difficult to establish a definitive diagnosis when the imaging features are atypical. Therefore, biopsy has a key role in the final diagnosis.

Declaration of patient consent

The authors certify that they have obtained all appropriate patient consent forms. In the form the patient(s) has/have given his/her/their consent for his/her/their images and other clinical information to be reported in the journal. The patients

understand that their names and initials will not be published and due efforts will be made to conceal their identity, but anonymity cannot be guaranteed.

Financial support and sponsorship

Nil.

Conflicts of interest

There are no conflicts of interest.

References

1. Cojocaru M, Cojocaru IM, Silosi I, Vraibe CD, Tanasescu R. Extra-articular manifestations in rheumatoid arthritis. *Maedica (Buchar)* 2010;5:286-91.
2. Seongsik B, Yeseul K, Kiseok J, Seung SP, Su-Jin S. Clinicopathologic features of rheumatoid nodules: A retrospective analysis. *Clin Rheumatol* 2019;38:3041-8.
3. Horwitz M. Muscle lesions in rheumatoid arthritis. *Ann Rheum Dis* 1949;8:258-66.
4. Császár A, Lapis K. Diffuse rheumatoid nodules in skeletal muscle in rheumatoid arthritis. *Acta Morphol Hung* 1984;32:127-32.
5. Dorfman HD, Norman A, Smith RJ. Bone erosion in relation to subcutaneous rheumatoid nodules. *Arthritis Rheum* 1979;13:69-73.
6. Courtney P, Wright G, Finch M. "Rheumatoid nodules" and lymphoma! *Ann Rheum Dis* 1998;57:578-9.
7. Timashpolsky A, Huntik R, Mortensen MM. Rheumatoid nodule of the vocal fold with spontaneous regression from immunosuppressant therapy. *Ear Nose Throat J* 2020;99:296-7.
8. Gupta SS, Sinha A, Namana V. The giant rheumatoid nodule: A case report. *Gen Med* 2017;5:3.
9. Ganguly A, Chaudhary SR, Rai M, Kesavanarayanan V, Aniq H. Thenar lumps: A review of differentials. *Clin Radiol* 2019;74:978.e15-e27.
10. Conigliaro P, Triggianese P, Martino E, Fonti GL, Chimenti MS, Sunzini F, *et al.* Challenges in the treatment of rheumatoid arthritis. *Autoimmun Rev* 2019;18:706-13.