

The use of thoracoscopy to enhance medical students' interest and understanding of thoracic anatomy

Sami A. AlNassar, Waseem Hajjar, Salah Rahal, Joanne Clifton¹, Richard Finley¹, Ravi Sidhu¹

Department of Surgery,
King Saud University,
Riyadh, Saudi Arabia,
¹Department of Surgery,
University of British
Columbia, Vancouver,
Canada

Address for correspondence:

Dr. Sami A. AlNassar,
Division of Thoracic
Surgery, Department of
Surgery (37), College
of Medicine, King Saud
University, P.O. Box 7805,
Riyadh 11427,
Saudi Arabia.
E-mail: dralnassar@
hotmail.com

Submission: 31-12-11
Accepted: 30-03-12

Abstract:

AIM: To develop a video-based educational tool designed for teaching thoracic anatomy and to examine whether this tool would increase students' stimulation and motivation for learning anatomy.

METHODS: Our video-based tool was developed by recording different thoracoscopic procedures focusing on intraoperative live thoracic anatomy. The tool was then integrated into a pre-existing program for first year medical students ($n = 150$), and included cadaver dissection of the thorax and review of clinical problem scenarios of the respiratory system. Students were guided through a viewing of the videotape that demonstrated live anatomy of the thorax (15 minutes) and then asked to complete a 5-point Likert-type questionnaire assessing the video's usefulness. Apart from this, a small group of entirely different set of students was divided into two groups, one group to view the 15-minute video presentation of thoracoscopy and chest anatomy and the other group to attend a 15-minute lecture of chest anatomy using radiological images. Both groups took a 10-item pretest and post-test multiple choice questions examination to assess short-term knowledge gained.

RESULTS: Of 150 medical students, 119 completed the questionnaires, 88.6% were satisfied with the thoracoscopic video as a teaching tool, 86.4% were satisfied with the quality of the images, 69.2% perceived it to be beneficial in learning anatomy, 96.2% increased their interest in learning anatomy, and 88.5% wanted this new teaching tool to be implemented to the curriculum. Majority (80.7%) of the students increased their interest in surgery as a future career. Post-test scores were significantly higher in the thoracoscopy group ($P = 0.0175$).

CONCLUSION: Incorporating live surgery using thoracoscopic video presentation in the gross anatomy teaching curriculum had high acceptance and satisfaction scores from first year medical students. The video increased students' interest in learning, in clinically applying anatomic fact, and in surgery as a future career.

Key words:

Medical students, thoracic anatomy, thoracoscopy

Over the last 15 years, teaching anatomy has faced many challenges. The component of anatomy in the undergraduate medical curricula decreased, and less emphasis is placed on teaching anatomy via dissection.^[1] Since 2001, there has been a decline in the use of cadavers for anatomical dissection studies because of health and safety issues,^[2] high cost of maintaining specimens,^[2,3] and employing trained staff.^[3]

The development and use of computers, 3D medical visualization, and interactive multimedia have allowed the development of computer-based applications.^[4,5] Computers offered the potential for anatomy to be organized in a more compact and logical way. Nowadays, the study of living anatomy includes medical imaging technologies, such as X-ray, computerized tomography (CT), magnetic resonance imaging, and ultrasound.^[6] These new systems make broad-based training experiences available for medical students at all levels. Medical students acquire proficiency and gain confidence in the ability to perform a wide variety of techniques

long before they need to use them clinically. They also allow students to rehearse and refine basic operative procedures, using an unlimited pool of virtual patients manifesting a wide range of anatomic and pathologic variations.

Minimal Invasive Surgery (MIS), a procedure involving internal inspection of the abdominal and pleural cavity, has become very increasingly popular since the early 1980's because of its direct visualization of the body cavity including laparoscopy for exploring abdominal anatomy and thoracoscopy for chest anatomy.^[7] MIS, together with CT with 3-dimensional reconstructions showed great potential in improving both healthcare and medical education.^[8] If this is so, then MIS thoracoscopy can be a useful teaching tool. It can offer a link between clinical medicine and basic science by offering students to view and review chest wall, pleural space, pulmonary and mediastinal anatomy in a living person. However, the magnitude on how MIS thoracoscopy can be a useful teaching tool is yet to be known and published. This study aimed

Access this article online
Quick Response Code:

Website: www.thoracicmedicine.org
DOI: 10.4103/1817-1737.98847

to develop a new video-based educational tool designed for learning anatomy based on thoracoscopic video segments captured during live surgery and determine if this new teaching tool increase students' knowledge and/or motivate them to learn anatomy, much more take surgery as their future career.

Methods

The study was of two parts; Part I - Development of a new video-based teaching tool, and Part II – Evaluation of the new video-based teaching tool.

The development of the new video-based teaching tool involved several stages.

- Pre-production stage – which started with thorough research of available literatures and materials need to develop this new teaching tool. This stage also involved the formulation of the storyboard, script, shooting schedule, acquiring permissions, length of video needed, and securing the location where the shooting was conducted.
- Shooting stage – the actual shoot was conducted on 15 different thoracic surgeries in the operating room. With every thoracic surgery performed, we used a small video camera that was introduced to the patient's chest through a 5-mm fiberoptic scope at 30-degree angle of visualization. Thoracic surgeries included biopsies for the diagnosis of pulmonary, pleural, or mediastinal pathology, decortications for empyema, pleurodesis for pleural effusions and pneumothorax, wedge resections of lung masses, resections of mediastinal or pleural masses and lung cancer.
- Post-production – Rushes from each 30-minute recordings from the 15 thoracic surgeries were assembled and edited one by one. Recordings were supplemented with anatomical landmark segments in order to produce a 30- to 45-minute video covering the essentials of thoracic anatomy. A panel comprising two thoracic surgeons, two surgical educators, an anatomist, and an undergraduate medical students' educator was formed to review the content of the video with regards to appropriateness and clarity of the video for teaching. To test the visual and anatomical quality of the finished product, we approached a small group of naïve subjects comprised of educators and surgeons after final editing.

To evaluate the satisfaction, motivation of students and usefulness of the newly developed video teaching tool, we sent emails to 119 first year medical students during their respiratory block for viewing of the video, which demonstrated live anatomy of the thorax for 15 minutes. A surgeon was present to guide and explain the different steps of the procedure showing the participants the important anatomical landmarks of the chest and the thorax. At the end of the presentation, participants were asked to fill up a 6-item Likert-type survey questionnaire with questions related to their experience with the presentation on thoracic anatomy. Scores on the individual items of the Likert questionnaire were summarized with descriptive statistics using percentages for each score and mean \pm standard deviation for the average score of the whole group.

To evaluate gain in knowledge with the use of the newly developed video-based teaching tool, we invited a different

set of students for a pretest – post-test recall system. Twenty-six medical students (who were not part of the video demonstration/Likert survey) were divided into two groups randomly (first in line and all odd-numbered position in one group, and 2nd and all even-numbered position in the other group). Both groups were given a 10-item multiple choice questions (MCQ) on chest and thorax anatomy. After the pretest, one group was guided by a thoracic surgeon through viewing of the newly developed video-based teaching tool (thoracoscopic video) for 15 minutes and the other group was guided by a radiologist through viewing of a reconstructed 3-dimensional CT image of the chest and thorax anatomy. After the presentations, a post-test which consisted of the same questions as the pretest was given to all students of both groups. For testing short-term knowledge of chest anatomy, results from both groups were compared to see if this new teaching modality has improved short-term knowledge of chest anatomy. MCQ scores (Pretest *vs* Post-test) were compared in between the two groups (Radiology *vs* the MIS thoracoscopy group) using *t*-test. A *P* value of <0.05 was considered statistically significant.

Results

One hundred nineteen first year medical students aged 21 to 22 years participated in the survey. All were males. Table 1 shows that 88.6% of the participants were satisfied with the teaching session using thoracoscopic video presentation as a tool to teach thoracic anatomy, 3.8% remained neutral, and 7.7% were dissatisfied of the session. The thoracoscopic video presentation was thought to be beneficial in 69.2% of respondents, 23.1% remained undecided, and 7.7% perceived no benefits to their understanding of anatomy. Most of the participants (88.5%) were satisfied with the presentation and they wanted this tool to be implemented to the anatomy curriculum, whereas 7.7% remained neutral in their decision, and 3.8% would not recommend this tool to be part of the curriculum. Majority of the participants (96.2%) agreed that the presentation increased their interest in learning anatomy, whereas 3.8% were dissatisfied. Many participants (84.6%) were satisfied with the overall quality of the images used in the presentation, 3.7% remained undecided, and 11.6% were dissatisfied with the quality of the images. Figure 1 shows a screenshot from the MIS thoracoscopic video. When participants were asked about whether thoracoscopy increased their interest in surgery as future career, 80.7% thought that this new teaching tool increased their interest in surgery as future career, whereas 11.6% remained undecided, and 7.7% strongly disagreed.

Table 2 shows the short-term knowledge gained among the 26

Table 1: Responses of 119 medical students to questionnaires on satisfaction of the new video-based teaching tool

Questionnaire items	Satisfaction (%)
Thoracoscopy as a new teaching tool	88.6
Thoracoscopy adds to understanding of anatomy	69.2
Implementation of thoracoscopy to anatomy curriculum	88.5
Increase interest to learn anatomy	96.2
Quality of thoracoscopic images	86.4
Increase interest to take surgery as future career	80.7

randomized participants. The mean pre-test scores between the MIS thoracoscopy group (6.33 ± 1.63 , 95% confidence interval (CI) of ± 0.89 with range of 5.44 to 7.22) was not significantly different ($P = 0.6964$) from the radiology group (6.09 ± 1.38 , 95% CI of ± 0.75 and range of 5.34 to 6.84). Mean post-test scores were also not significantly different ($P = 0.1511$) between both groups (6.40 ± 1.59 and 5.55 ± 1.21 , respectively). Mean post-test scores decreased in the Radiology group (6.09 ± 1.38 , 95% CI of ± 0.75 pretest to 5.55 ± 1.21 , 95% CI of ± 0.66 post-test, $P = 0.3408$). On the other hand, the mean post-test score of the MIS thoracoscopy group increased from 6.33 ± 1.63 , 95% CI of ± 0.89 pre-test to a post-test mean of 6.40 ± 1.59 , 95% CI of ± 0.86 . ($P = 0.9061$).

The Radiology group showed a mean decrease in the overall MCQ scores by $8.96 \pm 11.75\%$, 95% CI ± 6.39 , whereas the MIS group showed a mean increase in the overall MCQ scores by $1.05 \pm 2.35\%$, 95% CI ± 1.28 . There was a significant difference in the overall mean changes in the MCQ scores between the two groups ($P = 0.0175$) [Figure 2].

Discussion

Our results showed 88.6% satisfaction with the teaching session using MIS thoracoscopy as a new tool to teach thoracic anatomy. This satisfaction rate is high. In fact, not only were the students satisfied with MIS thoracoscopy, but 69.2% perceived benefit from the presentation. The rate for success if MIS thoracoscopy will be implemented as a teaching tool will be very high considering 88.5% of the students responded positively toward the implementation of this new teaching tool into the medical curriculum. The high quality of images further increased the satisfaction rate and interest of the students. Heightened interest plus good quality of images equals better retention and better recall. Although some of our participants were dissatisfied with the overall quality of the images, these issues can be easily resolved through enhancement using the most advanced digital technologies. Quality of images will significantly improve in the future.

Based on the short-term knowledge testing that we have obtained from the 26 participants, though were not significant, there were improvements in the test scores, particularly those who attended the MIS thoracoscopy session. Although the observation was conducted in a very short gap of time, we were able to observe and show relative differences in the pretest and post-test scores. In fact, students who had viewing of the MIS thoracoscopy showed increase in test scores by a mean of 1.05, by far better to students of the radiology session, whose scores decreased significantly by 8.96 [Figure 2]. This could be attributed mainly to the lack of interest of students to learn based on how the presentation was done and the lack of a stimulating factor which a video presentation possesses.

Another important aspect of this study that we have so far disclosed is the increase in the students' interest to take surgery as a future career. We have shown that the implementation of this new teaching tool has significantly increased the students' interest to take surgery as a future career. In both parts of our study, students are interested to take surgery as a future career.

Therefore, to incorporate this into a PBL curriculum, we agree

with prior studies that imaging techniques have great potentials in both healthcare and medical education.^[5-7] We have shown that the development of technically advanced videos from thoroscopic procedures will further enhance learning of the thoracic anatomy through positive stimulation, enhancement of students' interest, and acquisition and retention of knowledge even more than just radiological images. The use of live surgery via thoroscopic video presentation in the gross anatomy teaching curriculum was well perceived by medical students and students expressed high satisfaction scores. The video increased student's interest in learning, in clinically applying anatomic fact, and in selecting surgery as a future career. However, we think this new teaching tool will supplement rather than replacing the existing standard method of teaching anatomy such as cadaver dissection. Such teaching tool is an area for future research to evaluate and assess its usefulness in teaching and learning thoracic anatomy.

Table 2: Test scores of 26 students on thoracic anatomy

	Thoracoscopy group	Radiology group	P value
Number of participants	13	13	
Pretest scores, mean \pm SD	6.33 ± 1.63	6.09 ± 1.38	0.6964
Post-test scores, mean \pm SD	6.40 ± 1.59	5.55 ± 1.21	0.1511
Percent change in test scores	+1.05	-8.96	0.0175

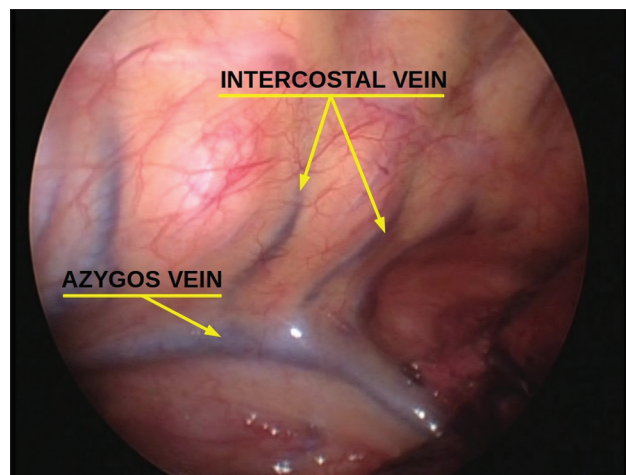


Figure 1: A screenshot taken from the MIS thoroscopic video showing the intercostal veins and the azygous vein

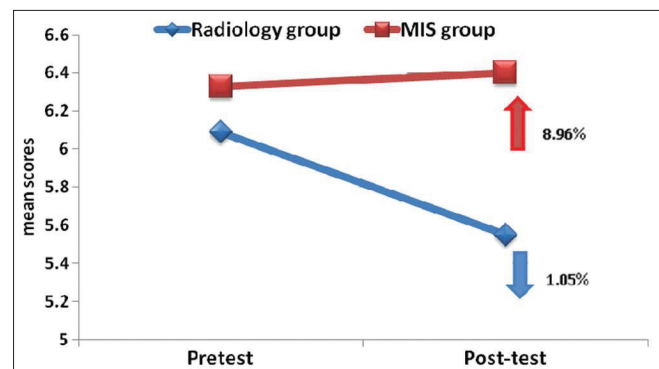


Figure 2: Changes in the MCQ scores (pretest to post-test)

Acknowledgment

This work was funded by College of Medicine Research Center, Deanship of Scientific Research, King Saud University, Riyadh, Saudi Arabia.

References

1. Needham C, Wilkinson C, Soames R. Virtual reality haptic human dissection. *Stud Health Technol Inform* 2011;163:397-9.
2. Gogalniceanu P, Madani H, Paraskeva PA, Darzi A. A minimally invasive approach to undergraduate anatomy teaching. *Anat Sci Educ* 2008;1:46-7.
3. Turney BW. Anatomy in a modern medical curriculum. *Ann R Coll Surg Engl* 2007;89:104-7.
4. Höhne KH, Pommert A, Riemer M, Schiemann T, Schubert R, Tiede U, et al. New kinds of 3-dimensional atlases of the anatomy and function of the human body. *Z Arztl Fortbild (Jena)* 1995;89:430-5.
5. Cahill DR, Leonard RJ, Marks SC Jr. A comment on recent teaching of human anatomy in the United States. *Surg radiol Anat* 2000;22:69-71.
6. Kaspar M, Dech F, Parsad NM, Silverstein JC. Web-based stereoscopic visualization for the global anatomy classroom. *Stud Health Technol Inform* 2010;163:264-70.
7. Jimenez AM, Aguilar JF. Laparoscopy: Learning a new surgical anatomy? *Anat Sci Edu* 2009;2:81-3.
8. Snow RE, Gardner H, Salomon G. *Interaction of Media, Cognition and Learning* (paperback). Hillsdale, New Jersey: Lawrence Erlbaum Associates (Publisher); 1994.

How to cite this article: AlNassar SA, Hajjar W, Rahal S, Clifton J, Finley R, Sidhu R. The use of thoracoscopy to enhance medical students' interest and understanding of thoracic anatomy. *Ann Thorac Med* 2012;7:145-8.

Source of Support: College of Medicine Research Center, Deanship of Scientific Research, King Saud University, Riyadh, Saudi Arabia.,
Conflict of Interest: None declared.

New features on the journal's website

Optimized content for mobile and hand-held devices

HTML pages have been optimized of mobile and other hand-held devices (such as iPad, Kindle, iPod) for faster browsing speed.

Click on **[Mobile Full text]** from Table of Contents page.

This is simple HTML version for faster download on mobiles (if viewed on desktop, it will be automatically redirected to full HTML version)

E-Pub for hand-held devices

EPUB is an open e-book standard recommended by The International Digital Publishing Forum which is designed for reflowable content i.e. the text display can be optimized for a particular display device.


Click on **[EPub]** from Table of Contents page.

There are various e-Pub readers such as for Windows: Digital Editions, OS X: Calibre/Bookworm, iPhone/iPod Touch/iPad: Stanza, and Linux: Calibre/Bookworm.

E-Book for desktop

One can also see the entire issue as printed here in a 'flip book' version on desktops.

Links are available from Current Issue as well as Archives pages.

Click on  View as eBook