



Contents lists available at ScienceDirect

International Journal of Surgery Case Reports

journal homepage: www.casereports.com

Colo-colonic intussusception due to large submucous lipoma: A case report



Luiza Ohasi de Figueiredo (M.D.) (Fellow of Surgery)^{a,*},
 D.P.C. Garcia (Ph.D) (Associate Professor General Surgeon)^b,
 Luiz Ronaldo Alberti (Ph.D) (Associate Professor General Surgeon)^c, R.A. Paiva^d,
 Andy Petroianu (M.D., Ph.D.) (Professor of Surgery)^e,
 Luiza Barbosa Paolucci (M.D.) (Fellow of Surgery)^f,
 M.R.L.G. Costa (M.D.) (Fellow of Surgery)^f

^a Hospital Felício Rocho, Belo Horizonte, MG, Brazil^b Department of Surgery, Instituto de Ensino e Pesquisa da Santa Casa, Belo Horizonte, MG, Brazil^c Department of Surgery, FMUFMG and Instituto de Ensino e Pesquisa da Santa Casa, Belo Horizonte, MG, Brazil^d Colorectal Surgeon at Hospital Felício Rocho, Av do Contorno 9530, 30110-130, Belo Horizonte, MG, Brazil^e FMUFMG and Instituto de Ensino e Pesquisa da Santa Casa, Belo Horizonte, MG, Brazil^f Hospital Felício Rocho, Belo Horizonte, MG, Brazil

ARTICLE INFO

Article history:

Received 16 August 2016

Accepted 19 September 2016

Available online 21 September 2016

Keywords:

Colo-colonic intussusception

Chronic abdominal pain

Submucous lipoma

ABSTRACT

INTRODUCTION: Intussusception in adult is rarely caused by idiopathic conditions. Main causes are inflammatory diseases, benign or malignant tumors and motility disorders. As a benign cause, lipomas appear as a particularly rare gastrointestinal intraluminal tumor occurring with highest incidence in the colon, mostly in the caecum and ascending colon.

PRESENTATION OF CASE: A 57-year-old male patient was admitted at the surgical emergency in Belo Horizonte, with history of chronic and intermittent diffuse abdominal pain, associated with variations of his bowel habits and rare episodes of vomiting starting around 3 days prior to admission.

DISCUSSION: Intussusception is the cause of adult symptomatic bowel obstruction in 1% of the cases and its colocolonic occurrence represents 17% of all intestinal intussusceptions in adults. The reported case presents itself as even rarer considering its evaluation according to the epidemiological statistics of 1:5 men/women ratio and lipoma's most common location being the right colon. Intussusception and intestinal obstructions caused by intraluminal lipomas are not often described in the literature and its occurrence is directly related to its size, usually larger than 2 cm diameter. The management of lipomatous intraluminal lesions of the colon is traditionally surgical, and it allows a selective resection, depending on the size of the tumor, length of intussusception, and the amount of inflammation.

CONCLUSION: Patients with chronic abdominal symptoms and semi-obstruction caused by intussusception are rarely diagnosed before surgery unless there is a high index of suspicion. Colonoscopy contributes to diagnosis given that it provides direct visualization and biopsy.

© 2016 The Authors. Published by Elsevier Ltd on behalf of IJS Publishing Group Ltd. This is an open access article under the CC BY-NC-ND license (<http://creativecommons.org/licenses/by-nc-nd/4.0/>).

1. Introduction

Intussusception is widely defined as the pathology that derives from the invagination of an intestinal loop into the distal portion of the same intestinal segment. It is argued that any lesion in the bowel wall or irritant within the lumen that alters normal

peristaltic bowel activity could initiate the invagination process. Rutherford et al. described it as a major pediatric condition of idiopathic or viral causes, with adult occurrence reaching nearly 5% of all cases of intussusception and it represents 1% of all causes of bowel obstruction in adults [1–3,8].

However, unlike child occurrence, adult intussusception is rarely caused by idiopathic conditions. In adults, causes include inflammatory diseases of the small and large intestines, benign or malignant tumors, adhesions and other mechanical conditions impairing peristalsis leading to chronic diarrhea and motility disorders [1,3,5,6]. According to El-Sergany et al., the higher percentage of intussusception in adults – 65% – occurs due to malignant or

* Corresponding author at: Rua Franz Schubert 310 - Chácaras Reunidas Santa Teresinha, Contagem - MG, CEP: 32183-120, Brazil.

E-mail addresses: luiza.ohasi@uol.com.br, luizaohasi@gmail.com (L.O. de Figueiredo).

benign neoplasms [1,2], noted that malignant tumors outweigh the incidence of benign [12]. As a benign cause, lipomas appear as a particularly rare gastrointestinal intraluminal tumor occurring with highest incidence in the colon, mostly in the caecum and ascending colon. They are usually asymptomatic, and its discovery is often incidental during routine procedures. The average age of affected adults is between 50 and 60 years old and it occurs more often in women [4,8,10–12].

This report shows a rare case of colo-colonic intussusception of the transverse colon caused by a large lipoma.

2. Presentation of case

A 57-year-old male patient was admitted at the surgical emergency wing of a high complexity hospital in Belo Horizonte, with history of chronic and intermittent diffuse abdominal pain, associated with variations of his bowel habits and complaints of worsened intermittent, sharp, non-radiating, colicky and diffuse abdominal pain, associated with rare episodes of vomiting starting around 3 days prior to admission. He also referred bowel habits alternating between diarrhea and constipation ever since the onset of the abdominal pain, but never presented signs of complete intestinal obstruction, according to the history of the symptoms. Patient denied presence of mucus, melena or active bleeding and referred that those symptoms were never as intense as presented in that occasion. He had no previous abdominal surgeries or prior comorbidities in his medical history.

On initial physical examination, the patient had stable vital signs, was hydrated, had a soft abdomen but presented tenderness over the left upper quadrant of his abdomen to deep palpation, without distention or peritoneal irritation signs. Peristalsis was physiological. Abdominal ultrasonography showed no signs of bowel distention, but revealed a heterogeneous hypodense mass inside the left colon (Fig. 1). Complementary abdominal CT scans showed descending colo-colonic intussusception causing partial obstruction due to intraluminal lipomatous mass of approximately

6 cm diameter (Fig. 2). Lab work on admission showed an CPR of 28, 9 and all other exams were within normal limits.

Since the patient was showing no signs of acute obstruction under physical examination or according with CT scans, he was admitted for further investigation. On his third day of hospitalization, he was submitted to a colonoscopy, for a better assessment of the lesion.

Colonoscopy showed a submucosal mass of fibro-elastic consistency compatible with a lipomatous mass on transverse colon topography filling entirely the colonic lumen, but permitting the transposition of the colonoscope. Mucosa was intact but presented a small area of necrotic tissue, which prevented an attempt to reduce the intussusception. The tissue adjacent to the mass was marked with ink stain. Biopsy was performed and histopathology showed no signs of malignancy and confirmed the mass to be lipomatous with ulcerations and a few necrotic portions with fibrino-leukocytic exudate (Fig. 3).

Patient was stable during all course of hospitalization, presenting diarrhea and maintenance of mild intermittent colicky abdominal pain. He was kept under pain medication and was given intravenous fluids.

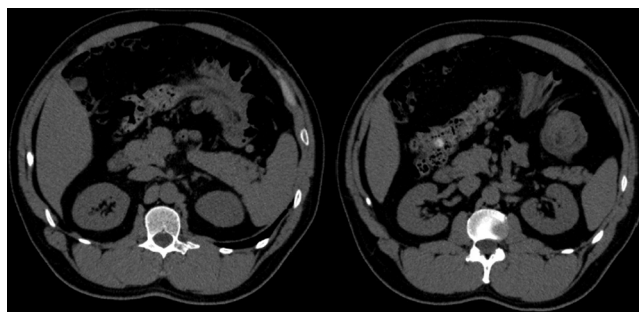


Fig. 2. Tomographic imaging showing colo-colonic intussusception causing partial obstruction due to intraluminal mass of suggested 6 cm with lipomatous aspect.

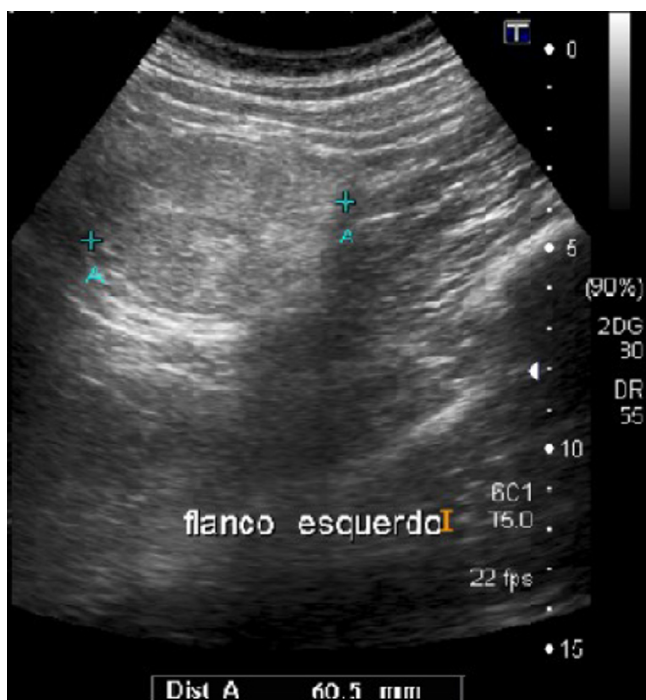

Fig. 1. Ultrasonographic assesment showing heterogeneous mass in the left flank, with an diameter of 60,5 mm.

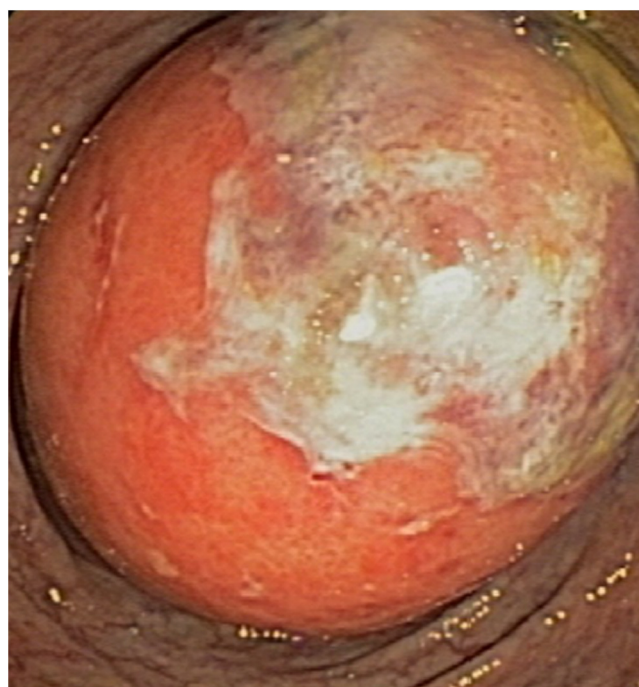


Fig. 3. Colonoscopy showing submucosal mass of fibro-elastic consistency, with intact mucosa but with small area of necrotic tissue.

Later, patient was submitted to a partial colectomy guided by video laparoscopy. The resection of the colonic segment affected by the lipomatous mass (previously marked) took place without previous reduction and reconstruction was performed through primary anastomosis, considering no inflammation or other alterations were present. Histopathological report of surgical piece also showed no signs of malignancy and confirmed the mass to be of benign lipomatous composition. Patient evolved uneventfully during the post-operative recovery period and was discharged five days after surgical procedure and presented complete remission of the symptoms.

3. Discussion

Intussusception is the cause of adult symptomatic bowel obstruction in 1% of the cases and its colocolonic occurrence represents 17% of all intestinal intussusceptions in adults. It is most likely to have a malignant etiology [1,5,7] and, although already described in literature, the occurrence of large lipomatous masses as cause of intussusception and semi-obstructive symptoms remains rare [10–12]. The reported case presents itself as even rarer considering its evaluation according to the epidemiological statistics of 1:5 men/women ratio³ and lipoma's most common location being the right colon [4,8].

Symptomatology of intussusception in adults is non-specific, chronic and ranges more frequently from abdominal complaints, such as pain and distention, obstructive claims like vomiting, nausea and constipation, to less frequent signs, like melena and active bleeding. Nonetheless, diarrhea, intermittent vomiting and other semi-obstructive symptoms are also described in literature, as seen on this case [7,10,12]. Therefore, preoperative diagnosis can be difficult, as half the patients are diagnosed during surgery, and the most accurate imaging method is CT scan [1,3,8].

Lipomas are the second most occurring type of benign gastroenterological neoplasm, following adenomas in the terms of incidence [12]. When symptomatic, this sort of formation usually causes unspecific abdominal manifestations, such as diffuse abdominal pain, bleeding, constipation and intestinal obstruction [4]. Intussusception and intestinal obstructions caused by intraluminal lipomas are not often described in the literature and its occurrence is directly related to its size, usually larger than 2 cm diameter [10,11]. Their presentation is typically submucosal and on the occurrence of intussusception they develop underlying necrosis that enhances the symptomatology of bleeding or hemocult-positive stools [5].

In this kind of patient, the chronic symptomatology is frequently seen due to slow tumoral growth, with progressive worsening of abdominal pain, evolving to partial or complete obstruction. The slow progression of the intraluminal lipomas reinforces the assumption that its discovery is usually incidental. As very few patients end up presenting symptoms up to the ages 50–60, the diagnosis of lipomatosis is often done during routine screening for colorectal cancers or other intestinal disorders [4,10–12].

The management of lipomatous intraluminal lesions of the colon is traditionally surgical, and it allows a selective resection, depending on the size of the tumor, length of intussusception, and the amount of inflammation. Although the reduction of intussusceptions is largely controversial, seeing that its most common cause is underlying malignant neoplasms, the procedure was not considered in this case since the patient did not present full obstruction or other symptoms that would lead to clinical instability. His chronic condition permitted the preliminary assessment including preoperative colonoscopy with histopathological results confirming lipomatous constitution and conduction for laparoscopic resection [2,5,9,10].

4. Conclusion

Patients with chronic abdominal symptoms and semi-obstruction caused by intussusception are rarely diagnosed before surgery unless there is a high index of suspicion. Colonoscopy contributes to diagnosis given that it provides direct visualization and biopsy. It is determined that the treatment is surgical, but there is still questioning on performing reduction prior to the resection due to the risk of malignancy.

In this case, patient's clinical condition combined with possibility of performing CT scan and colonoscopy, which provided an accurate diagnosis, allowed the best surgical choice in the hands of an experienced surgeon.

Conflicts of interest

No conflicts of interest.

Funding

No sources of funding.

Ethical approval

This paper required no ethical approval.

Consent

Written informed consent was obtained from the patient for publication of this case report and accompanying images. A copy of the written consent is available for review by the Editor-in-Chief of this journal on request.

Author contribution

Luiza Ohasi de Figueiredo; Diego Paim Carvalho Garcia; Luiza Barbosa Paolucci; Marilia Ribeiro Lima Gramiscelli Costa – Acquisition and interpretation of data, statistical analysis, manuscript writing, interpretation and reviewing of literature.

Luiz Ronaldo Alberti, Rodrigo de Almeida Paiva, Andy Petroianu – Acquisition and interpretation of data, technical analysis, revision of manuscript.

Guarantor

Luiza Ohasi de Figueiredo.

References

- [1] C.L. Rutherford, B. Alkhaffaf, E. Massa, P. Turner, Colo-colic intussusception secondary to lipomatous polyp in an adult, *BMJ Case Rep.* 2013 (March) (2013), PMID 23462651.
- [2] A. El-Sergany, A. Darwish, P. Mehta, A. Mahmoud, Community teaching hospital surgical experience with adult intussusception: Study of nine cases and literature review, *Int. J. Surg. Case Rep.* 12 (2015) 26–30, PMID 25989258.
- [3] H. Honjo, M. Mike, H. Kusanagi, N. Kano, Adult intussusception: a retrospective review, *World J. Surg.* 39 (January (1)) (2015) 134–138, PMID 25192846.
- [4] N. Howard, N. Pranesh, P. Carter, Colo-colonic Intussusception secondary to a lipoma, *Int. J. Surg. Case Rep.* 3 (2) (2012) 52–54, PMID 22288044.
- [5] T. Lu, Y.M. Chng, Adult Intussusception: Case study, *Perm J.* 2015 Winter; 19(1), 79–81, PMID 25663210.
- [6] T. Azar, D.L. Berger, Adult intussusception, *Ann. Surg.* 226 (August (2)) (1997) 134–138, PMID 9296505.
- [7] S. Yalamarthy, R.C. Smith, Adult intussusception: case reports and review of literature, *Postgrad. Med. J.* 81 (March (953)) (2005) 174–177.
- [8] G. Lianos, N. Xeropotamos, C. Bali, G. Baltogiannis, E. Ignatiadou, Adult bowel intussusception: presentation, location, etiology, diagnosis and treatment, *G. Chir.* 34 (September–October (9–10)) (2013) 280–283, PMID 24629817.

- [9] S. Yakan, C. Caliskan, A.G. Denecli, M.A. Korkut, Intussusception in adults: clinical characteristics, diagnosis and operative strategies, *World J. Gastroenterol.* 15 (April (16)) (2009) 1985–1989, PMID 19399931.
- [10] Z. Allos, D. Zhubandykova, Large benign submucosal lipoma presented with descending colonic intusseption in an adult, *Am. J. Case Rep.* 14 (July) (2013) 245–249, PMID 23869248.
- [11] M. Mohamed, K. Elghawy, D. Scholten, K. Wilson, M. McCann, Adult sigmoidorectal intussusception related to colonic lipoma: a rare case report with an atypical presentation, *Int. J. Surg. Case Rep.* 10 (2015) 134–137, PMID 25839433.
- [12] P.A. Ongom, H. Wabinga, R. Lukande, A giant intraluminal lipoma presenting with intussusception in an adult: a case report, *J. Med. Case Rep.* 29 (October (6)) (2012) 370, PMID 23107601.

Open Access

This article is published Open Access at scimedirect.com. It is distributed under the [IJSCR Supplemental terms and conditions](#), which permits unrestricted non commercial use, distribution, and reproduction in any medium, provided the original authors and source are credited.