

Case Report

## Lumps, Bumps and GI Bleeding

Michael Perry, Nicholas Kelly, Maurice Loughrey, Michael Hyland, Grant Caddy

Accepted 8 September 2011

### ABSTRACT

We report the case of a patient presenting with melaena and anaemia secondary to a metastatic phyllodes tumour of the breast. This is an unusual clinical presentation from a breast tumour that rarely metastasise.

### CASE

64 year old woman presented with a one-week history of melaena and increasing lethargy. Past medical history included a right breast lumpectomy in 2007 for a borderline phyllodes tumour, hypertension and irritable bowel syndrome. Physical examination was unremarkable. Clinical Observations on admission were within normal limits. Laboratory tests on admission showed: haemoglobin 7.4g/dL, C-reactive protein 138mg/L and albumin 26g/L. Other blood investigations were within normal limits. Ultrasound scan of the abdomen was unremarkable. Gatroscopy showed non-erosive gastritis with several nodules on the greater curve of the mid-body (fig. 1). Multiple biopsies were taken. Chest X-Ray showed lesions suspicious of pulmonary metastases. Computerised Tomography (CT) scan showed multiple pulmonary metastases, a 12mm right hilar lymph-node and enlarged para-aortic lymph nodes. No primary lesion was identified. A CT guided biopsy of an apical pulmonary nodule was undertaken.

Histological examination of the gastric biopsies showed an ulcer with an underlying population of pleomorphic spindle cells displaying high mitotic index. The spindle cells lay

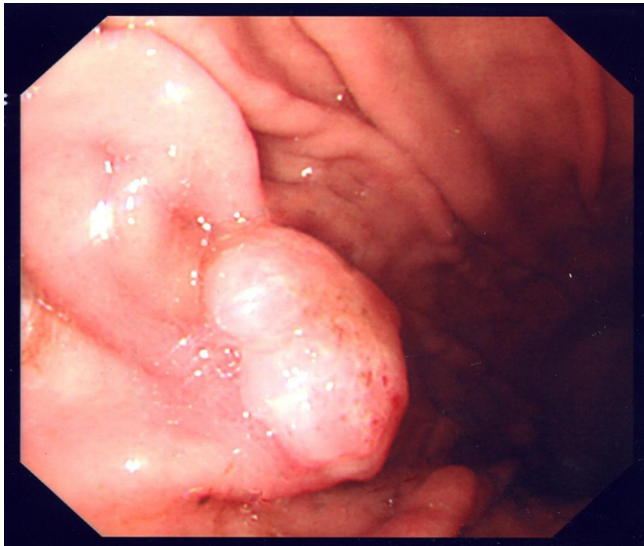

Fig 1.

within a myxoid stroma and surrounded by native glandular gastric structures (fig 2). Immunohistochemistry showed diffuse tumour cell positivity for smooth muscle actin and negativity for epithelial markers, CD117 (KIT), DOG1, S100, desmin, oestrogen receptor, and CD34.

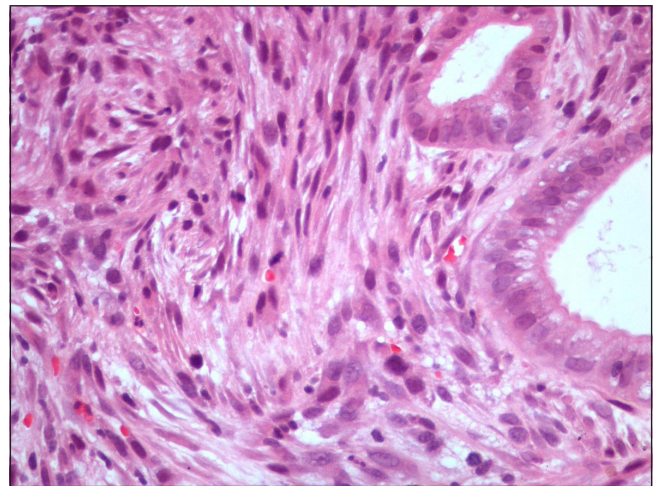


Fig 2.

A diagnosis of metastatic phyllodes tumour from the breast was made, based on the morphological and immunohistochemical features, and a comparison with those of the previously diagnosed primary breast tumour. Identical features were also seen within a biopsy from one of the pulmonary nodules.

### DISCUSSION

Phyllodes tumours are fibro-epithelial neoplasms which comprise less than 1% of all breast tumours with an incidence of 1 in 100,000. The tumours can be classified histologically into benign, borderline and malignant based on morphological features. The primary tumour in this case was classified as borderline with respect to malignant potential. Primary treatment is surgical excision. These tumours recur locally at an approximate rate of 15%. 15-33% of phyllodes tumours are of the malignant subtype of which 2-25% will metastasise haematogously with the commonest sites being lung and bones. "Borderline" phyllodes tumours may also

Dept. of Gastroenterology, Senior House Officer, Ulster Hospital Dundonald, Belfast, Northern Ireland

Correspondence to Dr Michael Perry,  
mperry02@qub.ac.uk

rarely metastasise.<sup>1+2</sup> A case series of 33 breast phyllodes tumours showed 7% of patients developed distant metastases.<sup>3</sup> None of their patients with metastases had primary tumours classified as benign or borderline.

Lobular carcinomas are the most common type of breast malignancy to metastasise to the gastrointestinal tract; more frequently to the stomach than the colon or rectum.<sup>4+5</sup> Consensus is that disease spread to the gastrointestinal tract from the breast is underdiagnosed. In each of these case series reports they advised a high index of suspicion in patients presenting with suspected primary gastrointestinal malignancy who had a history of breast neoplasia.

There have been some trials utilising chemotherapy for metastatic phyllodes tumour, however current consensus is that it has no role in the treatment of these tumours and that management is palliative.<sup>6</sup>

The authors have no conflict of interest

#### REFERENCES:

1. Guerrero MA, Ballard BR, Grau AM. Malignant phyllodes tumor of the breast: review of the literature and case report of stromal overgrowth. *Surg Oncol.* 2003;**12**(1):27-37.
2. Lenhard MS, Kahlert S, Himsl I, Ditsch N, Untch M, Bauerfeind I. Phyllodes tumour of the breast: clinical follow-up of 33 cases of this rare disease. *Eur J Obstet Gynaecol Reprod Biol.* 2008;**138**(2):217-21.
3. Taal BG, Peterse H, Boot H. Clinical presentation, endoscopic features, and treatment of gastric metastases from breast carcinoma. *Cancer.* 2000;**89**(11):2214-21.
4. Schwarz RE, Klimstra DS, Turnbull AD. Metastatic breast cancer masquerading as gastrointestinal primary. *Am J Gastroenterol.* 1998;**93**(1):111-4.
5. Pectasides D, Psyrris A, Pliarchopoulou K, Floros T, Papaxoinis G, Skondra M, *et al.* Gastric metastases originating from breast cancer: report of 8 cases and review of the literature. *Anticancer Res* 2009;**29**(11):4759-63.
6. Fou A, Schnabel FR, Hamele-Bena D, Wei XJ, Cheng B, El Tamer M, *et al.* Long-term outcomes of malignant phyllodes tumors patients: an institutional experience. *Am J Surg.* 2006;**192**(4):492-5.