

# Toxoplasmosis in a patient receiving ixekizumab for psoriasis



Yolanka Lobo, BPhysio, MBBS,<sup>a</sup> Teagan Holland, RN,<sup>a</sup> and Lynda Spelman, MBBS, FACD<sup>a,b</sup>  
Queensland, Australia

**Key words:** biologics; immunocompromised; ixekizumab; psoriasis; toxoplasmosis.

## INTRODUCTION

The advent of biologic therapies has greatly improved outcomes for patients with debilitating immune-mediated inflammatory diseases. Complications that have arisen from biologic use include infections by opportunistic pathogens. *Toxoplasma* infection is usually asymptomatic in immunocompetent hosts, and when symptoms do occur, lymphadenopathy is the most common presentation. In immunocompromised hosts, toxoplasmosis is usually a result of reactivation of a dormant infection and is associated with high mortality rates.<sup>1,2</sup> It commonly manifests as meningoencephalitis or disseminated infection.<sup>2</sup> To the best of our knowledge, only 1 case of toxoplasmosis in a psoriatic patient has been documented.<sup>3</sup> Several cases of toxoplasmosis have been reported in nonpsoriatic cohorts after treatment with tumor necrosis factor- $\alpha$  inhibitors.<sup>4,5</sup> The association between ixekizumab, an anti-interleukin 17A monoclonal antibody, and the development of toxoplasmosis in psoriatic patients has not been clearly established. We herein describe a case of toxoplasmosis in a 34-year-old health care worker receiving ixekizumab for chronic plaque psoriasis after 20 months of treatment.

## CASE REPORT

Our patient presented with a 3-month history of dry cough and rhinorrhea associated with tender left axillary lymphadenopathy. She had a history of chronic plaque psoriasis without joint disease since the age of 17 years, affecting her scalp, face, elbows, trunk, knees, and genital region. She was receiving

treatment with ixekizumab at a dose of 80 mg every month. She also had a history of depression. She was not receiving any other medications. The patient denied owning cats but did report consuming rare meat regularly. She had no other risk factors for toxoplasmosis.

Serologic testing was positive for anti-*Toxoplasma* immunoglobulins M (IgM) and G (IgG), with a *Toxoplasma* IgG index of 79.80 (>8.79 = positive), a *Toxoplasma* IgM index of 50.00 (>7.99 = positive), and a low *Toxoplasma* avidity index of 0.06 (<0.20 = low). Results of additional serologic investigations were negative, including those for HIV, cytomegalovirus, Bartonella, Epstein-Barr virus, and Q fever. Ultrasonography of the left axilla demonstrated an enlarged axillary lymph node with a thickened hypoechoic cortex, consistent with a reactive lymph node. An ultrasound-guided core needle biopsy was performed. Histopathologic features were in keeping with reactive adenopathy most likely caused by toxoplasmosis, without evidence of necrosis or lymphoid atypia (Fig 1).

The patient attended the infectious diseases clinic for further evaluation. Serial paired serology demonstrated an increasing IgG titre, a declining IgM titre, and a low *Toxoplasma* IgG avidity index, supportive of recent primary infection. Owing to concern for disseminated *Toxoplasma* infection in an immunocompromised patient, a 14-day treatment course with pyrimethamine, leucovorin, and clindamycin was completed. Our patient remains without recurrence of lymphadenopathy and *Toxoplasma* infection 5 years posttreatment. She continues to follow

From Veracity Clinical Research, Queensland<sup>a</sup>; and Queensland Institute of Dermatology.<sup>b</sup>

Funding sources: None.

Conflicts of interest: Dr Spelman has served on the advisory boards for Eli Lilly and Company and as an investigator for Eli Lilly and Company clinical trials. Drs Lobo and Holland have no conflicts of interest to declare.

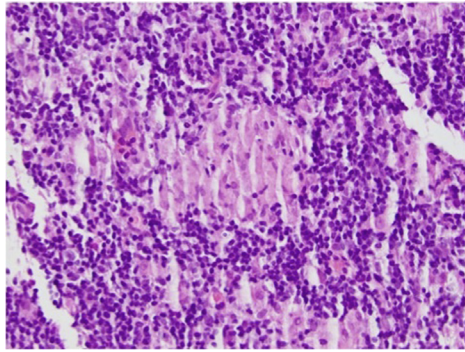
Correspondence to: Dr Yolanka Lobo, Veracity Clinical Research, Ste 18, Level 1/250 Ipswich Road, Woolloongabba, QLD 4102, Australia. E-mail: [yolanka\\_lobo@yahoo.com](mailto:yolanka_lobo@yahoo.com).

JAAD Case Reports 2020;6:204-6.

2352-5126

© 2020 by the American Academy of Dermatology, Inc. Published by Elsevier, Inc. This is an open access article under the CC BY-NC-ND license (<http://creativecommons.org/licenses/by-nc-nd/4.0/>).

<https://doi.org/10.1016/j.jidcr.2020.01.005>



**Fig 1.** Histopathologic examination of lymph node biopsy. Reactive nodal changes characterized by lymphoid hyperplasia and clusters of epithelioid histiocytes forming an ill-defined noncaseating granuloma that is present in the center of the field of view. (Hematoxylin-eosin stain; original magnification:  $\times 400$ .) (Written informed consent was obtained from the patient for publication of this case report and accompanying images.)

up in the dermatology clinic every 3 months while on ixekizumab.

## DISCUSSION

*Toxoplasma gondii* is a protozoan parasite that infects up to one-third of the world's population.<sup>2</sup> Members of the cat family are definitive hosts for *T gondii*. Human beings are infected by ingestion of food or water contaminated by the feces of infected cats, ingestion of undercooked or raw meat containing *Toxoplasma* cysts, organ transplantation, or receiving blood from an infected donor.

Mucocutaneous candidiasis is the most frequent type of opportunistic infection observed in ixekizumab-treated psoriatic patients.<sup>6</sup> This finding is consistent with the mechanism of action of ixekizumab because interleukin 17A is known to have a role against mucocutaneous infections. Toxoplasmosis has been infrequently described in association with the use of biologic agents. A meta-analysis of 70 randomized trials found that among patients with rheumatoid arthritis, biologic agents were associated with 1.7 excess infections per 1000 patients.<sup>7</sup> In the Safety Assessment of Biologic Therapy (SABER) study, the rate of nonviral opportunistic infections was higher in tumor necrosis factor- $\alpha$  inhibitor users than in nonbiologic disease-modifying antirheumatic drug users with autoimmune diseases. The most common opportunistic infections described were pneumocystosis, nocardiosis/actinomycosis, and tuberculosis. Of these nonviral opportunistic infections, the frequency of toxoplasmosis was 1.3%.<sup>8</sup>

To the best of our knowledge, only 1 other case of toxoplasmosis in a psoriatic patient has been

reported.<sup>3</sup> This patient received a diagnosis of severe toxoplasmosis while receiving ustekinumab for chronic psoriasis vulgaris. Ustekinumab was discontinued indefinitely. Several cases of toxoplasmosis have been reported in nonpsoriatic cohorts after treatment with tumor necrosis factor- $\alpha$  inhibitors.<sup>4,5,9</sup> Pulivarthi et al<sup>4</sup> described a case of cerebral toxoplasmosis in a patient receiving methotrexate and infliximab for rheumatoid arthritis. Lassoued et al<sup>9</sup> documented 2 cases of *Toxoplasma* chorioretinitis after tumor necrosis factor- $\alpha$  inhibitor treatment with adalimumab, infliximab, and etanercept for rheumatoid arthritis. Clinicians should consider toxoplasmosis when any patient receiving biologic therapy presents with new ocular, cognitive, or neurologic deficits.

Clues to the diagnosis of toxoplasmosis include owning cats; recent travel to highly endemic areas; eating rare beef, rare lamb, cured meat, or raw molluscan shellfish; drinking unpasteurized goat's milk; and working with meat.<sup>10</sup> A review of cases of toxoplasmosis in nonallografted hematopoietic stem cell transplant patients found a high global mortality rate of 43%.<sup>1</sup> We are fortunate that our patient did not develop serious infection and was able to continue ixekizumab without interruption.

Psoriasis is a chronic disease that requires prolonged treatment, emphasizing the importance of long-term safety data. Data from randomized controlled trials may be inadequate when determining the incidence and prevalence of opportunistic infections in patients receiving biologics, because the rates of infection are usually low and the follow-up duration is frequently too short. Large population-based registries may therefore provide the best data. Furthermore, there is a lack of evidence to support the benefits of prescreening patients and primary prophylaxis for toxoplasmosis. Knowledge of the patient's serostatus would certainly enable close monitoring and the ability to provide early intervention as needed.

## CONCLUSION

Biologic therapies are increasingly being considered in patients with chronic plaque psoriasis. As such, the risk of opportunistic infections should be considered before initiation of any biologic agent. This case highlights the importance of counseling for high-risk behaviors that predispose patients receiving biologics to potentially life-threatening *Toxoplasma* infection. Patients should be counseled in regard to the potential risks of ingesting and interacting with sources of *Toxoplasma*, including eating undercooked meat

and interacting with cats. Clinicians must be encouraged to maintain a high index of suspicion for toxoplasmosis in patients receiving biologic agents and consider reporting cases via publishing case reports or using national adverse drug reaction reporting systems.

The authors wish to thank our patient for allowing us to share her story.

#### REFERENCES

1. Scerra S, Coignard-Biehler H, Lanternier F, et al. Disseminated toxoplasmosis in non-allografted patients with hematologic malignancies: report of two cases and literature review. *Eur J Clin Microbiol Infect Dis*. 2013;32(10):1259-1268.
2. Halonen SK, Weiss LM. Toxoplasmosis. *Handb Clin Neurol*. 2013;114:125-145.
3. Muslimani MA, Di Palma-Grisi J. Severe acute toxoplasmosis infection following ustekinumab treatment in a patient with psoriasis vulgaris. *BMJ Case Rep*. 2019;12(8):e230415.
4. Pulivarthi S, Reshi RA, McGary CT, et al. Cerebral toxoplasmosis in a patient on methotrexate and infliximab for rheumatoid arthritis. *Intern Med*. 2015;54(11):1433-1436.
5. Nardone R, Zuccoli G, Brigo F, et al. Cerebral toxoplasmosis following adalimumab treatment in rheumatoid arthritis. *Rheumatology (Oxford)*. 2014;53(2):284.
6. Langley RG, Kimball AB, Nak H, et al. Long-term safety profile of ixekizumab in patients with moderate-to-severe plaque psoriasis: an integrated analysis of 11 clinical trials. *J Eur Acad Dermatol Venereol*. 2019;33(2):333-339.
7. Kourbeti IS, Ziakas PD, Mylonakis E. Biologic therapies in rheumatoid arthritis and the risk of opportunistic infections: a meta-analysis. *Clin Infect Dis*. 2014;58(12):1649-1657.
8. Baddley JW, Winthrop KL, Chen L, et al. Non-viral opportunistic infections in new users of tumour necrosis factor inhibitor therapy: results of the Safety Assessment of Biologic Therapy (SABER) study. *Ann Rheum Dis*. 2014;73(11):1942-1948.
9. Lassoued S, Zabraniecki L, Marin F, et al. Toxoplasmic chorioretinitis and antitumor necrosis factor in rheumatoid arthritis. *Semin Arthritis Rheum*. 2007;36(4):262-263.
10. Jones JL, Dargelas V, Roberts J, et al. Risk factors for *Toxoplasma gondii* infection in the United States. *Clin Infect Dis*. 2009;49(6):878-884.