

# Abnormal Development of *Haemaphysalis qinghaiensis* (Acari: Ixodidae)

Qiaoyun Ren<sup>1</sup>, Ze Chen<sup>1</sup>, Jin Luo<sup>1</sup>, Guangyuan Liu<sup>1</sup>, Guiquan Guan<sup>1</sup>,  
Hong Yin<sup>1</sup> and Jianxun Luo<sup>1,2</sup>

<sup>1</sup>State Key Laboratory of Veterinary Etiological Biology, Key Laboratory of Veterinary Parasitology of Gansu Province, Lanzhou Veterinary Research Institute, Chinese Academy of Agricultural Science, Xujiaping 1, Lanzhou, Gansu, 730046, People's Republic of China and <sup>2</sup>e-mail: ljxnb@163.com

Subject editor: Luc Bussiere

## Abstract

A single *Haemaphysalis qinghaiensis* specimen exhibiting abnormal morphology was collected from a tick laboratory colony. The tick had a heart-shaped body with partial twinning of the posterior region (with two anal orifices and two genital grooves). To the best of our knowledge, this is the first report of teratological changes in *H. qinghaiensis*. The abnormal morphological features are described herein.

**Key words:** *Haemaphysalis qinghaiensis*, abnormal development, abnormalities, twinning

## Introduction

*Haemaphysalis qinghaiensis* is a three-host ixodid tick that is prevalent across the western plateau of China. It is a hematophagous ectoparasite that preferentially infests small ruminants, and can transmit *Theileria* spp. and *Babesia* spp. *H. qinghaiensis* and the protozoal diseases it transmits have resulted in severe economic losses in China.

Malformation in ixodid ticks is rare in nature; however, abnormalities in ticks have been extensively reported. Dergousoff (2007) described the abnormal morphology of an adult *Dermacentor andersoni* that comprised the absence of a leg on the right side of the body. Keskin et al. (2012) reported gynandromorphism in *Hyalomma marginatum*; the tick displayed abnormal characters such as female characteristics in the dorsal view, pieces of a male conscutum in a part of the alloscutum, and disorderly female and male characteristics in the ventral view. Estrada-Peña (2001) described a case of abnormal development in *Rhipicephalus sanguineus*, with partial twinning of the posterior region of the body. This has also been reported in *Ixodes persulcatus*, *Ixodes holocyclus*, *Amblyomma cajennense*, *Amblyomma variegatum*, and *Hyalomma asiaticum* (Doube 1974, Latif et al. 1988, Belozarov 1995, Labruna et al. 2002, Chen et al. 2015). Despite numerous reports of abnormal morphology in ticks, this has not yet been described in *H. qinghaiensis*. To the best of our knowledge, this is the first study on teratological changes in *H. qinghaiensis*.

## Materials and Methods

*H. qinghaiensis* specimens were collected directly from naturally infested sheep in Lintan County, Gansu Province, PR China. An abnormal engorged nymph tick was isolated from the tick batches. This was a cordiform specimen, with some normal external features such

as mouth-parts and four pairs of legs. The engorged stage of the tick was maintained in a glass tube, sealed with hydrophilic cotton for molting, placed in an incubator at  $28 \pm 2^\circ\text{C}$  with  $80 \pm 5\%$  RH. After 44d, the malformed tick molted.

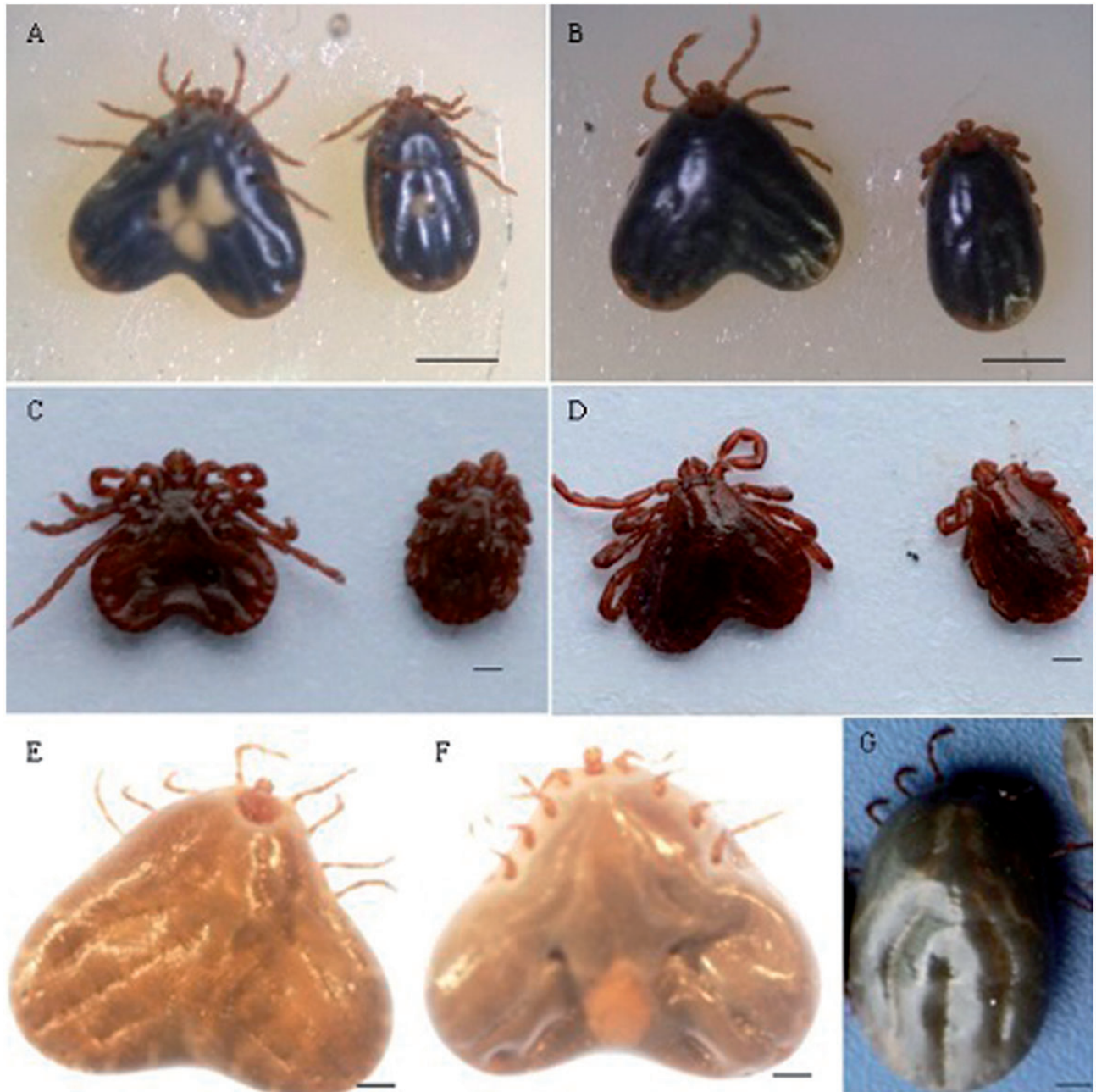
This abnormal female was then reared on the back of tick-naive rabbits using back bags alongside two normal females and three normal males. The ticks attached well. After 18 d, the engorged malformed female dropped off. The two normal females dropped off after 14 and 18 d.

These three ticks were placed into separate tubes and kept in the same condition as previously described for oviposition and hatching. The duration of the oviposition period was 40 d.

## Results

The egg weight of the engorged malformed female was 0.0224 g while that of the two normal females was 0.0189 and 0.0176 g. These egg mass were stored in the same conditions as previously described for the females. After 33 d, the eggs of the engorged malformed female hatched. It took 34 d for the eggs from the normal ticks to hatch following oviposition. A total of 91 larval ticks hatched, all shaped normally.

The abnormal female tick was identified and described. Photographs of the abnormal and normal engorged nymph ticks, unfed adult females, and engorged adult females are shown in Figure 1. The abnormal tick was bigger than the normal specimens. In contrast with normal specimens, the abnormal specimen was heart-shaped, with a bilobed posterior region and two anal pores. This malformed tick exhibited some normal external features, such as mouthparts, four pairs of legs, and two spiracles.



**Fig. 1.** *H. qinghaiensis* (A) engorged nymph tick—ventral view; (B) engorged nymph tick—dorsal view; (C) unengorged adult tick—ventral view; (D) unengorged adult tick—dorsal view; (E) engorged adult tick—dorsal view; (F) engorged adult tick—ventral view; (G) engorged adult tick—Dorsal view Bar = 1 mm

## Discussion

Several cases of anomalous development in ticks have been previously described. However, to the best of our knowledge, this is the first case of abnormal development in *H. qinghaiensis*. Similar cases have been reported with *A. variegatum* (Latif et al. 1998) and *R. sanguineus* (Estrada-Peña 2001). The factors that induce abnormalities in ticks have not yet been determined. While there have been numerous reports of abnormal ticks, few have described the contributing factor of tick malformations. Abnormalities are likely caused by several potential factors such as host resistance to tick infestation, tick mutation, ambient temperature, and high relative humidity

(Latif et al. 1988, Buczek 2000, Estrada-Peña 2001). Further studies are required to elucidate these factors.

## Acknowledgments

This study was financially supported by the Supporting Plan (2013BAD12B03), Science Foundation for youth of Gansu province (1107RJYA067), NSFC (31372432, 311101621, 31201899, 31272556), ASTIP, CAAS; Creative Research Groups of Gansu Province (1210RJJA006); ‘948’(2010-S06), NBCIS CARS-38, Special Fund for Agro-scientific Research in the Public Research (201303035, 201303037), MOA; 973 Program (2010CB530206), Basic Research program

(CRP No. 16198/R0), Supporting Program (2013BAD12B00), Specific Fund for Sino-Europe Cooperation, MOST, China; State Key Laboratory of Veterinary Etiological Biology Project. The research was also facilitated by CRP No. 16198/R0 IAEA, and PIROVAC (KBBE-3-245145) of European Commission.

## References Cited

- Belozеров, V. N. 1995. A case of abnormal size in eggs and larvae of the Taiga tick, *Ixodes persulcatus* (Acari: Ixodidae). *Exp. Appl. Acarol.* 19: 523–528.
- Buczek, A. 2000. Experimental teratogeny in the tick *Hyalomma marginatum* marginatum (Acari: Ixodida: Ixodidae): effect of high humidity on embryonic development. *J. Med. Entomol.* 37: 807–814.
- Chen, Z., Y. Q. Li, Q. Y. Ren, J. Luo, Y. Hu, K. Li, G. Y. Liu, J. X. Luo, J. Liu, and H. Yin. 2015. Morphological characteristics of normal and gynandromorphic *Hyalomma asiaticum* Schulze and Schlottke, 1930. *Korean J. Parasitol.* 53: 361–364.
- Dergousoff, S. J., and N. B. Chilton. 2007. Abnormal morphology of an adult Rocky Mountain wood tick, *Dermacentor andersoni* (Acari: Ixodidae). *J. Parasitol.* 93:708–709.
- Doube, B. M. 1974. A gynandromorph of *Ixodes holocyclus* Neumann. *Aust. J. Entomol.* 13: 361.
- Estrada-Peña, A. 2001. Abnormal development of *Rhipicephalus sanguineus* (Ixodidae). *Exp. Appl. Acarol.* 25: 757–761.
- Keskin, A., A. Bursali, and S. Tekin. 2012. A case of gynandromorphism in *Hyalomma marginatum* Koch, 1844 (Acari: Ixodidae). *J. Parasitol.* 98: 1271–1272.
- Labruna, M. B., A. F. Ribeiro, M. V. Cruz, L. M. Camargo, and E. P. Camargo. 2002. Gynandromorphism in *Amblyomma cajennense* and *Rhipicephalus sanguineus* (Acari: Ixodidae). *J. Parasitol.* 88: 810–811.
- Latif, A. A., T. S. Dhadialla, and R. M. Newson. 1988. Abnormal development of *Amblyomma variegatum* (Acarina: Ixodidae). *J. Med. Entomol.* 25: 142–143.