

Vertebrobasilar dolichoectasia induced hydrocephalus: the *water-hammer effect*

Vaso Zisimopoulou,¹ Aikaterini Ntouniadaki,¹ Panagiotis Aggelidakis,¹ Anna Siatouni,² Stylianos Gatzonis,² Antonios Tavernarakis¹

¹Department of Neurology, Evangelismos Hospital; ²Epilepsy Surgery Unit, Department of Neurosurgery, University of Athens, School of Medicine, Evangelismos Hospital, Athens, Greece

Abstract

Vertebrobasilar dolichoectasia is a clinical entity associated rarely with obstructive hydrocephalus. We present a 48-year old male with a profound dilatation of the ventricular system due to a dolichoectatic basilar artery, as appeared in imaging studies. The patient suffered from longstanding hydrocephalus and presenile dementia. The underlying mechanism for obstructive hydrocephalus due to vertebrobasilar dolichoectasia is considered to be both a *water-hammer effect* and a direct compression of adjacent structures. We suggest prompt surgical intervention upon diagnosis as a first choice treatment in order to avoid further complications.

Introduction

Vertebrobasilar dolichoectasia (VBD) is characterized by ectasia, elongation and tortuosity of the vertebrobasilar arteries and is a well-recognized clinical entity. It may have a clinical expression ranging from benign non-symptomatic to severe and malignant. Obstructive hydrocephalus as a result of VBD is a rare complication. Here we present a 48-year old patient with obstructive hydrocephalus and signs of presenile dementia secondary to compression of the third ventricle by a dolichoectatic basilar artery.

Case Report

A 48-year old man presented in emergency department (ED) with a 2-day history of right-sided numbness in face and arm. He was obese with body mass index of 43.6, heavy smoker since the age of 18 and had a medical history of uncontrolled hypertension, diabetes

and hyperlipidemia. At the ED his behavior-raised questions as disinhibition and impulsivity dominated with patient urinating in public in the examination room. Mild incontinence was reported by patient lasting one year. He also reported being unemployed for three years due to difficulty performing tasks he could easily manage some years before. Neurological examination revealed subtle facial paresis of which patient was unaware. An urgent brain computed tomography scan (CT) revealed marked dilatation of the third and lateral ventricles and a calcified dolichoectatic basilar artery (Figure 1). There was no papilledema or impaired eye movement on ophthalmological examination. During hospitalization and since there were no signs of mass effect on initial brain CT or papilledema patient underwent lumbar puncture (LP) in an attempt to perform a cerebrospinal fluid (CSF) tap test. Opening CSF pressure was 41 cm H₂O and tap test was early terminated after removing 20 mL. Laboratory studies were unremarkable. Patient was assessed before and after LP with mini-mental state examination (MMSE), reported incontinence, walking pattern and distance measured. Even though a full CSF tap test was not performed, we did confirm improvement in all four tests and especially wide-based gait returning to normal. There was also striking improvement in disinhibition and impulsivity. Neuropsychological examination concluded in moderate cognitive impairment, with MMSE score of 20 out of 30, especially in the elements of registration recall, attention and complex command execution. Magnetic resonance imaging (MRI) of brain found dilated third and lateral ventricles and a dolichoectatic basilar artery causing compression, upward displacement of third ventricular floor and mild posterior brainstem displacement (Figure 2). On MRI diffusion weighted images

Correspondence: Vaso Zisimopoulou, Department of Neurology, Evangelismos Hospital, 45-47 Ipsilantou Str, GR 10676, Athens, Greece. Tel.: +30.2132041401 - Fax: +30.2132041403. E-mail: vzisimopoulou@gmail.com

Key words: Vertebrobasilar; dolichoectasia; hydrocephalus.

Contributions: all authors reviewed and contributed to the text. VZ gathered data on the case, reviewed of literature and wrote the manuscript. AS and SG drafting of the text and editing. AN and PA provided background information. PA, AN, AS, SG, AT revised the manuscript, made substantial amendments and helped for images selection.

Conflict of interest: the authors declare no potential conflict of interest.

Received for publication: 10 January 2015.
Revision received: 27 March 2015.
Accepted for publication: 16 April 2015.

This work is licensed under a Creative Commons Attribution NonCommercial 3.0 License (CC BY-NC 3.0).

©Copyright V. Zisimopoulou et al., 2015
Licensee PAGEPress, Italy
Clinics and Practice 2015; 5:749
doi:10.4081/cp.2015.749

high signal was observed in the left periventricular white matter suggestive of 3 acute lacunar infarcts (Figure 3). Flow studies were also performed but were inconclusive. Ventricular-peritoneal shunt was proposed as treatment but patient refused any major intervention and he was alternatively prescribed with acetazolamide. During follow up cognitive impairment gradually worsened and finally patient dropped out counseling in our Neurology Department.

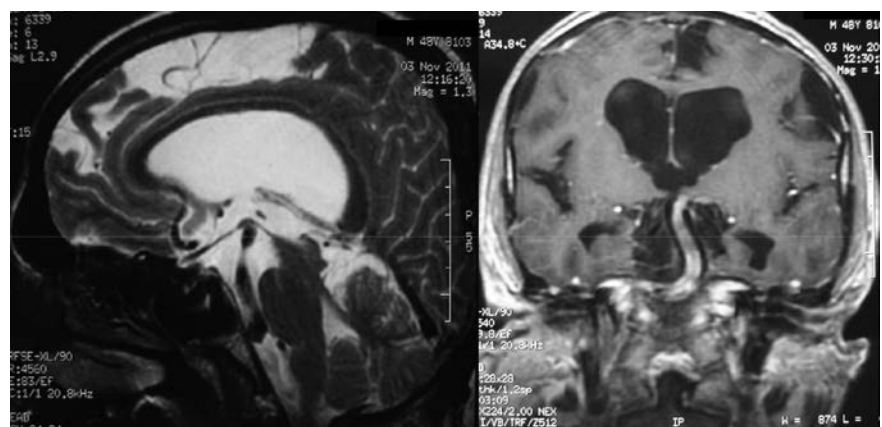


Figure 1. Axial computed tomography brain scan showing on the left an ectatic and calcified basilar artery and extensive dilatation of ventricles on the right.

Discussion

Vertebrobasilar dolichoectasia is a rare entity affecting less than 0.05% of the population with a mean age of presentation 60.5 (± 11.6) years.^{1,2} Diagnosis is based upon radiological findings. Ectasia of the vertebrobasilar system is defined as arterial diameter >4.5 mm in any location along its course. For the basilar artery bifurcation above the suprasellar cistern or evidence of any portion lateral to the margin of the clivus or dorsum sellae is considered elongated.^{3,4} The pathoanatomic findings in dolichoectatic arteries encompass abnormally large external diameter and a thin arterial wall, with degeneration of the internal elastic lamina, multiple gaps in the internal elastica, thinning of the media secondary to reticular fiber deficiency, and smooth muscle atrophy.⁵ The underlying etiology for these changes is unclear. Some authors suggest prolonged systematic arterial hypertension as the main cause,⁶ while others propose a congenital vasculopathy independent of atherosclerosis.⁷

Symptomatic VBD is associated either with ischemic events or direct compression of adjacent structures such as the brainstem, cranial nerves and third ventricle. Reported five year risk of progressive hydrocephalus is 3.3%.⁸ An interesting differentiation by radiological criteria divides hydrocephalus in obstruction-visible and obstruction-invisible.⁹ According to published case reports, obstructive-visible hydrocephalus in VBD is a result of compression of the foramen of Monro, the cerebral aqueduct, or the third ventricle.¹⁰ Other authors¹¹⁻¹³ speculated a different mechanism for obstructive-invisible hydrocephalus that is a combination of increased CSF pulse pressure and impairment of outward CSF flow by *counter current pulsations* of the basilar artery. In other words, a basilar artery extending into the floor of the third ventricle exerts a water-hammer pulse transmitted toward the foramina of Monro resulting in an impairment of outflow from the lateral ventricles and initiate distension.

We suggest that in our patient the dilated basilar artery initially caused non-obstructive or obstructive-invisible hydrocephalus under the *water-hammer effect* by impairment of CSF flow. That resulted to the aforementioned symptoms of evolving cognitive impairment and personality changes. Secondary, as the VBD evolved by direct compression of the third floor ventricle, hydrocephalus worsened. The time patient referred to our clinic probably was the turning point for obstructive hydrocephalus as speculated by the high opening pressure and lack of papilledema. Moreover, evolving VBD caused ischemic strokes suggesting a poor prognosis for our patient. According to Fleming *et al.* median survival is only 7.8 years.¹⁴

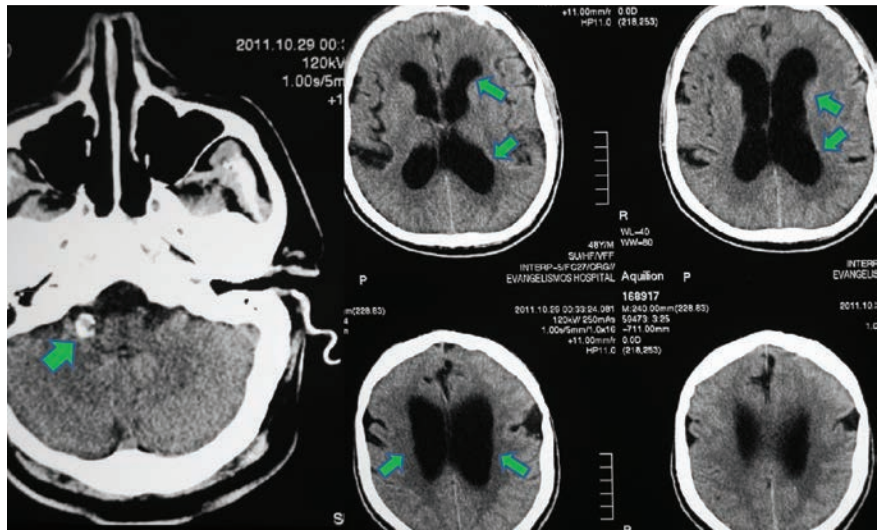


Figure 2. (Left to right) Sagittal T2-weighted brain magnetic resonance imaging (MRI) showing dolichoectatic basilar artery causing compression, upward displacement of third ventricular floor and mild posterior brainstem displacement. Coronal T1-weighted brain MRI showing the top of the basilar artery situated above the level of the sella turca and the dilated third and lateral ventricles.

Treatment options for VBD encompass mainly conservative measures although there is no evidence to support the efficacy of antiplatelet or oral anticoagulant in long term prognosis.² There are papers suggesting that antiplatelet therapy can worsen outcome by promoting hemorrhagic events.⁹ Surgical interventions include ventriculoperitoneal shunt for obstructive hydrocephalus and microvascular repositioning for simple compression syndromes.¹ In the presented case the patient was reluctant to any kind of treatment although he was an adequate candidate. Furthermore, the prescribed medication failed to adequately manage his condition and thus we suggest a more vigorous surgical treatment must be the first choice in obstructive hydrocephalus due to VBD.

VBD is a rare and complex progressive arterial disease, mainly asymptomatic, with poor prognosis in 5-year follow up if symptomatic. To our knowledge this is one of the few cases described until now with a profound VBD and long lasting hydrocephalous before the age of 50. Our case presents with a unique image of extensive dilatation of the ventricular system due to dolichoectatic basilar artery.

References

1. Pereira-Filho A, Faria M, Bleil C, et al. Brainstem compression syndrome caused by vertebrobasilar dolichoectasia:

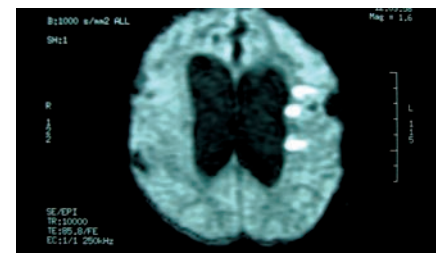


Figure 3. Diffusion-weighted brain magnetic resonance imaging showing 3 acute lacunar infarcts in the left periventricular white matter.

- microvascular repositioning technique. *Arq Neuropsiquiatr* 2008;66:408-11.
2. Passero S, Rossi S. Natural history of vertebrobasilar dolichoectasia. *Neurology* 2008;70:66-72.
3. Smoker WRK, Corbett JJ, Gentry LR, et al. High-resolution computed tomography of the basilar artery: 2 vertebrobasilar dolichoectasia: clinical-pathologic correlation and review. *AJNR Am J Neuroradiol* 1986;7:61-72.
4. Giang DW, Perlin SJ, Monajati A, et al. Vertebrobasilar dolichoectasia: assessment using MR. *Neuroradiol* 1988;30:518-23.
5. Lou M, Caplan LR. Vertebrobasilar dilatative arteriopathy (dolichoectasia). *Ann NY Acad Sci* 2010;1184:121-33.
6. Schulz R, Fegbeutel C, Althoff A, et al.

- Central sleep apnoea diaphragmatic paralysis associated with vertebral artery compression of the medulla oblongata. *J Neurol* 2003;250:503-5.
7. Passero S, Filosomi G. Posterior circulation infarcts in patients with vertebrobasilar dolichoectasia. *Stroke* 1998;29:653-9.
 8. Wolters FJ, Rinkel GJ, Vergouwen MD. Clinical course and treatment of vertebrobasilar dolichoectasia: a systematic review of the literature. *Neurol Res* 2013;35.2:131-7.
 9. Yuan Y, Xu K, Luo Q, Yu J. Research progress on vertebrobasilar dolichoectasia. *Int J Med Sci* 2014;11:1039-48.
 10. Seshadri R, Sadashiva N, Shukla D, et al. Vertebrobasilar dolichoectasia presenting as symptomatic obstructive hydrocephalus: a case report with review of literature. *Indian J Neurosurg* 2012;1.2:165.
 11. Marinescu M, Remy A, Dufour H, et al. A peculiar mechanism of hydrocephalus: the "water-hammering" effect. *Neurochir* 1998;44:117-20.
 12. Nishizaki T, Tamaki N, Takeda N, et al. Dolichoectatic basilar artery: a review of 23 cases. *Stroke* 1986;17:1277-81.
 13. Breig A, Ekbom K, Greitz T, et al. Hydrocephalus due to elongated basilar artery: a new clinicoradiological syndrome. *Lancet* 1967;1:874-5.
 14. Flemming KD, Wiebers DO, Brown RD Jr, et al. The natural history of radiographically defined vertebrobasilar nonsaccular intracranial aneurysms. *Cerebrovasc Dis* 2005;20:270-9.