

Arteriovenous Malformation Complicating Cesarean Scar Pregnancy: A Rare Case of Vaginal Bleeding Managed Successfully by Uterine Artery Embolization

Sangam Jha; M.D., Akanksha Singh; M.D.

Department of Obstetrics and Gynecology, All India Institute of Medical Sciences Patna, Bihar, India

Received April 2021; Revised and accepted June 2021

Abstract

Objective: Arteriovenous malformation (AVM) can occur in cesarean scar ectopic pregnancy. The presence of retained product of conception can pose a diagnostic dilemma and clinical presentation could be similar.

Case report: A 27 year old female presented with continuous vaginal bleeding for two and half months following dilatation and evacuation (D&E) done for cesarean scar pregnancy (CSP) of 10 weeks 4days period of gestation. Sonography with color Doppler revealed dilated tortuous vessels around the mass in lower uterine segment suggesting CSP with AVM. Digital subtraction angiography confirmed the diagnosis. Bilateral uterine artery embolization achieved complete devascularisation as confirmed on post intervention angiogram. Patient became symptom free since then.

Conclusion: Uterine artery embolization is an effective mode of treatment of AVM complicating CSP if future fertility is desired.

Keywords: Cesarean Section; Arteriovenous Malformations; Uterine Artery Embolization

Introduction

In the current practice, the incidence of cesarean section has risen steadily worldwide leading to increase in subsequent obstetric complications including cesarean scar pregnancy (CSP) and adherent placental pathologies (1). CSP is an ectopic pregnancy implanted in the myometrium at the site of a previous cesarean section scar, with a reported incidence of 1:1800- 1:2216 of total pregnancies (2). CSPs can cause serious maternal complications thus mandate early diagnosis and treatment. Many treatment strategies have been proposed including resection of

the scar tissue via abdominal, vaginal or endoscopic route, methotrexate injection, uterine artery embolization (UAE) and dilatation and curettage (3).

Arteriovenous malformation (AVM) are congenital or acquired abnormal vascular shunts between myometrial vessels. It is a very rare condition with hardly 150 cases reported but has potential to cause life threatening complications (4). Acquired AVMs are usually the consequences of uterine surgery like dilation and curettage (D&C) and cesarean section. Recently treatment of CSP has been proposed as causative factor of acquired AVM (5). Optimal management is still uncertain and options include cytotoxic drugs, hormonal therapy, excision of the lesion, hysterectomy and uterine artery

Correspondence:

Dr. Sangam Jha

Email: sangam.jha78@gmail.com

Copyright © 2021 Tehran University of Medical Sciences. Published by Tehran University of Medical Sciences.



This work is licensed under a Creative Commons Attribution-NonCommercial 4.0 International license (<https://creativecommons.org/licenses/by-nc/4.0/>). Noncommercial uses of the work are permitted, provided the original work is properly cited.

embolization (UAE).

We, hereby, present one case of CSP complicated with AVM and retained products of conception (RPOC) offering an insight into clinical manifestation and management for a patient strongly in favor of uterine preservation.

Case report

A 27 year old, G4P1A3L1, referred to our center with irregular vaginal bleeding and lower abdominal pain along with persistently raised beta HCG 37.03 IU/L for two and half months. Her symptoms started post dilatation and evacuation for failure of self-initiated medical termination (with mifepristone and misoprostol) of 10 weeks 4 days gestational age cesarean scar pregnancy. Her preceding ultrasonography before dilation and evacuation (D&E) had demonstrated gestational sac embedded in lower uterine scar with collapsed fundal uterine cavity and beta human chorionic gonadotropin (HCG) level was 150000 IU/L.

Her obstetric history was significant having 3 D&Es for in early pregnancies, all were induced abortion and one cesarean delivery three years ago. At the time of presentation, her vital signs were within normal limits and had hemoglobin of 11.4 mg/dl along with normal coagulation profile. Local examination revealed a 12 week tender uterus and a soft cervix with slight bleeding. Doppler study showed mosaic pattern tangled vessels forming AVM with turbulent course & high velocity flow (Figure 1 A), which was suggestive of AVM. A subsequent computed tomographic angiography revealed a mass in lower uterine segment involving myometrium, endometrium and cervix with internal necrosis, and being fed by both the uterine arteries (Figure 1 B)

thus confirming the diagnosis of AVM following CSP with RPOC.

As she was desirous of future fertility, UAE was planned. Digital subtraction angiography (DSA) was performed using femoral artery approach. Selective catheterization of uterine artery demonstrated hypertrophied bilateral uterine arteries feeding the lesion (Figure 2 A, B). There was early enhancement of nidus with draining vein suggesting high flow AVM with drainage into uterine veins. Bilateral UAE was done using 20% Lipiodol-(n-butyl-2-cyanoacrylate) NBCA mixture achieving complete devascularisation as confirmed on post procedure angiography (Figure 2 C, D) & ultrasonography (Figure 3 A). Postoperative period was uneventful.

She was discharged the next day and kept under regular follow up. Her beta HCG normalized after 1 week to the level of 0.12 IU/L and menstruation resumed 1 month after intervention. Intrauterine mass had reduced significantly (1.5X1.9 cm) as demonstrated at 8 weeks post UAE sonography (Figure 3 B).

Discussion

True incidence of acquired AVM is not known due to its rarity. The literature review showed only a few cases of CSP complicated with AVM (4). It can present with acute or chronic symptoms. Acute presentation is usually a life threatening hemorrhage and thus needs early diagnosis and prompt treatment. Our patient presented with chronic symptom of irregular vaginal bleeding. Though the pathogenesis of acquired AVM is not fully established but it is suggested to result from development of arteriovenous fistulas within the placenta caused by necrosis of the chorionic villi or due to defective endometrium at the scar tissue promoting abnormal angiogenesis (6).

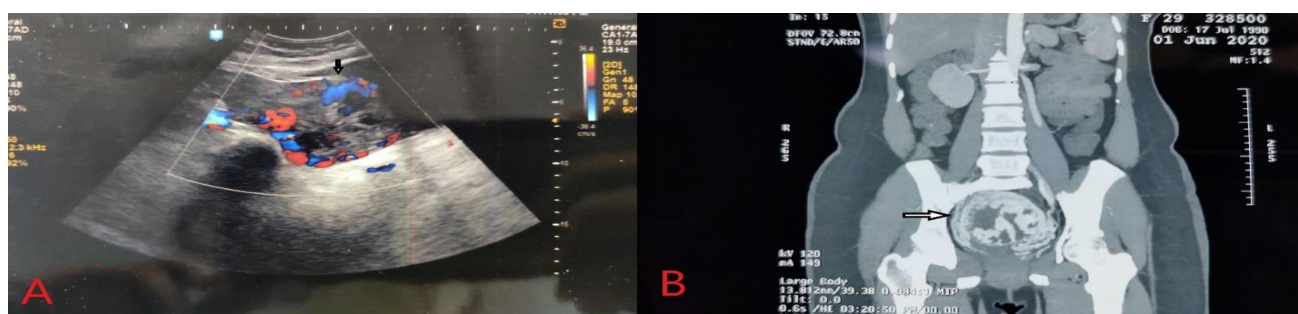


Figure 1: A. Ultrasound image showing 6.8 X 7.1 cm heterogeneous mass with multiple serpentine cystic spaces (black arrow) in lower uterine segment close to previous cesarean scar site. B. Coronal section of CT angiography showing 7.7X7.3 cm mass in lower uterine segment (white arrow) involving myometrium, endometrium and cervix with internal necrosis, and multiple tortuous vessels being fed by both the uterine arteries

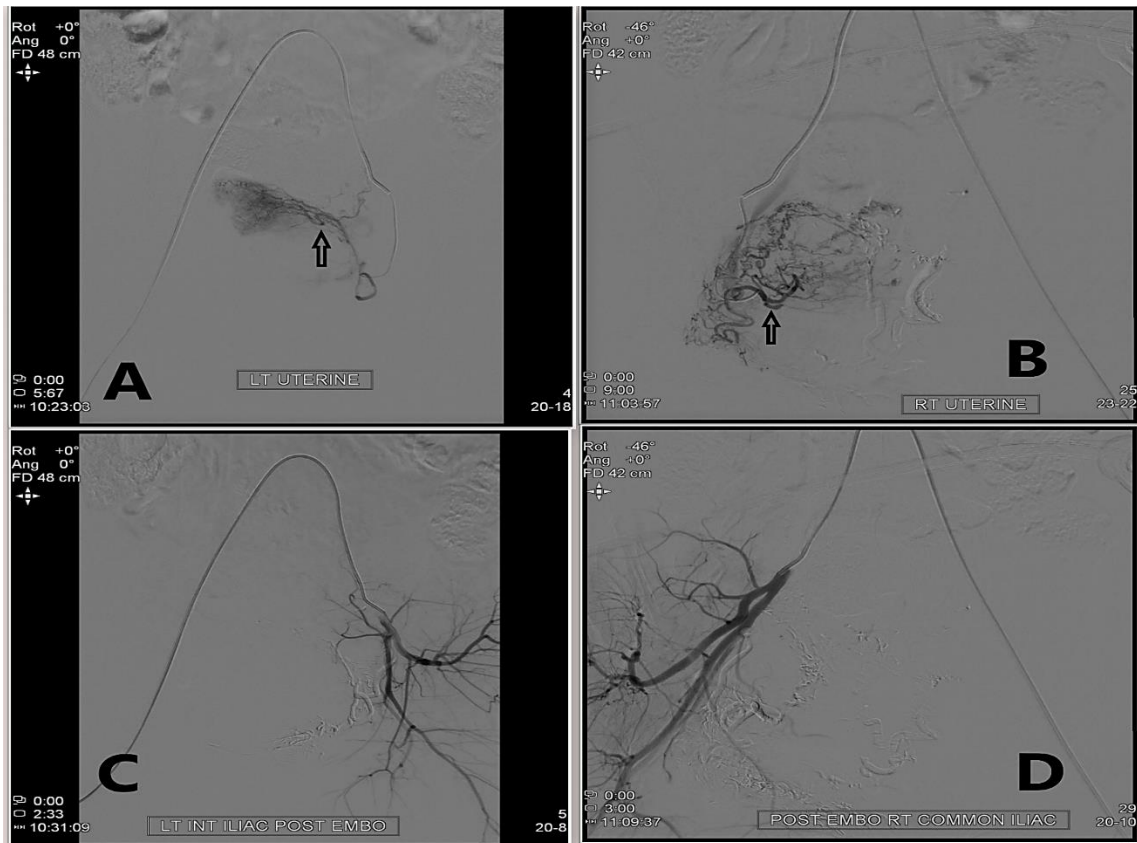


Figure 2: A & B: Super selective angiography images showing hypertrophied vessels with parenchymal blush (hollow arrow). A: Left uterine artery. B: Right uterine artery. C & D: Post embolization angiography. C: Left internal iliac artery showing complete exclusion of the hypertrophied vessels & blush from circulation. D: Right common iliac artery image with other patent normal vessels.

Diagnosis may pose a dilemma especially in post cesarean ectopic cases due to similar clinical manifestation with retained product of conception or concurrence of both entity as in our case

(continuous vaginal bleeding and raised beta HCG). So diagnosis should take relevant clinical history into account accompanied by characteristic radiological findings.

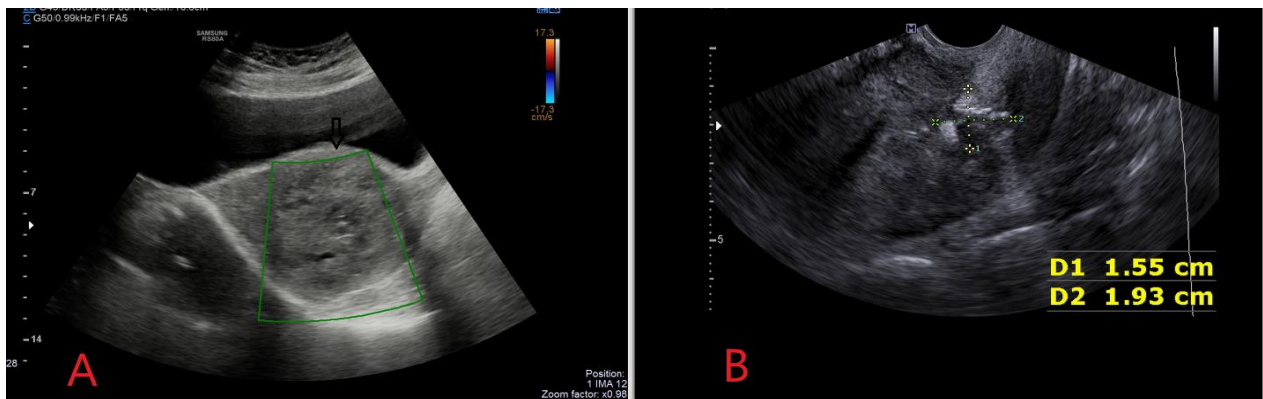


Figure 3: A & B: Post UAE sonographic images. A: At day 1 post UAE- Showing 7X7cm soft tissue lesion in lower uterine segment, thinned out posterior myometrium & no significant anterior myometrium (hollow arrow) with no significant flow on color Doppler. B: At 8 weeks post UAE- showing intrauterine mass of 1.5X1.9 cm size in lower uterine segment.

Color Doppler is the initial investigating tool utilized for its diagnosis. On color Doppler tortuous vascular structures, with a multidirectional flow with low resistance and high velocity is highly suggestive of AVM (7). Spectral Doppler had been proposed as tool for triaging patients based on the peak systolic velocity who would be at greater risk of complication and need UAE (7). Nevertheless, Doppler features of AVM may overlap with other cause of arteriovenous shunting like gestational trophoblastic disease, retained products of conception, placental polyp and endometrial neoplasm. So high index of suspicion for AVM among differential diagnosis is essential. Presently, CT/MRI angiography is used to confirm the diagnosis, know the extent of lesion, delineate feeder vessels and rule out extra uterine involvement (8). CT angiographic features are presence of bunch of dilated vascular channels within the uterus being fed by uterine vessels. Serial serum beta HCG monitoring with USG/CT angiography would help in diagnosing and managing these cases. Our case presented a diagnostic dilemma, as persistent vaginal bleeding could be due to RPOC, or AVM or both. RPOC was the possibility as the HCG level was raised, but history of recent D&E, CT angiography findings and raised HCG favoured the diagnosis of concurrent AVM with RPOC.

Treatment options available for AVM are expectant, medical or surgical and should be based on symptomatology, extent of lesion and desire of fertility. Various drugs which have been described for the medical management in the literature are danazol, prostaglandins, estrogens, gonadotropins and methylergonovine but with limited success (9). Fertility sparing procedures are preferred mode of treatment in symptomatic young women. As our patient was young, desired future fertility and had large symptomatic lesion, we performed bilateral UAE. Rygh et al. reported a similar case of AVM complicating scar pregnancy (with normal beta HCG value) which was initially managed with uterine artery embolization but surgical resection was done subsequently for re-hemorrhage (10).

UAE has recurrence due to revascularization and associated with other major and minor complication like hematoma or neurological injury at puncture site, pelvic pain, and retention of urine (9). Fortunately, in our patient UAE resulted in cessation of flow to the lesion, resolution of symptoms, regression of lesion and had no post-operative complication or any adverse effect on follow up. Kim et al. reported a

case of AVM developing in scar pregnancy which was initially misdiagnosed as RPOC and two sittings of UAE were required to control recurrent vaginal bleeding. During second UAE, an angiogram detected AVM in the uterus (11). Kiyokawa et al reviewed six cases of CSP associated with AVM and reported that all of them required either UAE, surgical excision or hysterectomy (12). Akbayir et al had also reported a case of AVM following dilatation and curettage in women with previous two cesarean deliveries, patient was treated with methotrexate under the diagnosis of CSP initially, however, subsequently diagnosed with AVM and managed with UAE (13). In the present case, AVM was suspected at the presentation and confirmed on subsequent imaging. This facilitated planning of appropriate treatment to reduce patient's morbidity and avoided frequent hospital visits.

Surgical management includes excision of the lesion (abdominally, vaginally, by laparoscopy or hysteroscopy) or hysterectomy. Recently, Groszmann et al. had advocated D&C with ultrasound guidance as safe option for the management of enhanced myometrial vascularity associated with RPOCs, however their cohort did not include abnormally located pregnancy (14). Hysterectomy remains the last resort for women not desiring uterine conservation or where UAE or fertility preserving surgery have failed. Till date only 24 cases of AVM complicating cesarean scar pregnancy have been reported in the literature. Both CSP and AVM are potentially life threatening conditions and when present together, they can lead to catastrophic complications. UAE is an effective mode of treatment for acquired AVM. Large number of cases of this rare entity need to be reported to provide reference for its early diagnosis and appropriate treatment.

Conclusion

High clinical suspicion is required for early and accurate diagnosis of AVM especially in presence of risk factors like uterine surgery. Diagnosis may be difficult in presence of concurrent RPOC as in this case. CT angiography is very helpful in confirming the diagnosis. UAE is an effective mode of treatment for morbid uterine AVM complicating CSP with concurrent RPOC.

Conflict of Interests

Authors have no conflict of interests.

Acknowledgments

We acknowledge our radiologist for successful performance of UAE.

References

1. American College of Obstetricians and Gynecologists, Society for Maternal-Fetal Medicine. Obstetric Care Consensus No. 7: Placenta Accreta Spectrum. *Obstet Gynecol* 2018; 132: e259–e75.
2. Seow KM, Huang LW, Lin YH, Lin MY, Tsai YL, Hwang JL. Cesarean scar pregnancy: issues in management. *Ultrasound Obstet Gynecol* 2004; 23: 247–53.
3. Li X, Sun W, Chen L, Jin M, Zhang Z, Gao J, et al. Cesarean scar pregnancy combined with arteriovenous malformation successfully treated with transvaginal fertility-sparing surgery: a case report and literature review. *Medicine (Baltimore)* 2020; 99: e21432.
4. Huynh C, Ha TN, Hoang VT, Huynh PH. Acquired life-threatening uterine arteriovenous malformation treated by endovascular embolization. *Radiol Case Rep* 2020; 16: 241-5.
5. Timor-Tritsch IE, Haynes MC, Monteagudo A, Khatib N, Kovács S. Ultrasound diagnosis and management of acquired uterine enhanced myometrial vascularity/arteriovenous malformations. *Am J Obstet Gynecol* 2016; 214: 731.
6. Visvalingam G, Lee R, Tan, T, Tan H. An Unusual Case of Acquired Uterine Arteriovenous Malformation with Persistent Scar Ectopic Pregnancy Successfully Managed With Uterine Artery Embolization. *Journal of Medical Cases*. 2016; 7: 143-7.
7. Timmerman D, Wauters J, Van Calenbergh S, Van Schoubroeck D, Maleux G, Van Den Bosch T, et al. Color Doppler imaging is a valuable tool for the diagnosis and management of uterine vascular malformations. *Ultrasound Obstet Gynecol* 2003; 21: 570–7.
8. Aiyappan SK, Ranga U, Veeraiyan S. Doppler Sonography and 3D CT Angiography of Acquired Uterine Arteriovenous Malformations (AVMs): Report of Two Cases. *J Clin Diagn Res* 2014; 8: 187-9.
9. Molvi SN, Dash K, Rastogi H, Khanna SB. Transcatheter embolization of uterine arteriovenous malformation: report of 2 cases and review of literature. *J Minim Invasive Gynecol* 2011; 18: 812-9.
10. Rygh AB, Greve OJ, Fjetland L, Berland JM, Eggebø TM. Arteriovenous malformation as a consequence of a scar pregnancy. *Acta Obstet Gynecol Scand* 2009; 88: 853–5.
11. Kim D, Moon NR, Lee SR, Won YD, Lee HJ, Park TC, et al. Acquired uterine arteriovenous malformation in a cesarean scar pregnancy. *Taiwan J Obstet Gynecol* 2013; 52: 590-2.
12. Kiyokawa S, Chiyoda T, Ueno K, Saotome K, Kim SH, Nakada S. Development of pseudoaneurysm in cesarean section scar pregnancy: a case report and literature review. *J Med Ultrason (2001)* 2018; 45: 357-62.
13. Akbayir O, Gedikbasi A, Akyol A, Ucar A, Saygi-Ozyurt S, Gulkilik A. Cesarean scar pregnancy: a rare cause of uterine arteriovenous malformation. *J Clin Ultrasound*. 2011; 39: 534-8.
14. Groszmann YS, Healy Murphy AL, Benacerraf BR. Diagnosis and management of patients with enhanced myometrial vascularity associated with retained products of conception. *Ultrasound Obstet Gynecol* 2018; 52: 396-9.

Citation: Jha S, Singh A. **Arteriovenous Malformation Complicating Cesarean Scar Pregnancy: A Rare Case of Vaginal Bleeding Managed Successfully by Uterine Artery Embolization.** *J Family Reprod Health* 2021; 15(3): 210-4.