

CASE REPORT

Thyroid disease and covid-19 infection: Case series

Magdy Mohamed Allam¹  | Hanaa Tarek El-Zawawy² | Soha Magdy Ahmed¹  | Mohamed Aly Abdelhamid³

¹Endocrinology Unit, Internal Medicine Department, Alexandria University Student Hospital (AUSH), Alexandria, Egypt

²Endocrinology Division, Internal Medicine Department, Faculty of Medicine, Alexandria University, Alexandria, Egypt

³Critical Care Department, Alexandria University, Alexandria, Egypt

Correspondence

Magdy Mohamed Allam, Endocrinology Unit, Internal Medicine Department, Alexandria University Student Hospital (AUSH), Alexandria, Egypt.
Email: drmagdyallam@gmail.com

Abstract

Early and frequent evaluation of thyroid profile in COVID-19 infected patients is crucial as it will influence thyroid disease sequelae and management in those patients; moreover, it will facilitate setting an appropriate management plan.

KEYWORDS

COVID-19, Grave's disease, Graves' ophthalmopathy, Hashimoto's thyroiditis, hyperthyroidism, hypothyroidism

1 | BACKGROUND

The severe acute respiratory syndrome coronavirus 2 (SARS-CoV-2) is a novel RNA coronavirus responsible for the coronavirus disease-19 (COVID-19) pandemic. The clinical manifestations of COVID-19 are variable, ranging from asymptomatic cases to severe respiratory affection, and were found to cause thyroid dysfunction in some cases. Our case series aim to shed the light on the effect of SARS-CoV-2 infection on thyroid function, thyroid gland size, and treatment of thyroid dysfunction. We demonstrated three cases indicating that COVID-19 infection can accentuate thyrotoxic state and Graves' ophthalmopathy, aggravate hypothyroidism, increase thyroid gland volume, and in euthyroid individuals can induce some sort of thyroiditis, characterized by hyperthyroidism followed by hypothyroidism which is eventually followed by euthyroidism. Furthermore, treatment of thyroid disease was found to be affected by COVID-19 infection.

The novel coronavirus (SARS-CoV-2) was first discovered at the end of the year 2019 in Wuhan, China. After

which, it rapidly spread, causing an epidemic throughout China, which then spread across the entire world, resulting in coronavirus pandemic. In February 2020, the World Health Organization (WHO) designated the disease COVID-19, which stands for coronavirus disease 2019.¹

SARS-CoV-2-specific antibodies and cell-mediated responses are induced following infection. Preliminary evidence suggests that some of these responses are protective, but this remains to be definitively verified. Moreover, it is unknown whether all infected patients develop a protective immune response and how long a protective effect might last.²

Data about the effect of SARS-CoV-2 on the thyroid function are scarce; however, one study addressed this effect and demonstrated that, out of 287 patients with confirmed SARS-CoV-2, 58 patients had hyperthyroidism and 15 patients had hypothyroidism.³ Our case series aim to shed the light on the effect of SARS-CoV-2 infection on thyroid function, which will ultimately influence thyroid disease sequelae and management in patients with COVID-19.

This is an open access article under the terms of the Creative Commons Attribution-NonCommercial License, which permits use, distribution and reproduction in any medium, provided the original work is properly cited and is not used for commercial purposes.

© 2021 The Authors. *Clinical Case Reports* published by John Wiley & Sons Ltd.

2 | CASE PRESENTATION

2.1 | Case 1: hyperthyroid

A 33-year-old female patient was diagnosed with Grave's hyperthyroidism 9 months ago. Her past medical history included hypercholesterolemia, allergic rhinitis, endometriosis, and pre-eclampsia. Her family history was irrelevant. In her regular follow-up visit in January 2020, she was clinically controlled (BMI: 29.5 kg/m², BP: 130/70 mm Hg, HR: 70 beat/min., temperature: 37°C). Laboratory investigations showed TSH: 0.01 mIU/mL (0.39–4.16 mIU/L), FT4: 1.1 ng/dL (0.8–2 ng/dL), FT3: 4.25 pg/mL (1.4–4.2 pg/mL), TRAb: 2.4 U/L (<1.8 U/L), and C-reactive protein (CRP): 3.1 mg/dL (0–5 mg/dL). Her blood counts were as follows: Hemoglobin (Hb): 10.5 g/dL, Platelets (PLT): 208 × 10⁹/L, and White blood cells (WBC): 7.3 × 10⁹/L. Ultrasound (US) neck revealed a diffuse goiter (volume = 20 mL). It also showed a right thyroid nodule measuring 8 × 8 mm. Therefore, we prescribed her carbimazole 30 mg (instead of 20 mg daily), lactoferrin 10 mg, and propranolol 10 mg twice daily.

In May 2020, she was complaining of mild puffiness and proptosis in both eyes, unintentional weight loss, tremors, cough, rhinorrhea, body aches, and loss of appetite. Her physical examination showed BMI: 28 kg/m², BP: 100/60 mm Hg, HR: 90 beat/min., respiratory rate of 19 breaths/min and an oxygen saturation (SpO₂) of 98% on room air, temperature: 38.7°C at two separate settings. Laboratory investigations were as follows: TSH: 0.01 mIU/mL, FT4: 1.79 ng/dL, FT3: 5.165 pg/mL, and TRAb: 11.2 U/L, CRP: 6.1 mg/dL, HB: 14.5 g/dL, PLT: 234 × 10⁹/L, WBC: 9.23 × 10⁹/L. Liver and renal functions were normal. The patient was diagnosed with flare up of Graves' disease (GD) with Graves' ophthalmopathy. Based on her respiratory symptoms, real-time reverse transcription polymerase chain reaction (RT-PCR) of a nasopharyngeal swab was performed and confirmed the diagnosis of COVID-19. Chest X-rays and computed tomography scanning of the chest were normal. Thyroid US showed an enlarged gland with a relative diffuse reduction in vascularity and heterogeneous parenchyma. She was admitted to an isolation cohort ward where she received prednisolone 20 mg, after which she showed a significant improvement in her clinical condition. A steroid-tapering regimen was devised to reduce the dosage of prednisone to the minimum required in the management of COVID-19. The dose of carbimazole was increased to six tablets daily, and artificial tears and selenium were added to her regimen.

One month later, physical examination showed BMI: 28 Kg/m², BP: 110/70 mm Hg, HR: 80 beat/min., and temperature: 37°C. Laboratory investigations were as follows: TSH: 0.09 mIU/mL, FT4: 1.29 ng/dL, FT3: 3.16 pg/mL, TRAb: 12.2 U/L, CRP: 2.1 mg/dL, Hb: 13.5 g/dL, PLT:

230 × 10⁹/L, and WBC: 4.23 × 10⁹/L. She was no longer on corticosteroids, and she was maintained on carbimazole (5 mg) four tablets per day, lactoferrin 10 mg, and propranolol 10 mg artificial tears and selenium. Three months later, her thyroid function was controlled rapidly, coinciding with the decline of thyroid antibody levels. (Figure 1).

2.2 | Case 2: hypothyroid

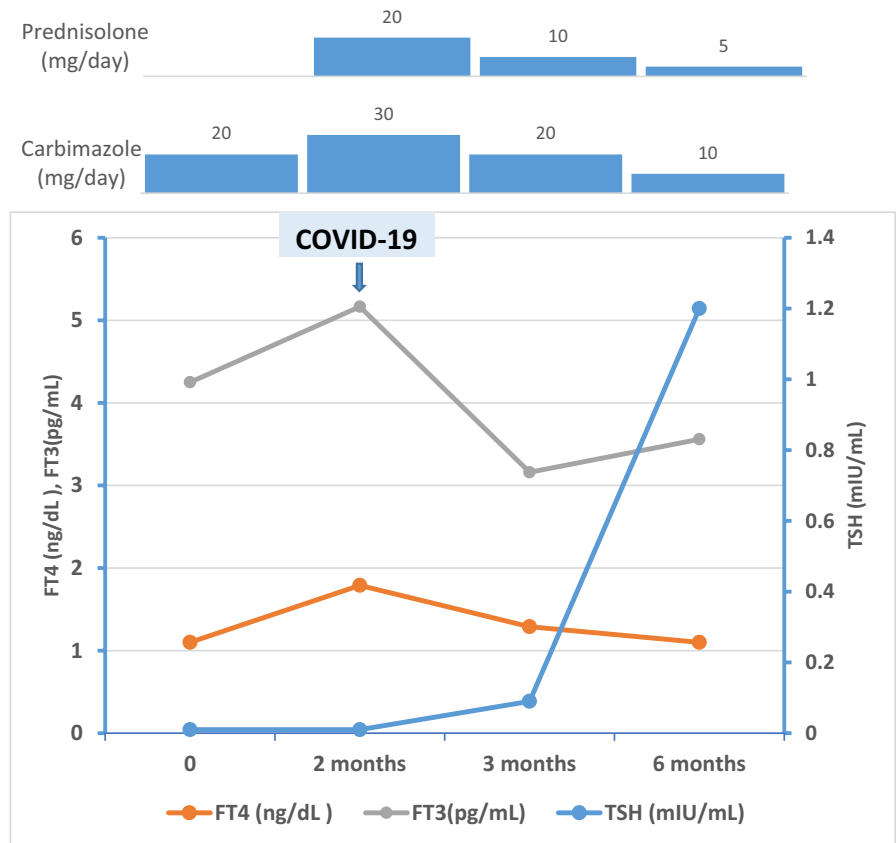
A 42-year-old female patient was diagnosed with hypothyroidism due to Hashimoto's thyroiditis (HT) 10 years ago. Her past medical history included osteoarthritis, allergic rhinitis, and a uterine fibroid. Drug history included levothyroxine (LT4) 100 mcg daily and vitamin D injections for 3 months. Regarding family history, her sister also has hypothyroidism. Her menstrual history revealed menorrhagia.

During her regular follow-up visit in March 2020, she was clinically controlled (BMI: 33 kg/m², BP: 100/70 mm Hg, HR: 78 beat/min, temperature: 37°C). In line with that, laboratory investigations showed TSH: 2.31 mIU/mL, FT4: 1.4 ng/dL, FT3: 3.54 pg/mL, and CRP: 1.21 mg/dL. Her blood counts were as follows: Hb: 12.5 g/dL, PLT: 258 × 10⁹/L, and WBC: 5.93 × 10⁹/L. US of the thyroid gland (volume = 16 mL). Hence, she was maintained on the same medications.

In April 2020, she was complaining of diarrhea, cough, rhinorrhea, and body aches. Her physical examination showed BMI: 32 Kg/m², BP: 100/60 mm Hg, HR: 88 beat/min, respiratory rate: 16 cycle/min, SpO₂ of 96% in room air, and temperature: 38.9°C in two separate settings. Laboratory investigations were as follows: TSH: 2.1 mIU/mL, FT4: 1.46 ng/dL, FT3: 3.46 pg/mL, CRP: 10 mg/dL, Hb: 13.5 g/dL, PLT: 222 × 10⁹/L, and WBC: 10.23 × 10⁹/L. Liver and renal functions were normal. The RT-PCR of the nasopharyngeal swab confirmed the diagnosis of COVID-19. Chest X-rays and computed tomography scanning of the chest were normal. Thyroid US showed a homogenous thyroid gland with few streaks and relative hypervascularity, and volume 23 mL. At home, she received magnesium, vitamin C, and zinc, ceftriaxone 1 gm, ciprofloxacin 500 mg, prednisolone 20 mg, and paracetamol 500 mg.

After 21 days, she showed significant improvement of her clinical condition when she stopped the steroids. The patient reported that she stopped taking her prescribed levothyroxine (LT4) since the start of COVID-19 infection. Laboratory investigations showed TSH: 1.27 mIU/L, FT4: 1.32 ng/dL, FT3: 3.921 pg/mL, T4: 16.09 µg/dL (5–12 µg/dL), T3: 203 ng/dL (70–190 ng/dL), PTH: 28.5 pg/mL, and TPOAb (Less than 35 IU/mL) and TBG (Less than 60 IU/mL) were both negative, liver and renal functions were normal, CRP: 2.6 mg/dL, Ferritin: 4 ng/mL, and vitamin D: 27.3 ng/mL. Her blood counts were as follows: Hb: 10.3 g/dL, PLT: 363 × 10⁹/L, and

FIGURE 1 Case one. The effect of COVID-19 on the course of Graves' disease. FT3, free triiodothyronine; FT4, free thyroxine; TSH, thyrotropin



her WBC: $5.73 \times 10^9/L$. The patient was maintained on LT4 50 mcg daily and ferrous sulfate twice daily.

One month later, the patient's physical examination showed BMI: 33 Kg/m², BP: 130/70 mm Hg, HR: 72 beat/min., and temperature: 37°C. Laboratory investigations showed TSH: 7.86 mIU/mL, FT4: 0.64 ng/dL, and FT3: 2.35 pg/mL. Her blood counts were as follows: Hb: 12.8 g/dL, PLT: $265 \times 10^9/L$, and her WBC: $6.02 \times 10^9/L$. The LT4 dose was modified to 125 mcg daily, and fluticasone propionate 50 mcg inhaler was prescribed for her allergic rhinitis.

The patient's next visit was 4 weeks later, and her physical examination was unremarkable. Laboratory investigations showed TSH: 25.46 mIU/mL, FT4: 0.88 ng/dL, and FT3: 2.14 pg/mL. Liver and renal functions were normal, CRP: 1.1 mg/dL, serum iron: 46 µg/dL (60-160 µg/dL), ferritin: 39 ng/mL, vitamin D: 30.7 ng/mL, total calcium: 8.7 mg/dL, and D dimer: 228 ng/mL (<250 ng/mL). Based on these investigations, the patient was prescribed LT4 150 mcg daily, ferrous sulfate twice daily, cholecalciferol 1000 IU, and fluticasone propionate 50 mcg inhaler. After 2 months, the thyroid function was controlled rapidly. (Figure 2).

2.3 | Case 3: euthyroid goiter

A 29-year-old female patient, diagnosed with goiter since 2016, presented to our clinic for her 6-month regular

follow-up. She had no other medical history. She had regular menses. Physical examination revealed BMI: 34 Kg/m², BP: 130/70 mm Hg, HR: 90 beat/min, and temperature: 37°C. Several posterior cervical lymph nodes were palpable on examination.

Laboratory investigations showed TSH: 1.98 mIU/mL, and TPO Ab (Less than 35 IU/mL) and TGB Ab (Less than 60 IU/mL) were both negative, Hb: 11 g/dL, PLT: $404 \times 10^9/L$, WBC: $6.1 \times 10^9/L$, LDL: 172 mg/dL, CRP: 1.1 mg/dL, and vitamin D: 35 ng/mL. US neck revealed right lobe: 23 mm, left lobe: 16 mm and isthmus: 1 mm, in addition to a solitary thyroid nodule (STN) measuring 12 × 9 mm in the right lobe and showing halo sign without any changes since 2016.

One month later, she was complaining of dry cough, diarrhea, body aches, and loss of appetite. Her physical examination was as follows: BMI: 33.9 Kg/m², BP: 110/70 mm, HR: 68 beat/min., SpO₂ 98% on room air, and temperature: 37.8°C. Chest X-ray and computed tomography scanning of the chest were normal. The patient was diagnosed with COVID-19 after a RT-PCR of the nasopharyngeal swab was done. The most recent US neck revealed an increase in size and vascularity of the thyroid gland; the thyroid gland volume became 31 mL, STN in the right lobe measuring 20 × 10 mm with no halo. A fine needle aspiration cytology (FNAC) was ordered, which indicated a Bethesda category II cytology. She received Ciprofloxacin 500 mg daily,

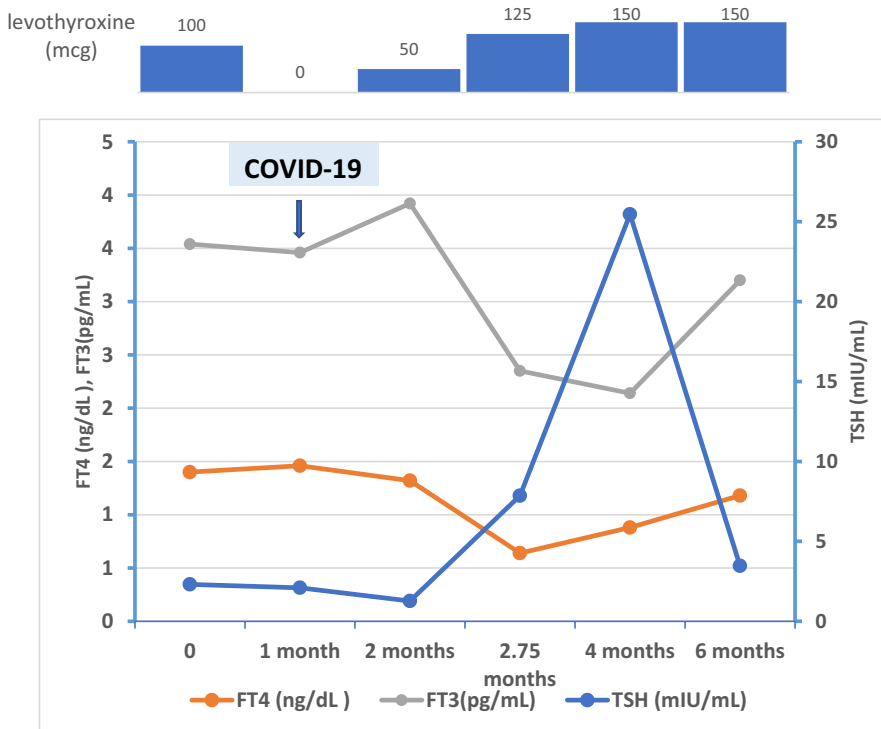


FIGURE 2 Case two. The effect of COVID-19 on the course of Hashimoto's thyroiditis. FT3, free triiodothyronine; FT4, free thyroxine; TSH, thyrotropin

and her clinical condition showed significant improvement. The patient was maintained on some minerals and vitamins including zinc, selenium, magnesium, calcium, vitamins A, C, and E.

3 | DISCUSSION

3.1 | COVID-19 and thyroid gland

COVID-19 may affect thyroid gland through subacute thyroiditis which is characterized by a self-limiting thyrotoxicosis of variable duration—lasting a period of weeks or months—followed by hypothyroidism with final restoration of euthyroidism.⁴ In the THYROCOV study conducted in Italy ($n = 287$), the frequency of thyrotoxicosis and hypothyroidism in non-ICU COVID-19 patients was 20.2% and 5.2%, respectively.³ Furthermore, based on meta-analysis of the available data, thyroid disease was found to be associated with an enhanced risk of severe COVID-19 infection.⁵

Several reasons can be proposed to explain the interaction between COVID-19 and thyroid disease. First of all, autoimmune thyroid diseases can cause dysregulation of innate immune response.⁶ Immune dysregulation in HT was found to be mediated by T helper 17 cells (Th17) cells that are considered a major source of interleukin 17 (IL-17). HT alters immune response via increased IL-17 levels.⁷ Additionally, it has been shown that patients with severe COVID-19 infection may have a cytokine storm characterized by hyperactivity of Th1/Th17 immune response with increased production

of several proinflammatory cytokines, including interleukin 6 (IL-6) and tumor necrosis factor- α (TNF- α).³ Thus, patients with HT and COVID-19 are expected to have an augmented immune response with a higher risk of cytokine storm and severe COVID-19 infection.

Selenium (Se) is an essential trace element, vital for the proper function of both the thyroid and the immune system. Selenium deficiency has been implicated in the pathogenesis of autoimmune thyroid disease (AITD) especially HT.⁸ Regarding COVID-19 disease, Zhang identified an association between adequate selenium intake/status and higher cure rate. The selenium metabolic pool could employ their separate mechanisms to attenuate virus-triggered oxidative stress, excessive inflammatory responses, and immune system dysfunction, thus improving the outcome of SARS-CoV-2 infection.⁹

Furthermore, the angiotensin-converting enzyme 2 (ACE2) is a host-cell entry receptor for SARS-CoV-2, and it might be partly responsible for a common pathogenic pathway. ACE2 is more often expressed in thyroid cells than in lung cells, and in women, such expression negatively correlates with signatures of immune cell enrichment.¹⁰ Severe pathologic injury in follicular epithelial cells with follicular distortion and collapse has been found in thyroid glands of SARS patients.¹¹ After examining the endocrine cells in the pituitary gland of five SARS patients, Wei et al¹² found that TSH positive cells were significantly decreased.

Moreover, cytokine storms were found to be very common in COVID-19 patients, especially in severe cases, which are characterized by the uncontrolled and excessive

release of inflammatory mediators resulting in overwhelming systemic inflammation and even multiple organ dysfunction.¹³ The increase of inflammatory cytokines can result in suppression of central TSH and 5'-deiodinases activity. Euthyroid sick syndrome (ESS) was reported to be significantly associated with disease severity and inflammatory parameters in COVID-19 patients, with a prevalence of 27.52% in COVID-19 patients. It has also been noted that ESS is strongly associated with the severity of COVID-19 (hazards ratio = 2.52), including the severity of symptoms and elevated inflammatory markers.¹⁴

Nevertheless, the effects of certain drugs on the thyroid function should not be ignored. Glucocorticoids, heparin and dopamine can inhibit the secretion of TSH by the pituitary gland as well as the intake of T4 by peripheral tissues. In addition, nonsteroidal anti-inflammatory drugs (NSAIDs) are capable of transiently increasing free thyroid hormone levels by preventing their binding to plasma transport proteins.¹⁵

Additionally, COVID-19 is not simply a disease of the upper respiratory tract, and some COVID-19 patients experience hypercoagulability which have been referred to as COVID-19-associated coagulopathy that appears to be caused by a SARS-CoV-2 induced local inflammatory response in small to mid-sized pulmonary arteries.¹⁶ Also, a severe course of COVID-19 was found to be initiated by hyperhomocysteinemia (H-Hcy), which can be triggered by the presence of the 5, 10-methylenetetrahydrofolic acid reductase C677T polymorphism,¹⁷ which is highly associated with thyroid disease.¹⁸

3.2 | Hyperthyroidism treatment in the light of COVID-19

In the first case, the patient suffered a deterioration in thyroid function and an ophthalmopathy which required an increase in drug dosage and the addition of selenium. This can be explained by a cytokine storm which was reported to induce hyperthyroidism.¹⁹ Moreover, both IFN- γ and IFN- α are known to be potent promoters of GD pathology;²⁰ meanwhile, different types of IFNs were found to be elevated in patients with COVID-19 cytokine storm.²¹ Hence in GD & COVID-19 patients with cytokine storm, both GD and Graves' ophthalmopathy (GO) might be exaggerated.

A study, conducted in Spain, described two cases of GD, in which, both patients had previous history of GD, but they were in remission and had maintained a normal thyroid function prior to contracting COVID-19 infection.²² GO has many mechanisms; IGF-1 plays a key role in the pathogenesis of COVID-19 as costimulation of IGF-1 receptors (IGF-1R) and the thyrotropin receptor on the orbital fibroblast is critical for the development of GO.²³ Recently, IGF-1 and IGF-1R were found to be upregulated in lung tissues of patients with

ARDS related to COVID-19, contributing to tissue injury and fibrosis.²⁴

The antithyroid drugs are used to inhibit thyroid activity in patients with hyperthyroidism, while they do not increase the risk of COVID-19 infection or affect severity of the disease, they can still cause neutropenia in susceptible individuals who experience symptoms (sore throat, mouth ulceration, fever, and flu-like symptoms), which are similar to the symptoms of COVID-19 (fever, new persistent cough, and flu-like symptoms). That is why, it can be difficult for physicians to differentiate between these two diagnoses.²⁵ Furthermore, steroids, the initial treatment for GO, may affect innate immunity and facilitate COVID-19 infection.

3.3 | Hypothyroid treatment in the light of COVID-19

As seen in the second case, thyroid hormone requirements have decreased for 3 months, which may be due to the effect of vitamin C and other supplements. The only study that addressed that issue was the British Thyroid Association (BTA), which did not have specific recommendations for patients with hypothyroidism & COVID-19 and advised patients to continue taking their medication as prescribed.²⁶

A retrospective study of 251 COVID-19 patients, who had pre-existing hypothyroidism and received thyroid hormone therapy, reported that hypothyroidism had no effect on the outcomes of COVID-19 positive patients.²⁷

3.4 | Goiter in the light of COVID-19

As described in the third case, COVID-19 infection may affect the size of thyroid nodules. The rate of detection of nodules measuring ≥ 1 cm on noncontrast chest CT images of ICU patients diagnosed with COVID-19 was 26%. Significantly, more nodules were detected in ICU patients than in non-ICU patients.²⁸

4 | CONCLUSION

COVID-19 infection has been found to affect thyroid function as well as the management of thyroid disease. Therefore, frequent and thorough evaluation of thyroid profile in COVID-19 patients is vital as it will facilitate a planned proper treatment. This case series highlights the effects of COVID-19 infection on thyroid disease and management.

ACKNOWLEDGMENTS

This research did not receive any specific grant funding from any agency in the public, commercial, or nonprofit sector.

CONFLICT OF INTEREST

None declared.

AUTHOR CONTRIBUTIONS

MMA: participated in patient management and data collection, contributed to the interpretation of cases, and critically reviewed the manuscript. HTE-Z, SMA: participated in data collection, contributed to the interpretation of the cases, and critically reviewed the manuscript. MAA: participated in interpretation of the cases, and critically reviewed the manuscript. All authors were major contributors. All authors of this paper have reviewed the document in its entirety and are in agreement with the structure and content.

ETHICAL APPROVAL

All patient data have been kept confidential, and appropriate consent has been obtained from the patient.

DATA AVAILABILITY STATEMENT

The data that support the findings of this study are available upon the quality of request.

ORCID

Magdy Mohamed Allam  <https://orcid.org/0000-0003-3178-0487>

Soha Magdy Ahmed  <https://orcid.org/0000-0002-1807-9250>

REFERENCES

1. Coronavirus disease (COVID-19) – World Health Organization. Who.int. <https://www.who.int/emergencies/diseases/novel-coronavirus-2019>. Accessed November 3, 2020.
2. McIntosh K, Hirsch MS, Bloom A. Coronavirus disease 2019 (COVID-19): epidemiology, virology, clinical features, diagnosis, and prevention. UpToDate.com. <https://www.uptodate.com/contents/coronavirusdisease-2019-covid-19-epidemiology-virology-clinical-features-diagnosis-and-prevention>. Accessed November 4, 2020.
3. Lania A, Sandri MT, Cellini M, Mirani M, Lavezzi E, Mazziotti G. Thyrotoxicosis in patients with COVID-19: the thyrcov study. *Eur J Endocrinol*. 2020;183(4):381-387. <https://doi.org/10.1530/EJE-20-0335>
4. Sohrabpour S, Heidari F, Karimi E, Ansari R, Tajdini A, Heidari F. Subacute thyroiditis in COVID-19 patients. *Eur Thyroid J*. 2020;9(6):321-323. <https://doi.org/10.1159/000511707>
5. Hariyanto TI, Kurniawan A. Thyroid disease is associated with severe coronavirus disease 2019 (COVID-19) infection. *Diabetes Metab Syndr*. 2020;14(5):1429-1430. <https://doi.org/10.1016/j.dsx.2020.07.044>
6. McKechnie JL, Blish CA. The innate immune system: fighting on the front lines or fanning the flames of Covid-19? *Cell Host Microbe*. 2020;27(6):863-869. <https://doi.org/10.1016/j.chom.2020.05.009>
7. El-Zawawy HT, Farag HF, Tolba MM, Abdalsamea HA. Improving Hashimoto's thyroiditis by eradicating *Blastocystis hominis*: relation to IL-17. *Ther Adv Endocrinol Metab*. 2020;11:2042018820907013. <https://doi.org/10.1177/2042018820907013>
8. Wu Q, Rayman MP, Lv H, et al. Low population selenium status is associated with increased prevalence of thyroid disease. *J Clin Endocrinol Metab*. 2015;100(11):4037-4047. <https://doi.org/10.1210/jc.2015-2222>
9. Zhang J, Saad R, Taylor EW, Rayman MP. Selenium and selenoproteins in viral infection with potential relevance to COVID-19. *Redox Biol*. 2020;37:101715. <https://doi.org/10.1016/j.redox.2020.101715>
10. Li MY, Li L, Zhang Y, Wang XS. Expression of the SARS-CoV-2 cell receptor gene ACE2 in a wide variety of human tissues. *Infect Dis Poverty*. 2020;9(1):45. <https://doi.org/10.1186/s40249-020-00662-x>
11. Wei L, Sun S, Xu CH, et al. Pathology of the thyroid in severe acute respiratory syndrome. *Hum Pathol*. 2007;38(1):95-102. <https://doi.org/10.1016/j.humpath.2006.06.011>
12. Wei L, Sun S, Zhang J, et al. Endocrine cells of the adenohypophysis in severe acute respiratory syndrome (SARS). *Biochem Cell Biol*. 2010;88(4):723-730. <https://doi.org/10.1139/O10-022>
13. Ye Q, Wang B, Mao J. The pathogenesis and treatment of the 'cytokine storm' in COVID-19. *J Infect*. 2020;80(6):607-613. <https://doi.org/10.1016/j.jinf.2020.03.037>
14. Zou R, Wu C, Zhang S, et al. Euthyroid sick syndrome in patients with Covid-19. *Front Endocrinol (Lausanne)*. 2020;11:566439. <https://doi.org/10.3389/fendo.2020.566439>
15. Burch HB. Drug effects on the thyroid. *N Engl J Med*. 2019;381(8):749-761. <https://doi.org/10.1056/NEJMr1901214>
16. Levi M, Thachil J, Iba T, Levy JH. Coagulation abnormalities and thrombosis in patients with COVID-19. *Lancet Haematol*. 2020;7(6):e438-e440. [https://doi.org/10.1016/S2352-3026\(20\)30145-9](https://doi.org/10.1016/S2352-3026(20)30145-9)
17. Karst M, Hollenhorst J, Achenbach J. Life-threatening course in coronavirus disease 2019 (COVID-19): is there a link to methylenetetrahydrofolate reductase (MTHFR) polymorphism and hyperhomocysteinemia? *Med Hypotheses*. 2020;144:110234. <https://doi.org/10.1016/j.mehy.2020.110234>
18. Allam MM, El-Zawawy HT, Barakat SS, Ahmed SM, Saleh RNM. A hidden cause of infertility in hypothyroid patients. *Clin Case Rep*. 2020;8(2):374-378. <https://doi.org/10.1002/ccr3.2654>
19. Allam MM, Elzawawy HT. Prevalence of subclinical thyroid dysfunction in coronary artery disease patients: relation to severity of vessel affection. CardioAlex 2017 conference proceedings abstracts. *Eur Heart J Suppl*. 2017;19(suppl_G):G1-G8. <https://doi.org/10.1093/eurheartj/sux040>
20. El-Zawawy HT, El-Aghoury AA, Azzam EZ, Deghady AAM, Abdellatif MA. Osteopontin as a marker in thyroid disease: relation to body mass index. *Endocrin Metabol Sci*. 2020;1(1-2):100049. <https://doi.org/10.1016/j.endmts.2020.100049>
21. Fara A, Mitrev Z, Rosalia RA, Assas BM. Cytokine storm and COVID-19: a chronicle of pro-inflammatory cytokines. *Open Biol*. 2020;10(9):200160. <https://doi.org/10.1098/rsob.200160>
22. Jiménez-Blanco S, Pla-Peris B, Marazuela M. COVID-19: a cause of recurrent Graves' hyperthyroidism? *J Endocrinol Invest*. 2020;44(2):387-388. <https://doi.org/10.1007/s40618-020-01440-0>
23. Khong JJ, McNab AA, Ebeling PR, Craig JE, Selva D. Pathogenesis of thyroid eye disease: review and update on molecular mechanisms. *Br J Ophthalmol*. 2016;100(1):142-150. <https://doi.org/10.1136/bjophthalmol-2015-307399>

24. Winn BJ. Is there a role for insulin-like growth factor inhibition in the treatment of COVID-19-related adult respiratory distress syndrome? *Med Hypotheses*. 2020;144:110167. <https://doi.org/10.1016/j.mehy.2020.110167>
25. Boelaert K, Visser WE, Taylor PN, Moran C, Léger J, Persani L. Endocrinology in the time of Covid-19: management of hyperthyroidism and hypothyroidism. *Eur J Endocrinol*. 2020;183(1):G33-G39. <https://doi.org/10.1530/EJE-20-0445>
26. Thyroid disease and coronavirus (Covid-19). British thyroid foundation. <https://www.btf-thyroid.org/news/thyroid-disease-and-coronavirus-covid-19>. Accessed November 7, 2020.
27. van Gerwen M, Alsen M, Little C, et al. Outcomes of patients with hypothyroidism and Covid-19: a retrospective cohort study. *Front Endocrinol (Lausanne)*. 2020;11:565. <https://doi.org/10.3389/fendo.2020.00565>
28. Güven M, Gültekin H. The prognostic impact of thyroid disorders on the clinical severity of COVID-19: Results of single-centre pandemic hospital. *International Journal of Clinical Practice*. 2021;<http://dx.doi.org/10.1111/ijcp.14129>

How to cite this article: Allam MM, El-Zawawy HT, Ahmed SM, Aly Abdelhamid M. Thyroid disease and covid-19 infection: Case series. *Clin Case Rep*. 2021;9:e04225. <https://doi.org/10.1002/ccr3.4225>