

Total robotic iliac aneurysm repair with preservation of the internal iliac artery using sutureless vascular anastomosis

Benjamin Colvard, MD,^{a,b} Yannick Georg, MD, PhD,^c Anne Lejay, MD, PhD,^c Jean-Baptiste Ricco, MD, PhD,^d Lee Swanstrom, MD,^a Jason Lee, MD,^b Jean Bismuth, MD,^e Nabil Chakfé, MD, PhD,^c and Fabien Thaveau, MD, PhD,^c *Strasbourg and Poitiers, France; Stanford, Calif; and Houston, Tex*

ABSTRACT

Objective: Internal iliac artery (IIA) preservation is associated with improved outcomes after both open and endovascular aortoiliac aneurysm repair. Total robotic laparoscopic repair of aortoiliac aneurysms has been reported in the past, but not in combination with sutureless anastomosis applied to the IIAs. The objective of this study was to demonstrate the feasibility of the total robotic laparoscopic technique including a method of deploying the Gore Hybrid Vascular Graft (GHVG; W. L. Gore & Associates, Flagstaff, Ariz) using robotic instruments.

Methods: Between June 2015 and December 2016, four patients underwent total robotic laparoscopic repair of isolated common iliac artery (CIA) aneurysms. Two patients had unilateral aneurysms and two had bilateral aneurysms. Unilateral CIA aneurysms were treated with a graft from the proximal CIA to the proximal external iliac artery, and bilateral CIA aneurysms were treated with a bifurcated graft between the distal aorta and both proximal external iliac arteries. The nitinol reinforced section of the GHVG was then inserted and deployed into the corresponding IIA, and the nonreinforced segment was sewn in an end-to-side fashion to the iliac graft.

Results: The median age of patients was 55.5 years (range, 48-64 years); median body mass index was 24.9 kg/m² (range, 23-26.4 kg/m²). All four cases were technically successful. Operative times were 325 and 332 minutes for unilateral cases and 491 and 385 minutes for bilateral cases. For the entire series, median proximal clamping time was 143 minutes (range, 110-163 minutes), and the median time to deploy the GHVG was 15 minutes (range, 8-27 minutes). The median estimated blood loss was 1800 mL (range, 800-2100 mL). Intraoperative cell salvage was used in all cases. No intraoperative or postoperative complications occurred. No patient required blood transfusion. All patients tolerated a regular diet on postoperative day 2 and were discharged on postoperative day 4. Patients returned to work and full physical activity within 6 weeks (range, 2-6 weeks). At 6-month follow-up, computed tomography angiography demonstrated 100% patency of iliac artery grafts as well as of the GHVGs.

Conclusions: Total robotic laparoscopic CIA aneurysm repair is feasible in both unilateral and bilateral cases in carefully selected patients. The GHVG can be successfully deployed using robotic technique for IIA preservation during total robotic CIA aneurysm repair. (*J Vasc Surg Cases and Innovative Techniques* 2019;5:218-24.)

Keywords: Robotic vascular surgery; Hybrid graft; Iliac aneurysm; Laparoscopic

Isolated common iliac artery (CIA) aneurysms are an uncommon vascular finding with complex management considerations. Repair planning should include careful consideration of both lower extremity perfusion through

From the Institut Hospitalo-Universitaire de Strasbourg, Strasbourg^a; the Division of Vascular and Endovascular Surgery, Department of Surgery, Stanford University, Stanford^b; the Department of Vascular Surgery and Kidney Transplantation, Les Hôpitaux Universitaires de Strasbourg, Strasbourg^c; the Department of Vascular Surgery, Université de Poitiers, Poitiers^d; and the Houston Methodist Cardiovascular Surgery Associates, Department of Cardiovascular Surgery, Houston Methodist Hospital, Houston.^e

Author conflict of interest: none.

Correspondence: Fabien Thaveau, MD, PhD, FEBVS, Department of Vascular Surgery and Kidney Transplantation, Hôpital Civil, 1 place de l'Hôpital, BP 426, 67091 Strasbourg Cedex, France (e-mail: fabien.thaveau@chru-strasbourg.fr).

The editors and reviewers of this article have no relevant financial relationships to disclose per the Journal policy that requires reviewers to decline review of any manuscript for which they may have a conflict of interest.

2468-4287

© 2019 Published by Elsevier Inc. on behalf of Society for Vascular Surgery. This is an open access article under the CC BY-NC-ND license (<http://creativecommons.org/licenses/by-nc-nd/4.0/>).

<https://doi.org/10.1016/j.jvscit.2019.01.001>

the external iliac artery (EIA) and pelvic perfusion through the internal iliac artery (IIA). Repair options include endovascular methods such as stent grafting with or without coil embolization of the IIA as well as open repair. Considering the need to preserve the IIA for spinal and colonic perfusion as well as for the prevention of buttock claudication and sexual dysfunction, various techniques for IIA preservation during aortoiliac reconstruction have been developed. Conventional open surgery with direct surgical bypass has long been considered the “gold standard” for a durable aortoiliac repair. Endovascular techniques have also been used in this setting with acceptable outcomes. These techniques include the sandwich technique, in which two parallel covered stents are deployed into the iliac limb of a conventional bifurcated endograft, requiring brachial access.¹ As surgeons have continued to develop their own endovascular solutions for preservation of the IIA, device companies have recently introduced iliac branch endoprostheses (IBEs), which are now Food and Drug Administration approved. Results of these devices are promising, but reintervention for occlusion

and endoleak remains an issue. Based on the endovascular aneurysm repair data, it is reasonable to expect a relatively high reintervention rate with these procedures.^{2,3} Robotic aortoiliac reconstruction offers a different approach with the advantage of minimally invasive surgery combined with the durability of open arterial repair. Traditional laparoscopic techniques have proved to be exceedingly difficult, given the need for circumferential anastomoses and the depth of the dissection. Coggia et al⁴ have described the technique for total laparoscopic aortic repair in which they mention the exposure of the right EIA through a conventional open approach. Open exposure of the right EIA is required in this approach because the dissection, control, and anastomosis are difficult to perform by laparoscopy. This exemplifies an important challenge for minimally invasive aortoiliac repair. In Coggia's approach, the patient is in a steep right lateral decubitus position, making exposure of the right iliac arteries extremely difficult with conventional laparoscopy. In addition, IIA preservation is prohibitively difficult regardless of the laterality by the laparoscopic approach because of the small size and depth of the vessel in the pelvis. A physician-made hybrid vascular graft created by sewing endovascular iliac limbs to the limbs of a conventional polyester bifurcated graft has previously been described to reduce operative time during open abdominal aortic aneurysm repair and could be applicable to a robotic approach.⁵ The Gore Hybrid Vascular Graft (GHVG; W. L. Gore & Associates, Flagstaff, Ariz) has been used to revascularize vessels in difficult locations, such as the distal internal carotid artery,^{6,7} as well as renal and visceral arteries during thoracoabdominal repair.⁸ Combining this sutureless anastomotic technique with the robotic approach allows us to access, control, and reconstruct the iliac system more easily as it greatly facilitates deep pelvic dissection and circumferential vessel anastomosis. We describe herein the first report of the use of the GHVG in conjunction with a total robotic approach to iliac aneurysm repair. Informed consent for publication was obtained from study patients, and Institutional Review Board approval was granted for this review.

OPERATIVE TECHNIQUE

Patients were evaluated with preoperative noninvasive vascular studies including ankle-brachial index, and computed tomography angiography (CTA) was performed for preoperative planning. Patients were excluded on the basis of the inability to tolerate pneumoperitoneum (ie, severe chronic obstructive pulmonary disease), extensive prior abdominal surgery, presence of comorbid conditions such as congestive heart failure that would create excessive risk with prolonged anesthesia, and heavily calcified vessels that would prevent safe clamping.

Each patient underwent total robotic repair of unilateral (cases 1 and 3) or bilateral (cases 2 and 4) CIA using the

GHVG as a conduit for the IIA. The operating room is arranged as shown in Fig 1 with the robotic system on the left side of the patient. The patient is placed supine for induction of general endotracheal anesthesia. Lateral support pads are positioned at the level of the right anterior superior iliac spine and the right axilla, and the extremities are secured with tape. An inflatable pillow is positioned under the left flank to increase the rightward tilt by up to 35 degrees. The patient is then turned to 80-degree right lateral decubitus position for sterile skin preparation and draping. Next, the table is returned to 0 degrees, and a 12-mm umbilical port is introduced by direct dissection. After returning to steep right lateral decubitus position, five more trocars are placed, including two 8-mm da Vinci (Intuitive Surgical, Inc, Sunnyvale, Calif) trocars (Fig 2). The robot is docked from the patient's left side (Fig 1). Docking from the left side allows rapid undocking of the arms and access to the left flank or abdomen should emergent open conversion be required. For right unilateral iliac aneurysms, the positioning is the same, except with left lateral decubitus tilt and docking from the right. Monopolar scissors and bipolar fenestrated graspers are used for dissection. The exposure of the aortoiliac system is performed by incising the left paracolic gutter and dissecting the left colon (right colon for right unilateral iliac aneurysms) off its lateral peritoneal attachments. At this point, the dissection closely resembles the standard open retroperitoneal exposure with a retrocolic approach. Once the retroperitoneum is entered, the left ureter is identified and protected by retracting it with the T'LIFT system (VECTEC, Hauterive, France). The abdominal aorta and its bifurcation, iliac arteries, and iliac bifurcations are exposed; 150 units/kg of unfractionated heparin is administered intravenously. At this point, the steps vary slightly from case to case on the basis of the individual's anatomy.

For unilateral cases, proximal control is obtained at the level of the proximal CIA. We use the laparoscopic vascular clamp (Karl Storz GmbH, Tuttlingen, Germany), which provides secure vascular occlusion with a locking mechanism on the ratchet to prevent inadvertent unclamping. Distal control is obtained at the EIA and IIA using bulldog clamps. The aneurysm sac is opened and the nitinol reinforced segment of the GHVG is deployed into the origin of the IIA with at least half the length of this reinforced segment within the vessel (2.5 cm for the 5-cm GHVG). Gore-Tex tacking sutures are placed at the 11-o'clock and 3-o'clock positions to secure the nitinol segment per the instructions for use of the device (Video). Next, the expanded polytetrafluoroethylene CIA to EIA interposition graft is sewn into place, followed by an end-to-side anastomosis of the end of the nonreinforced segment of the GHVG to the side of the interposition graft. All anastomoses are performed robotically. Clamps are removed, hemostasis is ensured, and protamine is administered to fully reverse heparinization. The posterior peritoneum is closed, and

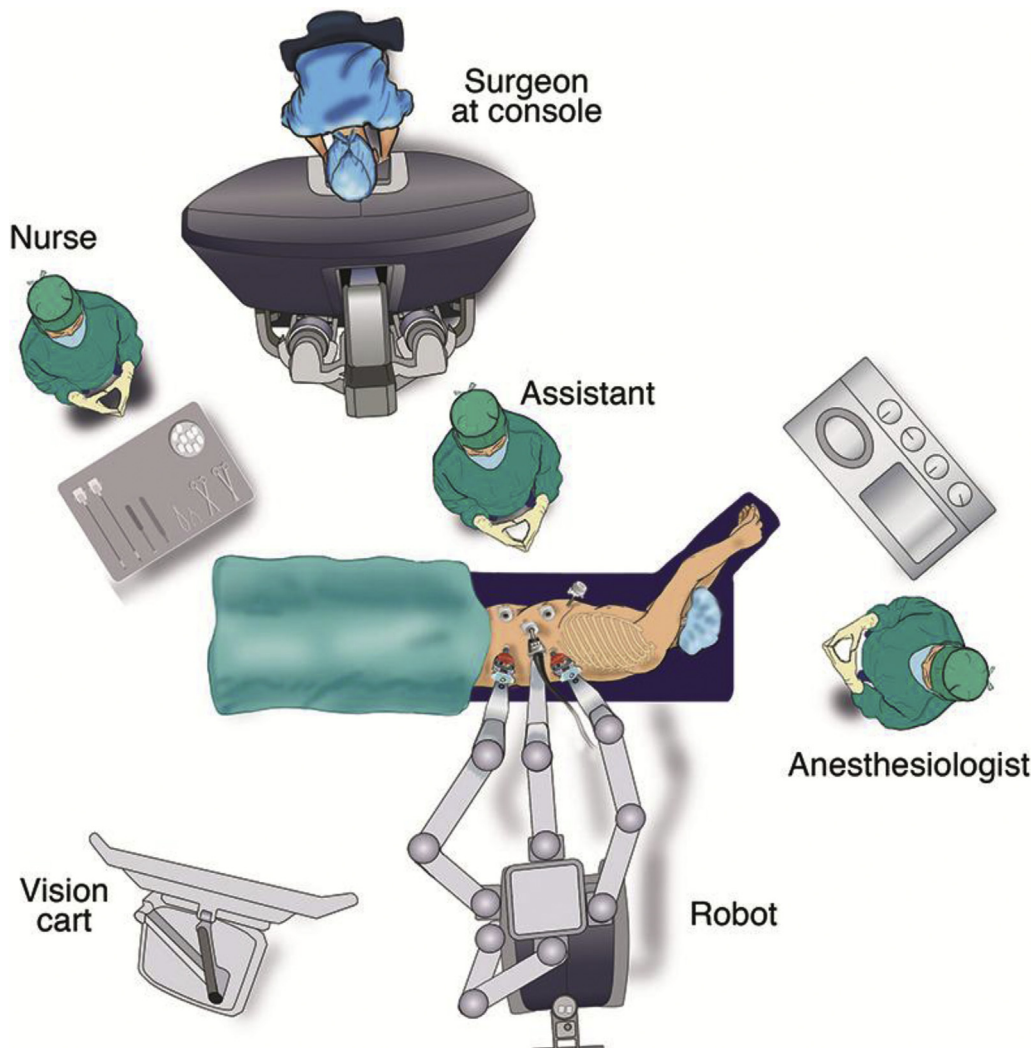


Fig 1. Operating room setup. The robotic cart is docked from the left side of the patient. In case of conversion, the robot cart can easily be retracted.

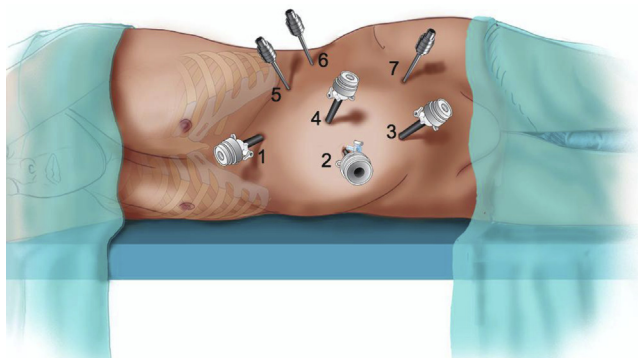


Fig 2. Four 12-mm laparoscopic trocars are placed for the following: 1, Proximal clamp trocar; 2, assistant's trocar (suction, retraction); 3, distal clamp (bulldogs), insufflation, and assistant's trocar; 4, camera port. Initially, two (5 and 7) 8-mm robotic trocars are placed in triangulation with the camera port. A third (6) robotic trocar can be placed if needed.

the trocars are removed under direct observation and sites closed in standard fashion.

Bilateral cases require an aortobi-iliac graft (Fig 3). Proximal control is obtained at the level of the distal abdominal aorta, and distal control is obtained at the bilateral EIAs and IIAs. The aneurysm sacs are opened, and the aortic and iliac anastomoses are completed using Gore-Tex CV-3 suture (aortic) and CV-4 (iliac) suture, followed by the deployment of the GHVGs in the bilateral IIAs and anastomoses of both nonreinforced ends to their respective bypass limbs.

RESULTS

Patients' characteristics are presented in Table I. All patients were operated on between June 2015 and December 2016. During this period, we performed 276 endovascular aneurysm repairs with 32 IBEs and 100 conventional open repairs for aortoiliac aneurysms. A total of 30 total robotic abdominal aortic aneurysm repairs were

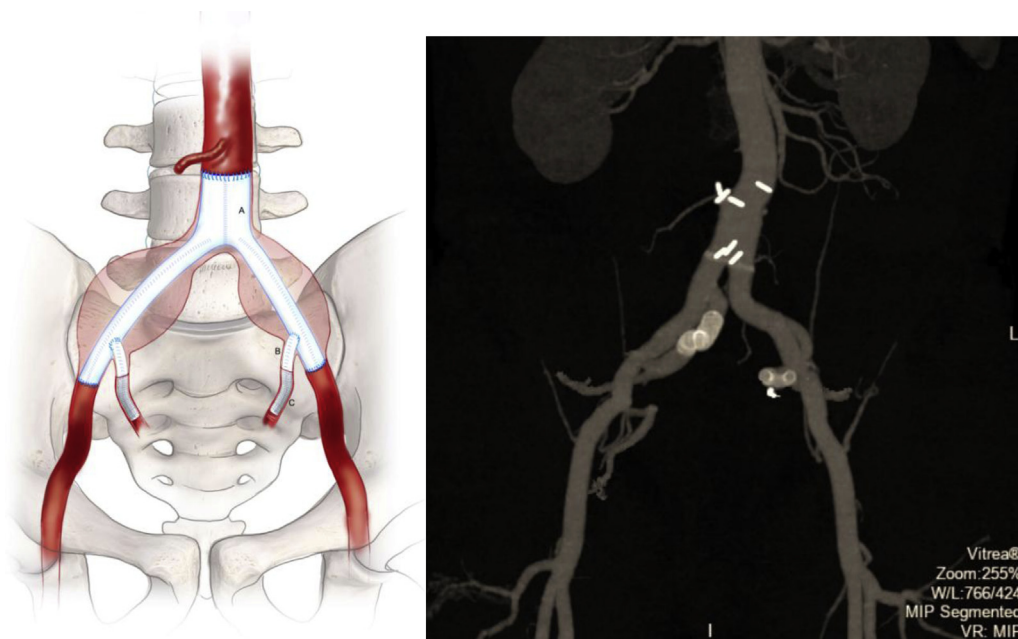


Fig 3. Left, Diagrammatic representation of the bilateral common iliac artery (CIA) aneurysm repair. A, Bifurcated expanded polytetrafluoroethylene graft. B, Nonreinforced segment of the Gore Hybrid Vascular Graft (GHVG) sewn to the limb of the bifurcated graft. C, Nitinol reinforced segment of the GHVG inserted into the origin of the internal iliac artery (IIA). For unilateral cases, a single interposition graft from the proximal CIA to the proximal external iliac artery (EIA) is created with the GHVG connected to the side of that graft. Right, Three-dimensional reconstruction of postoperative computed tomography angiography (CTA) image of case 2 demonstrating patent aortobi-iliac graft as well as patent IIA GHVG repair.

Table I. Demographic data

(I)	Case 1	Case 2	Case 3	Case 4
Age, years	48	52	64	59
Sex	M	M	M	M
BMI, kg/m ²	25.2	23	24.7	26.4
Previous tobacco use	Yes	No	No	Yes
ASA class	1	2	2	3
Comorbidities	None	None	Asthma	CKD
Functional capacity (METs)	5	10	10	4

ASA, American Society of Anesthesiologists; BMI, body mass index; CKD, chronic kidney disease; METs, metabolic equivalents.

performed during the study period. The median age was 55.5 years (range, 48-64 years). The median body mass index was 24.9 kg/m² (range, 23-26.4 kg/m²). Three of the four patients (cases 1-3) were highly active, including a carpenter and furniture mover (case 1), a marathon runner (case 2), and an active CrossFit athlete (case 3). There were few comorbidities among the patients in the series.

Preoperative planning was based on CTA. Perioperative data are presented in Table II. All four cases were technically successful, with no postoperative complications. In case 2, persistent bleeding was encountered after opening the right iliac aneurysm sac. This required deployment of the GHVG before completion of the iliac anastomosis to

control the bleeding. Despite significant reported estimated blood loss (EBL) in the first three cases (1.8 L, 2.1 L, 1.8 L), no patient required blood transfusion. Intraoperative cell salvage was used in all cases. Operative data are presented in Table III. Postoperatively, all patients were observed in the intensive care unit for one night. On postoperative day (POD) 1, patients were transferred to the ward. All patients tolerated a regular diet on POD 2 and were discharged on POD 4. Of the four patients, the first three were employed and returned to work at 6, 4, and 2 weeks, respectively. Surveillance was performed by duplex ultrasound at 6 weeks and by CTA at 6 months and demonstrated 100% patency of the iliac reconstructions (Fig 3). There was no evidence of connective tissue disorders based on histopathologic evaluation of vascular specimens obtained at the time of surgery.

DISCUSSION

In this series, we successfully implemented a total robotic approach to repair unilateral and bilateral CIA aneurysms with the addition of the GHVG to provide a sutureless anastomosis to the IIA. Use of the robot and the GHVG allows the practitioner to push the limits of laparoscopy through improved dexterity and even further by using a sutureless anastomosis technique for the technically challenging IIA anastomosis. In addition, we found the GHVG to be a useful bailout strategy for persistent bleeding from the IIA by deploying it

Table II. Preoperative arterial sizing based on computed tomography angiography (CTA) images

Diameter	Case 1	Case 2	Case 3	Case 4
Right CIA aneurysm, mm	43	25	NA	27
Left CIA aneurysm, mm	N/A	32	34	40
Distal aorta, mm	15	20	19	20
Right proximal CIA, mm	10	15	N/A	15
Right IIA, mm	7	9	N/A	9.5
Right EIA, mm	9.5	9	N/A	11
Left proximal CIA, mm	N/A	11	12	12
Left IIA, mm	N/A	7.5	8	9.5
Left EIA, mm	N/A	10	11	10.5

CIA, Common iliac artery; EIA, external iliac artery; IIA, internal iliac artery; N/A, not applicable.

Table III. Operative data and timing

Operative data	Case 1	Case 2	Case 3	Case 4
Surgical approach, minutes	28	45	38	69
Proximal clamp time, minutes	163	110	135	152
Anastomosis time, minutes				
Aorta	N/A	26	N/A	20
GHVG distal insertion	21	12 (R), 18 (L)	27	11(R), 8(L)
CIA	33	N/A	19	N/A
PTFE hybrid	20	13 (R), 15 (L)	23	14 (R), 10 (L)
EIA	14	15 (R), 18 (L)	19	30 (R), 13 (L)
Total operative time, minutes	325	491	332	385
EBL, L	1.8	2.1	1.8	0.8
Time to resumption of diet, POD	2	2	2	2
Time to discharge, POD	4	4	4	4
Time to return to full physical activity, weeks	6	6	6	4

CIA, Common iliac artery; EBL, estimated blood loss; EIA, external iliac artery; GHVG, Gore Hybrid Vascular Graft; N/A, not applicable; POD, post-operative day; PTFE, polytetrafluoroethylene.
Surgical approach describes the amount of time required from the beginning of the dissection until the aortoiliac system is fully exposed and ready for clamping. Proximal clamp time refers to the aortic clamp in cases 2 and 4 and the common iliac artery clamp in cases 1 and 3.

earlier than planned. Once the graft was deployed within the IIA, the nonreinforced section could easily be clamped, and hemostasis was achieved. The robotic approach allows the surgeon to maintain a minimally invasive exposure while retaining the dexterity required to efficiently sew an arterial anastomosis. The da Vinci surgical system is a telemanipulation system with four arms (three manipulators, one camera) that allows the surgeon to employ laparoscopic access while maintaining a high level of dexterity comparable to that of the surgeon's own wrist. In addition, the system employs two high-definition cameras within a single housing, which creates a virtual three-dimensional image, providing improved depth perception compared with traditional laparoscopy. These advantages have improved the ability of surgeons to perform complex operations, such as aortoiliac reconstructions, through a minimally invasive approach.

A critical aspect of this technique is selection of patients. In addition to the exclusion criteria mentioned before, we carefully selected candidates for the early experience with total robotic iliac aneurysm repair on the basis of multiple factors. All patients were relatively young and healthy with favorable anatomy. In this subset of patients, we generally prefer a direct repair, be it open or robotic, over an endovascular repair to provide a durable treatment with a low reintervention rate. Given our experience in total robotic repair, we favor this technique over open repair in suitable patients as it results in decreased postoperative pain, decreased ileus, and faster discharge. Furthermore, open surgery is not without technical challenges, with many surgeons considering ligation of the IIA a viable option. An endovascular approach could have been used in these cases with various graft conformations and possible coil embolization of the IIAs. We consider the robotic

approach to be preferable in patients with a relatively long life expectancy who can tolerate a significant operative time. The robotic approach also significantly decreases the follow-up radiation requirements as this is essentially similar to an open direct repair with one or two GHVG anastomoses for the IIA. Data for the IBE, which has up to 60-month follow-up, suggest that this is a durable alternative as well. Patency rates are high, ranging from 86% to 93%. Reintervention remains an issue with a reported range between 4% and 22%, mostly related to endoleak.⁹⁻¹¹ Whereas a stented vessel is a component of this technique, the risk of endoleak is essentially eliminated by opening the aneurysm sac and managing any side branches by surgical ligation as well as tacking the stent in place in the IIA. Importantly, this technique should not be considered a superior technique to IBE or other endovascular modalities but rather an alternative approach for select patients with favorable anatomy.

All four patients had minimal calcification of both proximal and distal clamping sites as well as of the IIA origins within the recommended diameter range for use of the nitinol reinforced section of the GHVG (4.8-8.5 mm) and main IIA trunk length of at least 15 mm to provide sufficient overlap. One concern that was noted in this series was the relatively high EBL. This was expected in case 2, in which we encountered difficulty in controlling the right IIA; however, in the first two cases, the EBL did not correspond to what we subjectively experienced during the cases. Based on the long operative times, we expect a relatively higher EBL than might be expected otherwise, but laparoscopic and robotic cases may give a more accurate estimate of blood loss as all blood is removed by suction, which can then be measured directly. We do not use gauze sponges as in open surgery, which can absorb a significant amount of blood that is then not generally directly measured. In addition, none of these patients experienced hemodynamic instability or required a blood transfusion. This requires continued monitoring as additional cases are performed.

Whereas robotic surgery has demonstrated significant benefits in pelvic urologic and gynecologic surgery, including lower rates of conversion to open surgery, less blood loss, and decreased length of hospital stay, it has been slow to catch on in vascular surgery.¹² This is most likely related to the excellent endovascular options that are now widely available. Like many urologic procedures performed robotically, iliac aneurysm repair requires deep pelvic dissection, which results in a technically difficult distal anastomosis, especially using conventional laparoscopy. In the field of minimally invasive surgery, vascular laparoscopy has had a low adoption rate because of a difficult learning curve and readily available endovascular alternatives. However, the improved dexterity offered by the robotic system

may help overcome these challenges. We previously demonstrated an easier learning curve in completion of vascular anastomoses with the robotic system when it is used by vascular trainees.¹³ The slow adoption of robotic vascular surgery can also be attributed to the perceived risk associated with the telemanipulation of vessels. However, several published series of partial and total robotic aortoiliac operations have demonstrated a low mortality and acceptable conversion rate. Stadler et al¹⁴ recently published results of 310 robot-assisted vascular operations, including 224 cases for occlusive disease and 65 cases for aortoiliac aneurysm surgery. The 30-day mortality was 1.6% for aneurysms and 0% for occlusive disease. Conversion rates were 13% for aneurysms and 0.9% for occlusive disease. The authors reported that conversions were mainly due to anastomotic bleeding or technical problems with the anastomosis. Notably, similar to our series, nearly all patients began a solid diet on POD 2, and the mean hospital stay was 5 days. Similarly, low mortality and conversion rates have also been reported by Novotný et al¹⁵ (0% mortality, 5% conversion), Jongkind et al¹⁶ (3% mortality, 14% conversion), and Lin et al¹⁷ (0% mortality, 4% conversion).

Whereas the long-term outcomes of GHVG remain to be seen, multiple authors have reported excellent short-term patency (92%-94%) of visceral vessels treated in this manner.^{8,18} Important limitations of this technique include the risk of autonomic nerve injury due to CIA dissection (particularly on the left), risk of ilio caval injury, high EBL, and long operative time. One important aspect of these cases deserves closer focus—the overall length of the operations. This must be taken in context with the considerable number of anastomoses (both suture and sutureless), especially in the bilateral cases, in which we perform seven. However, despite the increase in total operative time and blood loss, we believe the benefit of a durable repair with a minimally invasive approach outweighs this disadvantage. We expect that the operative time should decrease as we gain more experience with this technique, and patients were still able to be discharged within 4 days, returning to work within 2 to 4 weeks and to active sports at 6 weeks.

CONCLUSIONS

In carefully selected patients, use of the GHVG for IIA preservation is possible during total robotic CIA aneurysm repair. Deployment of the graft using the robotic instruments was not difficult, and the GHVG appeared as a valuable tool for the robotic aortic surgeon to decrease operative time and to address difficult-to-control pelvic vessels.

We would like to acknowledge and thank Catherine Meunier-Cers of WebSurg for creating the illustrations for this publication.

REFERENCES

1. Lobato AC, Camacho-Lobato L. The sandwich technique to treat complex aortoiliac or isolated iliac aneurysms: results of midterm follow-up. *J Vasc Surg* 2013;57(Suppl):26S-34S.
2. Paravastu SCV, Jayarajasingam R, Cottam R, Palfreyman SJ, Michaels JA, Thomas SM. Endovascular repair of abdominal aortic aneurysm. *Cochrane Database Syst Rev* 2014;1:CD004178.
3. van Sterkenburg SM, Heyligers JM, van Bladel M, Verhagen HJ, Eefting D, van Sambeek MR, et al; Dutch IBE Collaboration. Experience with the GORE EXCLUDER iliac branch endoprosthesis for common iliac artery aneurysms. *J Vasc Surg* 2016;63:1451-7.
4. Coggia M, Javerliat I, Di Centa I, Colacchio G, Cerceau P, Kitzis M, et al. Total laparoscopic infrarenal aortic aneurysm repair: preliminary results. *J Vasc Surg* 2004;40:448-54.
5. Lin JC, Kolvenbach R, Pinter L. Combining open and endovascular surgery for the treatment of infrarenal abdominal aortic aneurysm: a case report using a hybrid vascular graft. *J Vasc Surg* 2005;41:881-4.
6. Valenti D, Sayed S, Mistry H, Rashid H, Gambhir R, Slim H. Carotid bypass using the Gore Hybrid Vascular Graft as a rescue technique for on-table failed carotid endarterectomy. *J Vasc Surg* 2016;64:229-32.
7. Nigro G, Gatta E, Pagliariccio G, Grilli C, Carbonari L. Use of the Gore Hybrid Vascular Graft in a challenging high-lying extracranial carotid artery aneurysm. *J Vasc Surg* 2014;59:817-20.
8. Setacci F, Pecoraro F, Chaykovska L, Mangialardi N, Shingaki M, Veith FJ, et al. The Gore Hybrid Vascular Graft in renovisceral debranching for complex aortic aneurysm repair. *J Vasc Surg* 2016;64:33-8.
9. Schneider DB, Milner R, Heyligers JM, Chakfe N, Matsumura J. Outcomes of the GORE Iliac Branch Endoprosthesis in clinical trial and real-world registry settings. *J Vasc Surg* 2019;69:367-77.e1.
10. Fargion AT, Masciello F, Pratesi C, Pratesi G, Torsello G, Donas KP; pELVIS Registry collaborators. Results of the multicenter pELVIS Registry for isolated common iliac aneurysms treated by the iliac branch device. *J Vasc Surg* 2018;68:1367-73.
11. Marques de Marino P, Botos B, Kouvelos G, Verhoeven EL, Katsargyris A. Use of bilateral Cook Zenith iliac branch devices to preserve internal iliac artery flow during endovascular aneurysm repair. *Eur J Vasc Endovasc Surg* 2018 Aug 31. [Epub ahead of print].
12. Yaxley JW, Coughlin GD, Chambers SK, Occhipinti S, Samaratunga H, Zajdlecicz L, et al. Robot-assisted laparoscopic prostatectomy versus open radical retropubic prostatectomy: early outcomes from a randomised controlled phase 3 study. *Lancet* 2016;388:1057-66.
13. Lucereau B, Thaveau F, Lejay A, Roussin M, Georg Y, Heim F, et al. Learning curve of robotic-assisted anastomosis: shorter than the laparoscopic technique? An educational study. *Ann Vasc Surg* 2016;33:39-44.
14. Stadler P, Dvoracek L, Vitasek P, Matous P. Robot assisted aortic and Non-aortic Vascular Operations. *Eur J Vasc Endovasc Surg* 2016;52:22-8.
15. Novotný T, Dvorák M, Staffa R. The learning curve of robot-assisted laparoscopic aortofemoral bypass grafting for aortoiliac occlusive disease. *J Vasc Surg* 2011;53:414-20.
16. Jongkind V, Diks J, Yeung KK, Cuesta MA, Wisselink W. Mid-term results of robot-assisted laparoscopic surgery for aortoiliac occlusive disease. *Vascular* 2011;19:1-7.
17. Lin JC, Kaul SA, Bhandari A, Peterson EL, Peabody JO, Menon M. Robotic-assisted aortic surgery with and without minilaparotomy for complicated occlusive disease and aneurysm. *J Vasc Surg* 2012;55:16-22.
18. Chiesa R, Kahlberg A, Mascia D, Tshomba Y, Civilini E, Melissano G. Use of a novel hybrid vascular graft for sutureless revascularization of the renal arteries during open thoracoabdominal aortic aneurysm repair. *J Vasc Surg* 2014;60:622-30.

Submitted Mar 7, 2018; accepted Jan 31, 2019.