



## Case Report

# Sarcoidosis with Hepatic Involvement: A Case Report

Banu Yılmaz Özgüven,<sup>1</sup> Deniz Tunçel,<sup>1</sup> Fevziye Kabukçuoğlu,<sup>1</sup> Süleyman Özdemir,<sup>1</sup> Canan Alkim<sup>2</sup>

<sup>1</sup>Department of Pathology, Istanbul Sisli Hamidiye Etfal Application and Research Center, University of Health Sciences, Istanbul, Turkey

<sup>2</sup>Department of Gastroenterology, Şişli Hamidiye Etfal Training and Research Hospital, İstanbul, Turkey

### Abstract

Sarcoidosis is a systemic, noncaseating granulomatous disease with an unknown etiology. The liver is one of the most frequently affected organs. This case is presented to emphasize that hepatic granulomatous foci can lead to a determination of etiology in a diagnosis of sarcoidosis. A 53-year-old-female patient with complaints of fatigue and abdominal pain was admitted to the clinic of gastroenterology. The blood levels of alanine transaminase, aspartate transaminase, alkaline phosphatase and gamma-glutamyl transferase were markedly increased. The autoimmune parameters were negative. A Tru-Cut biopsy (Becton, Dickinson and Co., Franklin Lakes, NJ, USA) of the liver was performed based on the initial diagnoses of tuberculosis, lymphoma, and sarcoidosis. Histopathological evaluation revealed noncaseating granulomatous inflammation with Grade 3 macrovesicular steatosis. An investigation for hepatic sarcoidosis was recommended. The angiotensin-converting enzyme levels were 5 times higher than normal. Based on this result, the diagnosis was sarcoidosis with hepatic involvement. The treatment and follow-up of the patient continues.

**Keywords:** Granulomatous; hepatic; sarcoidosis

Please cite this article as "Yılmaz Özgüven B., Tunçel D., Kabukçuoğlu F., Özdemir S., Alkim C. Sarcoidosis with Hepatic Involvement: A Case Report. Med Bull Sisli Etfal Hosp 2018;52(1):54-56".

Sarcoidosis is a systemic, noncaseating granulomatous disease with an unknown etiology which is known to affect many organs. The liver is one of the most frequently affected. In many cases, hepatic involvement can be subtle. The present case is presented to emphasize that granulomatous foci detected in a biopsy performed to determine the reason for high levels of liver enzymes may play a guiding role in the determination of etiology.

### Case Report

In 2010, a 53-year-old female patient was consulted to the gastroenterology clinic with complaints of fatigue and abdominal pain. Biochemical analysis revealed elevated

blood levels of alanine aminotransferase (41 U/L), aspartate aminotransferase (108 U/L), alkaline phosphatase (ALP; 649 U/L), gamma-glutamyltransferase (GGT; 361 U/L) and a negative autoimmune panel. Ultrasound examination revealed hepatomegaly, and thoracic computed tomography results indicated that the lymph nodes in the mediastinum, paratracheal, and precarinal regions were 2x1 cm in size. Tru-Cut biopsy (Becton Dickinson and Co., Franklin Lakes, NJ, USA) of the liver was performed with the initial diagnoses of tuberculosis, lymphoma, and sarcoidosis. The histopathological evaluation indicated noncaseating granulomatous inflammation in the parenchyma consistent with grade 3 macrovesicular steatosis and foci of intralobular non-necrotising granulomatous inflammation (Figs. 1-3).

**Address for correspondence:** Deniz Tunçel, MD. Department of Pathology, Istanbul Sisli Hamidiye Etfal Application and Research Center, University of Health Sciences, Istanbul, Turkey

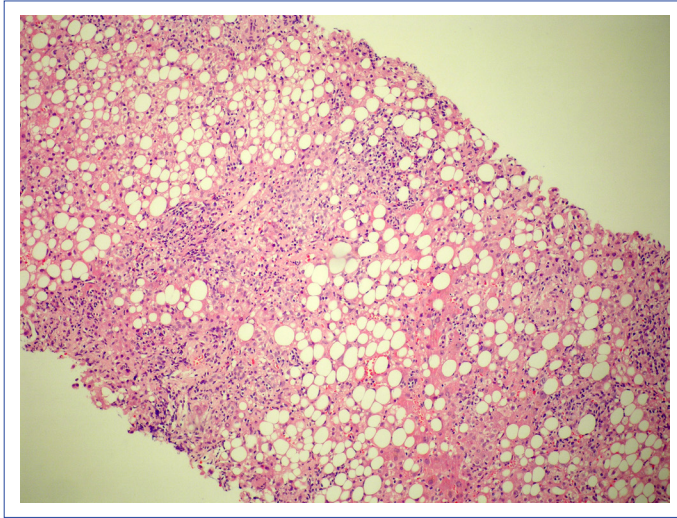
**Phone:** +90 505 391 31 81 **E-mail:** email@deniztuncel.com

**Submitted Date:** February 07, 2015 **Accepted Date:** April 17, 2017 **Available Online Date:** March 30, 2018

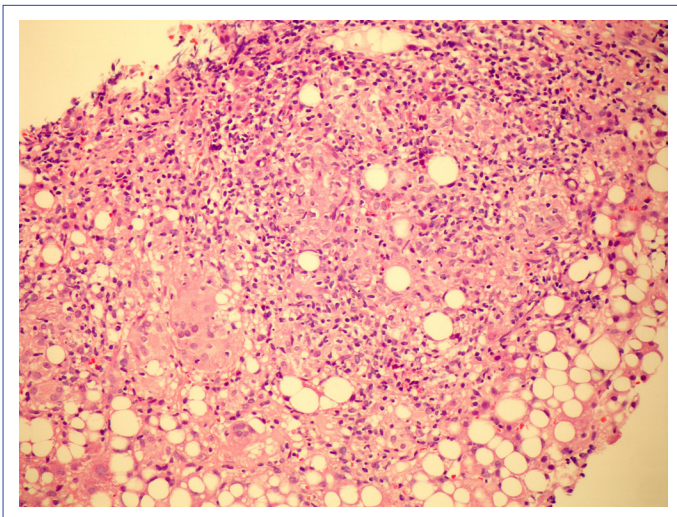
©Copyright 2018 by The Medical Bulletin of Sisli Etfal Hospital - Available online at [www.sislietfaltip.org](http://www.sislietfaltip.org)

This is an open access article under the CC BY-NC-ND license (<http://creativecommons.org/licenses/by-nc/4.0/>).





**Figure 1.** Intraparenchymal macrovesicular steatosis (Grade 3) and granulomatous formations consisting of epithelioid histiocytes and multinuclear cells (H&E, x100).

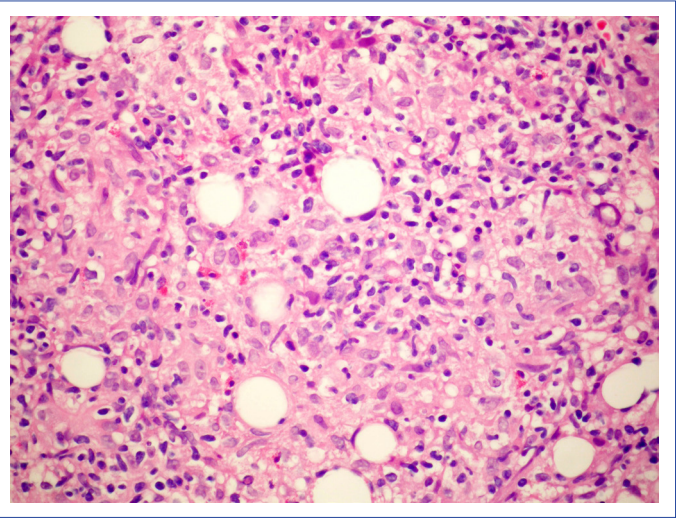


**Figure 2.** Intraparenchymal macrovesicular steatosis (Grade 3) and granulomatous formations consisting of epithelioid histiocytes and multinuclear cells (H&E, x200).

Ziehl-Neelsen staining results were unremarkable. As the angiotensin-converting enzyme level was 5 times higher than the upper limit of normal (250 U/L; normal: 8-52 U/L), the case was evaluated as sarcoidosis with hepatic involvement, and the patient was sent to a center with a sarcoidosis polyclinic. Treatment and follow-up continue.

## Discussion

Sarcoidosis is a disease with an unknown etiology characterized by granulomatous inflammation which most frequently affects the lungs, followed by the lymphoid system. In more than 90% of cases it is characterized by the presence of noncaseating granulomas containing activat-



**Figure 3.** Intraparenchymal macrovesicular steatosis (Grade 3) and granulomatous formations consisting of epithelioid histiocytes and multinuclear cells (H&E, x400).

ed T lymphocytes and mononuclear phagocytic cells in the lungs and lymph nodes, and may include the skin and eyes.<sup>[1, 2]</sup> The most affected intraabdominal organs are the liver, spleen, and lymph nodes. The liver is the third most frequently involved organ.<sup>[1]</sup> The most frequent sign of hepatic involvement in sarcoidosis is hepatomegaly, seen in more than half of the cases. Multiple nodules formed by the aggregation of granulomas may be observed in the liver.<sup>[3]</sup> Most cases with hepatic involvement have a subtle clinical course. In some cases, jaundice, chronic cholestasis, portal hypertension, and Budd-Chiari syndrome may develop.<sup>[4, 5]</sup> Cirrhosis is a very rarely seen entity in less than 1% of cases<sup>[6, 7]</sup> Granulomas are the characteristic histological feature in sarcoidosis.<sup>[6]</sup> In liver biopsies, granulomas have been reported in 60% to 80% of patients with sarcoidosis. However, laboratory findings of palpable hepatomegaly and/or liver involvement are detected in only 20% to 30% of the patients. Rarely, hepatic involvement might be the only manifestation of the disease. Sarcoidosis frequently affects the periportal areas. Isolated granulomatous hepatitis may be seen. If active hepatic inflammation is present, fever and upper left quadrant tenderness may be observed. In hepatic sarcoidosis, frequently, abnormalities in liver function tests are detected. The level of transaminases and bilirubin are slightly increased, and typically the values are greater than those of ALP and GGT transaminases. A cholestatic pattern may be seen.<sup>[8]</sup> In hepatic sarcoidosis, granulomatous lesions are often very small and clinically asymptomatic. Asymptomatic hepatic involvement and slightly increased transaminases do not require treatment; however, in cases with a marked increase in transaminases or severe hepatic dysfunction, steroids are used. With treat-

ment, the levels of enzymes normalize. If chronic granulomatous inflammation in the liver cannot be prevented, progressive hepatic cirrhosis, intrahepatic cholestasis, and portal hypertension may develop.<sup>[8]</sup> Frequently, intrahepatic cholestasis is seen in biopsy material. Cholestasis may develop as a consequence of cholestasis, hepatic granulomas, sarcoidotic involvement of intra- or extrahepatic biliary ducts, or compression of the common biliary duct by enlarged perihilar lymph nodes.<sup>[9, 10]</sup> Cholestasis was not observed in our case. In addition to foci of granulomatous inflammation, Grade 3 macrovesicular steatosis was present. The relationship between sarcoidosis and hepatosteatosis is not known. However, microgranulomas may accompany hepatosteatosis. Both of these conditions may lead to increased hepatic enzyme levels. Many diseases may induce formation of granulomas. These include autoimmune diseases (sarcoidosis, primary biliary cirrhosis, Wegener's granulomatosis, Crohn's disease), bacterial infections (mainly tuberculosis); viral infections (cytomegalovirus, Epstein-Barr virus infections, hepatitis A,B,C infections) fungal infections (histoplasmosis, cryptococcosis), parasitoses (toxoplasmosis, schistosomiasis), malignancies (especially Hodgkin's lymphoma), medications, and idiopathic causes of disease.<sup>[11, 12]</sup> When establishing a diagnosis, other clinical and laboratory findings of the patients in addition to histopathological characteristics are also important. The follow-up and treatment of this patient with a final diagnosis of sarcoidosis still continues.

#### Disclosures

**Informed consent:** Written informed consent was obtained from the patient for the publication of the case report and the accompanying images.

**Peer-review:** Externally peer-reviewed.

**Conflict of Interest:** None declared.

**Authorship contributions:** Concept – B.Y.Ö.; Design – B.Y.Ö.; Supervision – B.Y.Ö.; Materials – B.Y.Ö., C.A.; Data collection &/or processing – B.Y.Ö., C.A.; Analysis and/or interpretation – B.Y.Ö.; Literature search – S.Ö.; Writing – B.Y.Ö., D.T., S.Ö.; Critical review – F.K.

#### References

1. Tan CB, Rashid S, Rajan D, Gebre W, Mustacchia P. Hepatic sarcoidosis presenting as portal hypertension and liver cirrhosis: case report and review of the literature. *Case Rep Gastroenterol* 2012;6:183–9.
2. Ebert EC, Kierson M, Hagspiel KD. Gastrointestinal and hepatic manifestations of sarcoidosis. *Am J Gastroenterol* 2008;103:3184–92.
3. Gürses B, Seçil B. Diffüz karaciğer hastalıkları. *Trd Sem* 2015;3:349–65.
4. Blich M, Edoute Y. Clinical manifestations of sarcoid liver disease. *J Gastroenterol Hepatol* 2004;19:732–7.
5. Cremers J, Drent M, Driessen A, Nieman F, Wijnen P, Baughman R, et al. Liver-test abnormalities in sarcoidosis. *Eur J Gastroenterol Hepatol* 2012;24:17–24.
6. Gavilán F, Pereda T, Sousa JM, Serrano J, Gómez MA, García I, et al. Hepatic cirrhosis with sarcoid granulomas. Differential diagnosis and liver transplantation: a case report. *Transplant Proc* 2003;35:713–4.
7. Bass NM, Burroughs AK, Scheuer PJ, James DG, Sherlock S. Chronic intrahepatic cholestasis due to sarcoidosis. *Gut* 1982;23:417–21.
8. Okutur SK, Elibol ZS, Paksoy F, Dalar L, Borlu F. Atipik seyirli bir sarkoidoz olgusu. *Solunum* 2006;8:128–32.
9. Yoshiji H, Kitagawa K, Noguchi R, Uemura M, Ikenaka Y, Aihara Y et al. A histologically proven case of progressive liver sarcoidosis with variceal rupture. *World J Hepatol* 2011; 27;3:271–4
10. Elloumi H, Marzouk S, Tahri N, Bahloul Z, Azouz MM. Sarcoidosis and liver involvement: a case series of 25 patients. *Rev Med Interne* 2012;33:607–14.
11. Akın FE, Bolat AD, Ersoy O. Granülomatöz Karaciğer Hastalıkları. *Güncel Gastroenteroloji* 2016;20:55–60.
12. Ozaras R, Yemisen M, Balkan II. More on hepatic granulomas. *Diagn Pathol* 2015;10:203.