

# Interdisciplinary care of children with diffuse midline glioma



Christina Coleman<sup>a</sup>; Katherine Chen<sup>b</sup>; Alex Lu<sup>b</sup>;  
Elizabeth Seashore<sup>a</sup>; Schuyler Stoller<sup>d</sup>;  
Taron Davis<sup>e</sup>; Steve Braunstein<sup>b</sup>; Nalin Gupta<sup>a,e</sup>;  
Sabine Mueller<sup>a,e,d,f,\*</sup>

<sup>a</sup> Department of Pediatrics, University of California, San Francisco, United States

<sup>b</sup> Department of Radiation Oncology, University of California, San Francisco, United States

<sup>c</sup> Department of Neurological Surgery, University of California, San Francisco, United States

<sup>d</sup> Department of Neurology, University of California, San Francisco, United States

<sup>e</sup> Department of Orthopedic Surgery, University of California, San Francisco, United States

<sup>f</sup> Department of Pediatrics, University of Zurich, Zurich, Switzerland

## Abstract

Diffuse Midline Glioma (DMG) which includes Diffuse Intrinsic Pontine Glioma (DIPG) is an infiltrative tumor of the midline structures of the central nervous system that demonstrates an aggressive pattern of growth and has no known curative treatment. As these tumors progress, children experience ongoing neurological decline including inability to ambulate, swallow and communicate effectively. We propose that optimal care for patients with DMG should involve a specialized team experienced in caring for the multifaceted needs of these patients and their families. Herein we review the roles and evidence to support early involvement of a specialized interdisciplinary team and outline our views on best practices for these challenging tumors.

*Neoplasia* (2023) 35, 100851

**Keywords:** Diffuse Midline glioma, DIPG, Interdisciplinary care, Best practices

## Introduction

DMG including DIPG accounts for 10-20% of central nervous system (CNS) tumors in children [1]. The reported median survival is approximately 11 months from the time of diagnosis and only 4-5 months after radiologic progression with few children surviving past 2 years from diagnosis [2,3]. Biologically DMG is largely defined by highly specific and recurrent somatic mutations in the histone proteins H3.3 (~65%) and H3.1 (~20%), with a lysine-to-methionine substitution at position 27 on the histone tail (K27M) [4-6]. This results in abrogated H3K27 trimethylation and repression of the PRC2 complex. Recent evidence supports that loss of H3K27 trimethylation in DMG can also occur through EZHIP overexpression [7]. The most recent WHO classification introduced the category of *DMG H3K27M altered*, which includes tumors of the brainstem as well as other midline structures

such as the thalamus and spine [8]. Analysis of human DMG has shown that H3K27M mutations co-segregate non-randomly with specific partner mutations dependent on H3 subtype and anatomical location remains limited.

## Presentation and Initial Management

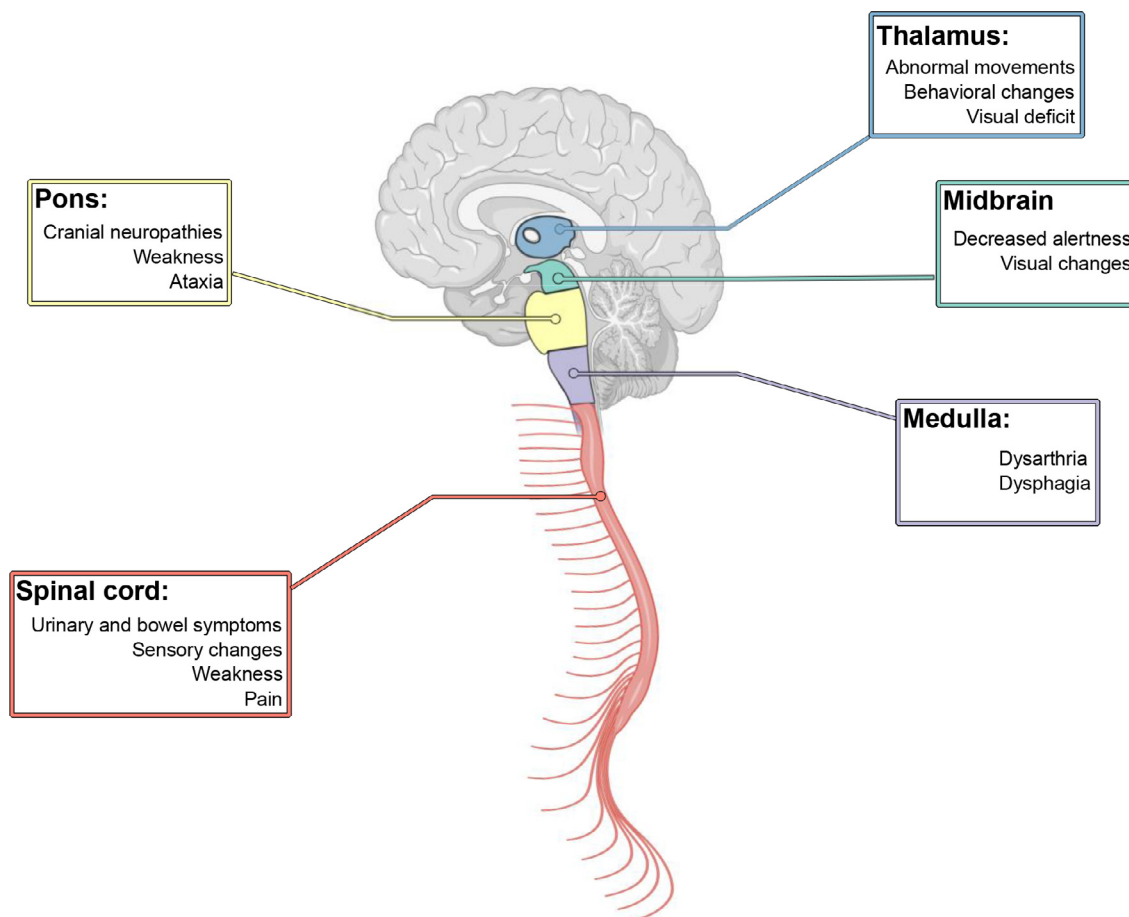
Patients with DIPG typically present after a mean of 2 months of symptoms [3] which generally include ataxia, long tract signs and cranial neuropathies, most often an abducens nerve palsy [9]. Children with DMG outside of the pons present with varied symptoms based on the specific location of the tumor. Symptoms can also be suggestive of dissemination.

Dissemination typically occurs over the course of the disease and may even occur prior to initial diagnosis [10]. Therefore, spine imaging at diagnosis and with progression is advised [11,12]. Once a suspected diagnosis of DMG is made based on imaging, a referral should be made to oncologists who are specialized in neuro-oncology. The initial consultation often centers around diagnostic evaluation, treatment options as well as overall prognosis. A neurosurgical referral for discussion of biopsy or other surgical interventions is strongly recommended unless urgent start of radiation therapy is indicated due to presenting clinical symptoms. Radiation oncology plays a critical role in the treatment of children with DMGs and consultation with a radiation oncologist who specializes in CNS tumors is recommended. Other referrals should also be made early based on patient specific symptoms, and

\* Corresponding author at: Departments of Neurology, Neurosurgery and Pediatrics, University of California, San Francisco, Sandler Neuroscience Building, 675 Nelson Rising Lane, San Francisco, CA 94148, United States.

E-mail address: [sabine.mueller@ucsf.edu](mailto:sabine.mueller@ucsf.edu) (S. Mueller).

Received 14 August 2022; received in revised form 10 October 2022; accepted 22 October 2022



**Fig. 1.** DMG symptoms based on tumor location.

this can include psychiatry, speech, physical and occupation therapy as well as ophthalmology. Early involvement of supportive care services including palliative care and social work is an integral aspect of care for these patients and their families especially considering the needs of siblings

Upfront treatment for symptom management often involves use of dexamethasone for relief of tumor related edema. However, given the many toxicities associated with steroid use such as significant weight gain, mood changes, and lymphopenia among others, the use of steroids should be discussed carefully with the family, patient and treating provider. Bevacizumab can help to decrease steroid use in patients who do not tolerate steroid wean and has been associated with improvement in reported quality of life (QOL) [13]. Given the lack of an acceptable standard of care, clinical trial participation should be discussed early in the disease course as some clinical trials enroll prior to biopsy or start of radiation therapy [14–16].

Given the rarity of these tumors and the complexity of care, second opinions and referral to centers of excellence should be offered to families. This can be challenging to arrange in a timely manner as a family navigates making treatment decisions. A new initiative of a National DIPG/DMG tumor board has been created to offer families a virtual comprehensive second opinion by a team of expert pediatric neuro-oncologists with the goal of facilitating this process (Figs. 1 and 2).

A discussion around post-mortem tissue donation should be integrated into clinical conversations with families impacted by DMG. While the best time for such a conversation depends on each family's particular context, our general recommendation is to have these discussions early in the course of treatment [17].

### Clinical Trial Participation: Pros and Cons

Numerous trials are currently open in the upfront and progression setting for DMG. Current approaches include small molecule inhibitors, targeted delivery and immunotherapy.

Given the number early phase trials with varying demands (in regard to number of visits, surgical interventions etc.) and potential risks, families face challenges in choosing the right trial option for them. Moreover, there can be uncertainty regarding eligibility and slot availability. The decision to participate in an early phase trial without known benefit for a terminal illness is complex and requires clear communication between physician, parent and child [18]. While there are many possible benefits to trial participation in clinical trials, there are also risks and demands placed on families including side effects, frequent travel and associated expenses. To date few clinical trials have integrated the use of comprehensive quality-of-life (QOL) measures. This is an important aspect when offering clinical trials to such a vulnerable patient population and should be investigated in future studies.

Disparity in access to clinical trials remains a problem with research showing that in the US, Hispanic children are being particularly underrepresented [19,20]. Adolescents and young adults (AYA), particularly young Black men, also represent a population who are less frequently enrolled in clinical trials [21–23]. These disparities are multifactorial and warrant further study to improve access to innovative therapies for a disease that lacks any standard of care options.

Given the paucity of treatment options for DMG, a significant number of families also report the use of complementary and alternative medicine both

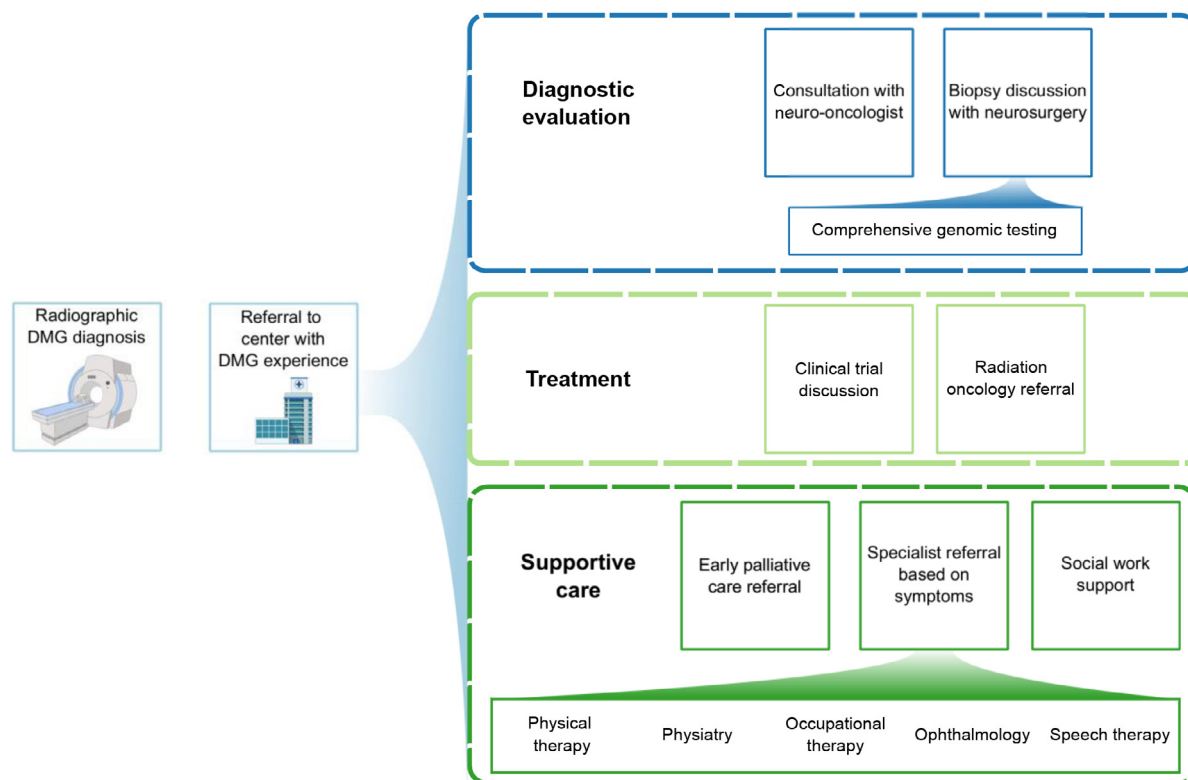


Fig. 2. Recommended referrals for new patient with DMG

for possible anti-tumor properties as well as symptomatic management [24]. For example, families are increasingly reporting use of cannabidiol (CBD) in cancer patients [25]. Pre-clinical studies have shown limited efficacy of CBD in killing DMG cells *in vitro* and decreasing tumor volume in animal models [26]. The use of a ketogenic diet has also shown limited efficacy [27] in preclinical models of glioblastoma. In a small retrospective study 5 out of 6 patients identified to have followed a ketogenic diet adhered to the diet for at least 3 months [28].

Further studies are needed to understand how diet and alternative medicine might be useful in the treatment and supportive care of patients with DMG. It is also crucial for treating physicians to know what supplements patients might be taking to understand possible interactions with concurrent therapies. We strongly recommend a detailed discussion with a trained neuro-pharmacologist about any supplements, specifically when the child is receiving experimental therapies on a clinical trial.

Whether or not a family decides to pursue treatment on a clinical trial, patients should have access to a center with interdisciplinary care and consultation with specialists experienced in evaluating and treating patients with DMG to provide comprehensive diagnostic, treatment, and supportive care.

#### DMG Biopsy: Approach, Benefits, and Risks

Until the early 2000s, surgical biopsy of DMG/DIPG was felt to be associated with high risk of complication, and the imaging and clinical features of these patients was believed to be sufficient to allow a diagnosis [29]. Significant advancements in neuroimaging such as diffusion tensor imaging and frameless stereotactic technologies have led to a re-evaluation of performing biopsies of tumors located within the brainstem [30]. Experienced pediatric neurosurgeons at major brain tumor centers can now obtain brainstem biopsies with an acceptable risk profile [31].

The availability of tissue has allowed detailed analyses of these tumors which has demonstrated the biologic diversity of these tumors, suggesting potential personalized therapies based on individual tumor molecular profiles [14,16,32–35]. Once a biopsy is obtained, the tissue is reviewed by a neuropathologist with IHC testing for H3K27M to rapidly confirm diagnosis. Recent consensus recommendations also advise that the tissue should undergo comprehensive genomic analysis with DNA based next generation sequencing as well as RNA fusion testing and methylation profiling if available, to allow for detailed discussion of prognosis, possible targeted therapies and relevant clinical trials [36]. Broad sharing of this molecular data will also help in our advancement of understanding of these tumors and is therefore strongly encouraged.

Two primary routes are used to biopsy tumors within the pons: transfrontal and transcerebellar. For tumors that extend superiorly into the midbrain or thalamus, a transfrontal approach would be preferred. However, because the transfrontal biopsy tract is longer and could unintentionally traverse structures such as the ventricle, tentorium, and major blood vessels, the transcerebellar approach through the middle cerebellar peduncle is favored [37]. A frameless stereotactic system for three-dimensional registration is used with a 2 centimeter incision and single burr hole spanning 10-15 millimeters in diameter posterior to the ear and inferior to the transverse sinus [38]. The dorsal half of the tumor is usually targeted to avoid major descending motor tracts of the ventral pons. Biopsies can safely yield 4-6 core samples that are ~3 millimeters in length and 1 millimeter in diameter [38]. General contraindication to biopsy includes pre-existing poor functional status such as severe swallowing/breathing difficulties or tetraplegia.

A meta-analysis of 735 brainstem mass biopsies in children (primarily single institution series) in 2017 revealed a diagnostic success rate of 96.1% with 0.6% of permanent morbidity and 0.6% for mortality [39]. In the DIPG Biology and Treatment Study (DIPG-BATS), 50 patients at

23 institutions underwent biopsy, of which 46 (92%) provided sufficient tissue to perform all study assays. No deaths occurred in this study and only one patient (2%) experienced a permanent neurologic deficit (hemiparesis) attributable to the biopsy [38]. Rarely, biopsy tracts may become disseminated with tumor although it remains unclear whether the tract should be included in radiotherapy fields. Another multi-institutional DIPG study, the Individualized Therapy For Relapsed Malignancies in Childhood (INFORM), had similar safety outcomes with no mortalities and only 1 out of 21 (4.7%) biopsies with permanent worsened neurologic deficit [40,41]. In INFORM, 16 of 21 biopsies (76%) identified potential targetable molecular alterations of which 5 patients (23.8%) proceeded with personalized therapy. Biopsy is generally done at time of initial diagnosis but has also been successfully completed after radiation therapy if the start of radiation cannot be delayed due to severe symptoms [42].

#### *Cerebrospinal Fluid Diversion and Ventricular Access in DIPG/DMG*

Ventriculomegaly associated with DIPG/DMG can be caused by mass effect on the fourth ventricle and resulting cerebrospinal fluid (CSF) outflow obstruction, or in the setting of disseminated leptomeningeal disease and reduced CSF reabsorption. Mild to moderate ventriculomegaly often occurs in patients with DIPG, but the majority of cases are asymptomatic and can be managed without surgical intervention. One single institutional series of 82 DIPG patients found 23 (28%) patients with ventriculomegaly on presentation, of which 8 (9.7%) were symptomatic and required CSF diversion [43]. Notably, 6 (26.1%) patients had ventriculomegaly resolution after radiation therapy. However, at time of progression for 66 patients, 36 (54.5%) of patients had ventriculomegaly with 9 (13.6%) requiring CSF diversion. Convection enhanced delivery of therapeutic agents into the brainstem may also increase ventricular volume but without the need for CSF diversion [44].

For patients with ventriculomegaly and clear symptoms such as headache, nausea/vomiting, and/or decreased level of consciousness that cannot be otherwise explained, there are two options for CSF diversion: a ventriculoperitoneal shunt (VPS), or endoscopic third ventriculostomy (ETV). A VPS allows diversion of CSF from cerebral ventricles into the peritoneal cavity through a small flexible tube, with a mechanical valve that controls the rate of CSF flow. While one of the most common neurosurgical procedures, VPS have a number of shortcomings. Infection or blockage of any VPS component can result in revision surgery, prolonged intensive care stays, extensive antibiotic regimens, and/or conversion of the VPS distal catheter into higher complication locations such as lung pleura, vena cava, or gallbladder. Tumor dissemination through VPS tubing into the abdominal cavity has also been described [45].

By contrast, an ETV creates a fenestration in the third ventricular floor, allowing CSF to flow to the subarachnoid cisterns anterior to the brainstem to bypass an obstructed fourth ventricle. The main advantage of ETV to a VPS is the lack of a permanent implant although not all DIPG/DMG patients with hydrocephalus are amenable to ETV. According to the ETV success score [46], a DIPG patient between the ages of 1 and 10 without prior shunt would have a 70% chance of ETV success. A meta-analysis of DIPG patients with hydrocephalus found that 30 of 35 (86%) patients undergoing ETV to experience clinical improvement after surgery [46,47]. One consideration that affects the decision to place a VPS or perform an ETV is maximizing a patient's functional status either to allow clinical trial enrollment, or in a palliative setting.

Lumbar drains, external ventricular drains, and Ommaya reservoirs are alternative methods of temporary CSF diversion due to the need for an external system of CSF collection or access. One potential benefit of the Ommaya reservoir for clinical trial design is the ability to infuse intraventricular therapeutic agents while providing a means to both monitor and treat increased intracranial pressures as demonstrated by the recent phase

I clinical trial of GD-2 directed chimeric antigen receptor T cells [48]. In some cases, patients will have mild ventriculomegaly without symptoms. In this situation, close observation without intervention is reasonable, particularly since many patients have at least a partial reduction in tumor size following radiation therapy.

#### *Radiation Therapy*

Radiation therapy is the mainstay of management for DMGs in providing local control and durable palliation of tumor. Although not curative in intent, treatment does appear to extend survival by about 3-4 months over best supportive care [49]. Importantly, radiation therapy is well-tolerated and results in high rates of symptomatic improvement in >80% of patients, and this initial benefit may be observed as early as the first 2-3 weeks of treatment [50,51].

In the upfront setting, conventionally fractionated radiation is prescribed to a total dose of 54 Gy in 1.8 Gy daily fractions over a course of 6 weeks. An alternate 2.5-week course of hypofractionated radiation therapy to a dose of 39 Gy in 3 Gy daily fractions has been shown to have comparable outcomes and toxicity, although did not meet the statistical threshold for non-inferiority in randomized trial [52,53]. However, hypofractionation may be a reasonable option to consider particularly for more debilitated patients, for whom the logistical burden of radiation may be relatively higher and is now considered the preferred strategy in some countries in Europe.

Modern radiation treatments are highly conformal in nature, and radiation fields for DMG are targeted to the radiographically-defined tumor with a limited clinical and setup margin. Photon radiation is commonly used given its widespread availability, but there has been interest in the use of proton radiation given potential advantages in minimizing dose to uninvolved brain. The use of protons for lesions in the brainstem and posterior fossa is somewhat controversial, given that some studies have reported elevated rates of brainstem necrosis up to 10% or higher [54,55]. However, others have identified low risk of brainstem necrosis with protons when adherent to careful dosimetric guidelines, suggesting a need for thoughtful radiation planning at an experienced proton radiation center [56,57].

To deliver high-quality, reproducible radiation treatments, coordination with anesthesia may be required for sedation of patients under the age of 6-7 or those unable to independently lie still during treatment. In conjunction with a custom immobilization mask, sedating agents such as propofol may be used to minimize patient motion and improve tolerability for young patients while alone in the treatment vault [58,59]. The use of anesthesia may add about 30-60 minutes to time spent in the department, with treatment times typically scheduled early in the morning due to need for patient fasting [60]. In light of these logistical considerations, there has been interest in alternative behavioral and environmental strategies to minimize treatment-related distress and need for sedation, including engagement with child life specialists.

Overall, radiation treatment for DMG is well-tolerated. Acute toxicities may include fatigue or dermatitis in the area of the radiation field, such as over the retroauricular skin, which is typically mild and self-limiting in nature. Pseudoprogression is a treatment related change in imaging and sometimes symptoms that can be difficult to distinguish with progression and can be seen in patients with DMG, typically within 12 weeks after radiation therapy [61]. For patients who experience pseudoprogression, bevacizumab can improve symptoms with minimal toxicity [62]. As most patients are already experiencing a number of tumor-related deficits at baseline, radiation therapy should generally not be delayed for side effect concerns due to the high potential for worsening morbidity or mortality from tumor progression.

Following initial radiation treatment, median progression-free survival is on the order of 6-8 months, indicating a need for close clinical and imaging surveillance [50,63]. Re-irradiation is an option for palliation at the time of recurrence, with nearly all tumors recurring within the treatment field.

In general, a minimum of at least 3-6 months between radiation courses is recommended [53]. In the re-irradiation setting, the radiation dose is on the order of 24-25 Gy in 10-12 fractions over 2-2.5 weeks [64,65]. Treatment has been associated with a benefit in median survival compared to no radiation at the time of recurrence, and it remains well-tolerated with the majority experiencing additional symptomatic improvement [53,66].

Despite advances in radiation delivery, the radiation treatment paradigm for DMG has remained largely unchanged for decades. To date, there is no evidence for benefit with the use of concurrent systemic therapy with radiation in either the upfront or recurrent setting, including radiosensitizing agents, intensive chemotherapy, or temozolomide [50,67-69]. The use of systemic agents in combination with radiation remains an area of active investigation in numerous ongoing clinical trials (NCT03416530, NCT05099003, NCT03605550), and trial enrollment should be encouraged.

### *Rehabilitation*

Patients with DMG are at risk for a variety of long-term functional neurologic impairments related to the pathology, surgical management, chemotherapy and radiation therapy [70,71]. Children may present with a wide range of focal neurologic impairment specific to the foci of injury. Damage to cortical and cerebellar tracks will impact movement and coordination, as well as muscular tone. Speech and swallow function are impacted by injury to cranial nerve nuclei and pathways. Global deficits in cognition, executive function, and communication issue from diffuse cortical and subcortical dysfunction. Due to their unique expertise in functional neurologic impairment and disability, pediatric physiatrists have an important role in the care of children with DMG. When possible, their expertise should be utilized to develop an appropriate interdisciplinary rehabilitation program that considers such multifocal deficits [70,72]. There is an increasing body of evidence in support of the therapeutic impact of exercise in neuro-oncology, and its promotion of neuroplasticity [71]. The physiatrist also assists in determining disposition, consideration for admission to an acute rehabilitation facility, and discharge planning. The pediatric physiatrist must lead in deciding appropriate intensity and setting (inpatient or outpatient) for rehabilitation care. They should also help providers, families, and patients understand such determinations [70]. For those children who require inpatient rehabilitation, the pediatric physiatrist should outline goals for inpatient rehabilitation therapy, work on functional goals and optimize therapeutic interventions within a specified period. Further, the physiatrist will prepare and educate family, caregivers, and patients on safety in the setting of impairment and disability prior to discharge from the hospital. Physiatrists can also assist in the medical, environmental, and pharmacologic management of specific symptoms including hypertonia, dystonia and spasticity, sleep/arousal impairments, paroxysmal sympathetic hyperactivity, as well as mood and behavioral disturbances [70,73].

### *Gross Motor and Mobility*

In addition to pediatric physiatry, consultation of physical therapy should be considered for any child with DMG with new motor or sensory deficit, especially those impacting functional mobility. In-hospital physical therapy evaluation can provide insight into the child's functional strength, assess tone, deficit awareness, and safety, as well as assist with and educate on repositioning, transfers, and mobility. A physical therapist can also provide recommendations for bracing and mobility equipment.

### *Fine Motor and Activities of Daily Living*

Occupational therapy (OT) consultation includes evaluation of tone impacting upper extremity function and recommendations for passive

and active orthotic bracing to improve extremity function. Occupational therapists also assess self-care domains in activities of daily living and can offer interventions to adapt and accommodate new disability. They also evaluate patients for durable medical equipment that may be required upon discharge for safety and independence in the setting of functional neurologic impairment.

### *Dysphagia*

Patients with brainstem DMG are at high risk for injury to cranial nerves and motor pathways controlling speech and swallow function. As a result, many patients develop dysphagia. Speech and language pathologists (SLP) and OT have an important role in managing swallow dysfunction in the inpatient and outpatient care settings [74]. These providers should be consulted early in the child's cancer journey. After biopsy, radiation therapy, or with any clinical change concerning for new cranial nerve deficit, an abundance of caution should be taken before clearing a child for oral drinking or feeding without dysphagia assessment. SLP/OT can provide bedside evaluations of swallow function as well as offer recommendations for advanced swallow studies. They are instrumental in providing education on safe swallow techniques to minimize inadvertent risks for injury such as aspiration.

### *Cognition and communication*

SLPs are also instrumental in the evaluation of communication and language function in children at risk from new impairment as a result of DMG or as a sequela of its treatment. The interventions for communication and language impairment must cater to the underlying etiology. For instance, neurologic injury resulting in aphasia (an impairment in production or understanding of language) will have different interventions from dysarthria (an impairment in the motor production of language) the latter of which may lend itself to augmentative and alternative communication devices and strategies such as communication boards.

### *Palliative Care*

Another critical aspect of interdisciplinary care for children with DMG is engagement with palliative care services. Pediatric palliative care (PPC) is an approach that focuses on addressing the physical, emotional, psychosocial, and spiritual needs of patients and families facing life-threatening and life-limiting illnesses. PPC can be provided by primary team members with specific training, or if available, by a subspecialty-trained team including physicians, advance practice providers, nurses, social workers, chaplains, child life specialists, and bereavement counselors. According to the World Health Organization definition, PPC "begins when illness is diagnosed, and continues regardless of whether or not a child receives treatment directed at the disease" [75].

Children and families facing DMG have several indications for close PPC involvement early in the disease course. First, they experience a significant symptom burden, one that progresses as a child approaches end of life. A retrospective cohort study of 64 children with DIPG in the United Kingdom found that patients experienced an average of 13 symptoms in the 12 weeks prior to death. Approximately 80% of children were found to have impaired mobility in the last three months of life, followed by the onset of dysarthria, dysphagia, and impaired nonverbal communication around two months before death, then finally an increase in breathing difficulty and loss of consciousness in the days preceding death. Less common though still prevalent symptoms in end-stage disease included nausea/vomiting, headache, constipation, urinary difficulty, behavioral issues, neuropathic pain, and seizures [76]. In addition, while the grim prognosis for these brain tumors is known, the disease trajectory for any given child is unpredictable.

PPC is focused on helping patients and families navigate this uncertainty by assisting in eliciting their goals of care and advocating on their behalf to the multiple involved subspecialties (neuro-oncology, neurology, neurosurgery, radiation oncology). PPC can also help facilitate clear communication of prognosis to the family and possibly also the child. In a study published based on a survey of bereaved parents, none of the parents who had talked to their child about dying regretted the discussion while 27% of the parents who did not discuss death with their child regretted not doing so [77]. Accordingly, caregiver distress is another source of suffering in the DMG patient population that would benefit from dedicated palliative care presence [78]. Finally, children with DMG often require intensive supportive care at the end of their life. Given over 75% of children with DIPG die at home, referral to hospice is often indicated. While the timing of hospice referral varies, it should be noted that a child and family do not need to choose between cancer therapies (radiation, phase I clinical trials) and enrollment in hospice, given the provision for concurrent disease-directed treatment and hospice care in the pediatric population and therefore we advocate for early engagement. PPC teams can help coordinate care and referral to hospice agencies.

Despite the indications and supportive evidence above, there remains a lack of research to support early PPC intervention for children with DMG. In a recent Cochrane review of patients with primary brain tumors and their caregivers, there were no studies of early specialist palliative care interventions or of early coordinated generalist palliative approaches [79]. Regardless, many oncology cooperative groups support early palliative care involvement for children with brain tumors. Specifically, the American Society of Clinical Oncology (ASCO) practice guidelines recommend early (within 8 weeks of diagnosis) palliative care consultation for patients with advanced cancer, defined as those with “distant metastases, late-stage disease, cancer that is life-limiting, and/or with prognosis of 6 to 24 months.” [80]. The pediatric DMG population certainly meets these criteria, and therefore we agree with the recommendation as described above. It is important to note that access to PPC may be a barrier for early palliative care intervention in many parts of the country, and in the global pediatric oncology community. In the same retrospective cohort of 64 children with DIPG in the United Kingdom, while 72% of surveyed clinicians reported they often mention PPC at the time of diagnosis, nearly 80% reported they did not have institutional guidelines for palliative care in children with DIPG [76]. Continued efforts to train PPC subspecialty providers and provide education in primary palliative care for neuro-oncology teams will also be important in ensuring children with DMG and their families receive optimal multidisciplinary patient-centered care throughout their illness journey. In centers that lack access to pediatric specific palliative care, oncology teams may also partner with adult palliative care providers to guide symptom management. With the broader use of telemedicine, combined visits with expertise in pediatric neuro-oncology and palliative care can be complementary.

## Conclusion

Patients with DMG have complex needs and therefore we strongly advocate for care by a specialized interdisciplinary team. We encourage tissue acquisition given the known heterogeneity of these tumors and that safety has been demonstrated in many studies when done in experienced centers. Radiation therapy should occur within centers with dedicated pediatric neuro-oncology expertise. Further, given the lack of an acceptable standard of care for these tumors, we recommend trial enrollment whenever feasible, and also support for families to seek second opinions. In addition, we believe that early involvement of palliative care services, psychiatry with directed therapies and social work will overall improve the QOL of families and patients.

All authors on this paper participated in writing of the original draft and writing/review and editing.

Christina Coleman

## Declaration of Competing Interest

The authors have declared that no conflict of interest exists.

## Acknowledgements

Figures created with BioRender.com

## References

- Patil N, Kelly ME, Yeboa DN, et al. Epidemiology of brainstem high-grade gliomas in children and adolescents in the United States, 2000-2017. *Neuro Oncol* 2021;**23**(6):990–8.
- Cooney T, Lane A, Bartels U, et al. Contemporary survival endpoints: an International Diffuse Intrinsic Pontine Glioma Registry study. *Neuro Oncol* 2017;**19**(9):1279–80.
- Karremann M, Gielen GH, Hoffmann M, et al. Diffuse high-grade gliomas with H3 K27M mutations carry a dismal prognosis independent of tumor location. *Neuro Oncol* 2018;**20**(1):123–31.
- Schwartzentruber J, Korshunov A, Liu X-Y, et al. Driver mutations in histone H3.3 and chromatin remodelling genes in paediatric glioblastoma. *Nature* 2012;**482**(7384):226–31.
- Khuong-Quang D-A, Buczkowicz P, Rakopoulos P, et al. K27M mutation in histone H3.3 defines clinically and biologically distinct subgroups of pediatric diffuse intrinsic pontine gliomas. *Acta Neuropathol* 2012;**124**(3):439–47.
- Wu G, Broniscer A, McEachron TA, et al. Somatic histone H3 alterations in pediatric diffuse intrinsic pontine gliomas and non-brainstem glioblastomas. *Nat Genet* 2012;**44**(3):251–3.
- Castel D, Kergrohen T, Tauziède-Espariat A, et al. Histone H3 wild-type DIPG/DMG overexpressing EZHIP extend the spectrum diffuse midline gliomas with PRC2 inhibition beyond H3-K27M mutation. *Acta Neuropathol* 2020;**139**(6):1109–13.
- Louis DN, Perry A, Wesseling P, et al. The 2021 WHO Classification of Tumors of the Central Nervous System: a summary. *Neuro Oncol* 2021;**23**(8):1231–51.
- Veldhuijzen van Zanten SEM, Jansen MHA, Sanchez Aliaga E, van Vuurden DG, Vandertop WP, Kaspers GJL. A twenty-year review of diagnosing and treating children with diffuse intrinsic pontine glioma in The Netherlands. *Expert Rev Anticancer Ther* 2015;**15**(2):157–64.
- Sethi R, Allen J, Donahue B, et al. Prospective neuraxis MRI surveillance reveals a high risk of leptomeningeal dissemination in diffuse intrinsic pontine glioma. *J Neurooncol* 2011;**102**(1):121–7.
- Erker C, Tamrazi B, Poussaint TY, et al. Response assessment in paediatric high-grade glioma: recommendations from the Response Assessment in Pediatric Neuro-Oncology (RAPNO) working group. *Lancet Oncol* 2020;**21**(6):e317–29.
- Cooney TM, Cohen KJ, Guimaraes CV, et al. Response assessment in diffuse intrinsic pontine glioma: recommendations from the Response Assessment in Pediatric Neuro-Oncology (RAPNO) working group. *Lancet Oncol* 2020;**21**(6):e330–6.
- Evans M, Gill R, Bull KS. Does a Bevacizumab-based regime have a role in the treatment of children with diffuse intrinsic pontine glioma? A systematic review. *Neurooncol Adv* 2022;**4**(1):vdac100.
- Mueller S, Jain P, Liang WS, et al. A pilot precision medicine trial for children with diffuse intrinsic pontine glioma-PNOC003: A report from the Pacific Pediatric Neuro-Oncology Consortium. *Int J Cancer* 2019;**145**(7):1889–901.
- Mueller S, Yang X, Pal S, et al. Pdct-04. phase I trial of wee1 kinase inhibitor azd1775 combined with radiation therapy for children with newly diagnosed diffuse intrinsic pontine glioma: a report from the children's oncology group phase 1 pilot consortium (adv11217). *Neuro Oncol* 2018;**20**(suppl\_6):vi201–vi201.
- Kline C, Jain P, Kilburn L, et al. Upfront biology-guided therapy in diffuse intrinsic pontine glioma: therapeutic, molecular, and biomarker outcomes from PNOC003. *Clin Cancer Res* 2022.
- Kambhampati M, Panditharatna E, Yadavilli S, et al. Harmonization of postmortem donations for pediatric brain tumors and molecular characterization of diffuse midline gliomas. *Sci Rep* 2020;**10**(1):10954.

- [18] Le Rouzic M-A, Claudot F. Characteristics of parental decision-making for children with advanced cancer who are offered enrollment in early-phase clinical trials: A systematic review. *Pediatr Hematol Oncol* 2020;**37**(6):500–29.
- [19] Nooka AK, Behera M, Lonial S, Dixon MD, Ramalingam SS, Pentz RD. Access to Children's Oncology Group and Pediatric Brain Tumor Consortium phase I clinical trials: Racial/ethnic dissimilarities in participation. *Cancer* 2016;**122**(20):3207–14.
- [20] Aristizabal P, Singer J, Cooper R, et al. Participation in pediatric oncology research protocols: Racial/ethnic, language and age-based disparities. *Pediatr Blood Cancer* 2015;**62**(8):1337–44.
- [21] Siembida EJ, Loomans-Kropp HA, Trivedi N, et al. Systematic review of barriers and facilitators to clinical trial enrollment among adolescents and young adults with cancer: Identifying opportunities for intervention. *Cancer* 2020;**126**(5):949–57.
- [22] Mittal N, Langevin A-M, Kyono W, et al. Barriers to Pediatric Oncologist Enrollment of Adolescents and Young Adults on a Cross-Network National Clinical Trials Network Supportive Care Cancer Clinical Trial. *J Adolesc Young Adult Oncol* 2022;**11**(1):117–21.
- [23] Roth M, Beauchemin M, Kahn JM, Bleyer A. Patterns of National Cancer Institute-Sponsored Clinical Trial Enrollment in Black Adolescents and Young Adults. *Cancer Med* 2021;**10**(21):7620–8.
- [24] El-Khouly FE, Adil SM, Wiese M, et al. Complementary and alternative medicine in children with diffuse intrinsic pontine glioma-A SIOPE DIPG Network and Registry study. *Pediatr Blood Cancer* 2021;**68**(9):e29061.
- [25] Wilkie G, Sakr B, Rizack T. Medical marijuana use in oncology: A review. *JAMA Oncol* 2016;**2**(5):670–5.
- [26] Messinger D, Harris MK, Cummings JR, et al. Therapeutic targeting of prenatal pontine ID1 signaling in diffuse midline glioma. *Neuro Oncol* 2022.
- [27] Dal Bello S, Valdemarin F, Martinuzzi D, Filippi F, Gigli GL, Valente M. Ketogenic diet in the treatment of gliomas and glioblastomas. *Nutrients* 2022;**14**(18).
- [28] Perez A, van der Louw E, Nathan J, et al. Ketogenic diet treatment in diffuse intrinsic pontine glioma in children: Retrospective analysis of feasibility, safety, and survival data. *Cancer Rep (Hoboken)* 2021;**4**(5):e1383.
- [29] Kieran MW. Time to rethink the unthinkable: upfront biopsy of children with newly diagnosed diffuse intrinsic pontine glioma (DIPG). *Pediatr Blood Cancer* 2015;**62**(1):3–4.
- [30] Joud A, Stella I, Klein O. Diffuse infiltrative pontine glioma biopsy in children with neuronavigation, frameless procedure: A single center experience of 10 cases. *Neurochirurgie* 2020;**66**(5):345–8.
- [31] Wang ZJ, Rao L, Bhambhani K, et al. Diffuse intrinsic pontine glioma biopsy: a single institution experience. *Pediatr Blood Cancer* 2015;**62**(1):163–5.
- [32] Buczkowicz P, Hoeman C, Rakopoulos P, et al. Genomic analysis of diffuse intrinsic pontine gliomas identifies three molecular subgroups and recurrent activating ACVR1 mutations. *Nat Genet* 2014;**46**(5):451–6.
- [33] Grasso CS, Tang Y, Truffaux N, et al. Functionally defined therapeutic targets in diffuse intrinsic pontine glioma. *Nat Med* 2015;**21**(6):555–9.
- [34] Anderson JL, Muraleedharan R, Oatman N, et al. The transcription factor Olig2 is important for the biology of diffuse intrinsic pontine gliomas. *Neuro Oncol* 2017;**19**(8):1068–78.
- [35] Mueller S, Taitt JM, Villanueva-Meyer JE, et al. Mass cytometry detects H3.3K27M-specific vaccine responses in diffuse midline glioma. *J Clin Invest* 2022;**132**(12).
- [36] Miklja Z, Pasternak A, Stallard S, et al. Molecular profiling and targeted therapy in pediatric gliomas: review and consensus recommendations. *Neuro Oncol* 2019;**21**(8):968–80.
- [37] Puget S, Blauwblomme T, Grill J. Is biopsy safe in children with newly diagnosed diffuse intrinsic pontine glioma? *Am Soc Clin Oncol Educ Book* 2012:629–33.
- [38] Gupta N, Goumnerova LC, Manley P, et al. Prospective feasibility and safety assessment of surgical biopsy for patients with newly diagnosed diffuse intrinsic pontine glioma. *Neuro Oncol* 2018;**20**(11):1547–55.
- [39] Hamisch C, Kickingereder P, Fischer M, Simon T, Ruge MI. Update on the diagnostic value and safety of stereotactic biopsy for pediatric brainstem tumors: a systematic review and meta-analysis of 735 cases. *J Neurosurg Pediatr* 2017;**20**(3):261–8.
- [40] Lobon-Iglesias M-J, Santa-Maria Lopez V, Puerta Roldan P, et al. Tumor dissemination through surgical tracts in diffuse intrinsic pontine glioma. *J Neurosurg Pediatr* 2018;**22**(6):678–83.
- [41] Pfaff E, El Damaty A, Balasubramanian GP, et al. Brainstem biopsy in pediatric diffuse intrinsic pontine glioma in the era of precision medicine: the INFORM study experience. *Eur J Cancer* 2019;**114**:27–35.
- [42] Hersh DS, Kumar R, Moore KA, et al. Safety and efficacy of brainstem biopsy in children and young adults. *J Neurosurg Pediatr* 2020;**26**(5):552–62.
- [43] Fonseca A, Solano P, Ramaswamy V, et al. Ventricular size determination and management of ventriculomegaly and hydrocephalus in patients with diffuse intrinsic pontine glioma: an institutional experience. *J Neurosurg* 2021:1–7.
- [44] Bander ED, Tizi K, Wembacher-Schroeder E, et al. Deformational changes after convection-enhanced delivery in the pediatric brainstem. *Neurosurg Focus* 2020;**48**(1):E3.
- [45] Gelder CL, Hawkins C, Zapotocky M, Dirks P, Bartels U, Bouffet E. Diffuse intrinsic pontine glioma ventricular peritoneal shunt metastasis: a case report and literature review. *Childs Nerv Syst* 2019;**35**(5):861–4.
- [46] Kulkarni AV, Drake JM, Mallucci CL, et al. Endoscopic third ventriculostomy in the treatment of childhood hydrocephalus. *J Pediatr* 2009;**155**(2) 254-9.e1.
- [47] Guida L, Roux F-E, Massimino M, Marras CE, Sganzerla E, Giussani C. Safety and efficacy of Endoscopic Third Ventriculostomy in Diffuse Intrinsic Pontine Glioma related hydrocephalus: a Systematic Review. *World Neurosurg* 2018.
- [48] Majzner RG, Ramakrishna S, Yeom KW, et al. GD2-CAR T cell therapy for H3K27M-mutated diffuse midline gliomas. *Nature* 2022;**603**(7903):934–41.
- [49] Langmoen IA, Lundar T, Storm-Mathisen I, Lie SO, Hovind KH. Management of pediatric pontine gliomas. *Childs Nerv Syst* 1991;**7**(1):13–15.
- [50] Hargrave D, Bartels U, Bouffet E. Diffuse brainstem glioma in children: critical review of clinical trials. *Lancet Oncol* 2006;**7**(3):241–8.
- [51] Tinkle CL, Campbell K, Han Y, et al. Radiation dose response of neurologic symptoms during conformal radiotherapy for diffuse intrinsic pontine glioma. *J Neurooncol* 2020;**147**(1):195–203.
- [52] Zaghoul MS, Nasr A, Tolba M, et al. Hypofractionated radiation therapy for diffuse intrinsic pontine glioma: A noninferiority randomized study including 253 children. *Int J Radiat Oncol Biol Phys* 2022;**113**(2):360–8.
- [53] Janssens GORJ, Gidding CEM, Van Lindert EJ, et al. The role of hypofractionation radiotherapy for diffuse intrinsic brainstem glioma in children: a pilot study. *Int J Radiat Oncol Biol Phys* 2009;**73**(3):722–6.
- [54] Indelicato DJ, Flampouri S, Rotondo RL, et al. Incidence and dosimetric parameters of pediatric brainstem toxicity following proton therapy. *Acta Oncol* 2014;**53**(10):1298–304.
- [55] Gentile MS, Yeap BY, Paganetti H, et al. Brainstem injury in pediatric patients with posterior fossa tumors treated with proton beam therapy and associated dosimetric factors. *Int J Radiat Oncol Biol Phys* 2018;**100**(3):719–29.
- [56] Devine CA, Liu KX, Ioakeim-Ioannidou M, et al. Brainstem injury in pediatric patients receiving posterior fossa photon radiation. *Int J Radiat Oncol Biol Phys* 2019;**105**(5):1034–42.
- [57] Haas-Kogan D, Indelicato D, Paganetti H, et al. National cancer institute workshop on proton therapy for children: considerations regarding brainstem injury. *Int J Radiat Oncol Biol Phys* 2018;**101**(1):152–68.
- [58] McFadyen JG, Pelly N, Orr RJ. Sedation and anesthesia for the pediatric patient undergoing radiation therapy. *Curr Opin Anaesthesiol* 2011;**24**(4):433–8.
- [59] Anghelescu DL, Burgoyne LL, Liu W, et al. Safe anesthesia for radiotherapy in pediatric oncology: St. Jude Children's Research Hospital Experience, 2004-2006. *Int J Radiat Oncol Biol Phys* 2008;**71**(2):491–7.
- [60] Holt DE, Hiniker SM, Kalapurakal JA, et al. Improving the Pediatric Patient Experience During Radiation Therapy-A Children's Oncology Group Study. *Int J Radiat Oncol Biol Phys* 2021;**109**(2):505–14.
- [61] Carceller F, Fowkes LA, Khabra K, et al. Pseudoprogression in children, adolescents and young adults with non-brainstem high grade glioma and diffuse intrinsic pontine glioma. *J Neurooncol* 2016;**129**(1):109–21.

- [62] Liu AK, Macy ME, Foreman NK. Bevacizumab as therapy for radiation necrosis in four children with pontine gliomas. *Int J Radiat Oncol Biol Phys* 2009;**75**(4):1148–54.
- [63] Gallitto M, Lazarev S, Wasserman I, et al. Role of radiation therapy in the management of diffuse intrinsic pontine glioma: A systematic review. *Adv Radiat Oncol* 2019;**4**(3):520–31.
- [64] Amsbaugh MJ, Mahajan A, Thall PF, et al. A phase 1/2 trial of reirradiation for diffuse intrinsic pontine glioma. *Int J Radiat Oncol Biol Phys* 2019;**104**(1):144–8.
- [65] Lassaletta A, Strother D, Laperriere N, et al. Reirradiation in patients with diffuse intrinsic pontine gliomas: The Canadian experience. *Pediatr Blood Cancer* 2018;**65**(6):e26988.
- [66] Lu VM, Welby JP, Mahajan A, Laack NN, Daniels DJ. Reirradiation for diffuse intrinsic pontine glioma: a systematic review and meta-analysis. *Childs Nerv Syst* 2019;**35**(5):739–46.
- [67] Freeman CR, Kepner J, Kun LE, et al. A detrimental effect of a combined chemotherapy-radiotherapy approach in children with diffuse intrinsic brain stem gliomas? *Int J Radiat Oncol Biol Phys* 2000;**47**(3):561–4.
- [68] Massimino M, Spreafico F, Biassoni V, et al. Diffuse pontine gliomas in children: changing strategies, changing results? A mono-institutional 20-year experience. *J Neurooncol* 2008;**87**(3):355–61.
- [69] Cohen KJ, Heideman RL, Zhou T, et al. Temozolomide in the treatment of children with newly diagnosed diffuse intrinsic pontine gliomas: a report from the Children's Oncology Group. *Neuro Oncol* 2011;**13**(4):410–16.
- [70] Pruitt DW, Bolikal PD, Bolger AK. Rehabilitation considerations in pediatric brain tumors. *Curr Phys Med Rehabil Rep* 2019;**7**(2):81–8.
- [71] Sharma B, Allison D, Tucker P, Mabbott D, Timmons BW. Exercise trials in pediatric brain tumor: A systematic review of randomized studies. *J Pediatr Hematol Oncol* 2021;**43**(2):59–67.
- [72] Treadgold B, Kennedy C, Spoudeas H, Sugden E, Walker D, Bull K. Paediatric neuro-oncology rehabilitation in the UK: carer and provider perspectives. *bmjpo* 2019;**3**(1):e000567.
- [73] Vargo M. Brain tumor rehabilitation. *Am J Phys Med Rehabil* 2011;**90**(5 Suppl 1):S50–62.
- [74] Kilcommons A, Rawlinson D. Dysphagia and Long-Term Feeding Difficulties in the Pediatric Brain Tumor Population. *Perspect ASHA Spec Interest Groups* 2016;**1**(13):143–8.
- [75] Chaffee S. Cancer Pain Relief and Palliative Care in Children. *Cancer Pain Relief and Palliative Care in Children*. World Health Organization, 1998, 76 pp. (available in English; French and Spanish in preparation). US \$16.20; ISBN 922 4 1545127. *J Palliat Med* 1999;**2**(4):425–6.
- [76] Veldhuijzen van Zanten SEM, van Meerwijk CLLI, Jansen MHA, et al. Palliative and end-of-life care for children with diffuse intrinsic pontine glioma: results from a London cohort study and international survey. *Neuro Oncol* 2016;**18**(4):582–8.
- [77] Kreicbergs U, Valdimarsdóttir U, Onelöv E, Henter J-I, Steineck G. Talking about death with children who have severe malignant disease. *N Engl J Med* 2004;**351**(12):1175–86.
- [78] Collins A, Lethborg C, Brand C, et al. The challenges and suffering of caring for people with primary malignant glioma: qualitative perspectives on improving current supportive and palliative care practices. *BMJ Support Palliat Care* 2014;**4**(1):68–76.
- [79] Byrne A, Torrens-Burton A, Sivell S, et al. Early palliative interventions for improving outcomes in people with a primary malignant brain tumour and their carers. *Cochrane Database Syst Rev* 2022;**1**:CD013440.
- [80] Ferrell BR, Temel JS, Temin S, Smith TJ. Integration of palliative care into standard oncology care: ASCO clinical practice guideline update summary. *J Oncol Pract* 2017;**13**(2):119–21.