

Single Case

# A 28-Year-Old Male Patient with Nail Tumors, Skin Lesions, and Epilepsy

Deepak M.W. Balak<sup>a, b</sup> Bernard A. Zonnenberg<sup>c</sup> Juliette M.J. Spitzer-Naaijken<sup>d</sup> Mieke M. Hulshof<sup>a</sup>

<sup>a</sup>Department of Dermatology, Reinier de Graaf Gasthuis, Delft, The Netherlands;

<sup>b</sup>Department of Dermatology, Erasmus University Medical Center, Rotterdam, The

Netherlands; <sup>c</sup>Department of Internal Medicine, University Medical Center Utrecht,

Utrecht, The Netherlands; <sup>d</sup>Department of Pathology, Reinier de Graaf Gasthuis, Delft, The Netherlands

## Keywords

Tuberous sclerosis complex · Ungual fibroma · Shagreen patch · Angiofibromas · Topical rapamycin

## Abstract

**Background:** Tuberous sclerosis complex (TSC) is an autosomal dominant disorder characterized by the development of benign hamartomas in multiple organs. Most patients with TSC exhibit cutaneous manifestations. **Methods:** We report a 28-year-old patient with multiple pink papules at the proximal nail fold of several toes. **Results:** Histopathological analysis of a biopsy of a papule was consistent with an unguinal fibroma. Histopathological analysis of a biopsy of an elevated skin-colored plaque at the lower back was diagnostic for a Shagreen patch. These findings were consistent with a clinical diagnosis of TSC. This patient was subsequently referred to a multidisciplinary TSC clinic for further screening, which revealed a giant cell astrocytoma and multiple subependymal tubers. Annual monitoring was recom-

mended. The skin lesions were treated with topical rapamycin ointment. **Conclusions:** Recognizing dermatological manifestations of TSC is of importance to allow early diagnosis. TSC should be considered as a differential diagnosis in the case of unguis fibromas, even in older patients.

© 2017 The Author(s)  
Published by S. Karger AG, Basel

## Introduction

Tuberous sclerosis complex (TSC) is an autosomal dominant genetic disorder caused by mutations in the TSC1 or TSC2 gene [1]. The incidence of TSC is estimated at 1 case per 6,000 births [2]. TSC is characterized by the development of benign hamartomas that can occur in multiple organs, including the brain, heart, lungs, kidneys, and skin [3]. Furthermore, TSC can be associated with neurological manifestations such as epilepsy and learning disabilities [4]. Both the spectrum and severity of clinical manifestations of TSC are variable. Several manifestations of TSC have an age-dependent onset of expression [5]. As a result, clinical evaluation for TSC can be difficult. Early diagnosis of TSC is of importance, considering that TSC is associated with increased morbidity and mortality [6]. In addition, there is an increased risk of malignancy in TSC, primarily in the kidneys, brain, and soft tissues [7].

TSC can be diagnosed through genetic identification of a pathological mutation or by means of clinical features. In 2012, the diagnostic criteria for TSC were revised and categorized into major and minor features (see Table 1) [3]. A definite diagnosis of TSC can be made in the case of 2 major features or 1 major feature with 2 or more minor features. Positivity of 1 major feature alone or 2 or more minor features is indicative of a possible diagnosis of TSC.

Cutaneous manifestations are common in TSC [8]. In fact, 4 out of 11 major TSC criteria and 3 out of 6 minor criteria comprise dermatological features. The majority of patients with TSC have 1 or more TSC-related skin lesions [9]. Several dermatological features of TSC often present early – within the first months after birth (see Table 2) [10]. Recognizing dermatological manifestations of TSC is therefore of importance to allow early diagnosis [8]. Here, we report a case of TSC in which the suspicion of a diagnosis of TSC was based on dermatological findings.

## Report

A 28-year-old male patient was referred to our dermatology outpatient clinic for evaluation of nail lesions. He had growths at the proximal nail fold of several of his toes that were present for 2 years. Prior treatment with miconazole cream was unsuccessful in clearing the nail lesions. His medical history was significant for asthma, for which he used salbutamol and salmeterol/fluticasone inhalation. Furthermore, at the age of 1 year he was diagnosed with epilepsy. There was no family history of dermatological or genetic disorders.

At clinical examination, multiple pink-colored pedunculated papules at the lateral basis of the proximal nail fold of digit 1 and 4 of his left foot were noted (see Fig. 1). Further, total body skin inspection revealed multiple hypopigmented maculae at the trunk and a slightly

elevated skin-colored plaque at the lower back. At the malar region of the face, several red papules were seen.

Histopathological analysis of a skin biopsy obtained from a papule at the proximal nail fold showed hyperkeratosis of the epidermis and thick collagen bundles together with dilated vessels in the dermis. These findings were consistent with a diagnosis of unguis fibroma, also known as a Koenen tumor (see Fig. 1). Histopathological analysis of a skin biopsy of the plaque at the lower trunk showed thickened bundles of collagen within the dermis with widely spaced, diminished, and fragmented elastic fibers, consistent with a collagenoma (see Fig. 2). Based on clinicopathological correlation, a diagnosis of Shagreen patch was made.

Taken together, these findings were consistent with a clinical diagnosis of TSC. This patient was subsequently referred to a specialized TSC clinic for adult patients at the University Medical Center Utrecht (Utrecht, The Netherlands) for further screening and management. MRI of the cerebrum showed a giant cell astrocytoma and multiple subependymal tubers. MRI of the kidneys showed multiple small cysts; there were no angiomyolipomas. CT of the thorax revealed lipomas in the cardiac ventricle wall. Ophthalmic evaluation was without abnormalities.

Given the abnormalities in the cerebrum, yearly follow-up was advised. The skin and nail lesions were treated with topical rapamycin (sirolimus) 0.01% ointment, which is a mammalian target of rapamycin (mTOR) inhibitor.

## Discussion

TSC is a genetic multi-organ disease with a highly variable disease expression. Here, we report a case of a 28-year-old male patient with a medical history of epilepsy in which the diagnosis of TSC was determined clinically on the presence of unguis fibromas and a Shagreen patch.

This report has several learning points. First, this case is an example of an age-related expression of the clinical manifestations of TSC. The unguis fibromas, which in this case were the presenting sign for the diagnosis of TSC, had an onset at age 26 years. This is in line with previous findings that unguis fibromas present during adolescence (see Table 2) [9, 11]. Therefore, a possible diagnosis of TSC should be considered when patients present with skin lesions suggestive for TSC, even at an older age. Second, TSC should be considered as a differential diagnosis in the case of unguis fibromas, especially with a medical history of neurological symptoms such as epilepsy. Third, full body skin examination including the nails and oral cavity is of importance when a diagnosis of TSC is suspected in order to assess other potential TSC-related cutaneous manifestations [10]. Fourth, *de novo* mutations, like in this case, occur in about 80% of TSC patients [12]. Therefore, in most cases there is no family history of TSC.

Given the potential multi-organ manifestations of TSC, the management and follow-up of TSC requires a multidisciplinary approach. We referred our patient to a specialized TSC clinic for adult patients. There, annual follow-up will be performed according to current recommendations [13].

Treatment with sirolimus ointment, a topical mTOR inhibitor, was initiated to treat the cutaneous lesions. To date, only case series are available on the use of topical sirolimus for

TSC-related skin lesions [14, 15]. In randomized, placebo-controlled trials with oral everolimus, an mTOR inhibitor, positive effects were noted on the clearance of skin lesions [16]. Other treatment options for cutaneous TSC lesions include surgery and laser therapy [8].

In conclusion, cutaneous features are common in TSC and may be a presenting sign for the diagnosis. Recognizing dermatological manifestations of TSC is of importance to allow early diagnosis.

### Statement of Ethics

Informed consent for publishing this case was obtained from the patient.

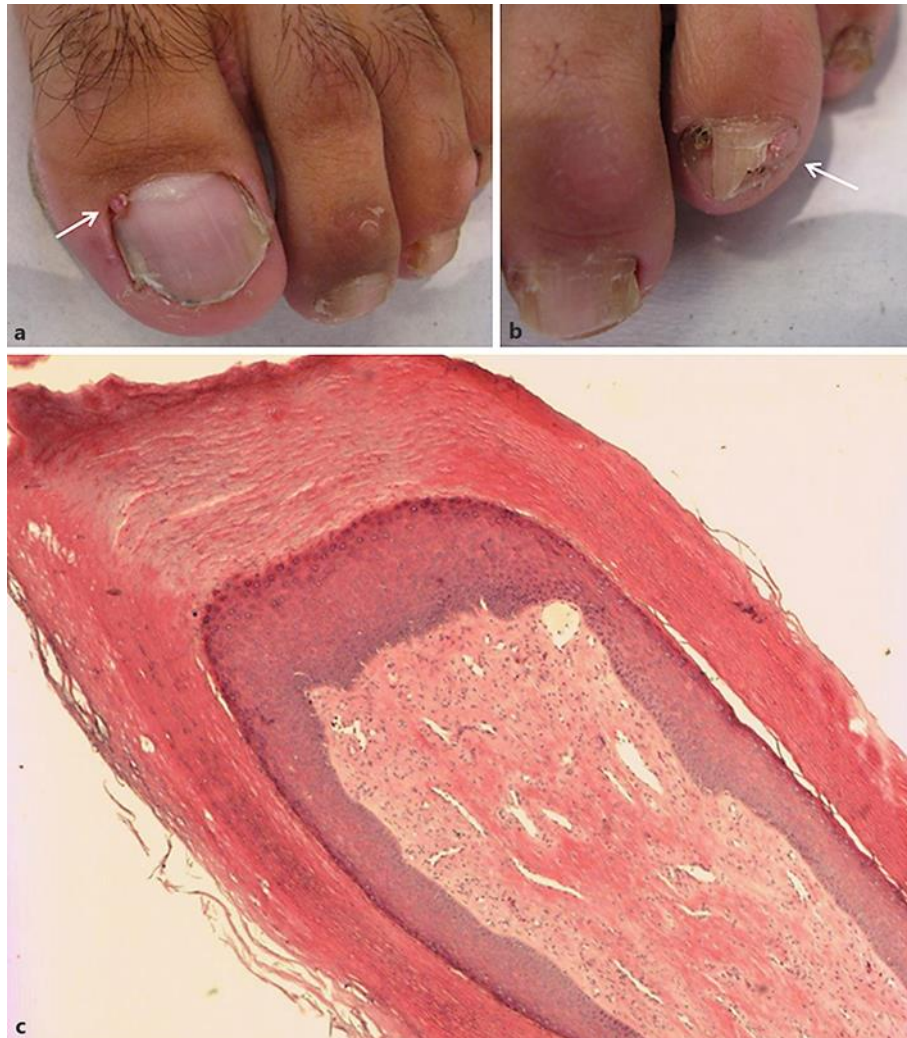### Disclosure Statement

There are no conflicts of interest. There are no funding sources for this work.

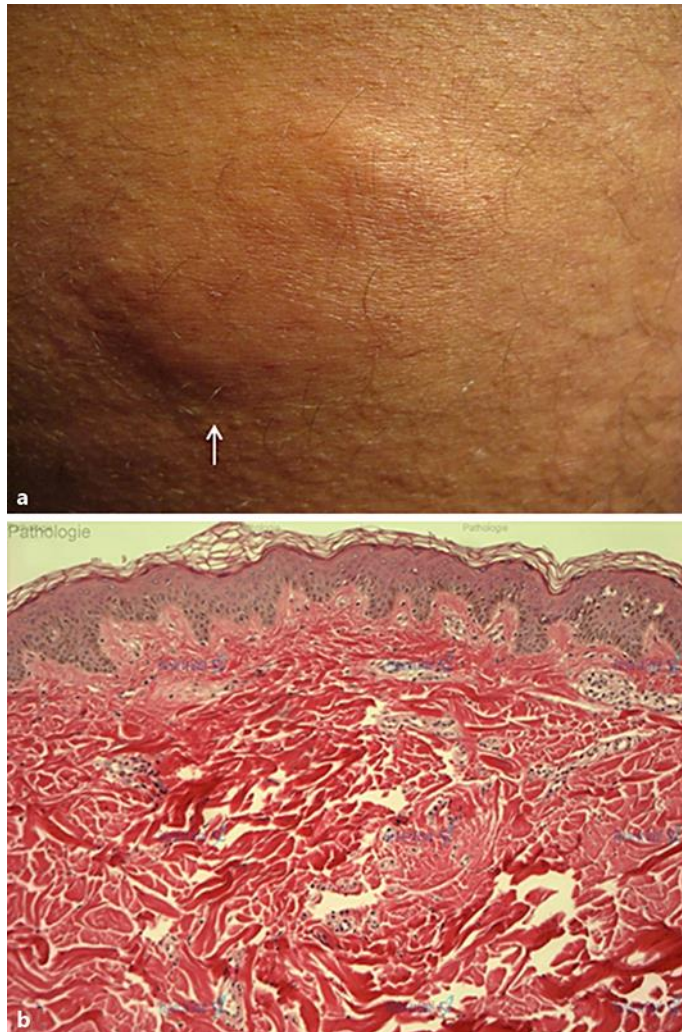
### References

- 1 Curatolo P, Bombardieri R, Jozwiak S: Tuberous sclerosis. *Lancet* 2008;372:657–668.
- 2 Osborne JP, Fryer A, Webb D: Epidemiology of tuberous sclerosis. *Ann NY Acad Sci* 1991;615:125–127.
- 3 Northrup H, Krueger DA; International Tuberous Sclerosis Complex Consensus Group: Tuberous sclerosis complex diagnostic criteria update: recommendations of the 2012 International Tuberous Sclerosis Complex Consensus Conference. *Pediatr Neurol* 2013;49:243–254.
- 4 Curatolo P, Moavero R, de Vries PJ: Neurological and neuropsychiatric aspects of tuberous sclerosis complex. *Lancet Neurol* 2015;14:733–745.
- 5 Crino PB, Nathanson KL, Henske EP: The tuberous sclerosis complex. *N Engl J Med* 2006;355:1345–1356.
- 6 Eijkemans MJ, van der Wal W, Reijnders LJ, Roes KC, van Waalwijk van Doorn-Khosrovani SB, Pelletier C, Magestro M, Zonnenberg B: Long-term follow-up assessing renal angiomyolipoma treatment patterns, morbidity, and mortality: an observational study in tuberous sclerosis complex patients in the Netherlands. *Am J Kidney Dis* 2015;66:638–645.
- 7 Owens J: BJTscG, clinical features, and diagnosis; in UpToDate, Post TW (ed): UpToDate, Waltham, MA (accessed April 15, 2016).
- 8 Teng JM, Cowen EW, Wataya-Kaneda M, Gosnell ES, Witman PM, Hebert AA, Mlynarczyk G, Soltani K, Darling TN: Dermatologic and dental aspects of the 2012 International Tuberous Sclerosis Complex Consensus Statements. *JAMA Dermatol* 2014;150:1095–1101.
- 9 Webb DW, Clarke A, Fryer A, Osborne JP: The cutaneous features of tuberous sclerosis: a population study. *Br J Dermatol* 1996;135:1–5.
- 10 Jacks SK, Witman PM: Tuberous sclerosis complex: an update for dermatologists. *Pediatr Dermatol* 2015;32:563–570.
- 11 Ma D, Darling T, Moss J, Lee CC: Histologic variants of periungual fibromas in tuberous sclerosis complex. *J Am Acad Dermatol* 2011;64:442–444.
- 12 Au KS, Williams AT, Roach ES, Batchelor L, Sparagana SP, Delgado MR, Wheless JW, Baumgartner JE, Roa BB, Wilson CM, Smith-Knuppel TK, Cheung MY, Whittemore VH, King TM, Northrup H: Genotype/phenotype correlation in 325 individuals referred for a diagnosis of tuberous sclerosis complex in the United States. *Genet Med* 2007;9:88–100.
- 13 Krueger DA, Northrup H; International Tuberous Sclerosis Complex Consensus Group: Tuberous sclerosis complex surveillance and management: recommendations of the 2012 International Tuberous Sclerosis Complex Consensus Conference. *Pediatr Neurol* 2013;49:255–265.

- 14 Vasani RJ: Facial angiofibromas of tuberous sclerosis treated with topical sirolimus in an Indian patient. *Indian J Dermatol* 2015;60:165–169.
- 15 Pynn EV, Collins J, Hunasehally PR, Hughes J: Successful topical rapamycin treatment for facial angiofibromata in two children. *Pediatr Dermatol* 2015;32:e120–e123.
- 16 Bissler JJ, Kingswood JC, Radzikowska E, Zonnenberg BA, Frost M, Belousova E, Sauter M, Nonomura N, Brakemeier S, de Vries PJ, Whittemore VH, Chen D, Sahmoud T, Shah G, Lincy J, Lebwohl D, Budde K: Everolimus for angiomyolipoma associated with tuberous sclerosis complex or sporadic lymphangioleiomyomatosis (EXIST-2): a multicentre, randomised, double-blind, placebo-controlled trial. *Lancet* 2013;381:817–824.



**Fig. 1.** a, b Clinical photographs of unguis fibromas (arrows). c Histopathological analysis of a skin biopsy obtained from a papule at the proximal nail fold, consistent with an unguis fibroma.



**Fig. 2.** **a** Clinical photograph of a Shagreen patch (arrow). **b** Histopathological analysis of a skin biopsy obtained from a plaque at the lower trunk, consistent with a Shagreen patch.

**Table 1.** Revised clinical diagnostic criteria for TSC, according to the 2012 International Tuberous Sclerosis Complex Consensus Conference [3]

*Major criteria*

Hypomelanotic macules ( $\geq 3$ , at least 5-mm diameter)  
 Angiofibromas ( $\geq 3$ ) or fibrous cephalic plaque  
 Ungual fibromas ( $\geq 2$ )  
 Shagreen patch  
 Multiple retinal hamartomas  
 Cortical dysplasias  
 Subependymal nodules  
 Subependymal giant cell astrocytoma  
 Cardiac rhabdomyoma  
 Lymphangiomyomatosis  
 Angiomyolipomas

*Minor criteria*

“Confetti” skin lesions  
 Dental enamel pits ( $>3$ )  
 Intraoral fibromas ( $\geq 2$ )  
 Retinal achromic patch  
 Multiple renal cysts  
 Nonrenal hamartomas

**Table 2.** Dermatological manifestations of TSC

Feature	Prevalence	Age at onset
Hypomelanotic macules	Up to 90%	0 years
Angiofibromas	75%	2–5 years
Ungual fibromas	20–80%	20–30 years
Shagreen patch	50%	0–10 years
“Confetti” skin lesions	Up to 60%	0–10 years