

ORIGINAL ARTICLE

Improved healing of chronic diabetic foot wounds in a prospective randomised controlled multi-centre clinical trial with a microvascular tissue allograft

Lisa J. Gould¹  | Dennis P. Orgill² | David G. Armstrong³ |
Robert D. Galiano⁴ | Paul M. Glat⁵ | Charles M. Zelen²  |
Lawrence A. DiDomenico⁶ | Marissa J. Carter⁷ | William W. Li⁸

¹South Shore Hospital, Weymouth, Massachusetts, USA

²Professional Education and Research Institute, Roanoke, Virginia, USA

³USC Keck School of Medicine, Los Angeles, California, USA

⁴Northwestern Medicine, Chicago, Illinois, USA

⁵Drexel University, Philadelphia, Pennsylvania, USA

⁶Ankle & Foot Care Centers, Youngstown, Ohio, USA

⁷Strategic Solutions, Inc., Bozeman, Montana, USA

⁸The Angiogenesis Foundation, Cambridge, Massachusetts, USA

Correspondence

Lisa J. Gould, 90 Libbey Parkway, Weymouth, MA 02189, USA.
Email: lgould44@hotmail.com

Funding information

MicroVascular Tissues, Inc.

Abstract

This study assesses the impact of a processed microvascular tissue (PMVT) allograft on wound closure and healing in a prospective, single-blinded, multi-centre, randomised controlled clinical trial of 100 subjects with Wagner Grade 1 and 2 chronic neuropathic diabetic foot ulcerations. In addition to standard wound care, including standardised offloading, the treatment arm received PMVT while the control arm received a collagen alginate dressing. The primary endpoint was complete wound closure at 12 weeks. Secondary endpoints assessed on all subjects were percent wound area reduction, time to healing, and local neuropathy. Novel exploratory sub-studies were conducted for wound area perfusion and changes in regional neuropathy. Weekly application of PMVT resulted in increased complete wound closure at 12 weeks (74% vs 38%; $P = .0003$), greater percent wound area reduction from weeks four through 12 (76% vs 24%; $P = .009$), decreased time to healing (54 days vs 64 days; $P = .009$), and improved local neuropathy (118% vs 11%; $P = .028$) compared with the control arm. Enhanced perfusion and improved regional neuropathy were demonstrated in the sub-studies. In conclusion, this study demonstrated increased complete healing with PMVT and supports its use in treating non-healing DFUs. The observed benefit of PMVT on the exploratory regional neuropathy and perfusion endpoints warrants further study.

KEYWORDS

angiogenesis, diabetic foot ulcer, microvasculature/microvascular tissue, peripheral neuropathy, wound healing

Key Messages

- PMVT, a novel microvascular tissue allograft, aims to directly address the compromised microvasculature found in chronic wounds

This is an open access article under the terms of the Creative Commons Attribution-NonCommercial-NoDerivs License, which permits use and distribution in any medium, provided the original work is properly cited, the use is non-commercial and no modifications or adaptations are made.

© 2021 The Authors. *International Wound Journal* published by Medicalhelplines.com Inc (3M) and John Wiley & Sons Ltd.

- this manuscript details the design and results of the HIFLO Trial, a prospective, single-blinded, multi-centre, randomised controlled clinical trial of PMVT conducted on 100 subjects with Wagner Grade 1 and 2 chronic neuropathic DFUs
- weekly application of PMVT resulted in significantly increased complete wound closure at 12 weeks, greater percent wound area reduction, decreased time to healing, and improved local neuropathy compared with the control arm
- exploratory results suggest that increased wound site perfusion and reduction of regional neuropathy accompany wound resolution accelerated by PMVT
- these findings support the utility of microvascular tissue intended to restore a functional microcirculation as a new approach to treating chronic DFUs

1 | INTRODUCTION

The economic burden of diabetic foot ulcers (DFUs) totals over \$60 billion U.S. dollars annually.¹⁻⁵ As a complication of non-healing or infected diabetes-related wounds, three lower extremity amputations occur every minute worldwide.⁶ Despite availability of advanced wound therapeutics, the 5-year mortality after amputation from a DFU remains over 45%.⁷ Given that roughly 40% of patients with a DFU have a wound recurrence within 1 year after ulcer healing, and 65% within 5 years, critical focus is needed on achieving wound closure as well as wound remission without recurrence.¹ Prior history of a diabetic foot ulceration is the single greatest predictor of recurrent DFUs in the context of peripheral neuropathy, bony prominences, repetitive microtrauma, and reduced tensile strength in the scarred tissue.^{1,8,9} Non-surgical and surgical methods have been used to reduce risk, although long-term outcomes of non-surgical methods are not encouraging as they depend on patient engagement with routine foot care and shoe gear use.¹⁰⁻¹³ Surgical interventions to improve sensation, reduce offending bony deformities and improve biomechanics may be beneficial; however, the data supporting long-term outcomes is limited.

Microvascular dysfunction and peripheral neuropathy are two of the most common complications of diabetes mellitus, leading to ulceration. Hyperglycaemia itself leads to vascular changes including endothelial dysfunction, hyperpermeability, decreased blood flow, and tissue hypoxia. Vascular defects involving the vasa nervorum contribute to diabetic neuropathy,¹⁴⁻¹⁹ which causes the insensate foot and undetected injury.^{1,20-22} Restoring the microvasculature in the non-healing diabetic wound environment is essential for complete healing. The microvasculature is composed of small blood vessels (arterioles, capillaries, and venules), extracellular matrix proteins

that form the basement membrane and vessel structure and serve as a reservoir for modulation of cellular activity, and inherent cells (multipotent cells, endothelial cells, pericytes, fibroblasts, and smooth muscle cells).^{23,24} A healthy microvascular tissue structure provides nutrient and oxygen delivery and removal of waste metabolites, which is critical for tissue function and survival.²³⁻²⁵ Formation of a new vascular and neural network following skin and soft tissue injury is critical for wound resolution beneath complete epithelialisation of the skin defect. New capillaries can sprout from the pre-existing vasculature at the time of injury and organise into functional vascular networks, so microvessel elements have been hypothesised to have the ability to promote angiogenesis and vascular repair as well as orchestrate signals of the wound healing cascade.²³⁻²⁹ This capability has been shown in laboratory studies demonstrating high endothelial proliferation rates and pro-angiogenic effects of microvascular tissue fragments derived from allogeneic cell and tissue sources.²⁸⁻³⁰

Processed microvascular tissue (PMVT) is a microvascular tissue structural allograft (mVASC[®], MicroVascular Tissues, Inc. [MVT], San Diego, CA) comprised of structural elements (small blood vessels and extracellular matrix), inherent non-viable cells, and associated biological signalling factors harvested from the subcutaneous tissue of the thighs, abdomen, and buttocks of cadaveric human donors. PMVT is isolated through a proprietary process that involves cutting, cleaning, extraction, lyophilisation, and sterilisation of the harvested tissue. Characterisation of PMVT confirmed that structural and biologic factors intrinsic to microvascular tissue, including angiogenic and neurotrophic factors, are preserved.³⁰ Preclinical studies of PMVT demonstrated induction of angiogenesis and significantly increased healing rates in rodent models of pressure injury and ischaemia.^{30,31} In an SCID mouse model of hindlimb ischaemia, mean

perfusion rates increased from 35% to 82% at Day 14 with the PMVT allograft treatment compared with an increase from 31% to 59% for the control.³⁰ Initial clinical applications of PMVT as a topical intervention in complex, recalcitrant, or senescent wounds of other aetiologies have demonstrated its ability to stimulate durable wound closure out to 9 months, even in cases where other advanced biologic therapies had failed.^{30,32,33}

In a small case series of patients with DFUs that had failed to heal with previous advanced wound care treatment, weekly application of PMVT allograft resulted in wound closure, improved wound perfusion, and improved lower extremity peripheral sensation.³² This provided the basis for the treatment regimen and analytic techniques used in the randomised controlled trial presented here. The purpose of this clinical study, named the HIFLO (Healing in Diabetic Foot Ulcers with Microvascular Tissue) Trial, was to evaluate the hypothesis that this PMVT allograft would improve wound healing and quality of tissue repair in non-healing DFUs compared with a control arm using a typical collagen alginate (CCA) dressing.

2 | MATERIALS AND METHODS

2.1 | Clinical study design and materials

The HIFLO Trial was an IRB-approved prospective, single-blinded, multi-centre, randomised controlled clinical trial evaluating patient outcomes after weekly application of PMVT allograft in addition to a standardised diabetic foot ulcer protocol in the treatment of 100 patients with Wagner Grade 1 and 2 DFUs of ≥ 4 weeks duration, compared with standard wound care with a typical CCA dressing control (ISRCTN #24783859, Western IRB study #1175398 protocol #20171089, and South Shore reference #17-013). The study was conducted at six clinical sites within the United States in accordance with Good Clinical Practice (GCP) requirements. Subjects were eligible for study inclusion if they met all inclusion and exclusion criteria (Table 1). A 14-day run-in period was used to validate the non-healing nature of each subject's index wound, during which all screened subjects received standard wound treatments including wound cleansing, focal debridement, primary collagen calcium alginate dressing (Fibracol™ Plus Collagen Wound Dressing with Alginate, Acelity, St. Paul, MN), secondary three-layer dressing (DYNA-FLEX Multi-Layer Compression System, Acelity, St. Paul, MN) with felt padding, and offloading of the foot. Subjects with $< 20\%$ reduction in wound area after this run-in period were deemed eligible for study inclusion. A sealed

TABLE 1 Inclusion and exclusion criteria for HIFLO trial enrolment

Inclusion criteria
<ul style="list-style-type: none"> Males and females ≥ 18 y of age
<ul style="list-style-type: none"> Wound duration > 4 and < 52 wk
<ul style="list-style-type: none"> Wound size > 0.75 and < 25 cm²
<ul style="list-style-type: none"> Adequate circulation to the affected foot as demonstrated by a dorsal transcutaneous oxygen measurement (TCOM) or a skin perfusion pressure (SPP) measurement of ≥ 30 mmHg or an ankle brachial index (ABI) between 0.7 and 1.3, biphasic dorsalis and posterior tibial vessels on arterial Doppler ultrasound toe brachial index (TBI) > 0.6 within three months prior to study enrollment
Exclusion criteria
<ul style="list-style-type: none"> Osteomyelitis or bone infection of the affected foot as verified by X-ray within 30 d prior to randomization
<ul style="list-style-type: none"> HbA1c > 12.0 within last 90 d of randomization.
<ul style="list-style-type: none"> Index ulcer has been previously treated or will need to be treated with any of the following therapies during the study period: <ul style="list-style-type: none"> Cellular and/or tissue-based products or wound dressings that include growth factors Revascularization surgery Radiation therapy to the foot Topical antibiotics or other topical antimicrobial therapies, including silver, honey, hydrofera blue, etc. Negative pressure wound therapy Hyperbaric oxygen therapy Non-invasive topical therapies (heat lamps, UV lights, whirlpool baths, hydrosurgical debridement, wound cleansers other than sterile water or sterile sale)
<ul style="list-style-type: none"> Subject with end stage renal disease as evidenced by a serum creatinine > 3.0mg/dL within last 120 d of Randomization.
<ul style="list-style-type: none"> History of more than 2 wk treatment with immune-suppressants (including systemic corticosteroids > 10 mg daily dose), cytotoxic chemotherapy, or application of topical steroids to the ulcer surface within 1 mo prior to study enrollment or required during study enrollment
<ul style="list-style-type: none"> Investigational drug(s) or therapeutic device(s) use within one month prior to study enrollment
<ul style="list-style-type: none"> Use of a selective COX-2 inhibitor
<ul style="list-style-type: none"> History of radiation at the ulcer site

envelope technique, in which the envelopes contained a random allocation sequence, was used to perform a 1:1 randomisation of eligible subjects to the control arm or PMVT. Randomisation was performed in 10-subject blocks to achieve balanced assignment of treatments, and clinical investigators were only informed of the randomisation assignment at the time of each individual patient's initial treatment visit. No changes were made with

respect to study methods or eligibility criteria after commencement of the trial.

PMVT is a structural allograft consisting of microvascular tissue fragments harvested from eligible non-diabetic donors younger than 65 years in age who have undergone donor screening and testing in accordance with US Food and Drug Administration (US FDA) regulations and American Association of Tissue Banks[®] (AATB) standards in order to assure safety and quality. Each ready-to-use vial of PMVT contains a sterilised, lyophilised disk with at least 500 000 microvascular tissue fragments, and is stable at room temperature for up to 5 years. In accordance with US FDA human cellular and tissue-based product (HCT/P) regulations, the PMVT allograft is indicated for the repair, reconstruction, replacement, or supplementation of microvascular tissue.

2.2 | Treatment and application

All subjects were seen on a weekly basis and underwent cleansing of the index DFU with either sterile saline or water and sharp debridement of the index ulcer with a scalpel and/or curette when indicated. All subjects received the same secondary three-layer dressing with felt padding. The only difference between the two groups was the primary dressing: a collagen calcium alginate dressing was applied weekly to the index ulcer in the control group versus weekly PMVT allograft covered with a non-adherent dressing (Adaptic Touch[™], Acclivity, St. Paul, MN). Offloading, which can be one of the biggest confounding variables in the outcome of clinical trials in DFUs, was standardised across all study sites and subjects, and was achieved using a DARCO diabetic cam boot with a tri-laminar insert (DARCO International, Inc., Huntington, WV) or equivalent. The quantity of PMVT allograft applied to the ulcer was based on the wound surface area, with application of one-half disk of PMVT for every 1.5 cm² of wound area.

2.3 | Assessments

Weekly assessments for all subjects included wound and local peripheral neuropathy assessment. Wound measurement assessment was performed using the eKare InSight[®] System (eKare Inc., Fairfax, VA), a 3D digital infrared imaging technology connected to an iPad tablet to scan the wound topography and accurately capture wound images. Calibrated software then translates the wound image into an accurate measurement of

the wound area. In addition, for the purposes of blinded adjudication of the closed wounds, high resolution photographs were taken at each visit using identical Sony 20.1 Megapixel cameras at each site.

Local peripheral neuropathy was assessed with the standard 10-point Semmes-Weinstein monofilament (SWM) exam using a 5.07 gauge/10 g target force monofilament pressed against the predefined 10 areas of the patient's foot.^{34,35} For exploratory evaluation of regional peripheral neuropathy, a technique mapping the stocking glove pattern of neuropathy³⁶ was conducted on the first consecutive²¹ patients (PMVT = 11; control = 10) at two pre-selected study sites. This technique used the same monofilament to mark the boundary of sensation on the lower extremity at multiple treatment visits. This boundary was outlined with a permanent marking pen and photographs of the lateral leg and plantar foot were taken, and changes to the neuropathy area over time were recorded. Digital contour tracing from the boundary of sensation to the base of the foot allowed the three-dimensional area of neuropathy to be calculated using ImageJ image analysis software. In both SWM and stocking glove assessments, subjects were prevented from visually observing the monofilament being pressed against their foot and lower limb.

For an evaluation of tissue perfusion, the first¹⁰ consecutive subjects (PMVT = 5; control = 5) at one study site also underwent microcirculation analysis at the baseline visit, at 1 week, and at wound resolution or end of the study period, whichever occurred first. Microcirculation assessment was performed using indocyanine green fluorescence microangiography (ICGFA) using the LUNA device (Stryker Corp., Kalamazoo, MI), which provides real-time visualisation and objective assessment of tissue perfusion to a specific area of concern.³⁷ Average ingress rate was measured at the centre of the wound bed and in the wound periphery, no more than 1 cm from the wound margin, at the 1, 4, 7, and 10 O'clock positions using the maximum observed ICG intensity as the injection was monitored in real time. Dynamic image capture from dye ingress to egress and measurements taken within this period were performed in the same fashion for each imaging sequence to allow for serial analysis. Blinded evaluation of ICGFA video and images were performed by three independent clinicians from different institutions with expertise using the LUNA system for tissue perfusion in DFUs.

2.4 | Study endpoints

The primary endpoint of the study was complete wound closure at 12 weeks. FDA guidance defines complete

wound closure as a wound that has reepithelialised without drainage or dressing requirements confirmed at two consecutive study visits 2 weeks apart. We expanded upon the US FDA guidance³⁸ by using a recently proposed standard definition that includes four criteria for complete closure: (a) 100% epithelialisation, (b) normal coloration with no marginal recurrence, (c) complete absence of exudate, and (d) no clinical signs of infection.³⁹ The investigator and a physician blinded to the subject's care made the initial determination of wound closure, followed by adjudication and confirmation of closure by a panel of three independent blinded plastic surgeons with >10 years of experience in wound care. In order to avoid the introduction of bias, the adjudicators only saw blinded images of the "closed" wound and evaluated them based on the four criteria. If an image was unclear, adjudicators could request additional images because several were taken at each visit. Wound closure was documented 2 weeks after adjudication at the healing confirmation visit. Secondary endpoints included the percent wound area reduction (PAR) at 4, 6, 8, and 12 weeks, time to healing, and local neuropathy. Exploratory endpoints were changes in wound perfusion and regional peripheral neuropathy.

2.5 | Statistical analysis

Continuous data were described at baseline and follow-up using descriptive statistics (mean, SD, median, minimum, and maximum), while categorical variables were characterised as counts and proportions or percentages. The intent-to-treat (ITT) population included all subjects who attended at least one treatment visit. All analyses were performed on the ITT population only.⁴⁰ Subjects who were lost to follow-up were included in the ITT analysis of primary and secondary endpoints using last observation carried forward (LOCF) principles to impute missing data.⁴¹ The study was designed to detect a difference of 0.3 between control and PMVT (proportions healed 0.4 and 0.7, respectively) with 50 subjects in each group and a statistical power of 88% (Pass 13 software). A chi-square test was performed to determine if there was a statistically significant difference in the proportion of wounds healed at 12 weeks between control and PMVT (unadjusted analysis). Logistic regression was used to adjust for available variables likely to affect wound healing. Kaplan-Meier analysis was used to determine the time to healing for both groups within 12 weeks. PAR between treatment groups at 4, 6, 8, and 12 weeks was statistically tested using general linear mixed modelling (GLMM), which is a repeated measures (PAR value at each week) version of general linear modelling. A *P* value

of .05 was considered statistically significant. Statistical analysis was performed using PASW 27. The Hochberg step-up procedure was used for simultaneous adjustment of all secondary endpoints in regard to multiplicity of statistical testing.

3 | RESULTS

3.1 | Study demographics

A total of 127 subjects were enrolled at six study sites. Twenty-seven subjects failed to meet inclusion and exclusion criteria, leaving 100 subjects for randomisation (*n* = 50, control arm; *n* = 50 PMVT arm). Of these 100

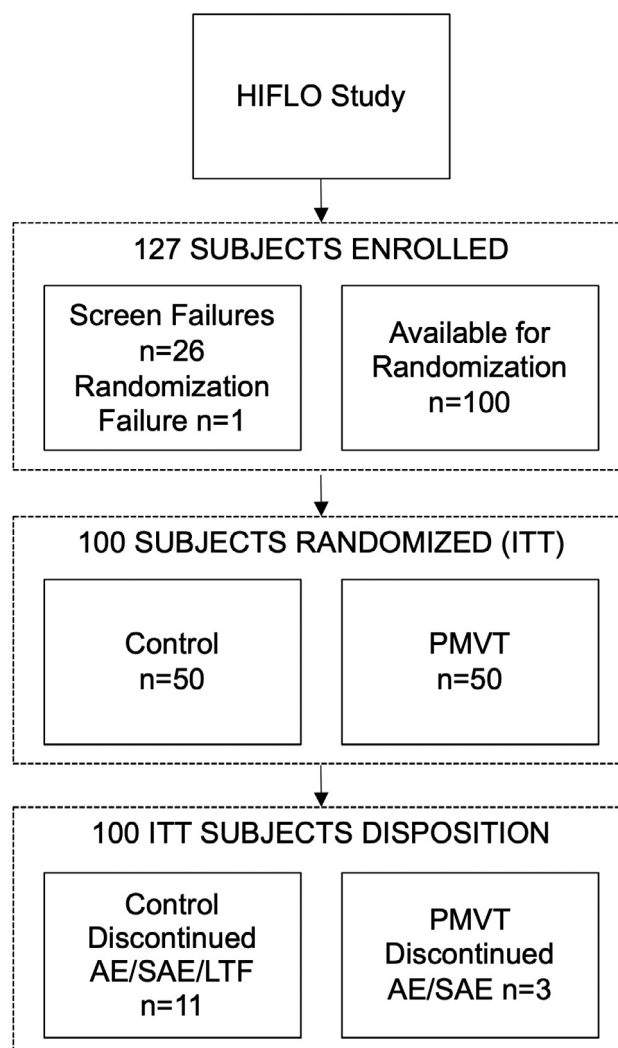


FIGURE 1 HIFLO Trial subject disposition. Flow chart depicting the disposition of the 127 subjects initially enrolled in the HIFLO Trial, conducted at 6 clinical study sites. Reasons for screen failure included suspected cancer, infection or osteomyelitis, use of investigational or prohibited drugs, and reduced wound area

TABLE 2 Mean baseline subject demographics and wound characteristics

Subject demographics			
Variable	PMVT (n = 50)	Control (n = 50)	P value
Age (y)	59.4 ± 13.22	61.2 ± 9.79	.43
Race n (%)			
Caucasian	44 (88)	46 (92)	.74
African American	6 (12)	4 (8)	
Sex n (%)			
Male	32 (64)	34 (68)	.67
Female	18 (36)	16 (32)	
BMI	34.3 ± 8.79	32.5 ± 6.65	.54
Smoking status n (%)			
Never	26 (52)	24 (48)	.91
Former	18 (36)	19 (38)	
Current	6 (12)	7 (14)	
Hypertension	39 (78)	37 (7)	.64
HbA1c			
Screening	8.1 ± 1.65	7.4 ± 1.50	.047
End of study ^a	8.0 ± 1.88	7.0 ± 1.57	.008
Creatinine	1.1 ± 0.36	1.1 ± 0.39	.80
DFU History			
Significant deformities n (%)	12 (24)	14 (28)	.65
Age first DFU appeared (y)	54.0 ± 14.3	55.7 ± 11.09	.51
Prior number of DFUs	3.2 ± 4.35	2.7 ± 2.48	.70
Amputations (study foot) n (%)	13 (26)	16 (32)	.51
Amputation (contralateral foot) n (%)	6 (12)	11 (22)	.18
Concurrent DFUs (screening) n (%)	6 (12)	12 (24)	.12
Wound characteristics			
Variable	PMVT (n = 50)	Control (n = 50)	P value
Wound area (cm ²) (randomisation)	3.1 ± 3.4	3.5 ± 2.3	.081
Initial depth (mm) n (%)			
<1	14 (28)	10 (20)	.024
1	27 (54)	19 (38)	
2	5 (10)	12 (24)	
>2	4 (8)	9 (18)	
Wound age (wk)	15.2 ± 10.4	15.6 ± 10.8	.71
Wagner grade n (%)			
Wagner 1	26 (52)	17 (34)	.07
Wagner 2	24 (48)	33 (66)	
Plantar location n (%)	41 (82)	35 (70)	.16
Wound position n (%)			
Lateral	24 (48)	21 (42)	.55
Medial	26 (52)	29 (58)	

TABLE 2 (Continued)

Wound characteristics			
Variable	PMVT (n = 50)	Control (n = 50)	P value
Wound location n (%)			
Toe	13 (26)	7 (14)	.04
Forefoot	17 (34)	14 (28)	
Midfoot	10 (20)	13 (26)	
Hindfoot	1 (2)	2 (4)	
Heel	8 (16)	8 (16)	
Ankle	1 (2)	6 (12)	
Mean duration of offloading at screening (wk)	16.0 ± 14.8	14.0 ± 11.4	.96
Mean percent time wound offloaded during study	82.1 ± 11.1	81.1 ± 9.1	.88

^aValues for one subject in the PMVT group and six subjects in the control group were missing. Bold value show * $p < 0.05$.

subjects, 14 subjects discontinued the study early because of adverse or serious adverse events (PMVT = 3; control = 11) and one subject (control) was lost to follow-up at week 12 (Figure 1). These 15 subjects were all counted as failed treatments in the final data analysis in accordance with LOCF principles. Baseline demographics between the control and PMVT groups were similar apart from there being deeper wounds in the control group and more wounds located on the toes in the PMVT group (Table 2). Approximately half of the subjects in both cohorts were current or past smokers, and the average BMI of both groups was above 30. While there were no statistically significant differences between the control and treatment cohorts for either demographic parameter ($P = .91$ and $P = .54$, respectively), these data attest to the high risk of impaired healing for the subjects enrolled in the HIFLO study.

3.2 | Primary and secondary wound closure endpoints

Subjects who received PMVT had a statistically significant increase in the percentage of wounds closed at 12 weeks compared with the control arm (74% vs 38%, $P = .0003$), meeting the study's primary endpoint (Figure 2A). The final statistical power of this endpoint was 96%, exceeding the projected power of 88% and signifying a greater ability to detect if a difference in outcomes existed between the two treatment groups. Logistic regression analysis to determine the effect of baseline wound area, baseline HbA1c level, and treatment group assignment on healing outcomes was also performed to calculate the adjusted results. Linearity of independent variables with log odds ratio (OR) was verified. While the odd ratios for healing decreased with each unit

increase in value for baseline wound area (OR = 0.82; $P = .023$) and HbA1c (OR = 0.57; $P = .001$), assignment into the PMVT group increased the odds of healing by approximately 9-fold (OR = 9.0; $P = .00008$) compared with the control.

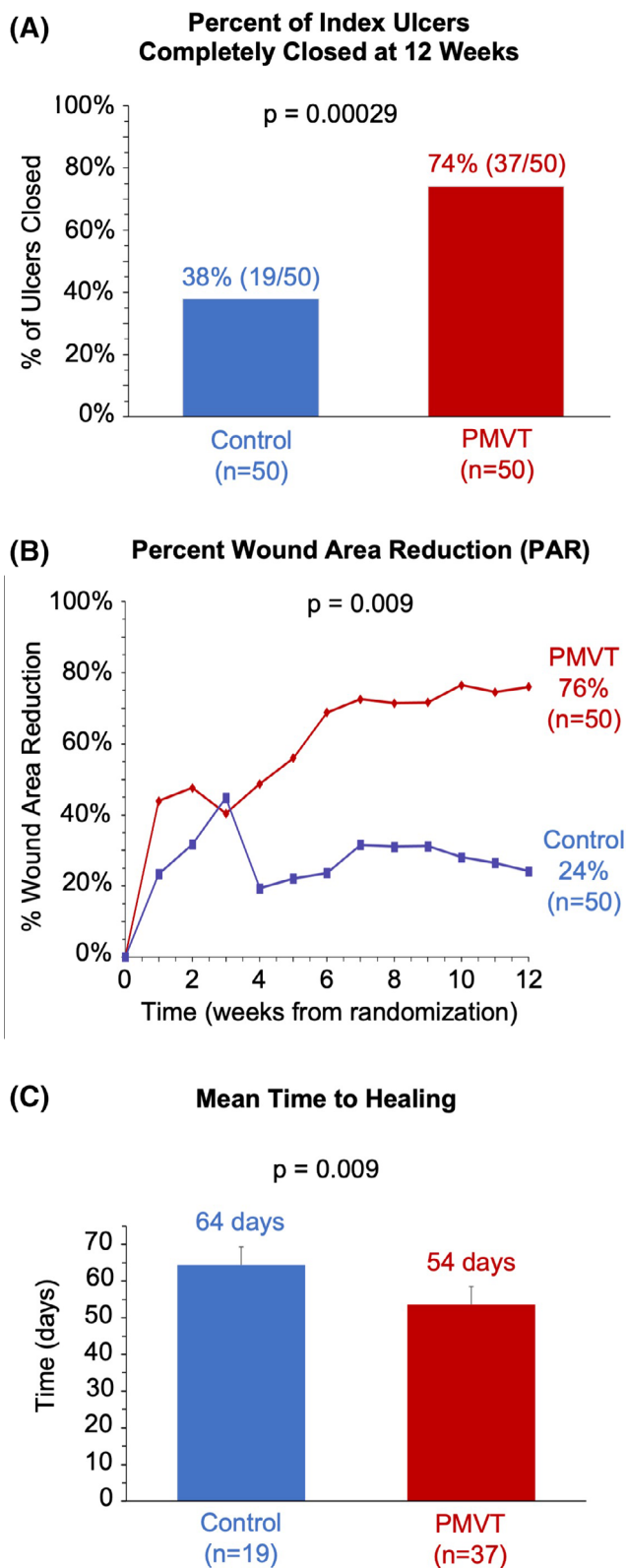
Change in PAR showed a divergence in trajectories with statistical significance seen between the PMVT and control groups beginning at 4 weeks and continuing through 12 weeks of treatment ($P = .009$). Subjects in the PMVT group had a mean PAR of 76%, over 3-fold more than the mean PAR seen in subjects in the control group (Figure 2B). The mean time to healing was statistically significantly faster for the PMVT group compared with subjects in the control group (54 days (95% CI: 46–61) vs 64 days (95% CI: 57–72); $P = .009$). This 10-day reduction in time to complete closure is particularly significant as it suggests a change in the wound healing trajectory in the cohort of subjects who achieved wound closure.⁴² This is further substantiated by Kaplan-Meier analysis showing clear divergent trajectories for time to healing between the PMVT and control groups beginning around 6 weeks, with a 16% faster time to healing seen for subjects in the PMVT group compared with the control group (Figure 2C).

3.3 | Exploratory wound perfusion endpoint

Representative image analyses of the¹⁰ consecutive subject subset who underwent wound perfusion assessment via ICGFA to determine ingress rate are shown in Figure 3A,B. ICGFA was analysed for all 10 subjects and timepoints, except for two control subjects who exited the trial prematurely. End study data for these two subjects

were imputed using LOCF principles. As a standardised table denoting ingress rates consistent with healing does not exist, change in average ingress rates from baseline to 12 weeks was assessed. A consistent, steady decrease in the mean ingress rate, corresponding to an increase

in perfusion of 60% was seen for the PMVT group, whereas the control group showed a consistent increase in the mean ingress rate corresponding to a significant decrease in perfusion (67%) (Figure 3C).



3.4 | Secondary local neuropathy endpoint and exploratory regional neuropathy endpoint

The 10-point SWM exam conducted on all 100 study subjects showed those treated with PMVT had a statistically significant improvement in peripheral neuropathy at end of treatment compared with those in the control group (118% vs 11%; $P = .028$) (Figure 4). Improved peripheral neuropathy was seen within the first 2 to 4 weeks of the study period.

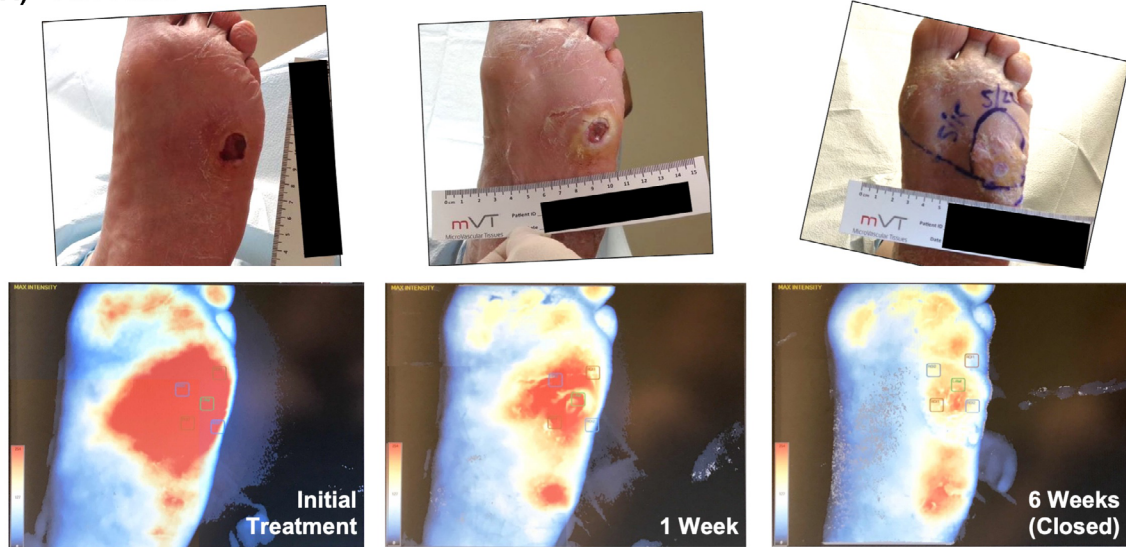
Mean percent reduction in the area of regional peripheral neuropathy assessed with the stocking glove technique was also greater in the PMVT group ($62 \pm 31\%$) compared with patients from the control group ($16 \pm 12\%$). An example of boundary of sensation marking over time and corresponding change in neuropathy area using image analysis is shown in Figure 5A,B. Although this assessment was only performed on the subset of 21 subjects, the change in sensation over time showed a trend of a rapid reduction of neuropathy area in PMVT treated subjects (Figure 5C).

3.5 | Safety

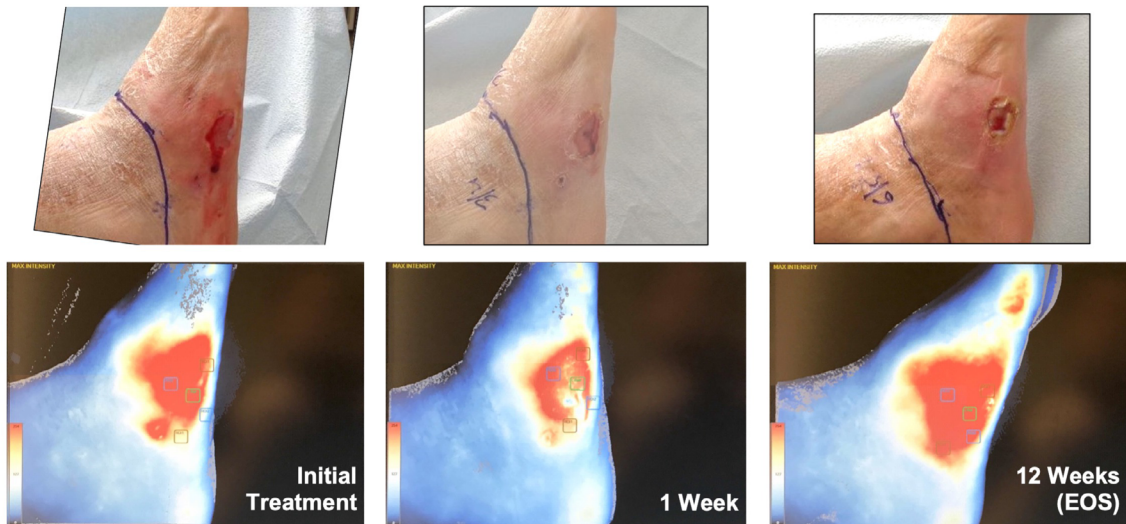
No adverse events (AEs) or serious adverse events (SAEs) related to the study treatment or the procedure were reported. A total of three AEs/SAEs in the PMVT arm and eight in the control arm related to the study wound were recorded (Table 3). Although the total AEs/SAEs in the control arm exceed that of the PMVT arm, all are

FIGURE 2 Primary and secondary wound closure results. (A) Percent of index ulcers closed at 12 weeks was nearly double in the PMVT treated group (74%) compared with the control (38%), using the predefined four-point closure criteria with blinded adjudication; (B) Percent wound area reduction over time was determined using a general linear mixed model. PMVT reduced the wound area approximately three times more than the control; (C) In the mean time to healing assessment, only subjects with complete wound closure during the 12-week trial period were included in the time to healing analysis. The 10-day difference between the two groups translates to a 16% faster closure rate for the PMVT group, which is not only statistically significant but clinically significant because of potential for fewer clinic visits

(A) – PMVT ulcer



(B) – Control ulcer



(C) Change in Wound Area Perfusion

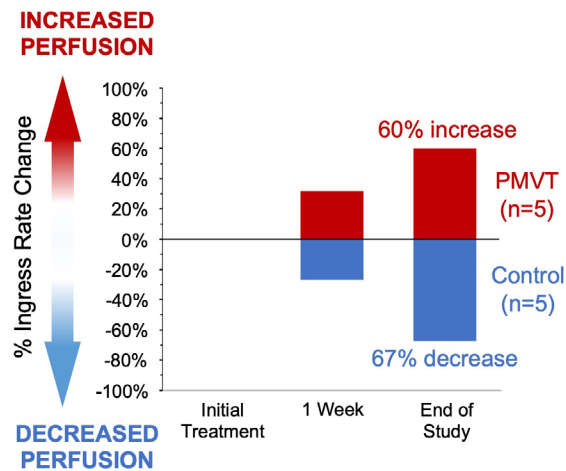


FIGURE 3 Legend on next page.

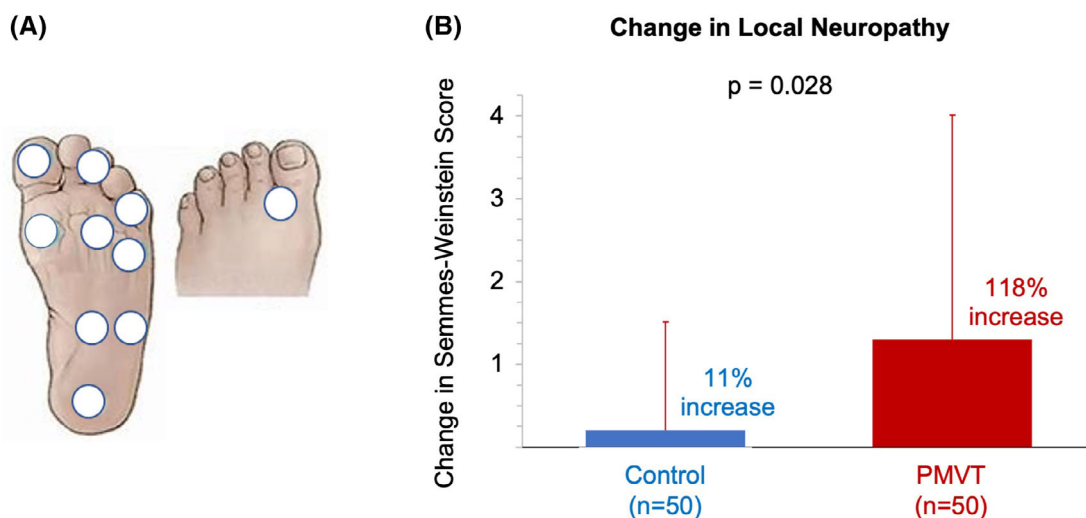


FIGURE 4 Change in local sensory neuropathy. (A) Schematic depicting the 10 predefined points on the foot used to assess local peripheral neuropathy with the standard Semmes-Weinstein monofilament (SWM) test; (B) Changes to local neuropathy were measured weekly on all 100 subjects. There was an 11% increase in the SWM score in the control group vs 118% ($P = .028$) in PMVT-treated subjects at the end of the study

typical of patients with DFUs, and none were deemed by the investigators to be a direct result of the topical treatment. Other AEs/SAEs unrelated to the study wound were typical of this patient population. In total, one PMVT subject and seven control subjects were hospitalised during the treatment phase of the study, although with the exception of one control subject hospitalised as a result of an infection of the index ulcer that led to amputation, all hospitalisations were because of non-study wound issues.

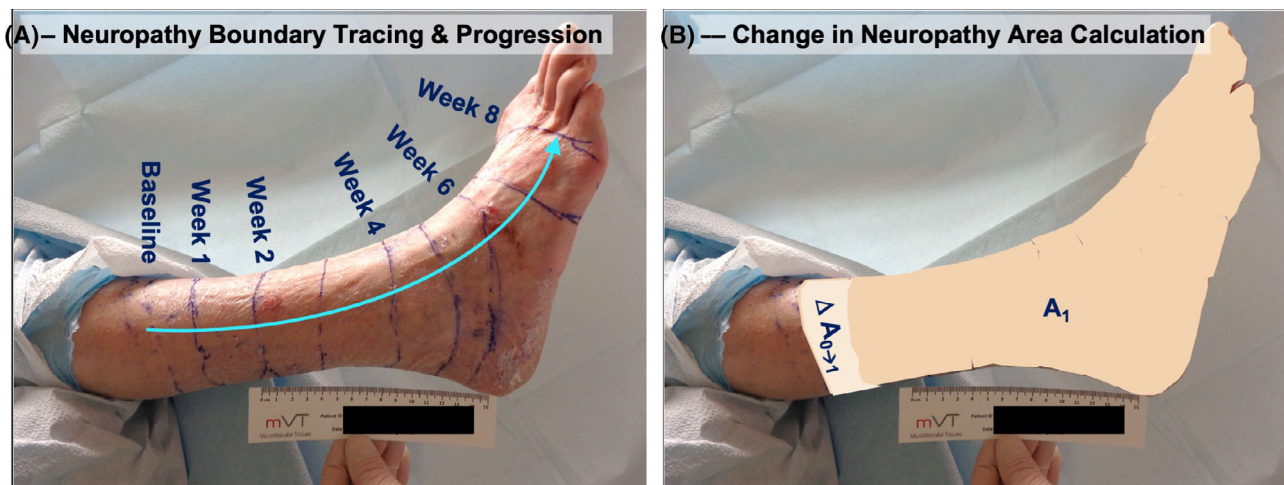
4 | DISCUSSION

Diabetic foot ulceration, caused by peripheral neuropathy and an impaired microcirculation, remains a significant complication of diabetes. Lower extremity amputation is the end result of untreated DFU that become infected, leading to gangrene and osteomyelitis. Standard

conservative approaches to DFU will resolve approximately 70% of DFUs after 4 months of treatment, but the remaining 30% of DFUs will become chronic,⁴³ placing the patient at risk for cellulitis, osteomyelitis, gangrene, and lower extremity amputation.⁴⁴ Advanced wound care techniques such as skin grafts, recombinant growth factors, hyperbaric oxygen, and bioengineered skin can be effective for therapy, but none directly address the defects of the microcirculation or neuropathy present in diabetic wounds. We here report that microvascular therapy can be effective to healing chronic DFU, achieving complete wound closure, with evidence of improved perfusion and improvement in neuropathy.

HIFLO is a randomised, prospective, single-blinded, multi-centre clinical trial designed to validate use of a microvascular tissue allograft (PMVT) in a diabetic population with non-healing Wagner Grade 1 and 2 DFU. The results demonstrated a statistically significant increase in complete wound closure at 12 weeks,

FIGURE 3 Fluorescence angiography. (A, B) Max Intensity images using indocyanine green fluorescence angiography (ICGFA) taken prior to initial PMVT treatment. The intensely red signal is indicative of unhealthy hyperpermeable (leaky) microvasculature in a chronic wound. When the microvasculature is re-established and new vessels mature, the permeability goes down, so the amount of red signal drops. (A) Shows the progression of a representative PMVT-treated DFU; note the decreasing red signal between the time of the initial treatment, 1 week later, and ultimately at 6 weeks, when the DFU was confirmed as closed. The greater blue signal demonstrates evidence of healing and improved perfusion driven by angiogenesis and maturation of blood vessels; (B) Is a similar representative set of images from the initial treatment to the end of study (EOS) for a DFU that received Control treatment. The vasculature never healed, as evidenced by the increased red signal in the final image, and this wound did not close within the 12-week study period; (C) Ingress rate, a variable reflective of vessel permeability, decreases as tissue perfusion improves. In this subset of 10 subjects, blood flow in the control subjects decreased at the week 1 visit and the EOS, while PMVT subjects exhibited early improvement and ultimately a 60% increase in mean perfusion by the end of the study



Individual Change in Regional Neuropathy

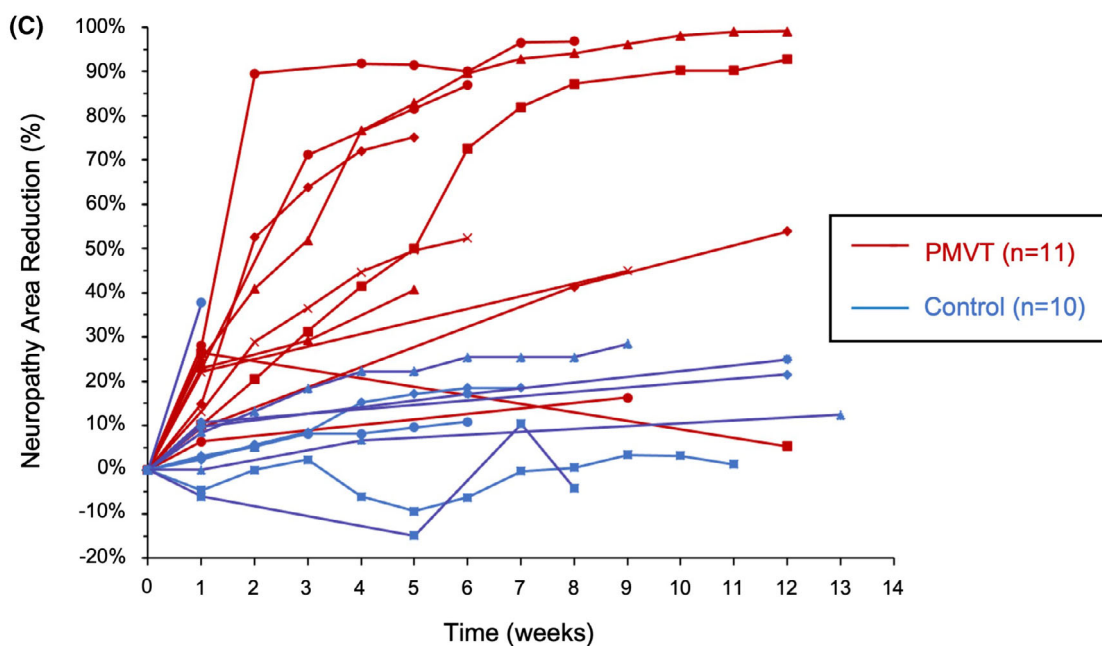


FIGURE 5 Change in regional sensory neuropathy (stocking glove technique). (A) Boundaries of sensation marked in successive visits demonstrate improved lower extremity regional neuropathy; (B) Image demonstrating the change in neuropathy area between visits using contour tracing and image analysis software; (C) Changes in neuropathy area over time based on the stocking glove technique for each of the 21 subjects included in the subset. The trend towards improved peripheral neuropathy during the study period with PMVT treatment is evident. Upon analysis, the neuropathy area in PMVT-treated subjects decreased an average of 62%, compared with a 16% decrease in the control group

reduced time to healing, increased PAR, and improved lower extremity peripheral neuropathy. In addition, the odds of healing with PMVT treatment were nine times greater than a control group in which standard wound care was applied along with a collagen alginate dressing. One of the challenges for clinicians in comparing available DFU treatment options is that there is an inconsistent definition of closure within the field. HIFLO therefore

incorporated a stringent definition of complete wound closure with adjudication verification, use of a robust and consistent standard of care treatment, and the final power (96%) of the statistical analysis performed. Confirmation of wound closure was determined by the investigator, a separate blinded physician at the study site who had not been treating the wound, and a panel of three independent blinded adjudicators with expertise in wound care, and then

TABLE 3 Study wound-related adverse and serious adverse events

Type of event	Control (n = 50)	PMVT (n = 50)
Adverse event (AE)	Infection (1)	Infection (1)
	Cellulitis (1)	Swelling (1)
	Bursitis (1)	
	Dehiscence (1)	
Serious adverse event (SAE)	Infection (2)	Dermatitis (1)
	Osteomyelitis (1)	
	Amputation (1)	
Total AE + SAE	8	3

reconfirmed 2 weeks after adjudication at the healing confirmation visit.

Improving the quality of healing is a critical goal for DFU, given the variety of advanced wound care technologies that offer improved wound closure. In the HIFLO Trial, numerous primary, secondary, and exploratory endpoints were assessed, including the use of functional imaging to evaluate perfusion and examination of changes in regional peripheral neuropathy in subsets of subjects. These exploratory endpoints suggest mechanisms by which PMVT expedites DFU healing.

While the cause of diabetic neuropathy is not fully understood, the compromise of both vascular and neural components, which are innately interconnected, are recognised as important elements in its pathophysiology. Vascular insufficiency, ischaemia, hypoxia, and inflammation have all been implicated in the development and progression of diabetic neuropathy.⁴⁵⁻⁴⁷ Neuronal dysfunction correlates closely with the development of blood vessel abnormalities, such as capillary basement membrane thickening and endothelial hyperplasia, which contribute to diminished oxygen tension and hypoxia. Neuronal ischaemia is a well-established characteristic of diabetic neuropathy.

The ability of PMVT to improve local neuropathy is an important observation in this study. Diabetic neuropathy is an underlying factor for skin injury that progresses to ulceration. The insensate feet contribute to decreased quality of life.⁴⁸ While the monofilament technique is known to have some variability, the large number of subjects analysed in the HIFLO Trial combined with the standardised training across all study sites enabled consistency in technique and the demonstration of statistically significant improvement in local neuropathy with PMVT. The improved sensation documented in this study is likely because of improved angiogenesis, although the mechanisms of action are not known and warrant further investigation. An intervention that improves diabetic neuropathy would address a primary risk factor for DFU formation, and has the potential to reduce wound recidivism.¹⁸

The increase in local tissue perfusion documented by fluorescence microangiography addresses another key risk factor for DFU, because microvascular pathology and reduced tissue oxygenation are observed in diabetes.⁴⁹ The restoration of the microcirculation allows increased oxygen and nutrient delivery to the wound, which promotes granulation and wound epithelialisation.⁵⁰ The finding that there appears to be an inflection point in the rate of wound closure between 2 and 4 weeks, where the control group's rate of closure falls off relative to the treatment group (Figure 2B), may suggest that PMVT promotes a transition towards a more normal wound healing process that enables closure of the wound.

The structure and composition of PMVT may provide insight into possible mechanisms that resulted in improved perfusion and wound healing. PMVT is microvascular tissue, which not only includes microvessels but also extracellular matrix (ECM). PMVT's microvessel fragments and ECM provide physical scaffolding, mechanical stability, and biochemical cues necessary for angiogenesis, tissue formation, and maintenance of stability in the microenvironment.^{30,31,51} The ECM modulates a whole host of processes including cell migration, attachment, differentiation, and repair, and serves as a reservoir and binding site for growth factors.⁵² Integrins bind to the extracellular matrix, which in turn triggers endothelial cell adhesion and migration, early indicators of the process of angiogenesis.^{53,54} PMVT preclinical data and the scientific literature are supportive of these mechanisms for the positive results seen with PMVT in this clinical study, and are deserving of future exploration.

4.1 | Limitations

One limitation of this study is the small subset size of subjects assessed for exploratory evaluation of changes in perfusion. Wound perfusion assessment is a relatively new technology, and ICGFA has not been validated in wound healing. The images can be influenced by various environmental and patient-related factors, including room temperature and patient activity prior to imaging. However, the fluorescence patterns observed for wounds that progressed to healing in this study followed the same trajectory of a chronic wound transitioning from stagnation in a dysfunctional inflammatory phase to the proliferative phase of healing as that reported in several other peer-reviewed publications.^{37,55,56} In addition, although the trial was powered to study local peripheral neuropathy as a secondary endpoint, the assessment in neuropathy area by the stocking glove technique was exploratory. The significant reduction in local and regional neuropathy seen upon PMVT treatment is an

important novel observation, but this outcome may be because of factors unrelated to PMVT, and it is possible that successful healing is accompanied by improved neuropathy that has not been measured in other controlled studies of DFU wound healing.

5 | CONCLUSION

Weekly application of PMVT, a microvascular tissue allograft, resulted in significantly greater wound closure and improved local neuropathy. These findings support the utility of microvascular therapy as a new approach to treating chronic DFUs. Exploratory results suggest that the increased wound site perfusion and reduction of regional neuropathy accompany wound resolution accelerated by PMVT. Therefore, the restoration of a functional microcirculation is a new approach to diabetic wound healing. By addressing the vascular deficiencies and impaired sensation underlying diabetes, PMVT treatment may also reduce wound recidivism, which would lower medical complications, improve quality of life, and lower associated healthcare costs because of wound recurrence. Further clinical and translational studies of microvascular therapy using PMVT will help to validate the outcomes of the HIFLO Trial.

ACKNOWLEDGEMENTS

The authors wish to acknowledge Nathan Young (Foot & Ankle Associates of Southwest Virginia), Allen Jacobs (SSM Health), and Rachel Hoyal (Sutter Health) for participation as clinical study investigators; Tracey Ikerd (Riverview Health), Jonathan Arnold (Mercy Healing Center), and John Lindberg (Emanate Health) for fluorescence angiography analysis and expertise; Travis Smith and Emmanuel Wilson (eKare, Inc.) for wound measurement system support; Morgan Stepanek and Kim Young (PERI, Inc.) for clinical study support; Douglas M. Arm (MicroVascular Tissues, Inc.) for assistance with study design, clinical study support, data analysis, and manuscript review/editing; and Valerie L. Marmolejo (Scriptum Medica) for assistance with manuscript preparation. L.G. is the guarantor of this work and, as such, had full access to all the data in the study and takes responsibility for the integrity of the data and the accuracy of the data analysis. The HIFLO Trial was sponsored by MicroVascular Tissues, Inc. (San Diego, CA).

CONFLICT OF INTEREST

C.Z. is an employee of Professional Educational Research Institute, the CRO that conducted this trial. W.L. is a consultant to MicroVascular Tissues, Inc.

AUTHOR CONTRIBUTIONS


Lisa Gould was the principal investigator for the study, reviewed the data, contributed to the discussion, and reviewed/edited the manuscript. Dennis P. Orgill served as an adjudicator for the study, contributed to the discussion, and reviewed/edited the manuscript. David G. Armstrong contributed to the discussion and reviewed/edited the manuscript. Robert D. Galiano served as an adjudicator for the study, contributed to the discussion, and reviewed/edited the manuscript. Paul M. Glat served as an adjudicator for the study, contributed to the discussion, and reviewed/edited the manuscript. Charles M. Zelen was a clinical investigator for the study, contributed to the study design, reviewed the data, and reviewed/edited the manuscript. Lawrence A. DiDomenico was a clinical investigator for the study, contributed to the discussion, and reviewed/edited the manuscript. Marissa J. Carter contributed to the development of the statistical plan, analysed data, and reviewed/edited the manuscript. William W. Li contributed to the study design, reviewed the data, and reviewed/edited the manuscript.

DATA AVAILABILITY STATEMENT

The data that support the findings of this study are the property of the study sponsor, MicroVascular Tissues, Inc., and therefore are not publicly available. IRB informed consent requirements limits disclosure of subject data to their health care provider, study sponsor and their representatives, regulatory agencies and the IRB.

ORCID

Lisa J. Gould  <https://orcid.org/0000-0001-5167-4679>

Charles M. Zelen  <https://orcid.org/0000-0001-5682-7056>

REFERENCES

1. Armstrong DG, Boulton AJM, Bus SA. Diabetic foot ulcers and their recurrence. *N Engl J Med*. 2017;376(24):2367-2375. <https://doi.org/10.1056/NEJMra1615439>
2. Zhang P, Lu J, Jing Y, Tang S, Zhu D, Bi Y. Global epidemiology of diabetic foot ulceration: a systematic review and meta-analysis. *Ann Med*. 2017;49(2):106-116. <https://doi.org/10.1080/07853890.2016.1231932>
3. Rice JB, Desai U, Cummings AK, Birnbaum HG, Skornicki M, Parsons NB. Burden of diabetic foot ulcers for medicare and private insurers. *Diabetes Care*. 2014;37(3):651-658.
4. Cavanagh P, Attinger C, Abbas Z, Bal A, Rojas N, Xu ZR. Cost of treating diabetic foot ulcers in five different countries. *Diabetes Metab Res Rev*. 2012;28(Suppl 1):107-111. <https://doi.org/10.1002/dmrr.2245>
5. Driver VR, Fabbri M, Lavery LA, Gibbons G. The costs of diabetic foot: the economic case for the limb salvage team. *J Am*

- Podiatr Med Assoc.* 2010;100(5):335-341. <https://doi.org/10.7547/1000335>
6. Boulton AJ. The diabetic foot: grand overview, epidemiology and pathogenesis. *Diabetes Metab Res Rev.* 2008;24(Suppl 1):S3-S6. <https://doi.org/10.1002/dmrr.833>
 7. Armstrong DG, Swerdlow MA, Armstrong AA, Conte MS, Padula WV, Bus SA. Five year mortality and direct costs of care for people with diabetic foot complications are comparable to cancer. *J Foot Ankle Res.* 2020;13(1):16. <https://doi.org/10.1186/s13047-020-00383-2>
 8. Vedhara K, Beattie A, Metcalfe C, et al. Development and preliminary evaluation of a psychosocial intervention for modifying psychosocial risk factors associated with foot re-ulceration in diabetes. *Behav Res Ther.* 2012;50(5):323-332.
 9. Ireton JE, Unger JG, Rohrich RJ. The role of wound healing and its everyday application in plastic surgery: a practical perspective and systematic review. *Plast Reconstr Surg Glob Open.* 2013;1(1):e10-e19. <https://doi.org/10.1097/GOX.0b013e31828ff9f4>
 10. Najafi B, Reeves ND, Armstrong DG. Leveraging smart technologies to improve the management of diabetic foot ulcers and extend ulcer-free days in remission. *Diabetes Metab Res Rev.* 2020;36(Suppl 1):e3239.
 11. Bus SA, Waaijman R, Arts M, et al. Effect of custom-made footwear on foot ulcer recurrence in diabetes: a multicenter randomized controlled trial. *Diabetes Care.* 2013;36(12):4109-4116.
 12. Skafjeld A, Iversen MM, Holme I, Ribu L, Hvaal K, Kilhovd BK. A pilot study testing the feasibility of skin temperature monitoring to reduce recurrent foot ulcers in patients with diabetes—a randomized controlled trial. *BMC Endocr Disord.* 2015;15:55.
 13. Beattie AM, Campbell R, Vedhara K. 'What ever I do it's a lost cause.' The emotional and behavioural experiences of individuals who are ulcer free living with the threat of developing further diabetic foot ulcers: a qualitative interview study. *Health Expect.* 2014;17(3):429-439.
 14. Rohkamm R. In: Taub E, ed. *Color Atlas of Neurology.* 2nd ed. Stuttgart, Germany: Georg Thieme Verlag; 2004:90.
 15. Moore KL, Agur AM, Dalley AF. *Clinically Oriented Anatomy.* 6th ed. Philadelphia, PA: Lippincott Williams & Wilkins, Wolters Kluwer; 2010:50.
 16. Cameron NE, Eaton SEM, Cotter MA, Tesfaye S. Vascular factors and metabolic interactions in the pathogenesis of diabetic neuropathy. *Dibetologia.* 2001;44:1973-1988.
 17. Fang F, Wang K, Wang Y-F, Peng Y-D. Microangiopathy in diabetic polyneuropathy revisited. *Eur Rev Med Pharmacol Sci.* 2018;22:6456-6462.
 18. Thrainsdottir S, Malik RA, Dahlin LB, et al. Endoneurial capillary abnormalities presage deterioration of glucose tolerance and accompany peripheral neuropathy in man. *Diabetes.* 2003; 52:2615-2622.
 19. Nukuda H. Ischemia and diabetic neuropathy. *Handb Clin Neurol.* 2014;126:469-487.
 20. Boulton AJ. The pathway to foot ulceration in diabetes. *Med Clin North Am.* 2013;97:775-790.
 21. Boulton AJ. Diabetic neuropathy and foot complications. *Handb Clin Neurol.* 2014;126:97-107.
 22. Tomita M, Kabeya Y, Okisugi M, et al. Diabetic microangiopathy is an independent predictor of incident diabetic foot ulcer. *J Diabetes Res.* 2016;2016:5938540.
 23. Dulmovits BM, Herman IM. Microvascular remodeling and wound healing: a role for pericytes. *Int J Biochem Cell Biol.* 2012;44:1800-1812.
 24. Pham HT, Economides PA, Veves A. The role of endothelial function on the foot. Microcirculation and wound healing in patients with diabetes. *Clin Podiatr Med Surg.* 1998;15:85-93.
 25. Nauta TD, van Hinsbergh VW, Koolwijk P. Hypoxic signaling during tissue repair and regenerative medicine. *Int J Mol Sci.* 2014;15:19791-19815.
 26. Bodnar RJ, Satish L, Yates CC, Wells A. Pericytes: a newly recognized player in wound healing. *Wound Rep Reg.* 2016;24: 204-214.
 27. James AW, Zara JN, Corselli M, et al. An abundant perivascular source of stem cells for bone tissue engineering. *Stem Cells Transl Med.* 2012;1:673-684.
 28. McDaniel JS, Pilia M, Ward CL, Pollot BE, Rathbone CR. Characterization and multilineage potential of cells derived from isolated microvascular fragments. *J Surg Res.* 2014;192:214-222.
 29. Laschke MW, Menger MD. Adipose tissue-derived microvascular fragments: natural vascularization units for regenerative medicine. *Trends Biotechnol.* 2015;33:442-448.
 30. Dobke M, Peterson DR, Mattern RH, Arm DM, Li WW. Microvascular tissue as a platform technology to modify the local microenvironment and influence the healing cascade. *Regen Med.* 2020;15(2):1313-1328. <https://doi.org/10.2217/rme-2019-0139>
 31. Gimble JM, Frazier T, Wu X, et al. A novel, sterilized microvascular tissue product improves healing in a murine pressure ulcer model. *Plast Reconstr Surg Glob Open.* 2018;6(11):e2010. <https://doi.org/10.1097/GOX.0000000000002010>
 32. Zelen CM, Gould LJ, Li WW. Clinical achievement of wound closure and tissue quality with a novel microvascular tissue graft. *Wounds.* 2019;31(4):E29-E32.
 33. Dobke M, Arm DM, Li WW. Reactivation of the clinically senescent wound using a novel microvascular tissue graft in complex lower irradiated leg wounds SAWC spring; 2019; CS-018.
 34. Armstrong DG, Lavery LA, Vela SA, Quebedeaux TL, Fleischli JG. Choosing a practical screening instrument to identify patients at risk for diabetic foot ulceration. *Arch Intern Med.* 1998;158(3):289-292. <https://doi.org/10.1001/archinte.158.3.289>
 35. Boulton AJM, Armstrong DG, Albert SF, et al. Comprehensive foot examination and risk assessment: a report of the task force of the foot care interest group of the American Diabetes Association, with endorsement by the American Association of Clinical Endocrinologists. *Diabetes Care.* 2008;31(8):1679-1685. <https://doi.org/10.2337/dc08-9021>
 36. Tanenberg R, Donofrio P. Chapter 3—Neuropathic Problems of the Lower Limbs in Diabetic Patients. In: Bowker JH, Pfeifer MA, eds. *Levin and O'Neal's: The Diabetic Foot.* 7th ed. Amsterdam, Netherlands: Elsevier; 2008:33-74. <https://doi.org/10.1016/B978-0-323-04145-4.50010-7>
 37. Arnold JF, Roscum M. The EXPLORE trial: a feasibility study using fluorescence angiography to evaluate perfusion in the oxygen-rich environment. *Surg Technol Int.* 2016;29:61-79.
 38. Food and Drug Administration. *Guidance for Industry: Chronic Cutaneous Ulcer and Burn Wounds—Developing Products for*

- Treatment*. Silver Spring, MD: Food and Drug Administration; 2006.
39. Gould L, Li WW. Defining complete wound closure: closing the gap in clinical trials and practice. *Wound Rep Reg*. 2019; 27(3):201-224. <https://doi.org/10.1111/wrr.12707>
 40. Gupta SK. Intention-to-treat concept: a review. *Perspect Clin Res*. 2011;2(3):109-112.
 41. Jakobsen JC, Gluud C, Wetterslev J, Winkel P. When and how should multiple imputation be used for handling missing data in randomised clinical trials—a practical guide with flowcharts. *BMC Med Res Methodol*. 2017;17(1):162.
 42. Robson MC, Hill DP, Woodske ME, Steed DL. Wound healing trajectories as predictors of effectiveness of therapeutic agents. *Arch Surg*. 2000;135(7):773-777.
 43. Margolis DJ, Kantor J, Berlin JA. Healing of diabetic neuropathic foot ulcers receiving standard treatment. A meta-analysis. *Diabetes Care*. 1999;22(5):692-695.
 44. Pickwell K, Siersma V, Kars M, et al. Predictors of lower-extremity amputation in patients with an infected diabetic foot ulcer. *Diabetes Care*. 2015;38(5):852-857.
 45. Vincent AM, Callaghan BC, Smith AL, Feldman EL. Diabetic neuropathy: cellular mechanisms as therapeutic targets. *Nat Rev Neurol*. 2011;7:573-583.
 46. Waterman RS, Morgenweck J, Nossaman BD, Scandurro AE, Scandurro SA, Betancourt AM. Anti-inflammatory mesenchymal stem cells (MSC) attenuate symptoms of painful diabetic peripheral neuropathy. *Stem Cells Transl Med*. 2012;1:557-565.
 47. Zhou J, Zhou S. Inflammation: therapeutic targets for diabetic neuropathy. *Mol Neurobiol*. 2014;49:536-546.
 48. Pop-Busui R, Boulton AJ, Feldman EL, Bril V, Freeman R, et al. Diabetic neuropathy: a position statement by the American Diabetes Association. *Diabetes Care*. 2017;40:136-154.
 49. Whitney J. The influence of tissue oxygen and perfusion on wound healing. *AACN Adv Crit Care*. 1990;1(3):578-584.
 50. Gottrup F. Oxygen in wound healing and infection. *World J Surg*. 2004;28(3):312-315. <https://doi.org/10.1007/s00268-003-7398-5>
 51. Kim Y, Ko H, Kwon IK, Shin K. Extracellular matrix revisited: roles in tissue engineering. *Int Neurobiol J*. 2016;20:S23-S29. <https://doi.org/10.5213/inj.1632600.318>
 52. Hynes RO. The extracellular matrix: not just pretty fibrils. *Science*. 2009;326(5957):1216-1219. <https://doi.org/10.1126/science.1176009>
 53. Lamalice L, Le Boeuf F, Huot J. Endothelial cell migration during angiogenesis. *Circ Res*. 2007;100(6):782-794.
 54. Sottile J. Regulation of angiogenesis by extracellular matrix. *Biochim Biophys Acta*. 2004;1654(1):13-22. <https://doi.org/10.1016/j.bbcan.2003.07.002>
 55. Marmolejo VS, Arnold JF. The ability of fluorescence angiography to detect local ischemia in patients with heel ulceration. *Foot Ankle Spec*. 2018;11(3):269-276. <https://doi.org/10.1177/1938640018762557>
 56. Landsman A. Visualization of wound healing progression with near infrared spectroscopy: a retrospective study. *Wounds*. 2020;32(10):265-271.

How to cite this article: Gould LJ, Orgill DP, Armstrong DG, et al. Improved healing of chronic diabetic foot wounds in a prospective randomised controlled multi-centre clinical trial with a microvascular tissue allograft. *Int Wound J*. 2022; 19(4):811-825. doi:10.1111/iwj.13679