

## Original Article

## Relationship between Two Panoramic Radiography Indices and Bone Mineral Density of Postmenopausal Women with Osteopenia and Osteoporosis

Nader Navabi <sup>1</sup>, Reza Motaghi <sup>2</sup>, Mandana Rezazadeh <sup>3</sup>, Hatam Balooch <sup>4</sup>

<sup>1</sup> Dept. of Oral Medicine, Social Determinants on Oral Health Research Center, Kerman University of Medical Sciences, Kerman, Iran.

<sup>2</sup> Dept. of Oral and Maxillofacial Radiology, Kerman Dental School, Kerman University of Medical Sciences, Kerman, Iran.

<sup>3</sup> Internal Medicine Group, Kerman University of Medical Sciences, Kerman, Iran.

<sup>4</sup> General Dentist, Private Practice, Kerman, Iran.

### KEY WORDS

Menopause;  
Mandibular Cortical Index;  
Mandibular Cortical Width;  
Osteoporosis;  
Osteopenia;

### ABSTRACT

**Statement of the Problem:** Reduced bone mineral density (BMD) generally affects postmenopausal women and it is classified into moderate (osteopenia) and significant osteoporosis. Based on digital panoramic radiographs (DPRs), several quantitative and qualitative assessment methods have been proposed for the diagnosis and evaluation of bone changes and as a predictor of BMD.

**Purpose:** The aim of this study was to compare mandibular cortical width (MCW) and mandibular cortical index (MCI) derived from DPRs in evaluating the BMD in osteopenic and osteoporotic post-menopausal women.

**Materials and Method:** In this cross-sectional study, the BMD assessment was performed using dual-energy X-ray absorptiometry (DEXA). Then, patients were divided into two groups: osteopenia and osteoporosis based on WHO criteria. Two types of T-scores including TT (trabecular) for lumbar spine, TC (cortical) for femoral neck and finally, MCW and MCI were measured based on DPRs.

**Results:** Fifty females with the average age of 57.64±6.03 years were entered into the study. MCW significantly correlated with BMD ( $p < 0.05$ ). Pearson correlation coefficient test revealed that there was almost significant relationship between MCI and BMD ( $p = 0.079$ ). The area under the curve (AUC) in ROC suggested that there was a close overlap between MCW (0.773) and TC (0.783), but TT had the greatest AUC (0.996).

**Conclusion:** The results showed that MCW is an appropriate index of osteoporosis in post-menopausal women. Although the prediction of osteoporosis is poorer at the femoral neck than lumbar spine, MCW can serve as a screening tool for osteoporosis in this area.

Received April 2017;  
Received in revised form August 2017;  
Accepted September 2017;

**Corresponding Author:** Navabi N., Dept. of Oral Medicine, Social Determinants on Oral Health Research Center, Kerman University of Medical Sciences, Kerman, Iran. Email: n\_navabi@kmu.ac.ir  
Tel: +98-3432118071 Fax: +98-3432118073

**Cite this article as:** Navabi N., Motaghi R., Rezazadeh M., Balooch H. Relationship between Two Panoramic Radiography Indices and Bone Mineral Density of Postmenopausal Women with Osteopenia and Osteoporosis. *J Dent Shiraz Univ Med Sci.*, 2018 September; 19(3):181-188.

### Introduction

Osteoporosis (OP) caused by the imbalance between bone formation and resorption is a chronic systemic skeletal and multi-factorial disease. Decrease in bone mass, disturbing the structure of bone tissue and extremely disposing to fracture are the main features of OP. [1-2] OP prevalence is estimated at 27.6 million in

Europe (22 million women and 5.6 million men); however, the statistics will be increased in the future. Certain known risk factors for the disease include older age, female sex, menopause, Asian race, low body mass index, smoking, alcohol use, inadequate intake of vitamin D and calcium, lack of physical activity, consumption of drugs such as corticosteroids (more than three months)

and anticonvulsants. [3] OP imposes a heavy economic cost on the health and treatment systems; hence, it is considered as a major public health problem in both developed and developing countries. [4] Reduction in bone mineral density (BMD), namely osteopenia, usually remains undiagnosed before the onset of serious complications due to being asymptomatic. [3-4] The prevalence of OP is higher in women than in men because of the menopause. [5] Nowadays, some of the public health promotion strategies are for screening of population susceptible to bone fractures (those with osteopenia) and for preventing the serious complications and even death caused by OP. [3]

The gold standard recommended by the World Health Organization (WHO) for diagnosis of OP is the measurement of BMD via dual energy X-ray absorptiometry (DEXA) method. In this method, X-ray is used to measure BMD, which is an areal density and expressed in grams per square centimeter. [2-3] Currently, DEXA method is widely applied worldwide and has very reliable outcomes in identifying individuals with low BMD at the hipbone and spine. It measures the amount of mineral in the skeletal system. [3, 5] For diagnosis of OP, in its early stages it is ideal to measure BMD in all postmenopausal women at risk. However, DEXA technique is expensive and it is better to use a low-cost and simpler alternative method for assessment of the skeletal status in this high-risk population, especially for the socio-economically poor strata of the population. [3]

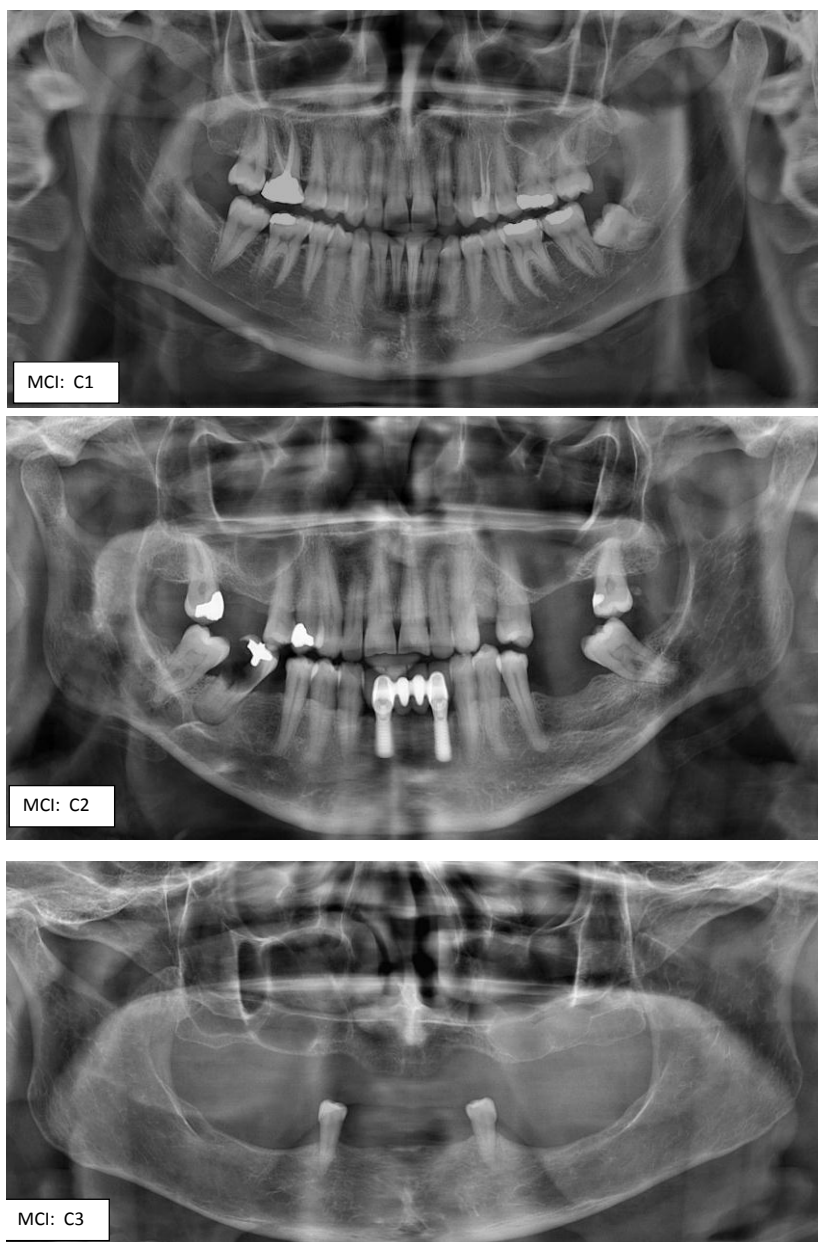
Dental panoramic radiograph (DPR) is considered as a common, simple, and cost-effective technique in dental visits as well as one of the most important diagnostic radiographies among patients over 40 years. [3] In recent decades, the diagnostic status of panoramic radiography has been discussed to find evidences for the OP in women after the age of menopause. In panoramic radiography, there are generally two series of quantitative and qualitative scales to analyze the bone for the signs of resorption and OP. [1-6] A systematic review by Martínez-Maestre *et al.* [7] showed that the majority of studies have confirmed the relationship between OP and jawbone resorption. In several studies, qualitative and quantitative indices of panoramic radiography have been evaluated in OP. [5-28] In another systemic review; Calciolari *et al.* [26] suggested that the dentists

could screen the low levels of BMD values using these indices. So far, in this regard, the most quantitative and qualitative indices have been mandibular cortical width (MCW) and mandibular cortical index (MCI), respectively, [1-6] while the results of various studies have shown that these two indices have no significant superiority to each other for application in postmenopausal women with OP. On the other hand, in previous studies, the comparison between qualitative and quantitative indices was never performed in two groups of patients with low BMD. The aim of this study was to compare the relationship of qualitative and quantitative indices of panoramic radiography with BMD index among postmenopausal women (with two different intensities of reduced BMD) to determine the importance of each index. (Figure 1 and 2)

### Materials and Method

In this cross-sectional research, the study population was women with age range of 45 to 65 years who entered into menopause and whose menstruation was discontinued at least 6 months ago. The study population consisted of the patients suspicious of OP or osteopenia visiting the rheumatologist. Inclusion of the subjects was based on simple sampling method. BMD test was performed for the participants based in the history and clinical examination. The patients with the history of hysterectomy or oophorectomy, taking medications affecting the bone metabolism such as bisphosphonates, corticosteroids, anticonvulsants, synthetic thyroid hormone and estrogen replacement therapy, positive history of bone metabolism diseases including hyperparathyroidism, initial malignancy or metastasis malignancy or degenerative diseases of bone and bone fracture history were excluded from the study. [1-6] Based on the tables of two systematic reviews, the sample size of the current study was 50 people who participated voluntarily. [7] Research objectives were explained for them, their panoramic radiographies were free, and their required dental treatments were given to them in written instructions. In addition, the patient's personal information was kept confidential during the research. This study received a code of ethics (Ir.Kmu.rec.1395.20) from the Department of Science and Technology of Kerman University of Medical Sciences, Iran.

BMD was measured using bone densitometry dev-

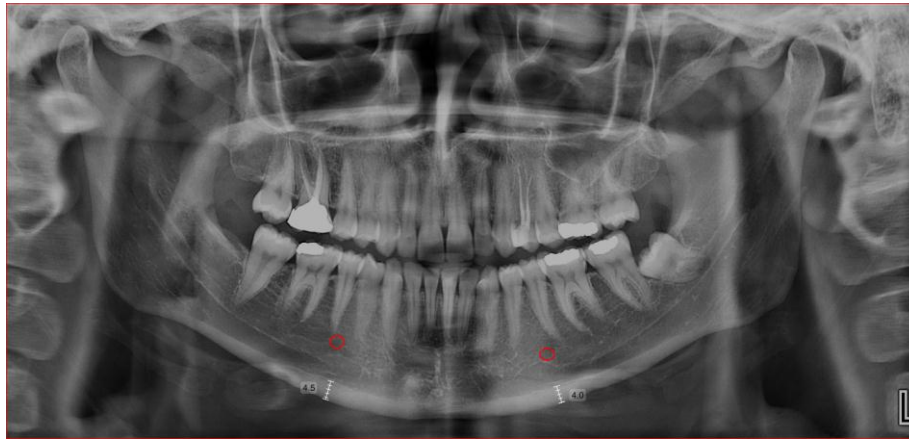


**Figure 1:** Measurement of the Mandibular Cortical Index (MCI) for three classes (C1 to C3) in three cases.

ice (DEXA, from QDR Series, Hologic Co., the USA) in the subspecialty division of rheumatology. After measuring BMD, the results were written in the medical record of each patient and they were referred to a private oral and maxillofacial imaging center along with written admission letter. The measurement results of BMD were reported as T-score. T-score is an index selected by the WHO for this measurement in order to compare the bone density of young healthy people at the same gender. Normal BMD is when the T-score is greater than -0.1. In the range of -0.1 to -2.5, patients are osteopenic and at risk of developing OP, and OP is a T-score less than -2.5. However, this score as -1 time of

standard deviation compared to the mean scale for adult females and -2.5 times of standard deviation are regarded as osteopenia and OP, respectively. [6] Only, the patients with the osteopenia and OP according to the BMD were entered into the present study. In this study, the device reported two types of T-scores for each patient: TC (Cortical bone) for BMD of femoral neck and TT (Trabecular bone) for BMD of lumbar spine.

Panoramic radiographs were prepared by oral and maxillofacial radiologist using digital radiography device (Planmeca/Promax, Finland) with 70kvp, 10 to 14 milliamps, and CCD sensor. The used software in this device was Promax 3.7.1 and images were observed on



**Figure 2:** Measurement of the Mandibular Cortical Width (MCW) index ( $4 + 4.5/2 = 4.25\text{mm}$  for this case)

27-inch monitor of Dell Ultra Sharp with the resolution of  $1440 \times 2560$ . MCW index was used for quantitative assessment of panoramic radiographies of patients, and MCI for qualitative assessment. MCW is defined in millimeter through drawing a perpendicular line from the middle of mental foramen to tangent of the lower border of the mandible. To measure MCW index, the mean was calculated for cases whose cortical bone thickness beneath the mental foramen was different on both sides of the mandible. MCI index (or Klemetti index) is defined as Class I: clear cortical bone boundaries, Class II: cortical bone boundaries with crescent-shaped thermal damage, Class III: clear porosity in the cortical bone with cortical damage on close view. [1-6]

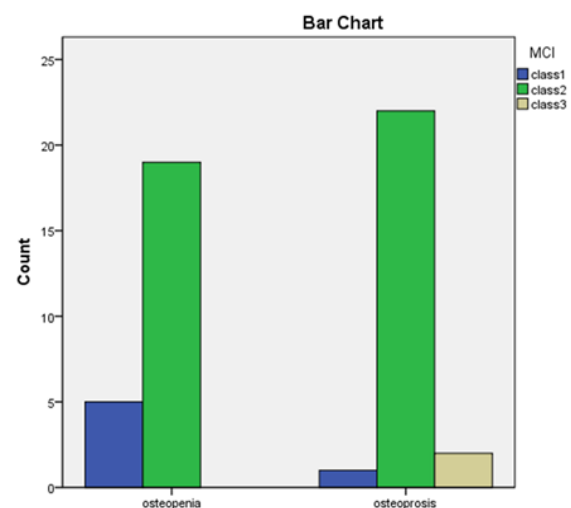
Data were analyzed using SPSS 25 and  $p < 0.05$  was considered as significant level. Pearson correlation coefficient was used to investigate the relationship between MCI and BMD. T-test was applied to examine the relationship of age and panoramic quantitative index (MCW) with the BMD index, and the sensitivity and specificity of the study indicators were analyzed using ROC curve to predict the increase in bone mineral density.

## Results

Totally, 50 postmenopausal women with the mean age of  $57.64 \pm 6.03$  years participated in the current study. The mean BMD of patients (T-score) was  $-2.41 \pm 1.19$  in the spine (TT) and  $-1 \pm 1.16$  in the femur (TC). The mean MCW in patients was obtained  $2.49 \pm 0.67\text{mm}$ . The highest frequency distribution of patients based on MCI was in Class III (84%) and the lowest one was in Class I (12%). Furthermore, according to BMD, half of the

patients were placed in osteopenia group and the other half was placed in OP group.

Figure 3 illustrates the relationship between panoramic MCI and BMD in patients. The majority of patients in terms of MCI were in Class II (84%), and others were in Class I (12%), and Class III (4%), respectively. According to this figure, MCI distribution in osteopenia group is 79.2% for Class II, 20.8% for Class I and 0 for Class III. In osteoporotic group, 88%, 8% and 4% of the subjects were in Class II, Class III, and Class I, respectively. Pearson correlation coefficient was nearly significant ( $p = 0.079$ ) for the relationship between MCI and BMD. In fact, Class II of MCI indicated the presence of OP.

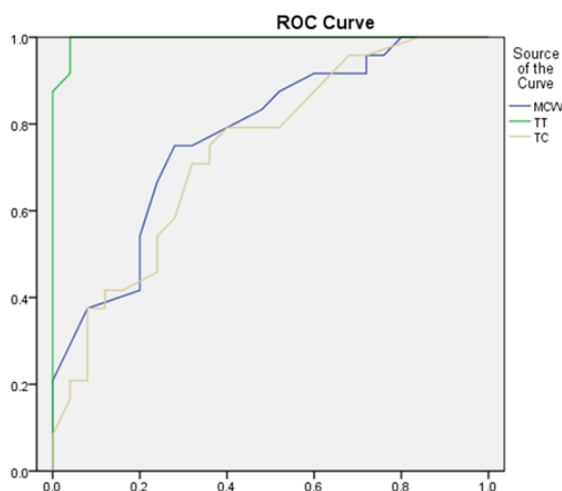


**Figure 3:** The relationship between bone mineral density (based on two groups: osteopenia & OP) and mandibular cortical index (MCI) in three classes (1, 2 & 3)

The T-test represented a significant relationship between age and panoramic MCW index with bone mineral density. In other words, in patients with OP,

significantly, the age was higher [Sig (2-tailed) =0.000] and MCW index was lower [Sig (2-tailed) =0.001].

Figure 4 indicates the ROC curve drawn for the calculation of sensitivity and specificity of the MCW index to predict the BMD. As shown in this graph, the highest level of area under the curve (AUC) is related to TT, but MCW index represents closely overlap with TC. This means that MCW is able to predict the rate of BMD in the femur though the bone mineral density in the spine has higher area and thus prediction of OP at the femoral neck is more accurate than lumbar spine. In addition, areas under the ROC curve were 0.773, 0.996, and .0783 for indices of MCW, TT, and TC, respectively.



**Figure 4:** The ROC curve illustrates predictability of mandibular cortical width (MCW) for the bone mineral density; using two types of T score: TC (Cortical bone) for femur and TT (Trabecular bone) for spine.

## Discussion

The results of the present study and several similar recent studies have suggested the relative superiority of radiographic quantitative indices over qualitative ones. [27-30] Because of the menopause in women and the significant impact of this phenomenon on the incidence of OP, most studies of this field such as the current study have been conducted on postmenopausal women, whereas few studies have been carried out on men like the study of Yamada *et al.* in 2015. [10]

One of the reasons causing the absence of certain definition of index as the criteria for prediction of OP based on panoramic radiography is the variety of indices used by researchers in this field. As previously mentioned, MCW and MCI seems to be the most practical

indices to identify patients at risk of OP and osteopenia, nevertheless some investigators used other indices instead of MCW and MCI. Kavitha *et al.* [8] and Koh *et al.* [18] used fractal dimension (FD) in their studies. Kavitha *et al.* [20] has proposed a technique called Support Vector Machine (SVM), which Muramatsu *et al.* [31] has interpreted it as Support Vector Regression (SVR) in a recent research. There are also other studies in which a particular technique has been used in this field such as the application of simple visual estimation (SVE) by Kim *et al.*, [11] relative bone density (RBD) by Bozic and Ihan Hren [16] and mandibular cortical shape index by Al-Dam *et al.* [17]

As seen, in addition to the researchers' disagreement over the selection of unique index in this field in dental radiographies, some researchers are currently seeking the new indices. However, Muramatsu *et al.* [31] have recently introduced mandibular cortical degree (MCD) index for the first time in this regard. Panoramic radiography is still used as a routine diagnostic tool in dental treatments of population prone to OP (elderly), whereas Gomes *et al.* [12] have indicated no significant difference between cone-beam computed tomography (CBCT) and panoramic technique in patients with low BMD.

The present results have shown a significant relationship of MCW and almost significant correlation of MCI with OP, but it seems that using MCW because of being quantitative is more practical to compare with numbers related to BMD. Moreover, Kavitha *et al.* [19] and Nagi *et al.* [9] in their studies explicitly expressed that there was a higher practical relationship between MCW and OP. However, Mansour *et al.*, [13] Bodade and Mody, [14] and Khojastehpour *et al.* [22] have emphasized MCI as more practical index in this field. Researchers such as Johari Khatoonabad *et al.* [21] and Roberts *et al.* [15] also considered the combination of qualitative and quantitative indicators more practical for comparison with OP.

Statistical approach with comparable index (CI) is one of the factors that seem to affect the heterogeneity of findings related to such studies. This means that the researchers used different statistical concepts for this comparison. In the present study similar to those of Nagi *et al.* [9] Mansour *et al.*, [13] and Bodade and Mody, [14] the significant associations were found be-

tween MCW and loss of natural teeth with OP using correlation coefficients. Nevertheless, Kavitha *et al.* [8] assessed accuracy, Mansour *et al.* [13] determined repeatability, and Khojastehpour *et al.* [22] evaluated sensitivity and specificity in this area. As mentioned before, the various statistical approaches to this comparison make it difficult to summarize the results of different studies in this area. A group of researchers such as Yamada *et al.* [10] and Martínez-Maestre *et al.* [7] have considered the occurrence of bone fractures as serious complication of OP and actually regarded as outcome.

Specific finding of the present study was the overlap among the results of MCW index and BMD in the femoral region of patients, which is inconsistent with the results of two studies by Mansour *et al.* [13] and Kavitha *et al.* [19]. In other words, the researchers have found a higher significant relationship between the MCW and MCI indices with the bone mineral density of lumbar spine compared to the femur, respectively. In the current study, the ROC curve was used to compare the MCW with two mentioned types of BMD. Roberts *et al.* [15] stated the value of 0.8 (80%) for the area under ROC curve to identify OP at the femoral neck, which was obtained 0.783 in the present study.

The limitation of some studies like the present research is the cross-sectional measurement of changes in panoramic radiography indices, while the changes of these indices in patients with OP should be measured in long-term studies. The results of a meta-analysis conducted by Irani *et al.* [32] have indicated that OP and osteopenia are common problems in the population over 30 years in Iran and the increasing prevalence of these disorders in recent years will turn them into a public health crisis in Iran in the near future.

In many patients, OP may not be diagnosed due to the lack of typical symptoms, unless their disease leads to the complication of bone fracture. Therefore, triage of these patients for referral and appropriate treatment by specialist physicians can prevent the occurrence of the adverse effects of OP, and dentists can play an important role in the triage via doing the routine radiographies. [33]

## Conclusion

The present study concludes that the combination of femoral neck BMD and MCW (a quantitative based

index) contributes a good assessment of OP. Postmenopausal women with low femoral BMD have thinner mandibular cortex at the mental foramen region and are more susceptible to femoral neck fractures. Hence, dental panoramic radiographs serve as a useful screening tool for postmenopausal osteoporotic patients, give sufficient information to make an early diagnosis and prevent from osteoporotic fractures in elderly women. A larger sample size study is required to confirm the results of this study.

## Acknowledgment

The authors would like to thank Kerman University of Medical Sciences for financial support (Research No: 95/132). This paper has been written from thesis number 904 of Kerman Dental School. The authors declare that there is no conflict of interests.

## Conflict of Interest

The authors disclose no potential conflicts of interest.

## References

- [1] Guiglia R, Di Fede O, Lo Russo L, Sprini D, Rini GB, Campisi G. Osteoporosis, jawbones and periodontal disease. *Med Oral Patol Oral Cir Bucal.* 2013; 18: e93-e99.
- [2] Esfahanian V, Shamami MS, Shamami MS. Relationship between osteoporosis and periodontal disease: review of the literature. *J Dent (Tehran).* 2012; 9: 256-264.
- [3] Gaur B, Chaudhary A, Wanjari PV, Sunil M, Basavaraj P. Evaluation of panoramic Radiographs as a Screening Tool of Osteoporosis in Post Menopausal Women: A Cross Sectional Study. *J Clin Diagn Res.* 2013; 7: 2051-2055.
- [4] Gulati M, Anand V, Jain N, Anand B, Bahuguna R, Govila V, et al. Essentials of periodontal medicine in preventive medicine. *Int J Prev Med.* 2013; 4: 988-994.
- [5] Dagistan S, Bilge OM. Comparison of antegonial index, mental index, panoramic mandibular index and mandibular cortical index values in the panoramic radiographs of normal males and male patients with osteoporosis. *Dentomaxillofac Radiol.* 2010; 39: 290-294.
- [6] Bhatnagar S, Krishnamurthy V, Pagare SS. Diagnostic efficacy of panoramic radiography in detection of osteoporosis in post-menopausal women with low bone mineral density. *J Clin Imaging Sci.* 2013; 3: 23.
- [7] Martínez-Maestre MÁ, González-Cejudo C, Machuca G,

- Torrejón R, Castelo-Branco C. Periodontitis and osteoporosis: a systematic review. *Climacteric*. 2010; 13: 523-529.
- [8] Kavitha MS, An SY, An CH, Huh KH, Yi WJ, Heo MS, et al. Texture analysis of mandibular cortical bone on digital dental panoramic radiographs for the diagnosis of osteoporosis in Korean women. *Oral Surg Oral Med Oral Pathol Oral Radiol*. 2015; 119: 346-356.
- [9] Nagi R, Devi B K Y, Rakesh N, Reddy SS, Santana N, Shetty N. Relationship between femur bone mineral density, body mass index and dental panoramic mandibular cortical width in diagnosis of elderly postmenopausal women with osteoporosis. *J Clin Diagn Res*. 2014; 8: ZC36-ZC40.
- [10] Yamada S, Uchida K, Iwamoto Y, Sugino N, Yoshinari N, Kagami H, et al. Panoramic radiography measurements, osteoporosis diagnoses and fractures in Japanese men and women. *Oral Dis*. 2015; 21: 335-341.
- [11] Kim OS, Shin MH, Song IH, Lim IG, Yoon SJ, Kim OJ, et al. Digital panoramic radiographs are useful for diagnosis of osteoporosis in Korean postmenopausal women. *Gerodontology*. 2016; 33: 185-192.
- [12] Gomes CC, de Rezende Barbosa GL, Bello RP, Bóscolo FN, de Almeida SM. A comparison of the mandibular index on panoramic and cross-sectional images from CBCT exams from osteoporosis risk group. *Osteoporos Int*. 2014; 25: 1885-1890.
- [13] Mansour S, AlGhamdi AS, Javed F, Marzouk H, Khan EA. Panoramic radiomorphometric indices as reliable parameters in predicting osteoporosis. *Am J Med Sci*. 2013; 346: 473-478.
- [14] Bodade PR, Mody RN. Panoramic radiography for screening postmenopausal osteoporosis in India: a pilot study. *Oral Health Dent Manag*. 2013; 12: 65-72.
- [15] Roberts MG, Graham J, Devlin H. Image texture in dental panoramic radiographs as a potential biomarker of osteoporosis. *IEEE Trans Biomed Eng*. 2013; 60: 2384-2392.
- [16] Božič M, Ihan Hren N. A novel method of dental panoramic tomogram analysis: a perspective tool for a screening test for osteoporosis. *J Craniomaxillofac Surg*. 2013; 41: 808-815.
- [17] Al-Dam A, Blake F, Atac A, Amling M, Blessmann M, Assaf A, et al. Mandibular cortical shape index in non-standardised panoramic radiographs for identifying patients with osteoporosis as defined by the German Osteology Organization. *J Craniomaxillofac Surg*. 2013; 41: e165-e169.
- [18] Koh KJ, Park HN, Kim KA. Prediction of age-related osteoporosis using fractal analysis on panoramic radiographs. *Imaging Sci Dent*. 2012; 42: 231-235.
- [19] Kavitha MS, Samopa F, Asano A, Taguchi A, Sanada M. Computer-aided measurement of mandibular cortical width on dental panoramic radiographs for identifying osteoporosis. *J Invest Clin Dent*. 2012; 3: 36-44.
- [20] Kavitha MS, Asano A, Taguchi A, Kurita T, Sanada M. Diagnosis of osteoporosis from dental panoramic radiographs using the support vector machine method in a computer-aided system. *BMC Med Imaging*. 2012; 12: 1.
- [21] Johari Khatoonabad M, Aghamohammadzade N, Taghilu H, Esmaeili F, Jabbari Khamnei H. Relationship Among Panoramic Radiography Findings, Biochemical Markers of Bone Turnover and Hip BMD in the Diagnosis of Postmenopausal Osteoporosis. *Iran J Radiol*. 2011; 8: 23-28.
- [22] Khojastehpour L, Afssa M, Dabbaghmanesh MH. Evaluation of Correlation between Width and Morphology of Mandibular Inferior Cortex in Digital Panoramic Radiography and Postmenopausal Osteoporosis. *Iran Red Crescent Med J*. 2011; 13: 181-186.
- [23] Watanabe PC, Dias FC, Issa JP, Monteiro SA, de Paula FJ, Tioffi R. Elongated styloid process and atheroma in panoramic radiography and its relationship with systemic osteoporosis and osteopenia. *Osteoporos Int*. 2010; 21: 831-836.
- [24] Iwamoto Y, Uchida K, Sugino N, Kuroiwa H, Kitamura Y, Udagawa N, et al. Osteoporosis, osteoporotic fractures, and carotid artery calcification detected on panoramic radiographs in Japanese men and women. *Oral Surg Oral Med Oral Pathol Oral Radiol*. 2016; 121: 673-680.
- [25] Cakur B, Sahin A, Dagistan S, Altun O, Caglayan F, Miloglu O, et al. Dental panoramic radiography in the diagnosis of osteoporosis. *J Int Med Res*. 2008; 36: 792-799.
- [26] Calciolari E, Donos N, Park JC, Petrie A, Mardas N. Panoramic measures for oral bone mass in detecting osteoporosis: a systematic review and meta-analysis. *J Dent Res*. 2015; 94(3 Suppl): 17S-27S.
- [27] Aggarwal A, Panat SR. Identification of postmenopausal women at risk of osteoporosis using panoramic and intraoral radiographs- a review. *Minerva Stomatol*. 2012; 61: 323-328.

- [28] Alapati S, Reddy RS, Tatapudi R, Kotha R, Bodu NK, Chennaju S. Identifying risk groups for osteoporosis by digital panoramic radiography. *Contemp Clin Dent*. 2015; 6(Suppl 1): S253-S257.
- [29] Richa RY, Puranik MP, Shrivastava A. Association between osteoporosis and periodontal disease among postmenopausal Indian women. *J Investig Clin Dent*. 2017; 8: doi: 10.1111/jicd.12223.
- [30] Penoni DC, Leão AT, Fernandes TM, Torres SR. Possible links between osteoporosis and periodontal disease. *Rev Bras Reumatol*. 2016: pii: S0482-5004(16)00028-0. doi: 10.1016/j.rbr.2015.12.002.
- [31] Muramatsu C, Horiba K, Hayashi T, Fukui T, Hara T, Katsumata A, et al. Quantitative assessment of mandibular cortical erosion on dental panoramic radiographs for screening osteoporosis. *Int J Comput Assist Radiol Surg*. 2016; 11: 2021-2032.
- [32] Irani AD, Poorolajal J, Khalilian A, Esmailnasab N, Cheraghi Z. Prevalence of osteoporosis in Iran: A meta-analysis. *J Res Med Sci*. 2013; 18: 759-766.
- [33] Taguchi A. Triage screening for osteoporosis in dental clinics using panoramic radiographs. *Oral Dis*. 2010; 16: 316-327.