

## Unusual markings on an intraocular lens postoperatively

Dear Editor,

The clear refractive surface of intraocular lenses (IOLs) may be clouded by inflammatory deposits, cells (posterior capsular opacification) or denaturation of the lens material itself. Our patient had highly unusual deposits on the lens postoperatively. Several factors causing opacification of intraocular lenses are discussed.

A 50-year-old lady had painless, progressive diminution of vision and sensation of glare since eight years. She had bilateral, small, central posterior subcapsular cataracts of Grade 2 density. Her best corrected visual acuity was 20/80 and 20/40, respectively. Fundii were normal. She underwent phacoemulsification surgery in her right eye and a foldable IOL, Aquafold (model CB F32 UVA, Omni Lens Pvt. Ltd.) was implanted through its circular plastic cartridge.

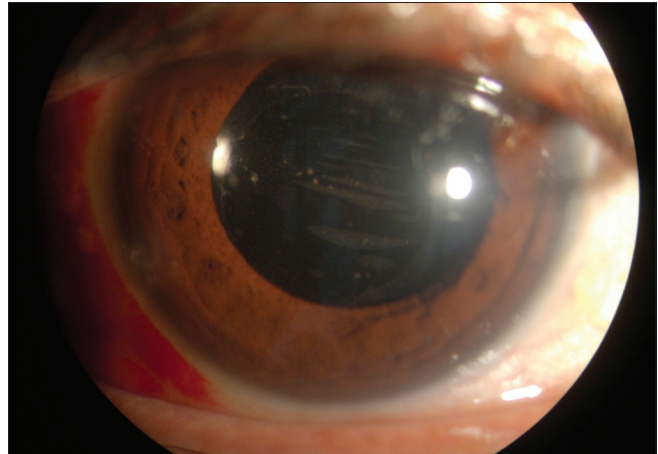
On the first postoperative day, the patient had significant anterior chamber reaction, with Grade 4+ cells and trace hypopyon. The cornea was clear. Her vision was 20/40. The fundus appeared normal. The reaction subsided with medication, over a period of two to three days, with cells decreasing to 2+ with no hypopyon. At this stage, seven to nine thin, elongated, oval-shaped markings were clearly noticeable on the posterior surface of the lens optic. These were between 3-7 mm long, about 1-3 mm wide, and arranged parallel to one another [Fig. 1] in a horizontally slanting direction across the back surface of the optic. These lines were perpendicular to the direction of the lens folding in the cartridge, not along it. These were not typical scratch marks or folding lines. They appeared to be deposits. Unlike typical inflammatory deposits which tend to be scattered and diffuse, they had a precise linear arrangement.

At one-month follow-up, these markings on her lens persisted, unchanged. Her BCVA was 20/25. However, at a fourth-month follow-up visit, there was no trace left of these deposits/lines. They had disappeared totally [Fig. 2].

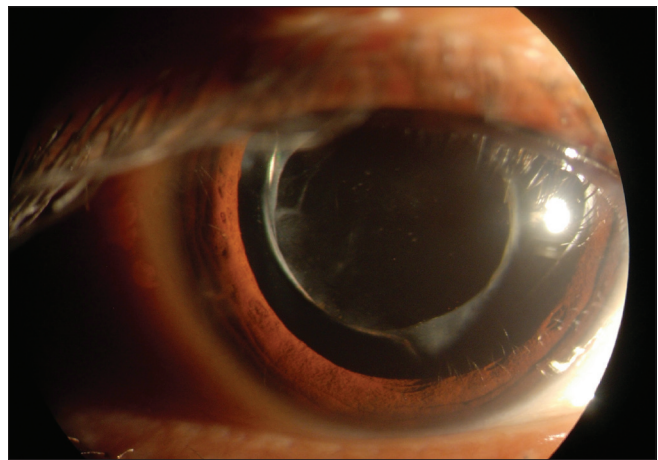
Postoperative causes of opacification include inflammatory/fibrin deposits and posterior capsular opacification. Lenticular deposits may occur in predisposed eyes; such as those with asteroid hyalosis<sup>[1]</sup> or uveitis, or in otherwise healthy eyes which have undergone routine cataract surgery. This may be due to an inherent problem with the lens material itself or the structure or composition of the lens injector used.<sup>[2-4]</sup> Intraocular lens deposits have been well studied and classified by some.<sup>[5]</sup>

In instances where the lens deposits interfere with vision significantly, the lens needs explantation. Such explanted lenses have been studied using methods like staining, transmission electron microscopy and elemental analysis. In almost all cases, the deposits were found to be calcium salts.<sup>[2,3,5]</sup>

The deposits in our patient did not fit clearly into any of the described categories. The lens markings were perpendicular to the direction of the folded lens in the injector barrel making this an unlikely cause. The deposits may have been inflammatory in nature or a very low-grade toxic anterior segment syndrome.



**Figure 1:** Unusual parallel markings on the posterior surface of the intraocular lens seen postoperatively



**Figure 2:** Clear lens surface at four months' follow-up: Complete disappearance of posterior surface markings

However, inflammatory deposits are rarely ever found in such precise parallel lines and they usually either disappear in a few days after anti-inflammatory medication or form permanent membranes. It is possible that some viscoelastic/ethylene oxide (ETO) residue remained on parts of the lens surface and these areas then became a nidus for a mild secondary calcification. In this case their disappearance is most unusual.

### Acknowledgments

Dr. Rajeev Sudan for sharing his perspectives on the topic.

**Anjali Mehta**

Vasundhara Eye Clinic, Dwarka, New Delhi, India.

Correspondence to: Dr. Anjali Mehta,  
B-119, Sarvodaya Enclave, New Delhi – 110 017, India.  
E-mail: mehtanjali@gmail.com

### References

1. Foot L, Werner L, Gills JP, Shoemaker PW, Philips PS, Mamalis N.

- Surface calcification of silicon plate intraocular lenses in patients with asteroid hyalosis. *Am J Ophthalmol* 2004;137:979-87
- Altaie RW, Costigan T, Donegan S, O'Brien P, Mahmood U, Bogdan AJ, *et al.* Investigation and management of an epidemic of Hydroview intraocular lens opacification. *Graefes Arch Clin Exp Ophthalmol* 2005;243:1124-33.
  - Neuhan IM, Werner L, Izak AM, Pandey SK, Kleinman G. Late postoperative opacification of a hydrophilic acrylic (hydrogel) lens: A clinicopathological analysis of 106 implants. *Ophthalmology* 2004;111:1965-6.
  - Kleinman G, Marcovich AL, Apple DJ, Mamalis N. Linear deposits on the surface of intraocular lenses implanted through a hexagonal cartridge which mimic scratches/cracks on the lenses. *Br J Ophthalmol* 2005;89:1474-7.
  - Neuhann IM, Kleinman G, Apple DJ. A new classification of calcification of intraocular lenses. *Ophthalmology* 2008;115:73-9.

**Access this article online**

<b>Quick Response Code:</b>	<b>Website:</b> www.ijo.in
	<b>DOI:</b> 10.4103/0301-4738.95887