

## Original Article

# Hearing Outcome After Linear Accelerator–Based Radiotherapy for Vestibular Schwannomas: A Retrospective Analysis of a Single Center

Dominique Valérie Clarence de Jel<sup>1</sup>, Ernst J. Smid<sup>2</sup>, Tristan P.C. van Doormaal<sup>3</sup>,  
Hans G.X.M. Thomeer<sup>1</sup>

<sup>1</sup>Department of Otorhinolaryngology, Head and Neck Surgery, University Medical Center Utrecht, Utrecht, The Netherlands

<sup>2</sup>Department of Radiation Oncology, University Medical Center Utrecht, Utrecht, The Netherlands

<sup>3</sup>Department of Neurosurgery, University Medical Center Utrecht, Utrecht, The Netherlands

ORCID IDs of the authors: DVC de J. 0000-0001-8159-0089; E.J.S. 0000-0001-9652-0657; T.P.C.van.D. 0000-0002-6299-3859; H.G.X.M.T. 0000-0003-0937-6189

Cite this article as: de Jel DVC, Smid EJ, van Doormaal TPC, Thomeer HGXM. Hearing outcome after linear accelerator-based radiotherapy for vestibular schwannomas: A retrospective analysis of a single center. *J Int Adv Otol.* 2021; 17(5): 426–432.

**OBJECTIVE:** To report our results on hearing preservation after linear accelerator (LINAC)-based stereotactic radiotherapy for vestibular schwannomas (VS) in a tertiary referral center.

**METHODS:** All patients who presented with VS in our center between 2010 and 2018 and who were treated with LINAC-based radiotherapy were retrospectively analyzed. Pure tone average and speech discrimination score represented hearing outcome, pre- and post-radiotherapy. A Gardner-Robertson grade I or II hearing represented functional hearing.

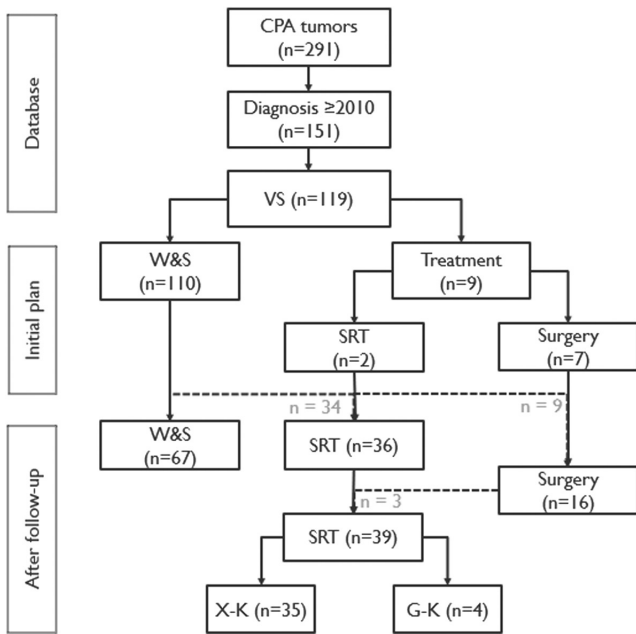
**RESULTS:** In total, 35 patients were treated with LINAC-based radiotherapy. Median age was 55 years (range 18–86 years), 22 (63%) were female. Sixteen patients had a Koos grade III or IV tumor. Twenty-four patients were treated with radiosurgery (1 or 5 fractions; stereotactic radiosurgery), and eleven patients were treated with fractionated stereotactic radiotherapy. Mean follow-up was 4.8 years (range 1.8–8.4 years). In 34 patients, hearing was assessed pre- and post-radiotherapy. In seventeen patients, hearing remained stable. In eleven patients, a decrease in GR scale was observed, of which seven patients showed a decrease from a functional to a non-functional level (4 GR III, 2 GR IV, and 1 GR V). Tumor control was 95% (34/35), and except for hearing loss, all post-radiation complications and morbidity were transient.

**CONCLUSION:** These data emphasize that although the rate of tumor control (the primary goal of radiotherapeutic treatment) is high, it is important to adequately manage patients' expectations regarding the outcomes of the secondary possibly positive outcome; hearing preservation.

**KEYWORDS:** Acoustic neuroma, clinical audit, hearing loss, radiotherapy

## INTRODUCTION

Tumors in the cerebellopontine angle (CPA) predominantly (~85%) consist of benign schwannomas, originating from the vestibular nerve. The incidence is estimated around 1–2 per 100 000 per year and seems to be increasing.<sup>1</sup> In most of these patients, the diagnosis is based on complaints of progressive unilateral hearing loss and tinnitus.<sup>2,3</sup> The minority of these patients report concomitant problems with equilibrium or instability.<sup>2</sup> In the literature, there is controversy regarding the correlation between the tumor size and the amount of hearing loss.<sup>3,4</sup> The treatment of these tumors depends, among others, on the size, clinical symptoms, patient characteristics (age, comorbidity, previous treatment, etc.), and patients' wishes. For the last two decennia, treatment protocols are guiding the clinicians merely toward a conservative approach, whereas in the era before that, surgical treatment was the mainstay of treatment.<sup>5</sup> Recent insights show the rather indolent character of these tumors, with no growth (in 50% of cases) or stabilization of growth during follow-up. This makes treatment unnecessary on the long term in around 80% of these patients.<sup>6,7</sup> However, in particular, vestibular schwannomas (VS) with extra meatal extension do grow especially in the first five years.<sup>8</sup>



**Figure 1.** Flowchart of treatment plan for the patients with vestibular schwannoma. The dotted arrows and the gray numbers represent the patients with an altered treatment plan. CPA, cerebellopontine angle; VS, vestibular schwannoma; W&S, wait-and-scan policy; SRT, stereotactic radiotherapy; X-K, LINAC based radiotherapy; G-K, gammaknife radiosurgery.

Radiotherapy has emerged as a viable treatment option since its introduction in 1951. If growth occurs, patients undergo radiotherapy to attain tumor control of different sizes of lesions without the need for surgery.<sup>5,9,10</sup> Fractionating regimens are reserved for larger tumors with risk for brain stem compression due to post-radiation edema. For smaller growing tumors, single fraction regime is preferred. Nevertheless, lifelong follow-up remains necessary for these patients. After gross total to total tumor resection, there might not be an indication for lifelong follow-up after postoperative control imaging. Furthermore, there is still an ongoing debate regarding the long-term preservation of hearing<sup>6,7,9</sup>: does radiation therapy interrupt the progressive perceptible hearing deterioration? The mentioned publications concerning this topic lack sufficient information

to properly conclude whether hearing preservation was due to different inclusion criteria or due to the retrospective nature of the studies. This cohort study aims to report on the hearing preservation of VS patients treated with radiotherapy in our tertiary referral center.

**MATERIALS AND METHODS**

**Study Population**

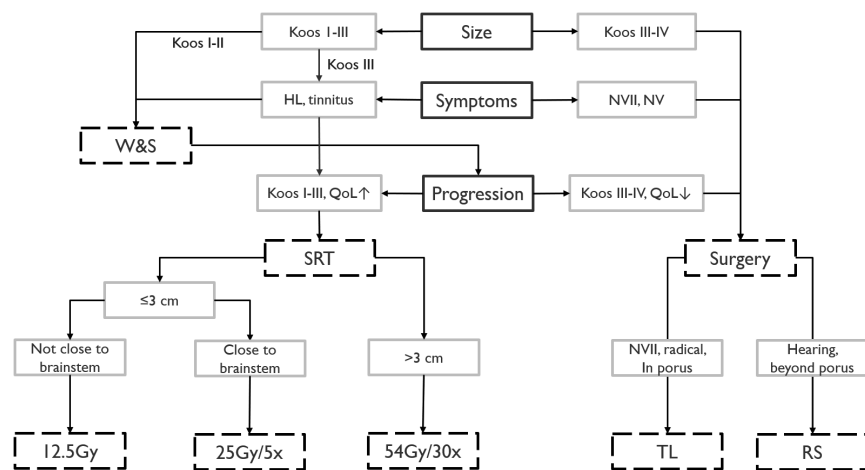
The data of patients diagnosed with a lesion in the CPA region in our tertiary referral center between 2010 and 2018 were retrieved (Figure 1). Exclusion criteria were skull base tumors not in the CPA (1), tumors other than VS (2), patients diagnosed and/or treated before 2010 (3), patients not treated with a form of linear accelerator (LINAC)-based stereotactic radiotherapy (SRT) in our center (4), and the lack of pre- or post-radiation radiologic evaluation (5). In our tertiary referral center, decision making for patients with a CPA tumor is done by a multidisciplinary team including a neurosurgeon, a radiation oncologist, a neurotologist-ENT surgeon, and a radiologist. According to the different patient and tumor characteristics, either wait-and-scan (W&S) follow-up or treatment is advised (radiation and/or microsurgical resection; Figure 2).

**Data Collection and Analysis**

Demographics and clinical and radiologic characteristics were retrieved from patients’ charts. We conducted this retrospective chart study in accordance with the Declaration of Helsinki guidelines.<sup>11</sup> Our Medical Ethic Committee approved that the Medical Research Involving Human Subjects Act (WMO) was not applicable to this study and approved the concept (reference number 19-216/C). Data collection and statistical analyses were performed according to the standards with SPSS software (Version 25, IBM Corp., Armonk, NY, USA).

**Tumor Dynamics**

The Koos classification<sup>12</sup> was used to grade the tumors. According to this classification, a grade I tumor is intracanalicular, grade II protrudes into the CPA, grade III touches the brainstem, and grade IV also displaces the brainstem and shifts the fourth ventricle.<sup>12</sup> According



**Figure 2.** Treatment algorithm used as guideline in the UMC Utrecht for patients with vestibular schwannoma in the cerebellopontine angle. RT performed in the UMC Utrecht is LINAC based. HL, hearing loss; W&S, wait-and-scan; QoL, quality of life; SRT, radiotherapy (LINAC based); Gy, cumulative doses in Gray; TL, translabyrinthine approach; RS, retrosigmoid approach.

to the Consensus Meeting in 2003,<sup>13</sup> the tumor diameter and tumor volumes were retrieved by manual measurements and delineation. This was done using neuronavigation (Brainlab, Munich, Germany) on the contrast-enhanced T1 with gadolinium or T2 of the magnetic resonance imaging. Tumor volumes were used as they are a more accurate measure of growth than two-dimensional measures.<sup>14,15</sup> Planning was performed on axial, coronal, and sagittal images. Pre-SRT tumor volumes (cm<sup>3</sup>) of the radiation planning were used to check accuracy of the manual delineation with Brainlab. Thereafter, several random pre-SRT volumes were checked with Brainlab. All tumor volume calculations were performed by one researcher to avoid systematic errors. Conflicts were resolved by consultation of a radiation oncologist (ES). Inaccuracies of ~13% have been reported in manually delineated versus known tumor volumes. Therefore, volume changes of more than 13% were labeled as progression or decrease.<sup>15</sup> If growth stabilized within the 13% changes, this was labeled as "tumor control."

**Hearing Performance**

Pure tone audiometry was performed according to ISO standards using Decos Audiology software (Decos systems BV, Noordwijk, the Netherlands) in a soundproof cabin. They were retrieved at two moments: closest before the start of SRT and at the latest follow-up. The pure tone average (PTA) and speech discrimination score (SDS) were collected. The PTA in decibel hearing loss (dB HL) was calculated by dividing the sum of dB HL measured at 0.5, 1, 2, and 4 kHz by 4, according to the internationally followed AAO-HNS 1995 guidelines.<sup>16</sup> Hearing performance was assigned to grades I-V according to the Gardner-Robertson (GR) scale.<sup>17</sup> GR grades I-II represent a functional hearing (good to serviceable), grades III-IV represent a non-serviceable hearing, and grade V is classified as deaf. Stable hearing or any variation that stayed within the same GR grade was scored as hearing preservation. If the PTA and SDS lacked pre-SRT, and the patient did not experience hearing loss, hearing performance was scored as serviceable (GR I-II). If a patient had a GR grade V hearing pre-SRT, a post-SRT hearing assessment would be unnecessary, and the pre-SRT score was adopted.

**RESULTS**

**Inclusion**

We identified a total of 151 patients diagnosed with a lesion in the CPA region between 2010 and 2018. Eighty percent of these patients (n= 119) were diagnosed with VS. In total, 35 patients were treated with LINAC-based stereotactic radiation therapy. Two patients underwent immediate radiotherapy because of large tumor volumes at presentation, 34 patients because of growth and/or progression of symptoms during their W&S policy, and three after previous surgery (Figure 1). Four patients who underwent Gamma Knife Radiosurgery elsewhere were excluded.

**Patient Characteristics**

Patients' age ranged between 18 and 86 years (median 55 years), and 63% were female (Table 1). Most patients presented with one or more symptoms, in most cases, unilateral hearing loss (91%), tinnitus (57%), and/or vertigo (40%). Facial nerve dysfunction was a presenting symptom in 3 patients with a Koos grade I tumor — House-Brackmann (HB) grade III in two patients and HB V in one patient. Two

**Table 1.** Overview of Patient, Tumor, and Radiotherapy Characteristics of All Patients Treated With LINAC-Based Stereotactic Radiotherapy

Variable	Total RT Patients (n = 151)
Age, Median (range)	55 years (18-86 years)
Categories	Number of patients (%)
Gender	
Male	13 (37%)
Female	22 (63%)
Side	
Left	20 (57%)
Right	15 (43%)
Presenting symptoms	
HL	32 (91%)
Tinnitus	20 (57%)
Vertigo	14 (40%)
N. VII dysfunction*	3 (9%),* 2 HB III and 1 HB V
Koos grade	
I	6 (17%)
II	13 (37%)
III	6 (17%)
IV	10 (29%)
Aspect	
Homogeneous	23 (66%)
Cystic	9 (26%)
Necrotic	1 (3%)
Heterogeneous, other	2 (6%)

HB, House-Brackmann scale; HL, hearing loss; LINAC, linear accelerator; RT, radiotherapy.

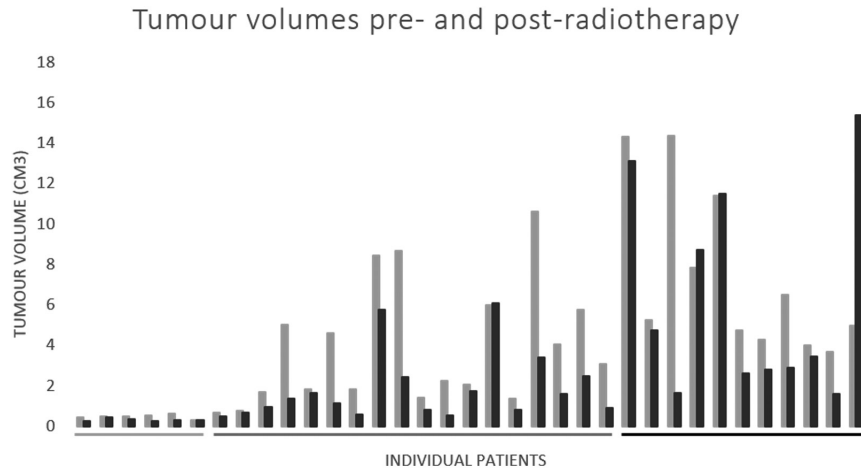
of these patients reported hearing loss, confirmed on audiogram in one patient. Sixteen patients had a Koos grade III or IV tumor.

**Radiotherapy**

Eight patients with small VS (median tumor volume 0.52 cm<sup>3</sup>) were treated with a single stereotactic radiosurgery (SRS) fraction of 12.5 Gy. Sixteen patients with VS up to 3 cm though in proximity to the brainstem were treated with a hypo-fractionated SRS schedule of 5 times 5 Gy. Eleven patients with larger VS (median tumor volume 5.26 cm<sup>3</sup>) were treated with a fractionated radiotherapy scheme of 30 times 1.8 Gy. The treatment modalities were in accordance with our treatment algorithm (Figure 2). The median time between diagnosis and start of radiation therapy was eighteen months (range 0 months to 7.3 years). The overall follow-up duration was 22 months to 8.4 years with a mean of 4.8 years.

**Tumor Dynamics**

Tumor volumes pre-radiation therapy were a median of 3.8 cm<sup>3</sup> (range 0.3-14.3cm<sup>3</sup>). In Koos grades I to IV, the proportions were 17%, 37%, 17%, and 29%, respectively (Table 1). Before treatment, most tumors were homogeneous (66%). After treatment, the median tumor volume was 1.6 cm<sup>3</sup> with a range of 0.3-15.4 cm<sup>3</sup>. A radiologic response was seen in 25 patients (71%), mostly specified as necrosis. Tumor dynamics (Figure 3, Supplementary Table S1) show a decrease in volume in all except one patient during a median follow-up of 3.3 years



**Figure 3.** Tumor volumes of all individual patients (n=35) treated with (fractionated) stereotactic radiotherapy (SRS/fSRT), in order of cumulative doses (Gy), f.l.t.r. 12.5 Gy, 25 Gy, and 54 Gy. Median follow-up was 3.3 years after SRT, range 2 months to 7.1 years. fSRT, Fractionated stereotactic radiotherapy; SRS, stereotactic radiosurgery.

(range 2 months to 7.1 years). Tumor progression occurred in a patient with a stage IV VS, despite surgical retrosigmoid debulking two years prior, accompanied by obstructive symptoms. Growth was observed at routine follow-up, 3.4 years post-radiotherapy, with 209%, from 5.0 to 15.4 cm. This patient subsequently underwent a surgical debulking with tumor control of a remnant three years postoperative.

**Complications**

The most frequently reported complaints during and directly after radiation therapy were headache (n=9) and vertigo (n=6) due to transient edema and swelling, treated with dexamethasone in seven patients. Other complaints were hearing loss (n=5), worsening of tinnitus (n=4), and facial palsy (NVII) dysfunction (HB II, III, and IV) in three patients. Except for the hearing loss, all complaints were transient.

**Hearing Performance**

Subjective hearing loss was reported in 91% of the patients of which 80% had objective good to serviceable hearing (GR I-II). In 34 of the 35 patients, hearing performance was assessed. The mean SDS and PTA before RT were 71% (range 0-100) and 64 dB HL (range 15-120), respectively. After RT, the mean SDS and PTA were 59% (range 0-100) and 78 dB HL (range 20-120), respectively. Based on the SDS (%),

27 of the 34 patients (79%) had serviceable hearing (GR grades I and II) before RT on the affected side. Hearing was preserved in 16 of these 27 patients (59%) during follow-up (Table 2). In nine patients (one-third of the 27 patients), hearing decreased with one or more GR grade(s). Two patients decreased from a GR grade I to a GR grade II hearing (still serviceable), six to a non-serviceable hearing (four GR III and two GR IV), and one patient became deaf (GR V). In the patients with pre-existent non-serviceable hearing (GR III to IV), hearing was preserved in one patient and the other two patients decreased with 1 GR grade. The number of deaf patients (GR V) thereby increased from 3 before RT to 5 at follow-up. In nine patients, hearing performance declined to GR III-V, resulting in non-serviceable hearing in seven patients (35%).

As expected, there was a discrepancy between GR grades based on the SDS and PTA (GR according to PTA > SDS) in twenty patients pre-SRT and fifteen patients post-SRT. In Figure 4, hearing performance is depicted as categorized using GR grades based on the SDS (% 4A) and PTA (dB HL, 4B). Of the patients in which hearing performance was assessed on the control side (n=28), all except for one patient had good hearing (GR I) pre-SRT. This was assessed post-SRT in 21 (75%) of those patients, and no decline was noticed.

**Table 2.** Hearing Performance According to Gardner-Robertson (GR) Grades Based on the Speech Discrimination Score (%) Before and After Radiotherapy

Pre-Radiotherapy		Post-Radiotherapy			
GR Grade	N	Hearing Preserved	GR Increase	GRV (Deaf)	NA
I	22	15	6	1	
II	5	1	2		2**
III	1	0	1	1	
IV	2	1		1	
V	3	-	-	3	

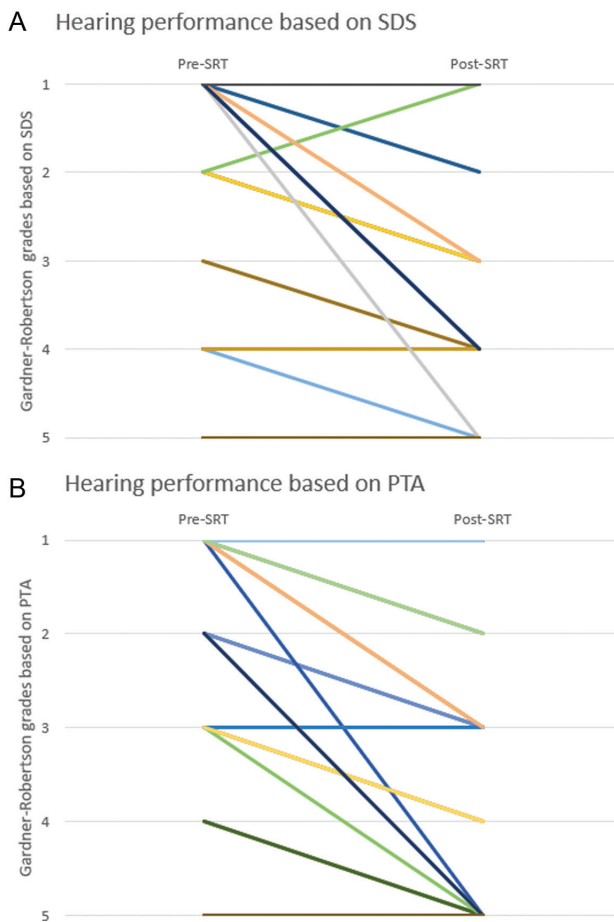
\*\*Hearing performance was not accessed post-radiotherapy as no subjective hearing loss was reported. N, number of patients; NA, not available. GR, Gardner-Robertson scales; N, number of patients; NA, not available.

**DISCUSSION**

Since the conservative approach is the new mainstay where possible, we were left with only 35 patients treated with radiotherapy. In 34 of these patients, hearing was evaluated. In seventeen patients (50%), hearing was preserved. This is comparable to the 58% hearing preservation described in the recent systematic review by Coughlin et al.<sup>18</sup> In eleven patients (~32%), a decrease in GR scale was observed. Of the patients with a decrease, seven showed a decrease from a functional to a non-functional level. However, this was accurately assessed bilaterally in a small subset of patients (Supplementary Tables S1 and S2). Tumor control was 95% (34 of 35 patients), and except for hearing loss, all post-radiation complications and morbidity were transient.

**Hearing Preservation**

Initially, 79% of the patients had pre-RT serviceable hearing. Post-SRT, hearing remained serviceable (GR grades I-II) in eleven patients (55%). In 35% of this subset of patients, loss of serviceable hearing



**Figure 4.** Hearing performance according to the Gardner-Robertson (GR) grades based on the SDS (%), A and PTA (dB HL), B of the affected side for all individual patients pre- and post-radiotherapy. The GR grades are presented for the SDS and PTA separately due to discrepancies in most patients. PTA, Pure tone average; SDS, speech discrimination score.

(GR grades III-V) was confirmed. Due to the incompleteness of the data and selection bias, no strong conclusions can be drawn. Pre-SRT, subjective hearing loss was reported in 91% of the patients. This is frequently reported as total deafness (GR grade V) in a patient’s perspective—in cases with interaural perceptive difference of >30 dB HL (PTA). However, the difference with total objective deafness (i.e., after translabyrinthine surgery) seems to be more cumbersome. In these cases, patients perceive no sound from the treated side, resulting in loss of directional hearing and spatial orientation.<sup>19</sup> This possible side effect should therefore be considered when deciding upon a treatment plan. When hearing preservation is of patient’s utmost importance, radiation therapy with low dose to the cochlea should be considered.<sup>20-22</sup> However, whether this hearing preservation will be maintained in the long run is questionable as hearing clearly decreases after ten years of follow-up.<sup>23-25</sup> This decline is suggested to result from direct cochlear nerve compression by the tumor in the internal acoustic canal resulting in impedance of the auditory nerve. Furthermore, the tumor may interact with the vascularity toward the cochlea, creating an ischemic and toxic micro-environment and causing irreversible perceptive hearing loss.<sup>26</sup> Therefore, in patients with serviceable hearing and a Koos I or II tumor, treatment should only be considered if the tumor continues to grow. Evidence in the literature regarding preventive hearing preservation radiation therapy is

lacking. Future studies should further investigate “preventive and sparing radiotherapy,” before considering this as an alternative treatment option for these situations.<sup>27,28</sup> Most other complications were minor (headache and vertigo) and treatable with dexamethasone. The more major complications such as (worsening of) tinnitus and NVII dysfunction were transient without the need for surgical interventions.

**Treatment Modalities**

Management of VS has evolved over the past century with a clear trend toward a more conservative approach (“watchful waiting”) with a growing focus on minimizing morbidity and mortality.<sup>6,10</sup> Of the observed tumors, 36% (55 of 151 patients) underwent treatment after follow-up (radiation therapy, surgery, or a combination of both). This is somewhat higher than that reported in another large Danish cohort after long-term follow-up, which reported that only 20% eventually opted for treatment.<sup>7</sup> Of note is the long-term follow-up of patients in a large Danish cohort without need for treatment, and thus tumor control, in about 80% of cases.<sup>7,8</sup> As the majority of VS do not grow or rather grow slowly, intervention should be reserved for a small group of patients. This makes observative strategies and otherwise radiation therapy appropriate for small- to medium-sized VS with serviceable hearing, without other cranial nerve neuropathy (Koos I-II).<sup>26,29</sup> In cases without a severe brain stem compression by the tumor and with serviceable hearing (initially 92% in our center) in which treatment indication arise after follow-up (in 40% of our initial W&S group), radiation therapy rather than microsurgery is performed (79% vs 21%). This percentage is in concordance with other groups.<sup>30,31</sup>

**Tumor Control**

Tumor control was achieved in all but one patient in whom the tumor volume increased from 4.89 cm<sup>3</sup> pre-treatment to 15.4 cm<sup>3</sup> at the last post-treatment magnetic resonance imaging, despite radiation therapy. The patient underwent surgical resection before radiation therapy, associated with transient tumor volume increase post-radiation.<sup>32</sup> Despite the value in terms of quality of life and cost-efficacy of radiation therapy, including “watchful waiting” regimen, microsurgical resection remains an important treatment option in selected cases.<sup>8,33</sup> There is evidence showing no clear disadvantage of surgical treatment, after long-term follow-up in quality of life compared to radiation therapy, especially in experienced multidisciplinary surgical teams.<sup>31,34</sup> In patients with (cystic) Koos III and IV VS with cranial nerve neuropathy or compression of the brainstem and/or cerebellum, surgery seems to be the primary choice of treatment. In this population, especially the transient edema and swelling seen in the first six months post-radiation can be accompanied by great risks (brain stem compression and elevated intracranial pressure).<sup>32</sup> Concurrent with the literature, treatment-related side effects were low and, if present, were transient, and tumor control rates were high (~95% vs. 97% in our center).<sup>6,23</sup>

**Differentiation Schwannomas Vestibular Versus Facial Nerve**

Diagnosis of a schwannoma in the CPA is a combined clinical (hearing loss, vestibular complaints, and central nerve system deficits) and radiological assessment. However, after radiological diagnosis based on these magnetic resonance images, it is still unknown whether the nerve of origin is the vestibular nerve. In general, a vestibular nerve schwannoma leads to hearing loss without facial

nerve weakness, even in larger tumors (Koos III and IV). Three of our patients presented with spontaneous facial nerve neuropathy with concomitant vertigo in two cases. These were patients with small VS of 0.5 cm<sup>3</sup>, of which one reported hearing loss with a non-serviceable hearing (GR IV to V). After radiotherapy, all patients reported hearing loss. Unfortunately, in only one patient an audiogram was performed which yielded an SDS of 80% and PTA of 43 dB. Especially in these cases with small tumors and with serviceable hearing (two out of three), indication for radiation therapy might have been reassessed. We hypothesized that these patients suffered from a facial nerve schwannoma rather than the vestibular nerve and should not have undergone radiotherapy to prevent unnecessary hearing loss. As hearing preservation is correlated to the maximal radiation dose at the cochlea<sup>21</sup> and, in these patients, as the cochlea was part of the radiation field, we hypothesized that the reported hearing loss is induced by the radiotherapy.

### Treatment Algorithm

As mentioned earlier, either W&S follow-up or treatment is advised according to the different patient and tumor characteristics. As a result of this study and the insight into the outcomes of all VS over the last eight years, our multidisciplinary team proposed a treatment algorithm to assist in decision making (Figure 2). In our opinion, this serves as a tool for patient and physician guidance in choosing the optimal treatment plan. The outcome of multidisciplinary board meetings is proposed to the patient, and shared decision making is requested. To attain tumor control, radiotherapy is the modality of choice in patients with serviceable hearing and small growing tumors (Koos I or II). Preventive radiotherapy is not standard of care in our opinion.<sup>27,28</sup> Future multicenter studies are necessary to uniformize the international treatment strategy and diminish variation in treatment between different Skull Base centers.

### Limitations

We chose a cut-off due to the absence of the electronic patient records before 2010 to minimize information bias. Especially since the group with a W&S policy has grown tremendously over the past decade, this left us with a small population. In our center, audiometric testing was not always part of standard follow-up. The lack of standardization of the assessment of hearing performance impeded the analysis of hearing preservation in this patient cohort. This selection bias may have caused an under- or overestimation of the hearing loss. To accurately assess the hearing outcomes, future cohort studies with the different treatment modalities should be conducted. Case-control studies with mandatory auditory evaluations in relation to cochlear dose are necessary to further elucidate this challenging topic. Though, especially as the group of VS patients undergoing treatment declines, proposing a multidisciplinary treatment algorithm can guide choosing the optimal treatment plan even in small centers.

### CONCLUSION

Our study emphasizes that although the rate of tumor control (the primary goal of radiotherapeutic treatment) is high, it is rather important to adequately manage patients' expectations regarding the secondary possibly positive outcome, hearing preservation. Furthermore, long-term preservation is still unclear and needs further investigation. No other long-term complications occurred.

**Ethics Committee Approval:** The Medical Ethic Committee of the UMC Utrecht approved that the Medical Research Involving Human Subjects Act (WMO) was not applicable and approved this study (reference number 19-216/C).

**Informed Consent:** Informed Consent was not obligated for participating patients.

**Peer Review:** Externally peer-reviewed.

**Author Contributions:** Concept – D.V.C. de J., E.J.S., T.P.C. van D., H.G.X.M.T.; Design – D.V.C. de J., H.G.X.M.T.; Supervision – E.J.S., T.P.C. van D., H.G.X.M.T.; Materials – D.V.C. de J., E.J.S., T.P.C. van D., H.G.X.M.T.; Data Collection and/or Processing – D.V.C. de J., E.J.S., T.P.C. van D., H.G.X.M.T.; Analysis and/or Interpretation – D.V.C. de J., E.J.S., T.P.C. van D., H.G.X.M.T.; Literature Search – D.V.C. de J., H.G.X.M.T.; Writing – D.V.C. de J., H.G.X.M.T.; Critical Reviews – E.J.S., T.P.C. van D., H.G.X.M.T.

**Acknowledgments:** None.

**Conflict of Interest:** The authors have declared that no conflicts of interest exist.

**Financial Disclosure:** The authors did not receive any funding for this study.

### REFERENCES

1. Marinelli JP, Lohse CM, Carlson ML. Incidence of vestibular schwannoma over the past half-century: a population-based study of Olmsted County, Minnesota. *Otolaryngol Head Neck Surg.* 2018;159(4):717-723.
2. Peris-Celda M, Graffeo CS, Perry A, et al. Main symptom that led to medical evaluation and diagnosis of vestibular schwannoma and patient-reported tumor size: cross-sectional study in 1,304 patients. *J Neurol Surg B Skull Base.* 2019;80(3):316-322.
3. Foley RW, Shirazi S, Maweni RM, et al. Signs and symptoms of acoustic neuroma at initial presentation: an exploratory analysis. *Cureus.* 2017;9(11):e1846.
4. Patel NS, Huang AE, Dowling EM, et al. The influence of vestibular schwannoma tumor volume and growth on hearing loss. *Otolaryngol Head Neck Surg.* 2020;162(4):530-537.
5. Alfaiqi A, Almutairi O, Allhaidan M, Alsaleh S, Ajlan A. The top 50 most-cited articles on acoustic neuroma. *World Neurosurg.* 2018;111:e454-e464.
6. Wolbers JG, Dallenga AHG, Mendez Romero AM, van Linge A. What intervention is best practice for vestibular schwannomas? A systematic review of controlled studies. *BMJ Open.* 2013;3(2).
7. Stangerup SE, Thomsen J, Tos M, Cayé-Thomasen P. Long-term hearing preservation in vestibular schwannoma. *Otol Neurotol.* 2010;31(2):271-275.
8. Stangerup SE, Cayé-Thomasen P, Tos M, Thomsen J. The natural history of vestibular schwannoma. *Otol Neurotol.* 2006;27(4):547-552.
9. Tsao MN, Sahgal A, Xu W, et al. Stereotactic radiosurgery for vestibular schwannoma: International Stereotactic Radiosurgery Society (ISRS) practice guideline. *J Radiosurg SBRT.* 2017;5(1):5-24.
10. Arthurs BJ, Fairbanks RK, Demakas JJ, et al. A review of treatment modalities for vestibular schwannoma. *Neurosurg Rev.* 2011;34(3):265-277; discussion 277-279.
11. The World Medical Association. WMA Declaration of Helsinki: ethical principles for medical research involving human subjects. 2018. Available at: <https://www.wma.net/policies-post/wma-declaration-of-helsinki-ethical-principles-for-medical-research-involving-human-subjects/>, Accessed October 7, 2019.
12. Koos WT, Spetzler R, Bock F. Microsurgery of cerebellopontine angle tumors. *Clin Microneurosurg.* 1976:91-112.

13. Kanzaki J, Tos M, Sanna M, Moffat DA. New and modified reporting systems from the consensus meeting on systems for reporting results in vestibular schwannoma. *Otol Neurotol*. 2003;24(4):642-649.
14. Van De Langenberg R, De Bondt BJ, Nelemans PJ, Baumert BG, Stokroos RJ. Follow-up assessment of vestibular schwannomas: volume quantification versus two-dimensional measurements. *Neuroradiology*. 2009;51(8):517-524.
15. Meijer OWM, Weijmans EJ, Knol DL, et al. Tumor-volume changes after radiosurgery for vestibular schwannoma: implications for follow-up MR imaging protocol. *AJNR Am J Neuroradiol*. 2008;29(5):906-910.
16. American Academy of Otolaryngology-Head and Neck Surgery Foundation, Inc. Committee on Hearing and Equilibrium guidelines for the evaluation of results of treatment of conductive hearing loss. *Otolaryngol Head Neck Surg*. 1995;113(3):186-187.
17. Gardner G, Robertson JH. Hearing preservation in unilateral acoustic neuroma surgery. *Ann Otol Rhinol Laryngol*. 1988;97(1):55-66.
18. Coughlin AR, Willman TJ, Gubbels SP. Systematic review of hearing preservation after radiotherapy for vestibular schwannoma. *Otol Neurotol*. 2018;39(3):273-283.
19. Peters JPM, Van Zon A, Smit AL, et al. CINGLE-trial: cochlear implantation for siNGLE-sided deafness, a randomised controlled trial and economic evaluation. *BMC Ear Nose Throat Disord*. 2015;15:3.
20. Van Linge A, Van Os R, Hoekstra N, et al. Progression of hearing loss after LINAC-based stereotactic radiotherapy for vestibular schwannoma is associated with cochlear dose, not with pre-treatment hearing level. *Radiat Oncol*. 2018;13(1):253.
21. Timmer FCA, Hanssens PEJ, Van Haren AEP, et al. Gamma knife radiosurgery for vestibular schwannomas: results of hearing preservation in relation to the cochlear radiation dose. *Laryngoscope*. 2009;119(6):1076-1081.
22. Patel KS, Ng E, Kaur T, et al. Increased cochlear radiation dose predicts delayed hearing loss following both stereotactic radiosurgery and fractionated stereotactic radiotherapy for vestibular schwannoma. *J Neurooncol*. 2019;145(2):329-337.
23. Mulder JJS, Kaanders JH, Van Overbeek JJ, Cremers CW. Radiation therapy for vestibular schwannomas. *Curr Opin Otolaryngol Head Neck Surg*. 2012;20(5):367-371.
24. Maniakas A, Saliba I. Conservative management versus stereotactic radiation for vestibular schwannomas: a meta-analysis of patients with more than 5 years' follow-up. *Otol Neurotol*. 2012;33(2):230-238.
25. Cohen WA, Albornoz CR, Cordeiro PG, et al. Health-related quality of life following reconstruction for common head and neck surgical defects. *Plast Reconstr Surg*. 2016;138(6):1312-1320.
26. Stangerup SE, Caye-Thomasen P, Tos M, Thomsen J. Change in hearing during 'wait and scan' management of patients with vestibular schwannoma. *J Laryngol Otol*. 2008;122(7):673-681.
27. Taha I, Hyvärinen A, Ranta A, et al. Facial nerve function and hearing after microsurgical removal of sporadic vestibular schwannomas in a population-based cohort. *Acta Neurochir*. 2020;162(1):43-54.
28. Daniel RT, Tuleasca C, Rocca A, et al. The changing paradigm for the surgical treatment of large vestibular schwannomas. *J Neurol Surg B Skull Base*. 2018;79(suppl 4):S362-S370.
29. Hunter JB, Francis DO, O'Connell BP, et al. Single Institutional experience with observing 564 vestibular schwannomas: factors associated with tumor growth. *Otol Neurotol*. 2016;37(10):1630-1636.
30. Mackeith SA, Kerr RS, Milford CA. Trends in acoustic neuroma management: a 20-year review of the Oxford skull base clinic. *J Neurol Surg B Skull Base*. 2013;74(4):194-200.
31. Carlson ML, Tveiten OV, Driscoll CL, et al. Long-term quality of life in patients with vestibular schwannoma: an international multicenter cross-sectional study comparing microsurgery, stereotactic radiosurgery, observation, and nontumor controls. *J Neurosurg*. 2015;122(4):833-842.
32. Hathout L. Transient tumor volume increase in vestibular schwannomas after radiotherapy [epub ahead of print]. *Cureus*. 2012.
33. Gait C, Frew EJ, Martin TPC, Jowett S, Irving R. Conservative management, surgery and radiosurgery for treatment of vestibular schwannomas: a model-based approach to cost-effectiveness. *Clin Otolaryngol*. 2014;39(1):22-31.
34. Robinett ZN, Walz PC, Miles-Markley B, Moberly AC, Welling DB. Comparison of long-term quality-of-life outcomes in vestibular schwannoma patients. *Otolaryngol Head Neck Surg*. 2014;150(6):1024-1032.