

[ CASE REPORT ]

## PaO<sub>2</sub>-guided Low-dose Oxygen Therapy for Pneumatosis Cystoides Intestinalis to Prevent Acute Exacerbation of Interstitial Pneumonia

Noboru Hamada<sup>1</sup>, Takafumi Yamano<sup>1</sup>, Yusaku Tada<sup>1</sup>, Yasuhiro Ooue<sup>2</sup>, Junko Itano<sup>3</sup>,  
Mitsunori Ishiga<sup>2</sup>, Hisaaki Tanaka<sup>2</sup>, Goro Kimura<sup>2</sup> and Yasushi Tanimoto<sup>2</sup>

### Abstract:

We herein report the first case of low-dose oxygen therapy for pneumatosis cystoides intestinalis (PCI) using PaO<sub>2</sub> as a therapeutic index to prevent acute exacerbation of interstitial pneumonia. An 86-year-old man was admitted to our hospital with abdominal distension. PCI was diagnosed by abdominal computed tomography. Low-dose oxygen therapy was started to avoid acute exacerbation of interstitial pneumonia. The oxygen dose was adjusted so that the PaO<sub>2</sub> value was approximately 100 mmHg. After seven days of treatment, the colon gas had disappeared, and no acute exacerbation of interstitial pneumonia was observed. A PaO<sub>2</sub> value around 100 mmHg is effective for PCI without inducing acute exacerbation of interstitial pneumonia.

**Key words:** PaO<sub>2</sub> level, low-dose oxygen therapy, interstitial pneumonia, pneumatosis cystoides intestinalis

(Intern Med 60: 3101-3105, 2021)

(DOI: 10.2169/internalmedicine.7064-21)

### Introduction

Forgacs reported in 1973 that high-dose oxygen therapy is effective for treating pneumatosis cystoides intestinalis (PCI) (1). In that report, the patients required an arterial oxygen concentration of 200 to 300 mmHg. In other cases of PCI with interstitial pneumonia since Forgacs's was first reported (2-6), high-dose oxygen was also administered (Table 1). However, such high-dose oxygen therapy is extremely dangerous, risking the acute exacerbation of interstitial pneumonia. It has been reported that postoperative acute exacerbation of interstitial pneumonia occurred in patient with interstitial pneumonia who underwent surgery due to a high oxygen concentration during surgery (7). There are currently no clear indicators of the oxygen concentration most effective for PCI that carries no risk of causing the acute exacerbation of interstitial pneumonia.

We herein report the optimal dose of oxygen therapy for PCI with interstitial pneumonia.

### Case Report

An 86-year-old man was admitted to our hospital with complaint of right upper abdominal distension. He had a one-year medical history of idiopathic interstitial pneumonia and had been taking prednisolone for the acute exacerbation of interstitial pneumonia (Fig. 1). The patient had developed steroid diabetes six months earlier and been treated with an  $\alpha$ -glucosidase inhibitor for elevated HbA1c four weeks before. A physical examination at admission revealed slight tenderness in the right upper abdomen, but no major problems with other physical findings were observed. Laboratory tests showed a normal inflammatory response with a white blood cell count of 7,400/ $\mu$ L and C-reactive protein level of 0.41 mg/dL. The other laboratory data were almost normal, except for slightly elevated KL-6 value of 629 U/mL and SP-D of 130 ng/mL.

Abdominal radiograph indicated cysts from the ascending to the right-sided transverse colon (Fig. 2A). Abdominal

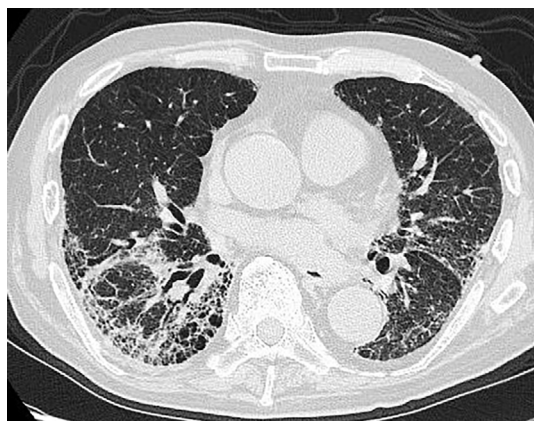
<sup>1</sup>Department of Respiratory Medicine, Okayama City Hospital, Japan, <sup>2</sup>Department of Allergy and Respiratory Medicine, National Hospital Organization, Minami Okayama Medical Center, Japan and <sup>3</sup>Department of Allergy and Respiratory Medicine, Okayama University Hospital, Japan  
Received: January 10, 2021; Accepted: February 21, 2021; Advance Publication by J-STAGE: April 12, 2021

Correspondence to Dr. Noboru Hamada, nobohamada@yahoo.co.jp

**Table 1. Previous Reports of Pneumatosis Cystoides Intestinalis Complicated with Interstitial Pneumonia Treated with High-dose Oxygen Therapy.**

Reference Number	Age/Sex	Oxygen (L/min)	Inhalation Method	PaO <sub>2</sub> (mmHg)	Time (hours/day)	Duration (day)
2.	58/F	5	Nasal	N.D.	5	15
3.	72/M	4	Nasal	N.D.	8	9
4.	49/M	10	Face mask	219	4	14
5.	61/M	6	Face mask	210	6	10
6.	51/M	5	Face mask	N.D.	5	14
Our case.	86/M	2-4	Nasal	114	24	7

PaO<sub>2</sub>: partial pressure of oxygen in arterial blood, F: female, M: male, N.D.: not described



**Figure 1. Chest computed tomography at admission showed linear consolidation around the broncho vascular bundles and the traction bronchiectasis in the bilateral lower lobe.**

computed tomography (CT) revealed no portal venous gas, but there were many linear gas pockets in the colon wall along the lumen gases from the ascending colon to the right transverse colon. In addition, there was also a small amount of free air in the peritoneal cavity (Fig. 2B, C). Because the patient refused to undergo colonoscopy, PCI was diagnosed based on these characteristic abdominal CT findings.

Fasting and fluid replacement were performed, and the  $\alpha$ -glucosidase inhibitor was discontinued for about one week. However, the symptoms persisted and there were no changes on abdominal radiographs (Fig. 3). Therefore, conservative treatment was not expected to improve PCI, low-dose oxygen therapy was started, although high-dose oxygen therapy is generally performed for PCI. To avoid acute exacerbation of interstitial pneumonia, an arterial blood gas analysis was performed twice a day, and the oxygen dose was adjusted to keep the PaO<sub>2</sub> around 100 mmHg. In practice, 2 to 4 L of oxygen was administered for 24 hours, and the PaO<sub>2</sub> level ranged from 114 to 120 mmHg (Table 2).

After seven days of low-dose oxygen treatment, the gas in the intestinal tract had disappeared on abdominal radiography (Fig. 4A) and the abdominal coronal CT (Fig. 4B, C) and the physical examination findings had improved. Oxygen administration was discontinued on the eighth day. On a laboratory examination, during low-dose oxygen therapy, the

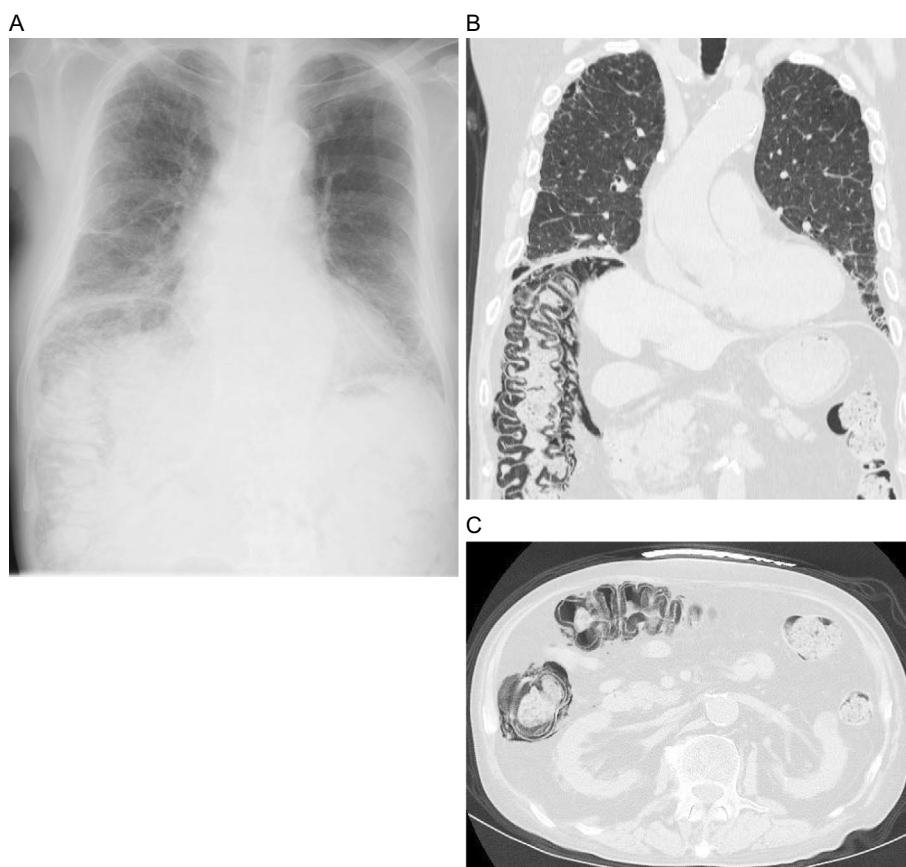
KL-6 and SP-D level increased slightly from 629 to 710 U/mL and 130 to 156 ng/mL, respectively. However, there was no change in the arterial oxygen saturation on room air or subjective symptoms of respiration, and no exacerbation of interstitial pneumonia was observed on chest CT (Fig. 5). The patient has been treated for interstitial pneumonia on an outpatient basis without recurrence of PCI.

## Discussion

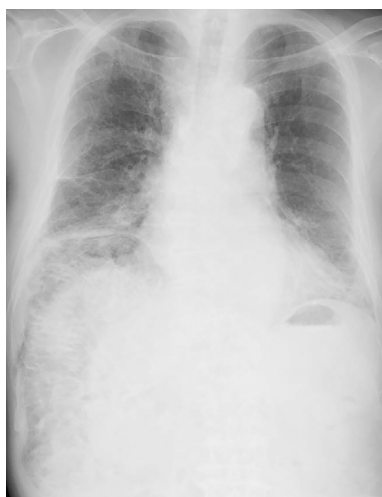
This is the first report of effective and safe low-dose oxygen therapy for PCI using PaO<sub>2</sub> as a therapeutic index to prevent acute exacerbation of interstitial pneumonia.

Various treatments of PCI have been reported, such as antibiotics (8), bowel rest, high-dose oxygen therapy (1), hyperbaric oxygen (9) and surgical resection. Regarding high-dose oxygen therapy, Forgacs et al. demonstrated in 1973 for the first time that a high concentration of oxygen was effective for treating of PCI (1). Their PCI patients required arterial oxygen concentrations of 200 to 300 mmHg, and this therapy was achieved only with cumbersome tight masks that had to be worn for 5 hours a day. In other reports of PCI with interstitial pneumonia Forgacs's manuscript (2-6), the oxygen dose ranged from 4 to 10 L / minute for 4 to 8 hours a day and the PaO<sub>2</sub> values ranged from 210 to 219 mmHg (Table 1).

High-dose oxygen therapy is still used for managing PCI patients with interstitial pneumonia. However, this oxygen concentration can be extremely dangerous for some patients with interstitial pneumonia. Fortunately, there were no cases of acute exacerbation of interstitial pneumonia in any previous reports, but the number of cases of acute exacerbation of interstitial pneumonia is expected to increase when high-dose oxygen therapy is continued. Sakamoto et al. investigated the risk factors for acute exacerbation of idiopathic interstitial pneumonia during lobectomy in 68 patients with idiopathic interstitial pneumonia. It is reported that the cause of the acute exacerbation is the intraoperative administration of a high concentration of oxygen (10). According to Miyamoto et al., In a survey of 721 institutions performing surgery on patients with interstitial pneumonia in Japan, 63.7 % of the institutions were careful to maintain the oxygen concentration at a PaO<sub>2</sub> of around 100 mmHg at the



**Figure 2.** (A) Abdominal radiograph showed the presence of cysts from the ascending to the right-sided transverse colon. (B) Abdominal coronal computed tomography (CT) showed no portal venous gas, but multiple intraluminal gas pockets from the ascending to the right-sided transverse colon. (C) Abdominal axial CT showed the same findings.



**Figure 3.** About one week after fasting, fluid replacement and discontinuation of the  $\alpha$ -glucosidase inhibitor, there was no improvement in PCI on abdominal radiography.

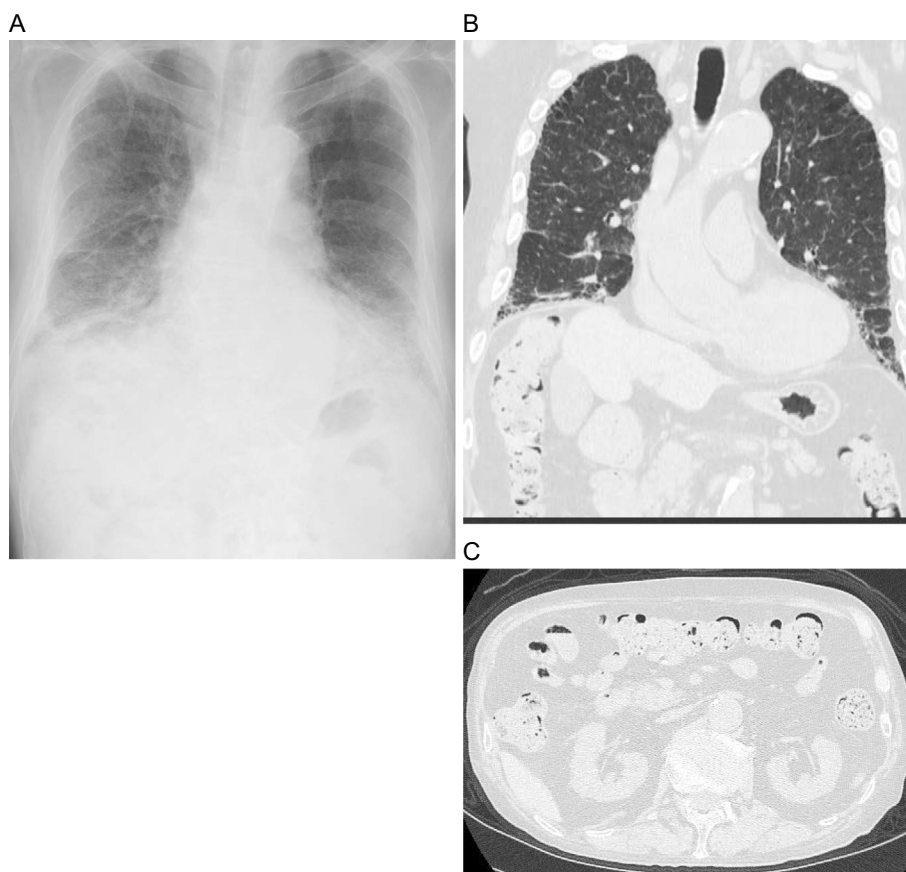
time of the operation in order to prevent postoperative acute exacerbations of interstitial pneumonia (11). Based on these reports, in our cases, relatively low oxygen concentrations of 2 to 4 L/min were administered over 24 hours, and care was taken to maintain the PaO<sub>2</sub> value at approximately 100

**Table 2.** Results of Arterial Blood Gas Before, during and after the Treatment.

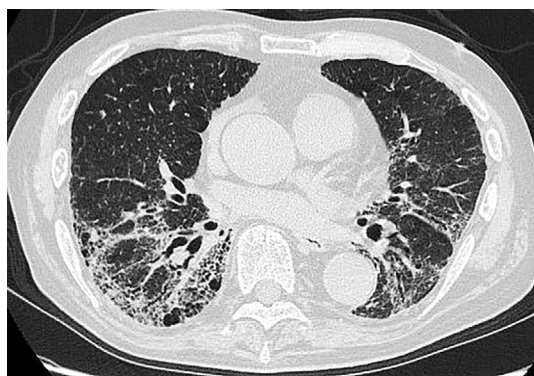ABGA	Before Treatment	During Treatment	After Treatment
pH	7.484	7.470	7.514
PaO <sub>2</sub> (mmHg)	71.8	114.0	67.9
PaCO <sub>2</sub> (mmHg)	34.3	34.5	33.7
SaO <sub>2</sub> (%)	94.9	98.7	94.0
BE (mmol/L)	2.7	1.8	4.5

ABGA: arterial blood gas analysis, pH: potential hydrogen, PaO<sub>2</sub>: partial pressure of oxygen in arterial blood, PaCO<sub>2</sub>: partial pressure of carbon dioxide in arterial blood, SaO<sub>2</sub>: saturation of arterial oxygen, BE: base excess

mmHg. To supplement the low oxygen dose, the oxygen inhalation time was extended to 24 hours. In our patient, the patient's PCI lesion recovered more rapidly (in 7 days) than previous PCI cases with interstitial pneumonia (from 9 to 15 days). Whether or not 24 hours of prolonged oxygen inhalation was effective or whether low doses of oxygen originally improved quickly was unclear. Furthermore, although there have been reports that PCI caused by the administration of an  $\alpha$ -glucosidase inhibitor improves only by stopping an  $\alpha$ -glucosidase inhibitor, there are cases in which the symptoms do not improve simply by stopping the drugs, as in our



**Figure 4.** (A) Abdominal radiography showed that the cysts had been reduced in size and improved. (B) Abdominal coronal computed tomography (CT) after the treatment showed the disappearance of the multiple intraluminal gas pockets that had been present at admission. (C) Abdominal axial CT showed the same findings.



**Figure 5.** No exacerbation of interstitial pneumonia was observed on chest computed tomography after low-dose oxygen therapy.

case. We successfully treated PCI with low-dose oxygen therapy. However, if PCI cannot be improved with low-dose oxygen therapy or if interstitial pneumonia worsens before low-dose oxygen therapy is effective, additional treatment may be needed. At present, various reports have been published concerning the mechanism underlying the pathogenesis of PCI, and there are following reports that PCI is improved by the method of each mechanism. Mechanism-

based methods include the use of metronidazole or kanamycin to control gas-producing bacteria (12), the use of intestinal peristaltic drugs to relieve intestinal paralysis, and surgery to relieve strictures that increase intestinal pressure (13). When the underlying disease of PCI is interstitial pneumonia, it is important not to increase the oxygen concentration too much in order to prevent the acute exacerbation of interstitial pneumonia, and to switch to other treatments while considering the occurrence mechanism. However, evidence supporting this approach is insufficient at present. To confirm the benefits and safety of this low-dose oxygen therapy using the  $\text{PaO}_2$  value as a therapeutic index, it is necessary to apply this method for other PCI cases with interstitial pneumonia.

### Conclusion

This is the first report describing the efficacy and safety of  $\text{PaO}_2$  as a therapeutic index of low-dose oxygen therapy for PCI to prevent acute exacerbation of interstitial pneumonia. Respiratory physicians often experience cases in which steroid therapy for interstitial pneumonia leads to steroid diabetes. It has been reported that complications of PCI can occur when  $\alpha$ -glucosidase inhibitors are used as antidiabetic drugs. Respiratory physicians treating interstitial pneumonia

should be aware of this. To prevent acute exacerbation of interstitial pneumonia in PCI treatment, it is necessary to apply the appropriate low-dose oxygen therapy while using PaO<sub>2</sub> as a therapeutic index instead of conventional high-dose oxygen therapy.

**The authors state that they have no Conflict of Interest (COI).**

#### Acknowledgement

We are grateful to the patient and her family for their cooperation with this research.

#### References

1. Forgas P, Wright PH, Wyatt AP. Treatment of intestinal gas cyst by oxygen breathing. *Lancet* **1**: 579-582, 1973.
2. Aoki M, Suwa A, Nakajima A, et al. A case of systemic sclerosis complicated with pneumoperitoneum and pneumatosis cystoides intestinalis. *Jpn J Clin Immun* **21**: 159-165, 1998 (in Japanese).
3. Nakamura K, Tomonaga M, Kajiyama H, et al. A case of pneumatosis cystoides intestinalis involving the small intestine, large intestine and stomach. *Jpn J Gastroenterol* **98**: 948-952, 2001 (in Japanese).
4. Wada Y, Murayama N, Hirose S, et al. A case of pneumatosis cystoides intestinalis in a patient with polymyositis and interstitial pneumonia. *Mod Rheumatol* **14**: 260-263, 2004.
5. Sekita Y, Fujimori S, Ehara A, et al. A case of pneumatosis cystoides intestinalis with polymyositis improved by high flow oxygen therapy. *Prog Dig Endosc* **66**: 35-38, 2005 (in Japanese).
6. Fushimi N, Kanoh Y, Hirota T, Kawachi S, Shibuya T, Takeda J. A case of polymyositis with recurrent pneumatosis cystoides intestinalis. *Clin Rheumatol* **22**: 220-228, 2010 (in Japanese).
7. Chida M, Kobayashi S, Karube Y, Hayama M, Tamura M, Ishihama H. Incidence of acute exacerbation of interstitial pneumonia in operated lung cancer: institutional report and review. *Ann Thorac Cardiovasc Surg* **18**: 314-317, 2012.
8. Gillon J, Tadesse K, Logan RF, Holt S, Sircus W. Breath hydrogen in pneumatosis cystoides intestinalis. *Gut* **20**: 1008-1011, 1979.
9. Masterson JST, Fratkin LB, Osler TR, Trapp WG. Treatment of pneumatosis cystoides intestinalis with hyperbaric oxygen. *Ann Surg* **187**: 245-247, 1978.
10. Sakamoto S, Homma S, Mun M. Acute exacerbation of idiopathic interstitial pneumonia following lung surgery in 3 of 68 consecutive patients. A retrospective study. *Intern Med* **50**: 77-85, 2011.
11. Miyamoto A, Kishi K, Yoshimaru K. A nationwide survey concerning lung surgery for lung cancer associated with idiopathic interstitial pneumonia. *Nihon Kokyuki Gakkai Zasshi* **49**: 148-150, 2011 (In Japanese).
12. Ellis BW. Symptomatic treatment of primary pneumatosis coli with metronidazole. *Br Med J* **280**: 763-764, 1980.
13. Schröpfer E, Meyer T. Surgical aspects of pneumatosis cystoides intestinalis. *Cases J* **2**: 1-6, 2009.

The Internal Medicine is an Open Access journal distributed under the Creative Commons Attribution-NonCommercial-NoDerivatives 4.0 International License. To view the details of this license, please visit (<https://creativecommons.org/licenses/by-nc-nd/4.0/>).