



Case Report

Long term seizure freedom on perampanel in highly drug-resistant epilepsy caused by bilateral periventricular nodular heterotopia: A case report

Makoto Kiyose^{a,c}, Marlies Wagner^{b,c}, Annika Männer^a, Sarah C. Reitz^a, Karl Martin Klein^{a,c}, Adam Strzelczyk^{a,c}, Sebastian Bauer^{a,c}, Felix Rosenow^{a,c,*}

^a Epilepsy Center Frankfurt Rhine-Main, Department of Neurology, Center of Neurology and Neurosurgery, University Hospital Frankfurt and Goethe University Frankfurt, Frankfurt, Germany

^b Institute of Neuroradiology, Center of Radiology, University Hospital Frankfurt and Goethe University Frankfurt, Frankfurt, Germany

^c LOEWE Center for Personalized translational Epilepsy Research (CePTER), Frankfurt, Germany

ARTICLE INFO

Article history:

Received 6 January 2019

Received in revised form 28 January 2019

Accepted 30 January 2019

Available online 13 February 2019

1. Introduction

While seizure prognosis of epilepsy is largely determined by etiology, clinical trials are usually directed at seizure type and not epilepsy syndrome or etiology [1]. This may be one of the relevant reasons for the lack of progress in reducing the percentage of drug-resistant epilepsy patients over the last decades despite an increasing number of anti-seizure drugs (ASD) [2,3]. Perampanel (PER) is a first in class non-competitive antagonist of the ionotropic AMPA receptor [4]. PER has been approved by the United States Food and Drug Administration as an adjunctive treatment for focal seizures with or without secondary generalization in epilepsy patients >12 years and for tonic-clonic seizures in idiopathic generalized epilepsy (IGE) [5–8]. There are few data on PERs efficacy in specific etiologies such as glioma-related epilepsies [9,10]. A PubMed search for perampanel and heterotopia resulted in 0 references found.

A dysfunction of neuronal migration can result in heterotopic gray matter, which can be located uni- or bilaterally in the periventricular zone as nodules and frequently causes drug-resistant epilepsy [11, 12]. PVNH occurs sporadically and in familial forms. It is more common in females as the most frequent genetic cause, with a filamin A mutation that is X-linked [13].

Here, we describe a patient with PVNH-associated active and highly drug-resistant focal epilepsy, who achieved sustained seizure freedom

after PER was added, in order to generate interest in a potentially specific utility for PER in this condition.

2. Case report

A 71-year-old cognitively unimpaired man with highly drug-resistant symptomatic epilepsy caused by bilateral symmetric periventricular heterotopia was treated in our outpatient clinic since January 2016. He reported near daily focal onset seizures and rare focal to bilateral tonic-clonic seizures since the age of 21 years. He described the focal seizures as beginning with a visual aura followed by aphasia and focal impaired awareness seizure. The MRI showed bilateral symmetric periventricular nodular heterotopia (PVNH) and bilateral hippocampal atrophy more pronounced on the left (Fig. 1). Comorbidities included essential tremor, glaucoma, arterial hypertension, arteriosclerotic heart disease and a thyroid hypofunction. No family history of epilepsy or risk factors for epilepsy were present. ASDs taken in the past included primidone (750 mg/d), lacosamide (300 mg/d), levetiracetam (3000 mg/d), lamotrigine (350 mg/d), brivaracetam (200 mg/d) as well as carbamazepine, valproate, topiramate, pregabalin, oxcarbazepine (unknown daily doses) resulted in a reduction of the number of bilateral tonic-clonic seizures but not the focal seizures and were associated with a number of side effects. His current medication of 600 mg of lacosamide, 750 mg of primidone and 300 mg of pregabalin was tolerated but did not have a significant impact on seizure frequency.

In December 2017, he was admitted to our epilepsy monitoring unit for presurgical evaluation and medication adjustment. The interictal EEG showed sharp waves over the left hemisphere, most frequently with a maximum over F3 and rarely with a bifrontal distribution (Fig. 2A). We recorded two right versive seizures evolving into bilateral tonic-clonic seizures associated with severe cyanosis and postictal apnoea as well as three subclinical seizures which were associated with a left frontal ictal onset zone (maximum Fz/F3, Fig. 2B). An additional invasive evaluation using stereo-EEG was offered and compassionate use intraventricular valproate application (NCT02899611) was considered but both declined by the patient.

Perampanel was added in 12/2017 to his ongoing medication with a target dose of 8 mg/d. The preexisting anti-seizure medication was not modified. In a last follow-up in 11/2018, he reported to have suffered

* Corresponding author at: Epilepsy Center Frankfurt Rhine-Main, Schleusenweg 2-16, Frankfurt am Main, Germany.

E-mail address: rosenow@med.uni-frankfurt.de (F. Rosenow).

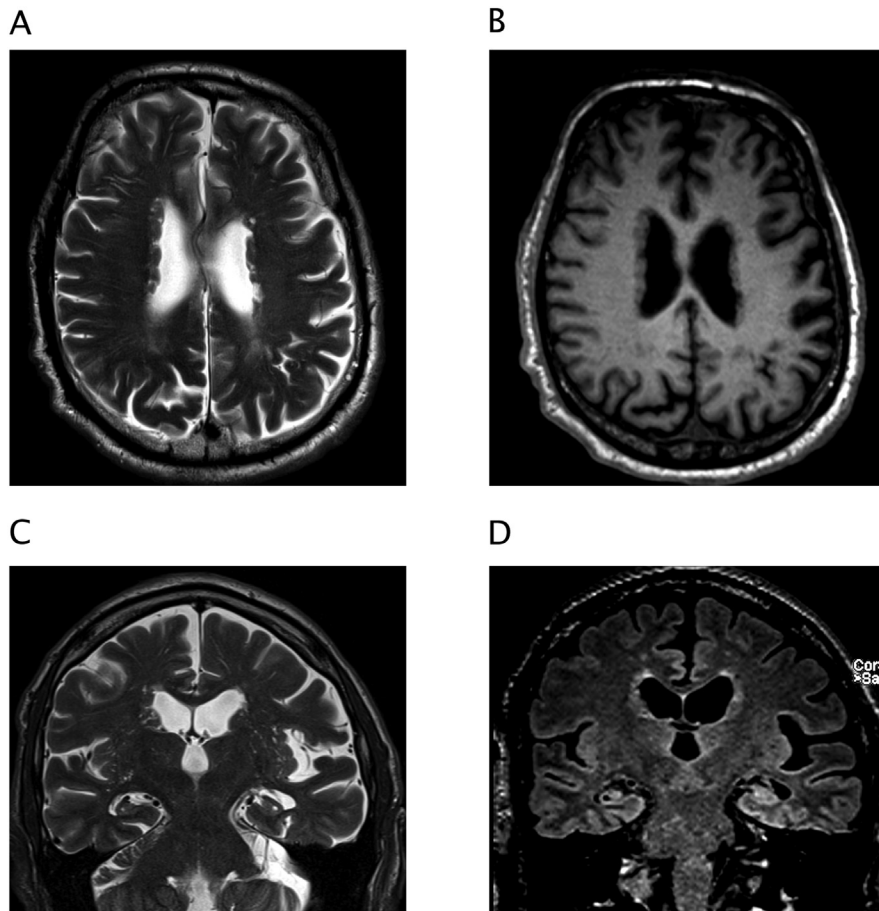


Fig. 1. MRI showing bilateral symmetric periventricular nodular heterotopia and bilateral hippocampal atrophy more pronounced on the left. In A) T2-weighted and B) T1-weighted images of the nodules that are isointense to cortical gray matter, adjacent enlarged perivascular spaces showing a T2-hyperintense cystic appearance. C) Coronal orientated T2-weighted images revealing hippocampal atrophy and disruption of the internal hippocampal structure on both sides. D) FLAIR-images supplementing these findings with hyperintense signals present in both hippocampi.

from only one focal seizure since the dose of 8 mg/d was reached in January 2018 with a seizure freedom of ten months.

3. Discussion

Unexpectedly, this man with a severe, highly drug resistant chronic structural epilepsy associated by a bilateral symmetric PVNH with nearly daily seizures for the first time achieved complete seizure freedom for ten months when perampanel was added to his anti-seizure polytherapy.

Data from the literature report the existence of an alteration of alpha-CaMKII and the NMDA-receptor complex in the epileptogenic brain tissue of human PVNH, suggesting a role in the basic mechanism of hyperexcitability associated with this brain dysgenesis. Corresponding immunocytochemistry showed that NMDA receptor subunit expression was decreased rather than increased as compared to normal neurons, especially when nodules extend to the neocortex [14]. These findings were supported by later investigations indicating that expressed levels of specific NMDA receptor subunits are altered in both cerebral heterotopia and cortical dysplasia in humans. Interestingly, a selective increase in the NR2B subunit was present in cortical dysplasia while the expressed level of NR2A and NR2B subunits is significantly downregulated in the patients with heterotopia. It is crucial to note, however, that this cohort did not have symmetrical bilateral PVNH [15]. An animal model with methylazoxymethonal (MAM) treated rats with heterotopia suggests, that a reduction of NR2A/B subunits is only present on at the postsynaptic level and not caused by expression, but eventually through phosphorylation [16]. Moreover, intrinsic ictal discharges of focal cortical dysplasias are mediated by

excitatory amino acid receptors, notably by NMDA [17]. While a reduction in NMDA-R subunits appears counterintuitive, when postulating high efficacy of an AMPA-R antagonist, these results could implicate glutamatergic transmission in the hyperexcitability of nodular heterotopia leading to seizures.

4. Conclusions

The dramatic effect observed might be explained by exspect, cumulative polytherapy of several ASDs or possibly by an etiology-specific efficacy of PER in our patient with PVNH. To assess if the latter was the case, further clinical studies including case series and monotherapy reports would help validate our initial findings.

Acknowledgements and funding

This publication was supported by a grant of the State of Hesse for the LOEWE Center for Personalized Translational Epilepsy Research (CePTER) and by the Detlev-Wrobel-Fonds for epilepsy research.

Conflict of interest statement

Dr. Rosenow reports grants from European Union, grants from Detlev-Wrobel-Fonds for Epilepsy Research, during the conduct of the study; personal fees from UCB Pharma, personal fees from Eisai, personal fees from Novartis, personal fees from Desitin Arzneimittel, personal fees from Bial, personal fees from cerbomed, personal fees and other from GW Pharma, other from Medtronic, personal fees from Shire, personal

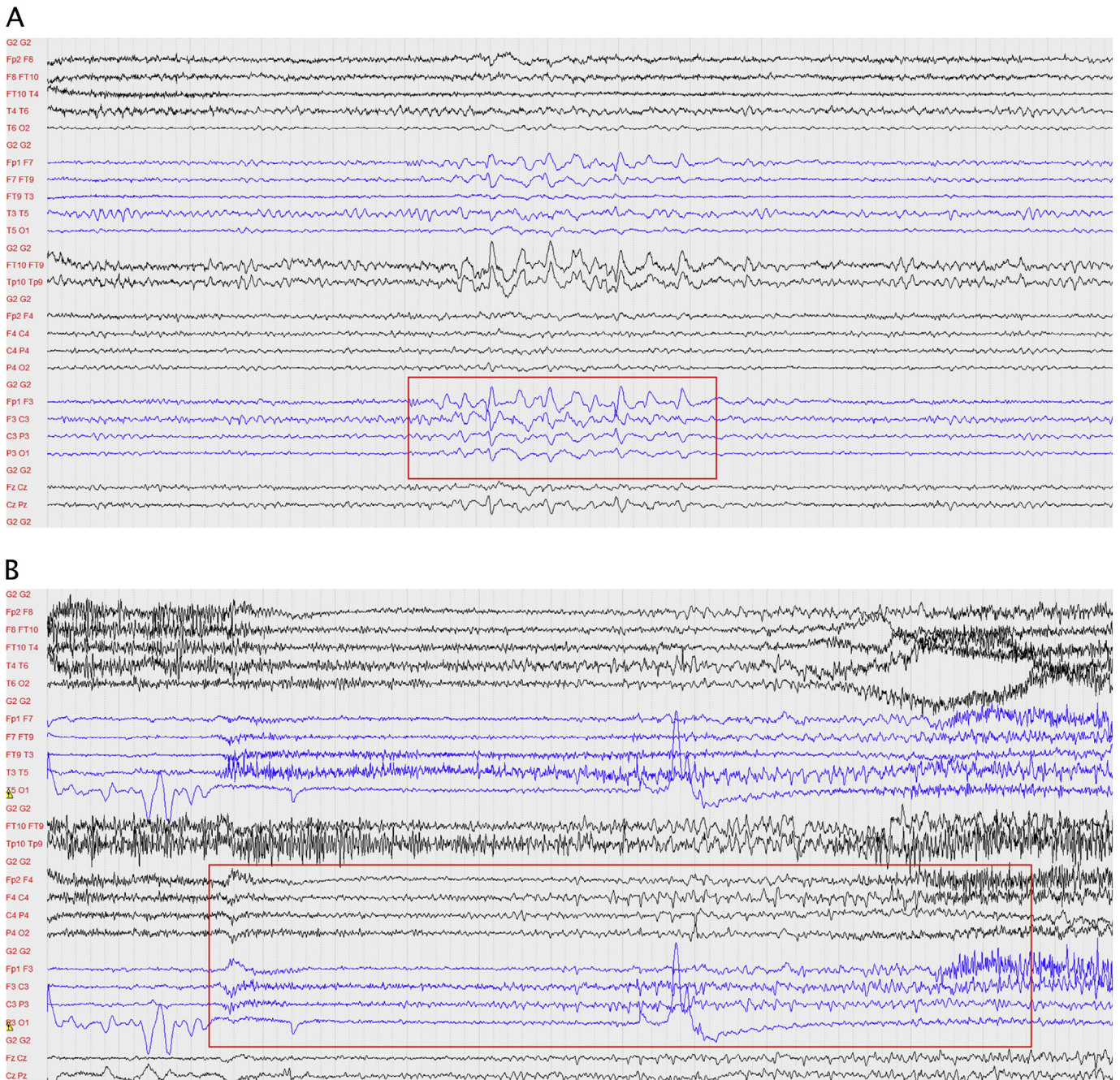


Fig. 2. A) Interictal EEG showing repetitive sharp waves, maximum left frontal (F3). B) Ictal EEG during the onset of a generalized tonic-clonic seizure showing low amplitude fast activity over both central regions.

fees from Sandoz outside the submitted work. A. Strzelczyk reports personal fees and grants from Desitin Arzneimittel, Eisai, LivaNova, Sage Therapeutics, UCB Pharma and Zogenix. K.M. Klein reports personal fees from UCB Pharma, Novartis Pharma AG, Eisai and GW Pharmaceuticals as well as grants from the Deutsche Forschungsgemeinschaft and The University of Melbourne. M. Wagner, S. Bauer, A. Männer, S.C. Reitz and M. Kiyose don't have to report any conflicts of interest.

Ethical statement

The local Ethics committee has granted approval for retrospective analysis and report of drug effects in epilepsy patients. Informed consent was waived due to anonymized and retrospective data report.

References

- [1] Semah F, Picot MC, Adam C, et al. Is the underlying cause of epilepsy a major prognostic factor for recurrence? *Neurology* 1998;51(5):1256–62.
- [2] Cockerell OC, Johnson AL, Sander JW, Hart YM, Shorvon SD. Remission of epilepsy: results from the National General Practice Study of Epilepsy. *Lancet Lond Engl* 1995;346(8968):140–4.
- [3] Chen Z, Brodie MJ, Liew D, Kwan P. Treatment outcomes in patients with newly diagnosed epilepsy treated with established and new antiepileptic drugs: a 30-year longitudinal cohort study. *JAMA Neurol* 2018;75(3):279–86. <https://doi.org/10.1001/jamaneurol.2017.3949>.
- [4] Rogawski MA, Hanada T. Preclinical pharmacology of perampanel, a selective non-competitive AMPA receptor antagonist. *Acta Neurol Scand* 2013;127:19–24. <https://doi.org/10.1111/ane.12100>.
- [5] French JA, Krauss GL, Biton V, et al. Adjunctive perampanel for refractory partial-onset seizures: randomized phase III study 304. *Neurology* 2012;79(6):589–96. <https://doi.org/10.1212/WNL.0b013e3182635735>.

- [6] French JA, Krauss GL, Steinhoff BJ, et al. Evaluation of adjunctive perampanel in patients with refractory partial-onset seizures: results of randomized global phase III study 305: perampanel for partial-onset seizures. *Epilepsia* 2013;54(1):117–25. <https://doi.org/10.1111/j.1528-1167.2012.03638.x>.
- [7] French JA, Krauss GL, Wechsler RT, et al. Perampanel for tonic-clonic seizures in idiopathic generalized epilepsy: a randomized trial. *Neurology* 2015;85(11):950–7. <https://doi.org/10.1212/WNL.0000000000001930>.
- [8] Krauss GL, Serratos JM, Villanueva V, et al. Randomized phase III study 306: adjunctive perampanel for refractory partial-onset seizures. *Neurology* 2012;78(18):1408–15. <https://doi.org/10.1212/WNL.0b013e318254473a>.
- [9] Vecht C, Duran-Peña A, Houillier C, Durand T, Capelle L, Huberfeld G. Seizure response to perampanel in drug-resistant epilepsy with gliomas: early observations. *J Neurooncol* 2017;133(3):603–7. <https://doi.org/10.1007/s11060-017-2473-1>.
- [10] Di Bonaventura C, Labate A, Maschio M, Meletti S, Russo E. AMPA receptors and perampanel behind selected epilepsies: current evidence and future perspectives. *Expert Opin Pharmacother* 2017;18(16):1751–64. <https://doi.org/10.1080/14656566.2017.1392509>.
- [11] Barkovich AJ, Guerrini R, Kuzniecky RI, Jackson GD, Dobyns WB. A developmental and genetic classification for malformations of cortical development: update 2012. *Brain* 2012;135(5):1348–69. <https://doi.org/10.1093/brain/aws019>.
- [12] Battaglia G, Chiapparini L, Franceschetti S, et al. Periventricular nodular heterotopia: classification, epileptic history, and genesis of epileptic discharges. *Epilepsia* 2006;47(1):86–97. <https://doi.org/10.1111/j.1528-1167.2006.00374.x>.
- [13] Dubeau F, Tampieri D, Andermann F. Periventricular and subcortical nodular heterotopia: comparison of clinical findings and results of surgical treatment. *Dysplasias of cerebral cortex and epilepsy*. Philadelphia - New York: Lippincott - Raven; 1996. p. 395–406.
- [14] Battaglia G, Pagliardini S, Ferrario A, et al. AlphaCaMKII and NMDA-receptor subunit expression in epileptogenic cortex from human periventricular nodular heterotopia. *Epilepsia* 2002;43(Suppl. 5):209–16.
- [15] Finardi A, Gardoni F, Bassanini S, et al. NMDA receptor composition differs among anatomically diverse malformations of cortical development. *J Neuropathol Exp Neurol* 2006;65(9):883–93. <https://doi.org/10.1097/01.jnen.0000235117.67558.6d>.
- [16] Gardoni F, Pagliardini S, Setola V, et al. The NMDA receptor complex is altered in an animal model of human cerebral heterotopia. *J Neuropathol Exp Neurol* 2003;62(6):662–75.
- [17] Avoli M, Louvel J, Mattia D, et al. Epileptiform synchronization in the human dysplastic cortex. *Epileptic Disord Int Epilepsy J Videotape* 2003;5(Suppl. 2):S45–50.