

The Relation between canine cognitive dysfunction and age-related brain lesions

Makiko OZAWA¹⁾, James K. CHAMBERS¹⁾, Kazuyuki UCHIDA¹⁾ and Hiroyuki NAKAYAMA^{1)*}

¹⁾Department of Veterinary Pathology, the University of Tokyo, Tokyo 113–8657, Japan

(Received 30 October 2015/Accepted 15 February 2016/Published online in J-STAGE 27 February 2016)

ABSTRACT. Canine cognitive dysfunction (CCD) is a syndrome that manifests itself in abnormal behaviors, such as disorientation and wandering. β -amyloid deposition in the brain, including the senile plaque (SP) and cerebral amyloid angiopathy (CAA), has been suggested as a major cause of the syndrome. However, the pathological significance of β -amyloid deposition in CCD dogs remains unclear. The present study was conducted using 16 dogs aged 10 years or older to clarify the relationship between the age-related histopathological lesions, such as β -amyloid deposition, in the brain and the clinical symptoms of CCD as evaluated in a questionnaire previously established in a large survey. In addition, age-related brain lesions were assessed in 37 dogs. The pathological lesions were evaluated by the severity of β -amyloid deposition (SP and CAA), the amount of ubiquitin-positive granules (UBQ), GFAP-positive astrocytes, Iba-1-positive microglia and Nissle stain-positive nerve cells. The results revealed that there was no significant correlation between the severities of canine SP and CCD. The SP increased until 14 years old, but decreased thereafter, although the incidence of CCD is high at these ages. The CAA consistently increased with age, but did not correlate greatly with the CCD score. In contrast, the increases of UBQ, astrocytes and microglia were significantly correlated with CCD. Thus, the impairment in the synapse and/or myelin suggested by increased UBQ and glial activation might be involved in CCD pathogenesis, but β -amyloid deposition, especially SP, is not a direct pathogenic factor of CCD.

KEY WORDS: aging, beta amyloid, canine cognitive dysfunction

doi: 10.1292/jvms.15-0624; *J. Vet. Med. Sci.* 78(6): 997–1006, 2016

Canine cognitive dysfunction (CCD) is a syndrome in aged dogs characterized by behavioral alterations, such as disorientation, deterioration of social-environmental interaction, changes of the sleep-wake cycle, house soiling, impairment of house training and changes of activity [6, 13, 14, 18, 22]. These behavioral alterations are major problems for owners, because such behaviors increase the level of care needed for their dogs and also owners suffer from additional noise, such as barking. Therefore, an investigation of the pathogenesis of CCD is urgently required.

Various brain lesions associated with aging are observed in dogs with CCD. Among them, amyloid β protein (A β) depositions observed as senile plaque (SP) and cerebral amyloid angiopathy (CAA) have been suggested as the main pathogenic factors, as in Alzheimer's disease in humans, the most predominant cause of dementia [2, 28, 33]. A β is thought to have an important role in the neuronal death cascade that finally leads to cognitive decline and dementia. Since aged dogs develop SP and CAA, and CCD shows clinical symptoms resembling those of Alzheimer's disease, the A β deposition has been assumed to initiate CCD by a similar pathophysiological process to Alzheimer's disease [1, 6, 7, 9, 10, 14, 20, 25, 30–32, 34]. Furthermore, the severity of A β deposition in dogs was reported to be involved in the level of their cognitive decline as assessed by some

cognition tests [5, 6, 10], which also supports the hypothesis for the cause of CCD.

Up to the present, several studies to clarify the correlation between A β deposition in the brain and CCD severity have been conducted with companion dogs, however, the results of the studies have differed [3, 12, 21]. The SP severity correlated with the CCD severity in a study conducted by Colle *et al.* [3]. Rofina *et al.* also reported a correlation between SP and CCD severities, but they found no significant difference in the SP severity in dogs older than 13 years with and without CCD [21]. Moreover, in the study by Kiatipattanasakul *et al.*, the CCD severity correlated with the number of Apopt Tag-positive (apoptotic) brain cells, but did not with SP [12].

The inconsistency in these results might be due to the difficulty in evaluating clinical presentations of CCD. Old dogs show various behavioral changes, and some of them are very similar to behaviors caused by CCD [13, 14]. Thus, the border of the behavioral changes between CCD and normal aging is not clear. Also, the clinical presentation and progression patterns vary even within CCD dogs [8, 16, 18]. In addition, several questionnaires to be completed by the owners have been developed in previous studies, but their accuracy has not yet been verified in a large survey. However, a questionnaire as an assessment tool for the diagnosis of CCD was recently established by Salvin *et al.* based on a large cross-sectional survey [23, 24]. This questionnaire consists of 13 items and had an overall 98.9% diagnostic accuracy in their study. In the present study, we evaluate behavioral presentations of CCD in 16 dogs using a questionnaire completed by the owners and examine the relationship between the CCD condition and histopathological brain lesions. Additionally, we examine the histopathological changes in the brain of 37 dogs to assess the physiological aging changes of each brain lesion.

*CORRESPONDENCE TO: NAKAYAMA, H., Department of Veterinary Pathology, the University of Tokyo, Tokyo 113–8657, Japan. e-mail: anakaya@mail.ecc.u-tokyo.ac.jp

©2016 The Japanese Society of Veterinary Science

This is an open-access article distributed under the terms of the Creative Commons Attribution Non-Commercial No Derivatives (by-nc-nd) License <<http://creativecommons.org/licenses/by-nc-nd/4.0/>>.

Table 1. Questionnaire used in the present study (Salvin *et al.* (2011) with modification)

	Never (1 point)	Once a month (2 point)	Once a week (3 point)	Once a day (4 point)	>Once a day (5 point)
1 How often does your dog pace up and down, walk in circles and/or wander with no direction or purpose?	<input type="checkbox"/>	<input type="checkbox"/>	<input type="checkbox"/>	<input type="checkbox"/>	<input type="checkbox"/>
2 How often does your dog stare blankly at the wall or floor?	<input type="checkbox"/>	<input type="checkbox"/>	<input type="checkbox"/>	<input type="checkbox"/>	<input type="checkbox"/>
3 How often does your dog get stuck behind objects and is unable to get around?	<input type="checkbox"/>	<input type="checkbox"/>	<input type="checkbox"/>	<input type="checkbox"/>	<input type="checkbox"/>
4 How often does your dog fail to recognise familiar people or pets?	<input type="checkbox"/>	<input type="checkbox"/>	<input type="checkbox"/>	<input type="checkbox"/>	<input type="checkbox"/>
5 How often does your dog walk into walls or doors?	<input type="checkbox"/>	<input type="checkbox"/>	<input type="checkbox"/>	<input type="checkbox"/>	<input type="checkbox"/>
6 How often does your dog walk away while, or avoid, being patted?	<input type="checkbox"/>	<input type="checkbox"/>	<input type="checkbox"/>	<input type="checkbox"/>	<input type="checkbox"/>
	Never (1 point)	1–30% of times (2 point)	31–60% of times (3 point)	61–99% of times (4 point)	Always (5 point)
7 How often does your dog have a difficulty in finding food dropped on the floor?	<input type="checkbox"/>	<input type="checkbox"/>	<input type="checkbox"/>	<input type="checkbox"/>	<input type="checkbox"/>
	Much less (1 point)	Slightly less (2 point)	The same (3 point)	Slightly more (4 point)	Much more (5 point)
8 Compared to 6 months ago, does your dog now pace up and down, walk in circles and/or wander with no direction or purpose?	<input type="checkbox"/>	<input type="checkbox"/>	<input type="checkbox"/>	<input type="checkbox"/>	<input type="checkbox"/>
9 Compared to 6 months ago, does your dog now stare blankly at the wall or floor?	<input type="checkbox"/>	<input type="checkbox"/>	<input type="checkbox"/>	<input type="checkbox"/>	<input type="checkbox"/>
10 Compared to 6 months ago, does your dog urinate or defecate in an area it has previously kept clean? (If your dog has never house-soiled, tick 'the same'.)	<input type="checkbox"/>	<input type="checkbox"/>	<input type="checkbox"/>	<input type="checkbox"/>	<input type="checkbox"/>
11 Compared to 6 months ago, does your dog have a difficulty in finding food dropped on the floor?	<input type="checkbox"/> x2	<input type="checkbox"/> x2	<input type="checkbox"/> x2	<input type="checkbox"/> x2	<input type="checkbox"/> x2
12 Compare to 6 months ago, does your dog fail to recognise familiar people or pets?	<input type="checkbox"/> x3	<input type="checkbox"/> x3	<input type="checkbox"/> x3	<input type="checkbox"/> x3	<input type="checkbox"/> x3
	Much more (1 point)	Slightly more (2 point)	The same (3 point)	Slightly less (4 point)	Much less (5 point)
13 Compared to 6 months ago, how much time does your dog spend being active?	<input type="checkbox"/>	<input type="checkbox"/>	<input type="checkbox"/>	<input type="checkbox"/>	<input type="checkbox"/>
Total =					

MATERIALS AND METHODS

Questionnaire: The questionnaire for CCD proposed by Salvin *et al.*, consisting of 13 questions, was used with some modifications (Table 1) [24]. Dog owners were requested to fill out the questionnaire after necropsy, and CCD scores (score 16 to 80) were calculated. Scores of 50 or higher were considered to be CCD [24].

Brain samples: Thirty-seven canine brains were obtained through routine necropsies performed at the Department of Veterinary Pathology, the University of Tokyo. The information of the dogs is summarized in Table 2. The ages of the dogs ranged from 5 to 18 years old, and the median was 14. Of the 37 necropsy cases, 16 dogs, aged 10 or older, were evaluated for behavioral changes with the questionnaire. Various breeds were included in necropsy cases, and most of them were small- or medium-sized breeds according to the American Kennel Club breed size division (mongrels are determined by their weight; <15 kg: small, 15–25 kg: medium, and >25 kg: large), but size data were not available for

one mongrel. The dogs used had died spontaneously or were euthanized due to various fatal diseases, but individuals with major brain lesions, such as neoplasms or inflammatory diseases that had been confirmed grossly or histopathologically, were excluded from the study. Dogs with spinal cord lesions that caused gait impairment, such as degenerative myelopathy and intervertebral disk herniation, were also excluded from the investigation.

At necropsy, the right or left hemisphere of the brain was fixed in a 10% phosphate-buffered formalin solution. After fixation, brains were dissected colonially and conventionally embedded in paraffin. Six parts: 1) the prefrontal lobe, 2) parietal and temporal lobes with the caudate nucleus, 3) parietal and temporal lobes with the hypothalamus, 4) parietal and temporal lobes with the hippocampus and mid brain, 5) occipital lobe with the cerebellum and 6) brain stem was collected and used for histopathological investigations.

Histopathology: Paraffin-embedded tissues were cut into 4- μ m-thick sections. Deparaffinized sections were then stained with hematoxylin and eosin (HE) for a general

Table 2. Age, breed, size and gender of the 37 dogs examined

Dog No.	Age (years)	Breed	Size ^{a)}	Gender ^{b)}	CCD score
1	5	Labrador Retriever	M	CM	Nd
2	5	Beagle	S	F	Nd
3	5	Beagle	S	F	Nd
4	8	Mongrel	S	CM	Nd
5	9	Beagle	S	CM	Nd
6	10	Beagle	S	CM	Nd
7	10	Mongrel	M	CM	Nd
8	10	Shiba Inu	M	CM	38
9	10	Beagle	S	M	Nd
10	10	Beagle	S	SF	Nd
11	11	Pembroke Welsh Corgi	M	M	Nd
12	11	Dachshund (Miniature)	S	SF	34
13	12	Dachshund (Miniature)	S	F	34
14	12	Shiba Inu	M	M	Nd
15	12	Miniature Schnauzer	S	M	Nd
16	13	Poodle (Toy)	S	F	Nd
17	13	Border Collie	M	SF	Nd
18	14	Papillon	S	CM	44
19	14	Pembroke Welsh Corgi	M	SF	Nd
20	14	Pembroke Welsh Corgi	M	M	Nd
21	14	Mongrel	M	CM	58
22	14	Dachshund (Miniature)	S	SF	Nd
23	14	Dachshund (Miniature)	S	SF	Nd
24	15	Pomeranian	S	M	58
25	15	Papillon	S	F	40
26	16	Shiba Inu	M	F	66
27	16	Pembroke Welsh Corgi	M	SF	Nd
28	16	Mongrel	S	SF	42
29	16	Lhasa Apso	S	M	38
30	16	Shih Tzu	S	SF	45
31	16	Pembroke Welsh Corgi	M	F	38
32	16	Mongrel	S	SF	Nd
33	16	Mongrel	S	F	50
34	17	Shiba Inu	M	SF	64
35	17	Mongrel	M	SF	60
36	17	Mongrel	Nd	Nd	Nd
37	18	Mongrel	S	SF	50

a) Size; S: small, M: medium. b) Gender; M: Male, CM: Castrated male, F: Female, SF: Spayed female. Nd: Not determined.

pathological evaluation, and Nissle stain was also performed to assess the number of nerve cells.

For immunohistochemistry, we used the primary antibodies listed in Table 3 to characterize the A β deposition, ubiquitin-positive granules (UBQ), glial fibrillary acidic protein

(GFAP)-positive cells (astrocytes) and Iba-1-positive cells (microglia). Vascular A β deposition (CAA) mainly consists of A β 40 in humans, but of both A β 40 and A β 42 in dogs [1]. Therefore, we used an anti-A β 42 antibody to evaluate CAA, as well as SPs, in the present study. The cerebrocortical CAA (Cor-CAA) and leptomeningeal CAA (Lm-CAA) were also evaluated. The cortex of the prefrontal lobe (FC), and that of parietal and the temporal lobes with hippocampus and midbrain (PTC) were immunohistochemically evaluated for A β deposition.

The immunohistochemical staining was performed using the Dako Envision+System (Dako, Glostrup, Denmark). Deparaffinized sections were treated with 3% hydrogen peroxide (H₂O₂)-methanol at room temperature for 5 min and incubated in 8% skimmed milk-Tris-buffered saline (TBS) at 37°C for 1 hr to avoid nonspecific reactions. The sections were then incubated at 4°C overnight with one of the primary antibodies and incubated with Envision horseradish peroxidase (HRP)-labeled polymer anti-mouse or anti-rabbit immunoglobulin G (Dako) at 37°C for 40 min. Then, the sections were reacted with 0.05% 3',3'-diaminobenzidine and 0.03% H₂O₂ in TBS, and counterstained with hematoxylin or methyl green.

Semi-quantitative and quantitative evaluations of brain lesions: Each section was semi-quantitatively evaluated by the histopathological scoring method or the digital image analyzing method using the Image J 1.43m software (National institutes of health, Bethesda, MD, U.S.A.). Sections of FC and PTC were each divided into the following 5 areas, respectively; FC consisted of FC1: longitudinal cerebral fissure, FC2: anterior suprasylvian gyrus, FC3: coronal sulcus and anterior suprasylvian gyrus, FC4: presylvian sulcus and FC5: proreus gyrus and sulcus olfactorius, while PTC consisted of PTC1: cingulate gyrus, splenialis sulcus and suprasplenialis sulcus, PTC2: lateral gyrus and superior side of lateral sulcus, PTC3: inferior side of lateral sulcus, medial suprasylvian gyrus and superior side of medial suprasylvian sulcus, PTC4: superior part of ectosylvian gyrus to posterior suprasylvian gyrus and PTC5: inferior part of ectosylvian gyrus to posterior suprasylvian gyrus. Each area was scored for A β deposition as follows; for SP and Cor-CAA, score 0: no deposition, score 1: slight deposition or severe deposition within half of the area and score 2: severe deposition in more than half of the area (Figs. 1 and 4), and for Lm-CAA, score 0: no deposition, score 1: slight deposition or severe deposition within half of the leptomeningeal vessel and score 2: severe deposition in more than half of the leptomeningeal vessel (Fig. 5). The score in each case was defined as the average total of the 5 areas in FC and PTC (score 0 to 10).

Table 3. Primary antibodies used in the present study

Antibody	Type	Dilution	Antigen retrieval	Manufacturer
A β x-42	Mouse monoclonal(clone12F4)	1:1,000	Formic acid	Merc Millipore, Temecula, CA, U.S.A.
Ubiquitin	Rabbit polyclonal	1:100	None	Dako, Glostrup, Denmark
GFAP	Rabbit polyclonal	1:1,000	None	Dako, Glostrup, Denmark
Iba-1	Rabbit polyclonal	1:500	Autoclave	Wako Pure Chemical Industries, Osaka, Japan

GFAP, glial fibrillary acidic protein; Iba1, ionized calcium-binding adapter molecule.

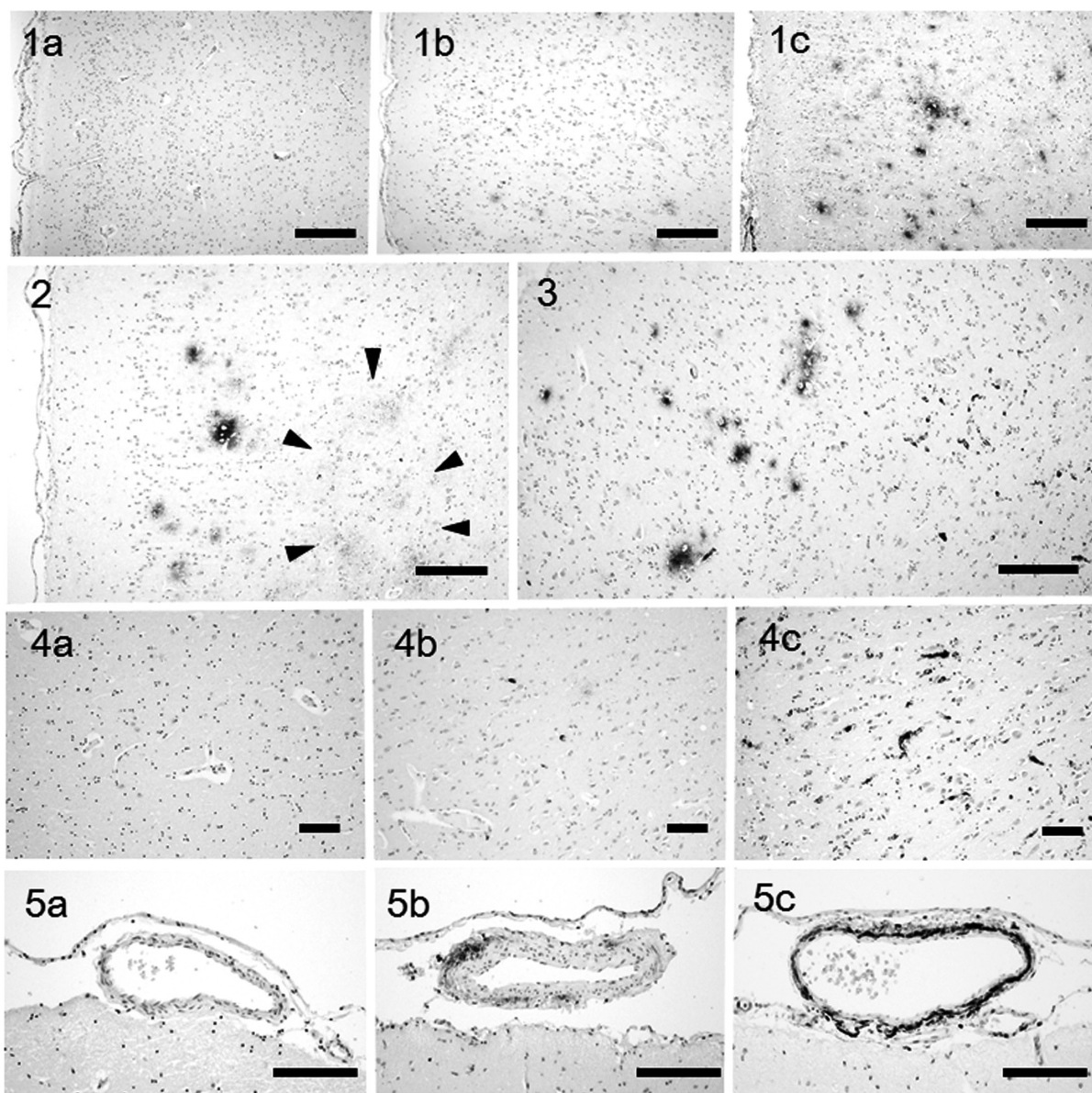


Fig. 1. (a) SP score 0. Dog No. 1, 5 years old. (b) SP score 1. A small number of SPs are observed. Dog No. 16, 13 years old. (c) SP score 2. A lot of SPs are observed all over the area. Dog No. 19, 14 years old. Immunohistochemistry for A β 42. Scale bar=250 μ m.

Fig. 2. A small number of SPs and diffuse A β deposition (arrowheads) are observed. Dog No. 33, 16 years old. Immunohistochemistry for A β 42. Scale bar=250 μ m.

Fig. 3. SP is detected in an area of the cerebral cortex (left), while a cluster of CAA is observed in the area lacking SP (right). Dog No. 24, 15 years old. Immunohistochemistry for A β 42. Scale bar=250 μ m.

Fig. 4. (a) Cor-CAA score 0. Dog No. 5, 9 years old. (b) Cor-CAA score 1. Small amount of CAA is observed. Dog No. 13, 12 years old. (c) Cor-CAA score 2. Severe CAA is observed all over the area. Dog No. 32, 16 years old. Immunohistochemistry for A β 42. Scale bar=100 μ m.

Fig. 5. (a) Lm-CAA score 0. (b) Lm-CAA score 1. Slight A β deposition is observed in the tunica media of a leptomeningeal vessel. Dog No. 10, 10 years old. (c) Lm-CAA score 2. Severe A β deposition is observed in the tunica media of a leptomeningeal vessel. Dog No. 13, 12 years old. Immunohistochemistry for A β 42. Scale bar=100 μ m.

Area ratio of U β Q (%), the number of astrocytes (/mm²) and the number of microglia (/mm²) were quantified with digital images ($\times 40$) in the cortex around the coronal sulcus in FC. One sample that showed a weak immunoreactiv-

ity with anti-Iba-1 antibody, possibly due to postmortem change, was excluded from the analysis.

Data analysis: Statistical analysis was performed using the IBM SPSS Statistics 22.0 software (IBM Japan, Tokyo,

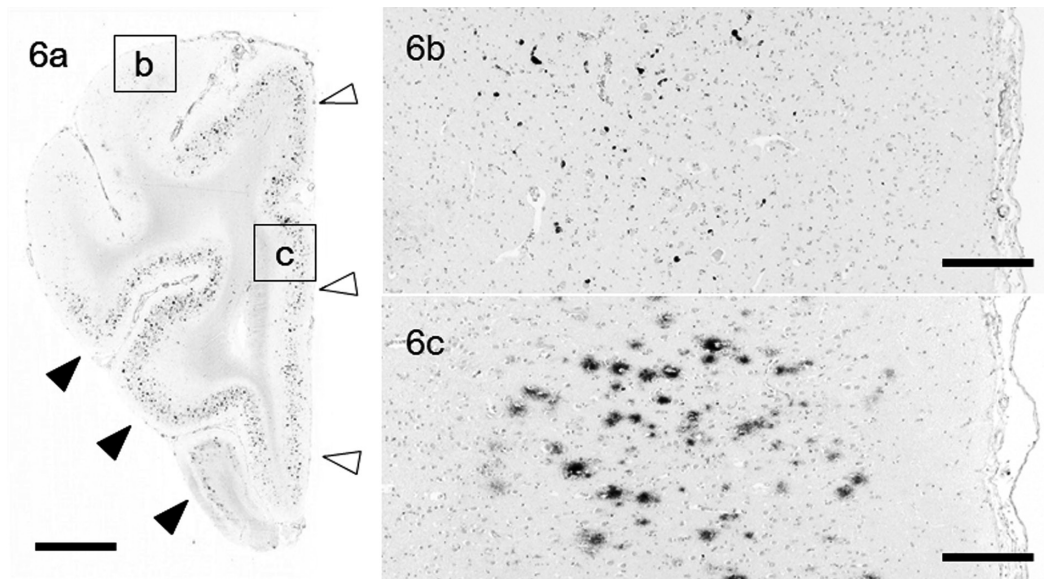


Fig. 6. (a) More SP is observed in the ventral areas (black arrowhead) and around the longitudinal cerebral fissure (white arrowhead). On the other hand, Cor-CAA is severe in the dorsal areas. Dog No. 25. Immunohistochemistry for A β 42. Scale bar = 5 mm. (b) Higher magnification of the square b in (a). Scale bar = 250 μ m. (c) Higher magnification of square c in (a). Scale bar = 250 μ m.

Japan). The significance levels were less than 5%. Curve fitting on scatter plots was performed using the polynomial regression model (linear or quadratic). The Spearman's rank correlation coefficient with two-tailed *P*-values was used to evaluate the correlations between variables.

RESULTS

Histopathological findings: SPs were observed in the brains of dogs of 10 years or older. Although the severity of SP varied among dogs of a similar age, the overall severity of SP increased drastically between 10 and 14 years old (Fig. 1). The peak age was around 14. SPs were distributed in the whole of the sulcus or gyrus at these ages. In brains older than 14 years, SPs were decreased in the cortical areas, but diffuse A β depositions were increased (Fig. 2). Also, CAA tended to occur in the cortical areas lacking or containing a very small number of SPs (Fig. 3).

The severity of Cor-CAA continuously increased with age (Fig. 4). CAA in the capillary wall was often observed as a cluster, while it was observed dispersedly in the arteriole wall. The severity of Lm-CAA also continuously increased with age (Fig. 5). The A β deposition occurred initially at a part of the tunica media of the vessel and then extended to the whole of the circumference with aging.

The SP and CAA tended to be separately distributed in the cerebral cortex. More SPs were observed in the ventral cortex and around the longitudinal cerebral fissure of the FC. On the contrary, Cor-CAA and Lm-CAA were more severe in the dorsal area of the FC and PTC (Figs. 6 and 7). This tendency was relatively consistent, regardless of the aging process (Fig. 7).

UBQ deposition was observed in the neuropil and severer in the white matter than in the cortex. However, older dogs showed considerable and various amounts of UBQ also in the cortex (Fig. 8).

A slight to moderate age-related increase of the number of astrocytes (Fig. 9), and no such increase of microglia (Fig. 10), were observed in the brains of the dogs. The number of nerve cells did not change with age.

Age-related brain lesions: The CCD score plots fitted a linear line, and the score significantly increased with age ($y=2.553x+9.122$, $R^2=0.284$, $P<0.05$) (Fig. 11A). The SP score plots fitted a convex upward quadratic curve ($y=-0.075x^2+2.115x-10.048$, $R^2=0.321$, $P<0.01$) (Fig. 11B), and the score increased until 14 years old, but tended to decrease at older ages. The Cor-CAA score plots fitted a convex downward quadratic curve, and the score significantly increased with age, especially sharply from older than 14 years ($y=0.053x^2-0.714x+2.209$, $R^2=0.475$, $P<0.001$) (Fig. 11C). The Lm-CAA score plots also fitted a linear line, and the score significantly increased with age ($y=0.858x-5.159$, $R^2=0.690$, $P<0.001$) (Fig. 11D). The area ratio plots of UBQ fitted a quadratic curve ($y=-0.002x^2+0.055x-0.250$, $R^2=0.234$, $P<0.05$) (Fig. 12A). The plots of the numbers of astrocytes, microglia and nerve cells fitted neither linear nor quadratic curves (Fig. 12B–D).

Relation of CCD with age-related brain lesions: The CCD score significantly correlated with the Lm-CAA score, area ratio of UBQ, the number of astrocytes and the number of microglia (Table 4, Figs. 13 and 14), and showed a tendency to increase with the Cor-CAA score ($r=0.488$, $P=0.055$, $n=16$). Table 4 summarizes the correlations among age, CCD score and brain lesions.

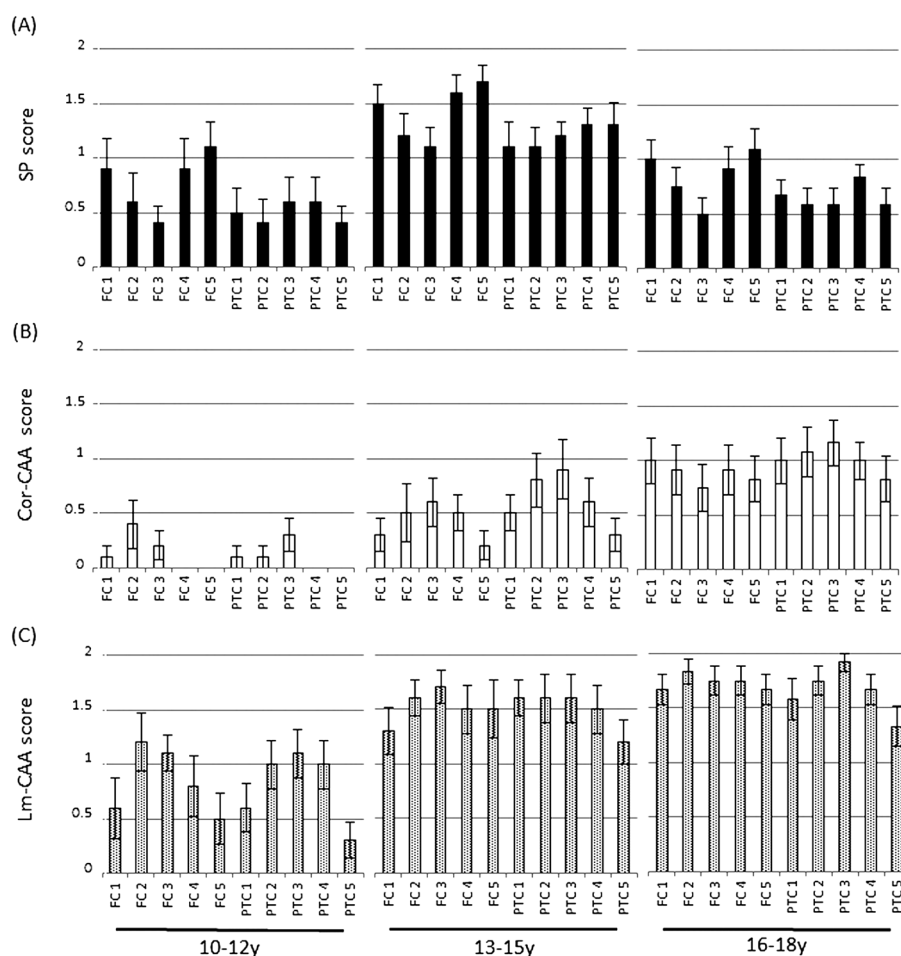


Fig. 7. Scores of SP (A), Cor-CAA (B) and Lm-CAA (C) in FC1-5 and PTC1-5 in the 3 age groups. FC1; longitudinal cerebral fissure, FC2; anterior suprasylvian gyrus, FC3; coronal sulcus and anterior suprasylvian gyrus, FC4; presylvian sulcus, FC5; proreus gyrus and sulcus olfactorius, PTC1; cingulate gyrus, splenialis sulcus and suprasplenialis sulcus, PTC2; lateral gyrus and superior side of lateral sulcus, PTC3; inferior side of lateral sulcus, medial suprasylvian gyrus and superior side of medial suprasylvian sulcus, PTC4; superior part of ectosylvian gyrus to posterior suprasylvian gyrus, PTC5; inferior part of ectosylvian gyrus to posterior suprasylvian gyrus.

DISCUSSION

In the present study, the relation between CCD and the age-related histopathological brain lesions, such as SP and CAA, was investigated. The results revealed no significant correlation between the severities of CCD and SP. Interestingly, the severity of SP increased until 14 years old, but tended to decrease thereafter, regardless of the high incidence of CCD at the older ages. In addition, severe SP formation was observed also in dogs without CCD around 14 years old, and mild SP formation in some CCD dogs at the older ages. Further, the number of nerve cells correlated with neither the severity of SP nor CCD. Therefore, canine SP might not be involved in neuronal death or behavioral dysfunction, unlike SP in human Alzheimer's disease. Canine SP consists largely of diffuse plaques, the most primitive subtype of

SP, and amyloid-containing matured plaques are very rare [7, 30]. The different ratio of SP subtypes between humans and dogs might cause the different pathological significance of SP. Also, the difference of the duration of the A β load, which is much longer in patients of Alzheimer's disease than in aged dogs, possibly explains the different influence of SPs on the pathogenesis.

The reason of the decrease of canine SPs at the older ages is uncertain. SPs are reported to regress in the later stage of Alzheimer's brain in human, and the mechanism is suggested to involve the degradation by astrocytic and microglial phagocytosis at the ages [17]. Since glia tended to increase in old dogs, a similar degradation mechanism to the human cases may be involved also in the canine cases.

Canine Cor-CAA and Lm-CAA exhibited a weak statistical correlation with CCD. On the other hand, the correlation

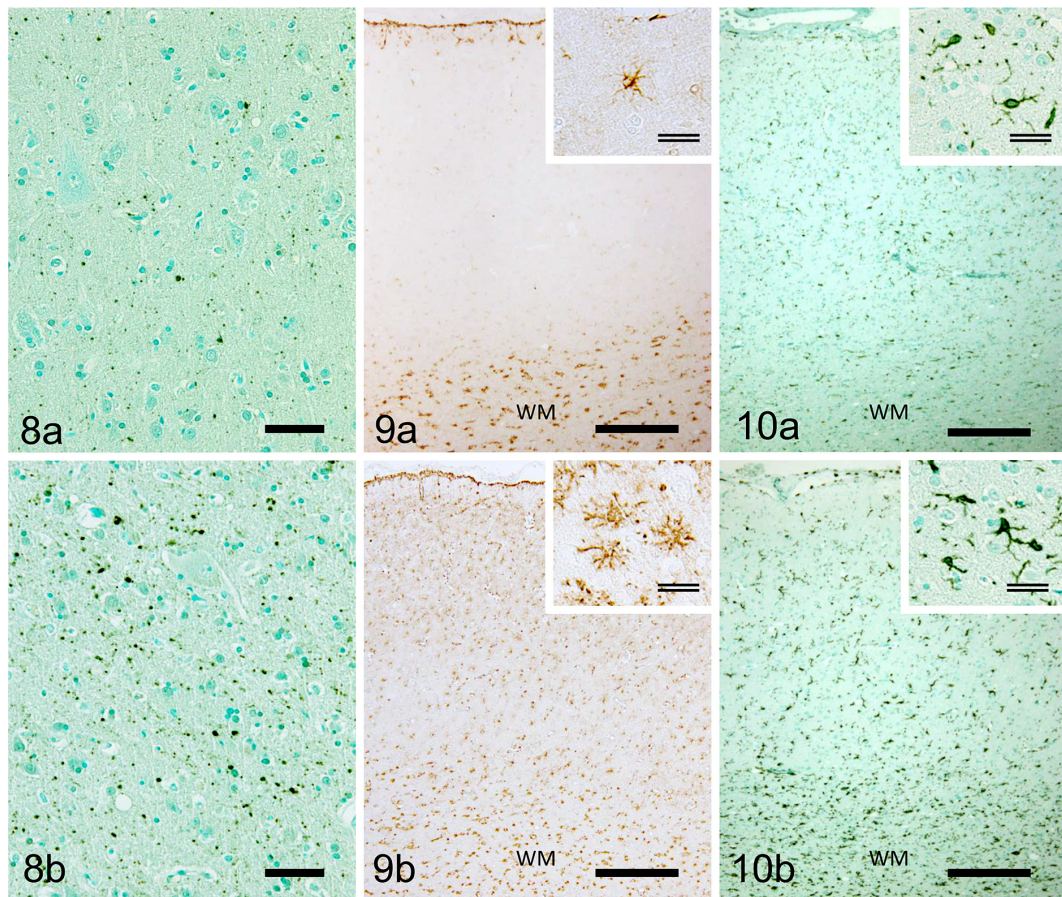


Fig. 8. Immunohistochemistry for UBQ. (a) Normal UBQ immunoreactivity in an aged dog. Dog No. 12, 11 years old. (b) Increased UBQ. Dog No. 21, 14 years old. Scale bar=50 μ m.

Fig. 9. Immunohistochemistry for GFAP. (a) Normal GFAP immunoreactivity in an aged dog. Dog No. 12, 11 years old. (b) Increased GFAP-positive astrocytes with activated shape. Dog No. 21, 14 years old. Scale bar (single line) = 250 μ m, scale bar (double lines) = 25 μ m. WM: White matter.

Fig. 10. Immunohistochemistry for Iba-1. (a) Normal Iba-1 immunoreactivity in an aged dog. Dog No. 12, 11 years old. (b) Slightly increased Iba-1-positive microglia with activated shape. Dog No. 21, 14 years old. Scale bar (single line) = 250 μ m, scale bar (double lines) = 25 μ m. WM: White matter.

between age and CAA was stronger than the correlation between CCD and CAA. The Cor-CAA and Lm-CAA continuously increased with age. A considerable amount of CAA was observed even in old dogs with a low CCD score. Thus, the positive relationship between CAA and CCD might be a confounding bias of brain aging rather than a direct link between them.

Additionally, our results revealed an interesting distribution of SP and CAA, two major lesions of A β deposition. The severities of Cor-CAA and Lm-CAA correlated strongly with each other. On the other hand, the severity of SP and that of CAA showed only a weak correlation. Severely affected areas of SP and CAA were separately distributed rather than mixed. These results suggest that there may be different mechanisms to form these lesions. Also in human, the distribution of SP and CAA does not always overlap. It is suggested that the two lesions may develop individually

through different factors, such as the ratio of A β 40/42 in the brain or other cerebrovascular abnormalities [2, 33].

The other results in the present study suggested that the amount of UBQ, the number of astrocytes and microglia positively correlated with the CCD aggravation. A previous study by immunoelectron microscopy revealed that UBQ is distributed in the synaptic process and myelin in dogs as in humans [15]. Ubiquitinated proteins are normally degraded by the ubiquitin-proteasome system. Misfolded proteins are also eliminated by this system [29]. The system also regulates the quantity of postsynaptic scaffold proteins and neurotransmitter receptors, and plays an important role in the synapse plasticity [29]. The increase of ubiquitinated proteins in the brain of CCD dogs may suggest the failure of protein homeostasis in the synapse and/or myelin. Thus, such changes might be involved in the pathogenesis of CCD.

The increase and activation of glial cells are suggested to

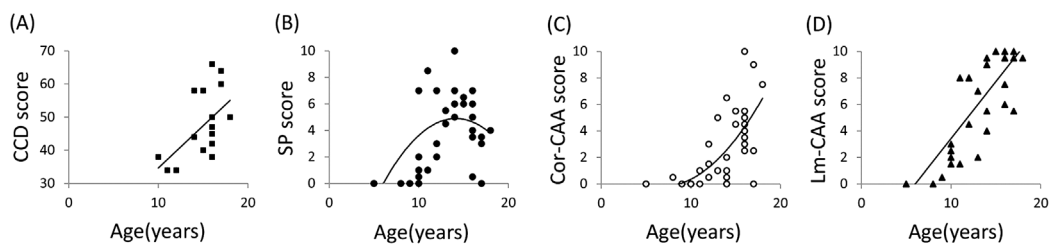


Fig. 11. Age-related changes of CCD score (A) examined in 16 dogs and those of scores of SP (B), Cor-CAA (C) and Lm-CAA (D) examined in 37 dogs.

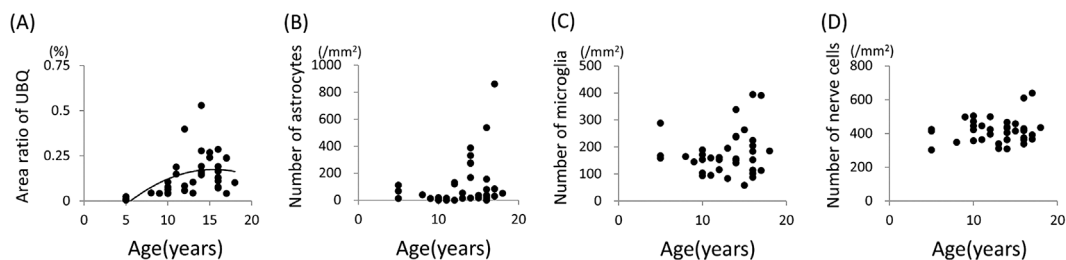


Fig. 12. Age-related changes of area ratio of UBQ (A) and of the numbers of astrocytes (B), microglia (C) and nerve cells (D) examined in 37 dogs (36 dogs for microglia).

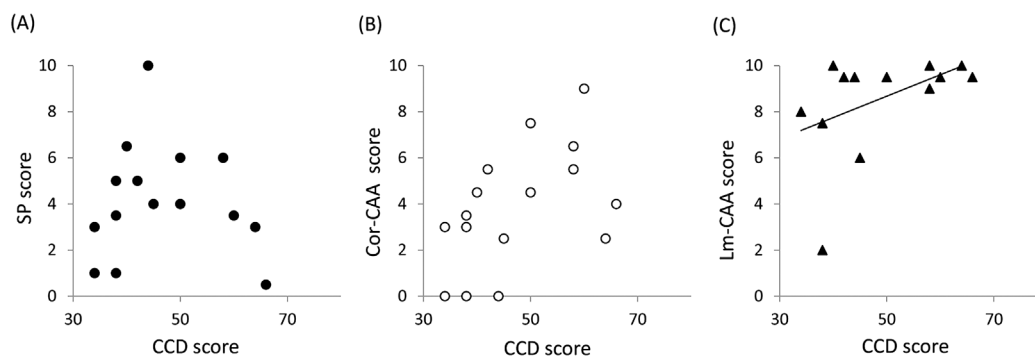


Fig. 13. Relation between CCD score and the score of SP (A), Cor-CAA (B) or Lm-CAA (C) in 16 dogs.

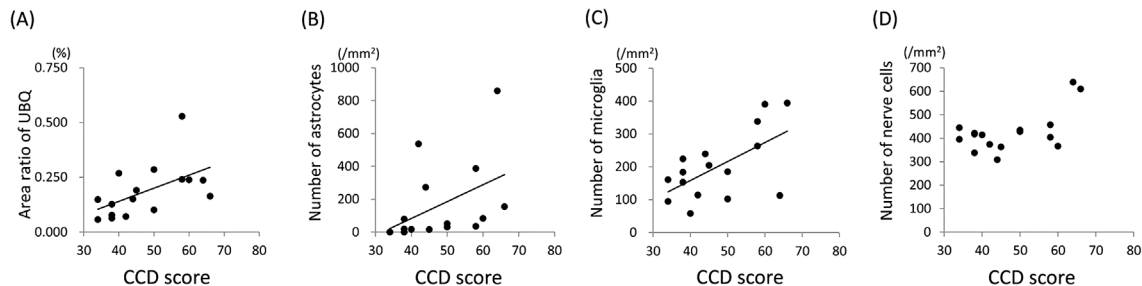


Fig. 14. Relation between CCD score and the area ratio of UBQ (A) or the number of astrocytes (B), microglia (C) and nerve cells (D) examined in 16 dogs.

Table 4. Correlations among age, CCD score and brain lesions

	Age	CCD score	SP score	Cor-CAA score	Lm-CAA score	Area ratio of UBQ (%)	Number of astrocytes (/mm ²)	Number of microglia (/mm ²)	Number of nerve cells (/mm ²)
Age	$r=1.000$ n=37								
CCD score	$r=0.568$ $P<0.05$	$r=1.000$ n=16							
SP score	$r=0.349$ $P<0.05$	$r=0.077$ Ns	$r=1.000$ n=37						
Cor-CAA score	$r=0.709$ $P<0.01$	$r=0.488$ $P<0.1$	$r=0.357$ $P<0.05$	$r=1.000$ n=37					
Lm-CAA score	$r=0.774$ $P<0.01$	$r=0.590$ $P<0.05$	$r=0.407$ $P<0.05$	$r=0.717$ $P<0.01$	$r=1.000$ n=37				
Area ratio of UBQ (%)	$r=0.513$ $P<0.01$	$r=0.628$ $P<0.01$	$r=0.524$ $P<0.01$	$r=0.492$ $P<0.01$	$r=0.659$ $P<0.01$	$r=1.000$ n=37			
Number of astrocytes (mm ²)	$r=0.346$ $P<0.05$	$r=0.670$ $P<0.01$	$r=0.263$ Ns	$r=0.251$ Ns	$r=0.384$ $P<0.05$	$r=0.346$ $P<0.05$	$r=1.000$ n=37		
Number of microglia (mm ²)	$r=0.087$ Ns	$r=0.514$ $P<0.05$	$r=-0.180$ Ns	$r=-0.054$ Ns	$r=-0.026$ Ns	$r=-0.012$ Ns	$r=0.270$ Ns	$r=1.000$ n=36	
Number of nerve cells (mm ²)	$r=0.026$ Ns	$r=0.339$ Ns	$r=-0.115$ Ns	$r=-0.028$ Ns	$r=0.199$ Ns	$r=0.173$ Ns	$r=-0.039$ Ns	$r=-0.186$ Ns	$r=1.000$ n=37

r =Spearman's rank correlation coefficient. P =Probability level. Ns: Not significant.

be associated with the onset of neurodegenerative diseases [4, 11, 26, 27]. The glial increase and activation after the exposure to misfolded or aggregated proteins may induce in the clearance of these proteins [11]. Glial cells are also activated in the old brain due to a failure in the homeostatic balance of inflammatory and anti-inflammatory molecules [26, 27]. The increase of glial cells also causes a brain damage through immunological mechanisms, such as the imbalance of cytokines, interleukins and other potentially cytotoxic molecules released from activated glia [11, 26, 27]. Also, glial alteration influences the dopaminergic system that is relevant to animal behavior [19]. Thus, the increase in glial cells possibly aggravates the CCD condition.

Previous studies revealed that the increase in the number of astrocytes was prominent in the cortex, subcortical and deep white matter of the cerebrum and the cortico-medullary junction in dogs [20]. On the other hand, UBQ was scattered throughout the white matter, but showed no change between frontal and temporal lobes [1, 15]. Further studies are needed to clarify culprit brain regions of CCD conditions.

On the other hand, mild increases of UBQ and glial cells were observed also in old dogs without CCD, suggesting that there was a pathological spectrum between normal brain aging and CCD. We therefore hypothesize that dogs with CCD consist of cases with extremely developed brain aging, rather than of cases with a neurodegenerative disease caused by a specific pathogenic factor.

The results in the present study may indicate that A β deposition, especially in the form of SP, is not a direct pathogenic factor of CCD, and that the possible impairment of the synapse and/or myelin, indicated by the increased amount of

UBQ deposits, and glial activation within the normal aging process may be involved more closely in the pathological mechanism of CCD.

ACKNOWLEDGMENTS. We are grateful to owners and veterinarians of the examined dogs who participated in this research.

REFERENCES

1. Chambers, J. K., Uchida, K. and Nakayama, H. 2012. White matter myelin loss in the brains of aged dogs. *Exp. Gerontol.* **47**: 263–269. [Medline] [CrossRef]
2. Charidimou, A., Gang, Q. and Werring, D. J. 2012. Sporadic cerebral amyloid angiopathy revisited: recent insights into pathophysiology and clinical spectrum. *J. Neurol. Neurosurg. Psychiatry* **83**: 124–137. [Medline] [CrossRef]
3. Colle M-A., Hauw J-J., Crespeau, F., Uchihara, T., Akiyama, H., Checler, F., Pageat, P. and Duykaerts, C. 2000. Vascular and parenchymal Abeta deposition in the aging dog: correlation with behavior. *Neurobiol. Aging* **21**: 695–704. [Medline] [CrossRef]
4. Cudaback, E., Jorstad, N. L., Yang, Y., Montine, T. J. and Keene, C. D. 2014. Therapeutic implications of the prostaglandin pathway in Alzheimer's disease. *Biochem. Pharmacol.* **88**: 565–572. [Medline] [CrossRef]
5. Cummings, B. J., Head, E., Afagh, A. J., Milgram, N. W. and Cotman, C. W. 1996. β -amyloid accumulation correlates with cognitive dysfunction in the aged canine. *Neurobiol. Learn. Mem.* **66**: 11–23. [Medline] [CrossRef]
6. Cummings, B. J., Head, E., Ruehl, W., Milgram, N. W. and Cotman, C. W. 1996. The canine as an animal model of human aging and dementia. *Neurobiol. Aging* **17**: 259–268. [Medline] [CrossRef]

7. Cummings, B. J., Su, J. H., Cotman, C. W., White, R. and Russell, M. J. 1993. β -amyloid accumulation in aged canine brain: a model of early plaque formation in Alzheimer's disease. *Neurobiol. Aging* **14**: 547–560. [[Medline](#)] [[CrossRef](#)]
8. Fast, R., Schütt, T., Toft, N., Møller, A. and Berendt, M. 2013. An observational study with long-term follow-up of canine cognitive dysfunction: clinical characteristics, survival, and risk factors. *J. Vet. Intern. Med.* **27**: 822–829. [[Medline](#)] [[CrossRef](#)]
9. Head, E., McCleary, R., Hahn, F. F., Milgram, N. W. and Cotman, C. W. 2000. Region-specific age at onset of β -amyloid in dogs. *Neurobiol. Aging* **21**: 89–96. [[Medline](#)] [[CrossRef](#)]
10. Head, E. 2013. A canine model of human aging and Alzheimer's disease. *Biochim. Biophys. Acta* **1832**: 1384–1389. [[Medline](#)] [[CrossRef](#)]
11. Heneka, M. T., Carson, M. J., El Khoury, J., Landreth, G. E., Brosseron, F., Feinstein, D. L., Jacobs, A. H., Wyss-Coray, T., Vitorica, J., Ransohoff, R. M., Herrup, K., Frautschy, S. A., Finsen, B., Brown, G. C., Verkhratsky, A., Yamanaka, K., Koistinaho, J., Latz, E., Halle, A., Petzold, G. C., Town, T., Morgan, D., Shinohara, M. L., Perry, V. H., Holmes, C., Bazan, N. G., Brooks, D. J., Hunot, S., Joseph, B., Deigendesch, N., Garaschuk, O., Boddeke, E., Dinarello, C. A., Breitner, J. C., Cole, G. M., Golenbock, D. T. and Kummer, M. P. 2015. Neuroinflammation in Alzheimer's disease. *Lancet Neurol.* **14**: 388–405. [[Medline](#)] [[CrossRef](#)]
12. Kiatipattanasakul, W., Nakamura, S., Hossain, M. M., Nakayama, H., Uchino, T., Shumiya, S., Goto, N. and Doi, K. 1996. Apoptosis in the aged dog brain. *Acta Neuropathol.* **92**: 242–248. [[Medline](#)] [[CrossRef](#)]
13. Landsberg, G. M., Deporter, T. and Araujo, J. A. 2011. Clinical signs and management of anxiety, sleeplessness, and cognitive dysfunction in the senior pet. *Vet. Clin. North Am. Small Anim. Pract.* **41**: 565–590. [[Medline](#)] [[CrossRef](#)]
14. Landsberg, G. M., Nichol, J. and Araujo, J. A. 2012. Cognitive dysfunction syndrome: a disease of canine and feline brain aging. *Vet. Clin. North Am. Small Anim. Pract.* **42**: 749–768, vii. [[Medline](#)] [[CrossRef](#)]
15. Migheli, A., Attanasio, A., Pezzulo, T., Gullotta, F., Giordana, M. T. and Schiffer, D. 1992. Age-related ubiquitin deposits in dystrophic neurites: an immunoelectron microscopic study. *Neuropathol. Appl. Neurobiol.* **18**: 3–11. [[Medline](#)] [[CrossRef](#)]
16. Neilson, J. C., Hart, B. L., Cliff, K. D. and Ruehl, W. W. 2001. Prevalence of behavioral changes associated with age-related cognitive impairment in dogs. *J. Am. Vet. Med. Assoc.* **218**: 1787–1791. [[Medline](#)] [[CrossRef](#)]
17. Oide, T., Kinoshita, T. and Arima, K. 2006. Regression stage senile plaques in the natural course of Alzheimer's disease. *Neuropathol. Appl. Neurobiol.* **32**: 539–556. [[Medline](#)] [[CrossRef](#)]
18. Osella, M. C., Re, G., Odore, R., Girardi, C., Badino, P., Barbero, R. and Bergamasco, L. 2007. Canine cognitive dysfunction syndrome: prevalence, clinical signs and treatment with a neuroprotective nutraceutical. *Appl. Anim. Behav. Sci.* **105**: 297–310. [[CrossRef](#)]
19. Ownby, R. L. 2010. Neuroinflammation and cognitive aging. *Curr. Psychiatry Rep.* **12**: 39–45. [[Medline](#)] [[CrossRef](#)]
20. Papaioannou, N., Tooten, P. C., van Ederen, A. M., Bohl, J. R., Rofina, J., Tsangaris, T. and Gruys, E. 2001. Immunohistochemical investigation of the brain of aged dogs. I. Detection of neurofibrillary tangles and of 4-hydroxynonenal protein, an oxidative damage product, in senile plaques. *Amyloid* **8**: 11–21. [[Medline](#)] [[CrossRef](#)]
21. Rofina, J. E., van Ederen, A. M., Toussaint, M. J., Secrève, M., van der Spek, A., van der Meer, I., Van Eerdenburg, F. J. and Gruys, E. 2006. Cognitive disturbances in old dogs suffering from the canine counterpart of Alzheimer's disease. *Brain Res.* **1069**: 216–226. [[Medline](#)] [[CrossRef](#)]
22. Ruehl, W. W., Bruyette, D. S., DePaoli, A., Cotman, C. W., Head, E., Milgram, N. W. and Cummings, B. J. 1995. Canine cognitive dysfunction as a model for human age-related cognitive decline, dementia and Alzheimer's disease: clinical presentation, cognitive testing, pathology and response to 1-deprenyl therapy. *Prog. Brain Res.* **106**: 217–225. [[Medline](#)] [[CrossRef](#)]
23. Salvin, H. E., McGreevy, P. D., Sachdev, P. S. and Valenzuela, M. J. 2010. Under diagnosis of canine cognitive dysfunction: a cross-sectional survey of older companion dogs. *Vet. J.* **184**: 277–281. [[Medline](#)] [[CrossRef](#)]
24. Salvin, H. E., McGreevy, P. D., Sachdev, P. S. and Valenzuela, M. J. 2011. The canine cognitive dysfunction rating scale (CCDR): a data-driven and ecologically relevant assessment tool. *Vet. J.* **188**: 331–336. [[Medline](#)] [[CrossRef](#)]
25. Satou, T., Cummings, B. J., Head, E., Nielson, K. A., Hahn, F. F., Milgram, N. W., Velazquez, P., Cribbs, D. H., Tenner, A. J. and Cotman, C. W. 1997. The progression of β -amyloid deposition in the frontal cortex of the aged canine. *Brain Res.* **774**: 35–43. [[Medline](#)] [[CrossRef](#)]
26. Simen, A. A., Bordner, K. A., Martin, M. P., Moy, L. A. and Barry, L. C. 2011. Cognitive dysfunction with aging and the role of inflammation. *Ther. Adv. Chronic Dis.* **2**: 175–195. [[Medline](#)] [[CrossRef](#)]
27. Sparkman, N. L. and Johnson, R. W. 2008. Neuroinflammation associated with aging sensitizes the brain to the effects of infection or stress. *Neuroimmunomodulation* **15**: 323–330. [[Medline](#)] [[CrossRef](#)]
28. Thal, D. R., Ghebremedhin, E., Orantes, M. and Wiestler, O. D. 2003. Vascular pathology in Alzheimer disease: correlation of cerebral amyloid angiopathy and arteriosclerosis/lipohyalinosis with cognitive decline. *J. Neuropathol. Exp. Neurol.* **62**: 1287–1301. [[Medline](#)] [[CrossRef](#)]
29. Tsai, N. P. 2014. Ubiquitin proteasome system-mediated degradation of synaptic proteins: An update from the postsynaptic side. *Biochim. Biophys. Acta* **1843**: 2838–2842. [[Medline](#)] [[CrossRef](#)]
30. Uchida, K., Nakayama, H. and Goto, N. 1991. Pathological studies on cerebral amyloid angiopathy, senile plaques and amyloid deposition in visceral organs in aged dogs. *J. Vet. Med. Sci.* **53**: 1037–1042. [[Medline](#)] [[CrossRef](#)]
31. Uchida, K., Kuroki, K., Yoshino, T., Yamaguchi, R. and Tateyama, S. 1997. Immunohistochemical study of constituents other than β -protein in canine senile plaques and cerebral amyloid angiopathy. *Acta Neuropathol.* **93**: 277–284. [[Medline](#)] [[CrossRef](#)]
32. Uchida, K., Tani, Y., Uetsuka, K., Nakayama, H. and Goto, N. 1992. Immunohistochemical studies on canine cerebral amyloid angiopathy and senile plaques. *J. Vet. Med. Sci.* **54**: 659–667. [[Medline](#)] [[CrossRef](#)]
33. Yamada, M. 2015. Cerebral amyloid angiopathy: emerging concepts. *J. Stroke* **17**: 17–30. [[Medline](#)] [[CrossRef](#)]
34. Yoshino, T., Uchida, K., Tateyama, S., Yamaguchi, R., Nakayama, H. and Goto, N. 1996. A retrospective study of canine senile plaques and cerebral amyloid angiopathy. *Vet. Pathol.* **33**: 230–234. [[Medline](#)] [[CrossRef](#)]