

Results of Crowe Type IV Developmental Dysplasia of Hip Treated by Subtrochantric Osteotomy and Total Hip Arthroplasty

Abstract

Background: Crowe type IV developmental dysplasia of hip (DDH), subtrochanteric shortening osteotomy is required to restore the hip joint. Several approaches have been described for subtrochanteric shortening osteotomy. Several osteotomy fixation techniques have been defined for Crowe type IV DDH. This study evaluates the outcomes of subtrochanteric shortening osteotomy fixed with a combination of split onlay autograft and distal fluted femoral stem. **Materials and Methods:** A retrospective study was carried out on 41 hips of 37 patients treated with total hip replacement for Crowe type IV developmental dysplasia of the hip by subtrochanteric transverse osteotomy and fixed with split intercalary autograft by two cables. A femoral stem with proximal coated and distally fluted was used. The patients were evaluated at a mean of 34 months (range 12–68 months) for union time, leg equalization, and clinical outcomes. **Results:** Mean time of union was 13.5 ± 4.6 weeks (range 6–24 weeks). Intraoperative instability of the osteotomy site ($n = 16$) that was encountered at the trial stage was restored properly by this surgical protocol. Leg length discrepancies were improved to 1.4 ± 0.8 cm (range 0–3 cm). Harris scores were improved from 47.7 ± 10.8 (range 30–68) to 88 ± 5.6 (range 72–98) ($P < 0.05$) points. There was no nonunion. **Conclusions:** Distally well-fitted stem and strengthening of fixation with split intercalary autograft promote additional rotational stability and improve bone union.

Keywords: Crowe type IV dysplasia, split onlay autograft, total hip replacement, transverse osteotomy

MeSH terms: Arthroplasty, replacement, hip, osteotomy, autograft

**Murat Altay,
İsmail Demirkale,
Mehmet Faruk
Çatma¹,
Hakan Şeşen,
Serhan Ünlü¹,
Mert Karaduman**

Department of Orthopaedics and Traumatology, Keçiören Education and Research Hospital, ¹Department of Orthopaedics and Traumatology, Dışkapı Yıldırım Beyazıt Education and Research Hospital, Ankara, Turkey

Introduction

Coxarthrosis secondary to developmental hip dysplasia (DDH) causes pain and minimizes functional abilities of the patients. There have been many reports suggesting the reconstruction of the hip joint at the level of the hypoplastic true acetabulum.¹ For Crowe type IV DDH, subtrochanteric shortening osteotomy is required to restore the hip joint at the level of the true acetabulum and to correct leg length discrepancy. Several approaches have been described for subtrochanteric shortening osteotomy.²⁻⁵

To overcome rotational problems at the osteotomy site and to obtain initial stability, osteotomy modifications such as step-cut, V-shaped, z-subtrochanteric, double Chevron, or oblique types as well as fixation of the osteotomy with plates have been defined.⁶⁻⁹ Each technique has its own challenges. Step-cut osteotomy entails technical difficulty and long lasting operation; transverse osteotomy

demands additional technique to achieve rotational stability; and oblique osteotomy requires long femoral stem.¹⁰⁻¹⁴ However, the subtrochanteric osteotomy enables simultaneous shortening and correction of the femoral anteversion as well as serving as a fulcrum for prevention of the rotation at the proximal site of the osteotomy site by preserving metaphysis. Krych *et al.* described their surgical technique for total hip replacement (THR) of coxarthrosis secondary to DDH.^{15,16} In this study, they used modular distal fluted cementless stems and fixed the transverse osteotomy site with split intercalary osteotomized bone obtained from the shortened distal fragment. They claimed that split grafts with maintained vascularity that were affixed around the osteotomy site enhanced stability and promoted biologic healing. Although they found 7% nonunion and 43% late complication or reoperation rates in 28 patients after a mean of 4.8 years followup, the hip scores of the patients were significantly improved.

Address for correspondence:

Prof. İsmail Demirkale,
Pınarbaşı M. Ardahan S.
No: 25, Keçiören 06380,
Ankara, Turkey.
E-mail: drismail@yahoo.com

Access this article online

Website: www.ijoonline.com

DOI:
10.4103/ortho.IJOrtho_445_16

Quick Response Code:



How to cite this article: Altay M, Demirkale I, Çatma MF, Sesen H, Unlu S, Karaduman M. Results of crowe Type IV developmental dysplasia of hip treated by subtrochantric osteotomy and total hip arthroplasty. Indian J Orthop 2018;52:374-9.

This is an open access journal, and articles are distributed under the terms of the Creative Commons Attribution-NonCommercial-ShareAlike 4.0 License, which allows others to remix, tweak, and build upon the work non-commercially, as long as appropriate credit is given and the new creations are licensed under the identical terms.

For reprints contact: reprints@medknow.com

This study evaluates the results of patients with Crowe type IV DDH treated with THR. A subtrochanteric transverse shortening osteotomy and fixation with onlay split intercalary autograft were performed. The two objectives of the study are (a) to determine if this fixation technique promotes early bone healing and provides initial intraoperative stability. Our second (b) to evaluate clinical outcomes by measuring final leg length discrepancy, determining functional scores and complication rates. We hypothesized, on the basis of clinical experience, that combination of distal femoral fit noncemented stem with split intercalary autograft fixed with two cable wires around the osteotomy site provides both proximal and distal rotational stability.

Materials and Methods

41 hips of 37 patients with ages ranging from 26 to 74 years operated between September 2008 and December 2013 were included in this retrospective study. The indication was coxarthrosis secondary to Crowe type IV DDH. Proximally porous-coated femoral stem with hydroxyapatite coating and distally fluted cementless (Secur-Fit Plus Max Femoral Hip Stem [Stryker Orthopaedics]) stem was used, and subtrochanteric transverse osteotomy with the application of onlay intercalary autograft by two cable wires was performed in all cases. The study protocol was approved by the local Institutional Review Board, and informed consent was obtained from all patients.

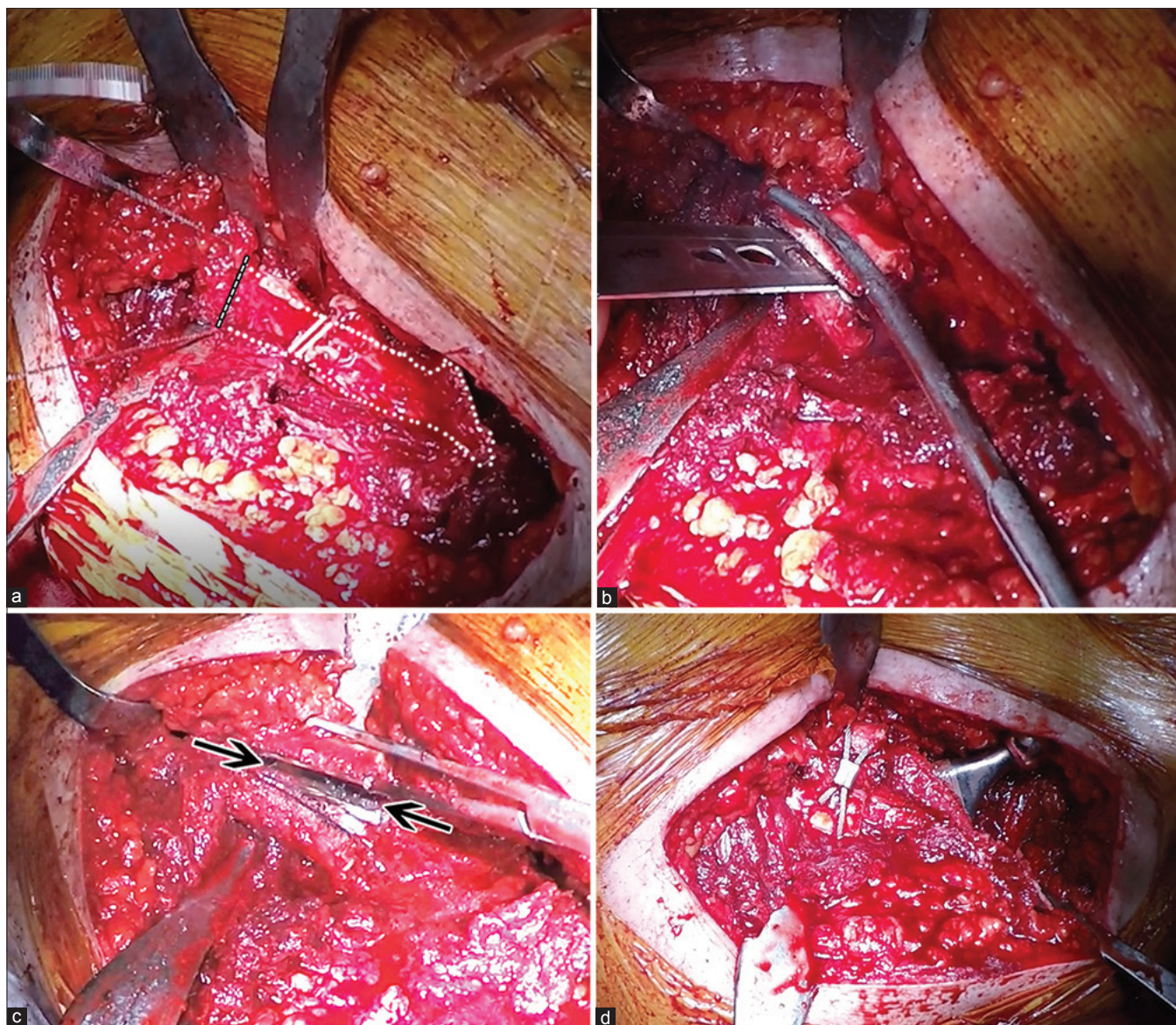


Figure 1: Perioperative photographs showing (a) Preparation and fixation of the split intercalary autograft. Distal part of the osteotomy was cut by Gigli saw (dotted white line). (b) The graft was then split into two equal anterior and posterior parts. (c) The medial (black arrow), anteromedial and posteromedial soft tissue attachments were protected. (d) After implanting the femoral stem, the split graft was fixed by cable wires around the osteotomy site with paying attention not to damage the soft tissue attachments

Operative procedure

The modified Hardinge approach was used in 15 (36.5%) cases, whereas posterior Southern approach was used in 26 (63.4%). The femur was osteotomized transversely, 1–2 cm distal to the lesser trochanter. Following the preparation of the true acetabulum, an area approximately 1 cm inferior to the lesser trochanter in the metaphyseal region was prepared for femoral shortening osteotomy. The level of the subtrochanteric osteotomy was measured by aligning the proximal part of the femur with the acetabulum. Overlapping part of the distal femur was considered as an excess segment, which equals to resection amount. Distal transverse osteotomy was performed. Following multiple small drill holes, Gigli wire saw was used at both subtrochanteric and distal osteotomies so as to prevent thermal necrosis and delayed bone union. Femoral excess segment was hemisected longitudinally. Distally fluted, proximally porous-coated femoral stem with hydroxyapatite coating was preferred as an implant. Every size of it offers two different distal diameters. Thus, it provided better distal engagement, facilitating distal rotational stability, especially in case of excessive femoral bowing. Next, hemisects of femoral excess segment were combined at the osteotomy site and then secured with two wires [Figure 1a-d]. Furthermore, autogenous intramedullary medullary graft obtained from reamer was used around osteotomy site. Hip joint was reduced, following the insertion of fitting femoral head and stability control.

Evaluation

The degree of union was radiologically assessed, quantifying the number of cortices bridged by bone, which was defined by Whelan *et al.*¹⁷ Intraoperative stability of the osteotomy site was defined as obvious movement of the osteotomy line after fixation with graft and cables and original distal fluted stem.

Leg length discrepancy of the patients was measured pre and postoperatively by measurement from the anterior superior iliac spine to the tip of the medial malleolus. Postoperative leg length difference was also determined with radiographic technique based on the measurement from the acetabular teardrop to the lesser trochanter [Figure 2].¹⁸ For the determination of the leg length difference, it was aimed to achieve an agreement between the measurements with a tape measure and by the radiographic method.¹⁹ To demonstrate interobserver agreement consistency, two observers were used to ensure accuracy of the measurements with a kappa test.

Mobilization with partial weight-bearing on crutches was started on the 2nd postoperative day. Followups were planned until bone union at the osteotomy site was observed on the postoperative 3rd and 6th week, 3rd and 6th months, and 1st year. When the bone union at the osteotomy site was observed, Harris hip scores of the patients were noted for pain, function, efficacy, deformity,

Table 1: Clinical details of the patients

| Variables | Participants (n=37) |
|--------------------|---------------------|
| Age (year) | 50.61±11.87 (26-74) |
| Followup (months) | 34.11±19.59 (12-68) |
| Gender (%) | |
| Male | 1 (2.7) |
| Female | 36 (97.2) |
| Osteotomy side (%) | |
| Left | 21 (51.2) |
| Right | 20 (48.7) |
| Approach (%) | |
| Posterior | 26 (63.4) |
| Lateral | 15 (36.5) |

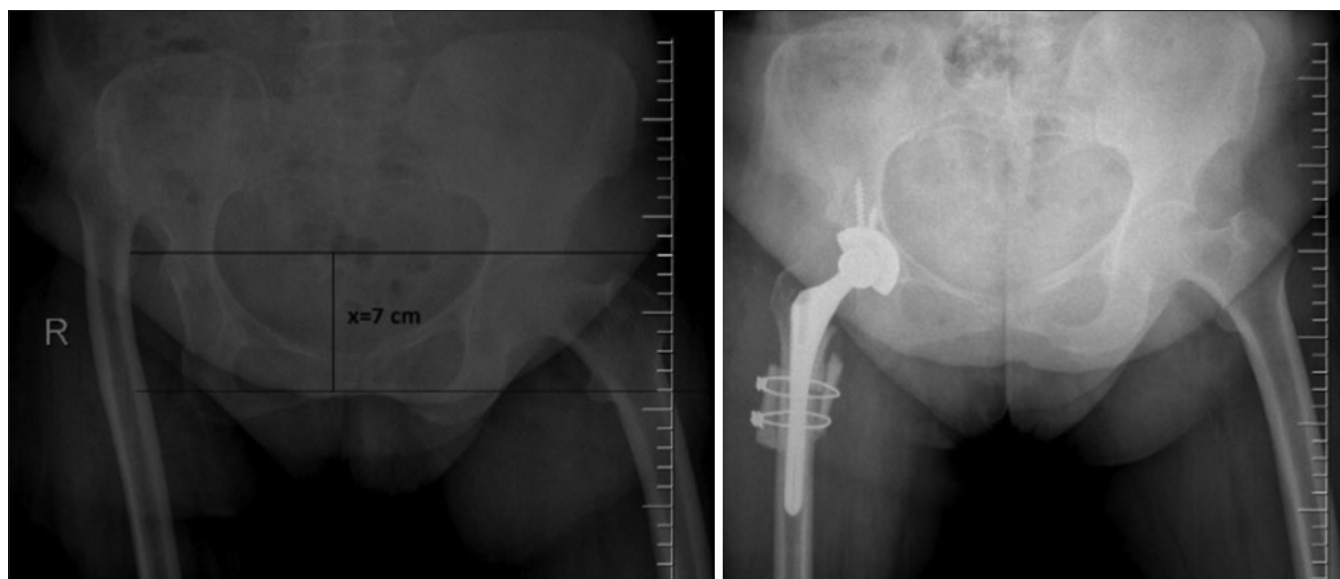


Figure 2: X-ray pelvis showing both hips anteroposterior view showing preoperative measurement of the resection and postoperative X-ray of the same patient

and range of motion. X-rays of the patients were examined to see if there was any femoral loosening in accordance with the guidance by Gruen *et al.*²⁰ Acetabular loosening was checked according to the method by DeLee and Charnley.²¹ Heterotopic ossification was graded as defined by Brooker *et al.*²²

Statistical analysis

SPSS version 11.5 (SPSS Inc., Chicago, IL, USA) package program was used for data analysis. Mean (\pm standard deviation) for metric variables and frequency (percent) for categorical variables were given as descriptive statistics. Interobserver reliability was measured using the simple percentage agreement and Cohen's kappa coefficient. Wilcoxon signed-rank test was used to compare pre- and postoperative Harris scores. $P < 0.05$ was considered statistically significant.

Results

Demographic findings of the patients by age, followup period, gender, osteotomy site, approach, and operation time are shown in Table 1. No patient was lost to followup. The patients were evaluated at a mean of 34 months (range: 12–68 months).

All patients' osteotomies were healed [Figure 3]. Mean time of union was 13.5 ± 4.6 weeks (range 6–24 weeks). At the trial stage, intraoperative proximal or distal stability of the

osteotomy site could not have achieved in 15 (36.6%) hips and 1 (2.4%) hip, respectively. After fixation of the osteotomy site by onlay split autograft, adequate stability was achieved in proximally unstable osteotomies ($n = 15$) and by implanting a large size of a stem in distally unstable osteotomies ($n = 1$).

The interobserver reliability results regarding the clinical leg length (anterior superior iliac spine to medial malleolus) and radiological measurements (distance between two lesser trochanters) for all subjects were excellent ($\kappa = 0.77$ and $\kappa = 0.80$, respectively). The average leg length of the patients was 155.5 ± 7.3 cm (range 140–178 cm). The average femoral shortening was 4 ± 0.8 cm (range 2–5.5 cm). Preoperative leg length discrepancy was 4.8 ± 1.8 cm (range 2–10 cm). Postoperative leg length discrepancy was 1.4 ± 0.8 cm (range: 0–3 cm).

Mean Harris score of the patients was improved from 47.7 ± 10.8 (range 30–68 points) points preoperatively to 88 ± 5.6 (range 72–98 points) points postoperatively ($P < 0.05$). Weight-bearing was restricted in seven patients for 3 weeks due to ineffectual initial cup stability.

There were no neurological deficits in the patients. Postoperative dislocation of the hip joint was encountered on three cases (7.3%). Two of them had decreased acetabular anteversion, and this was corrected with revision in the short run. One patient was found to have distal

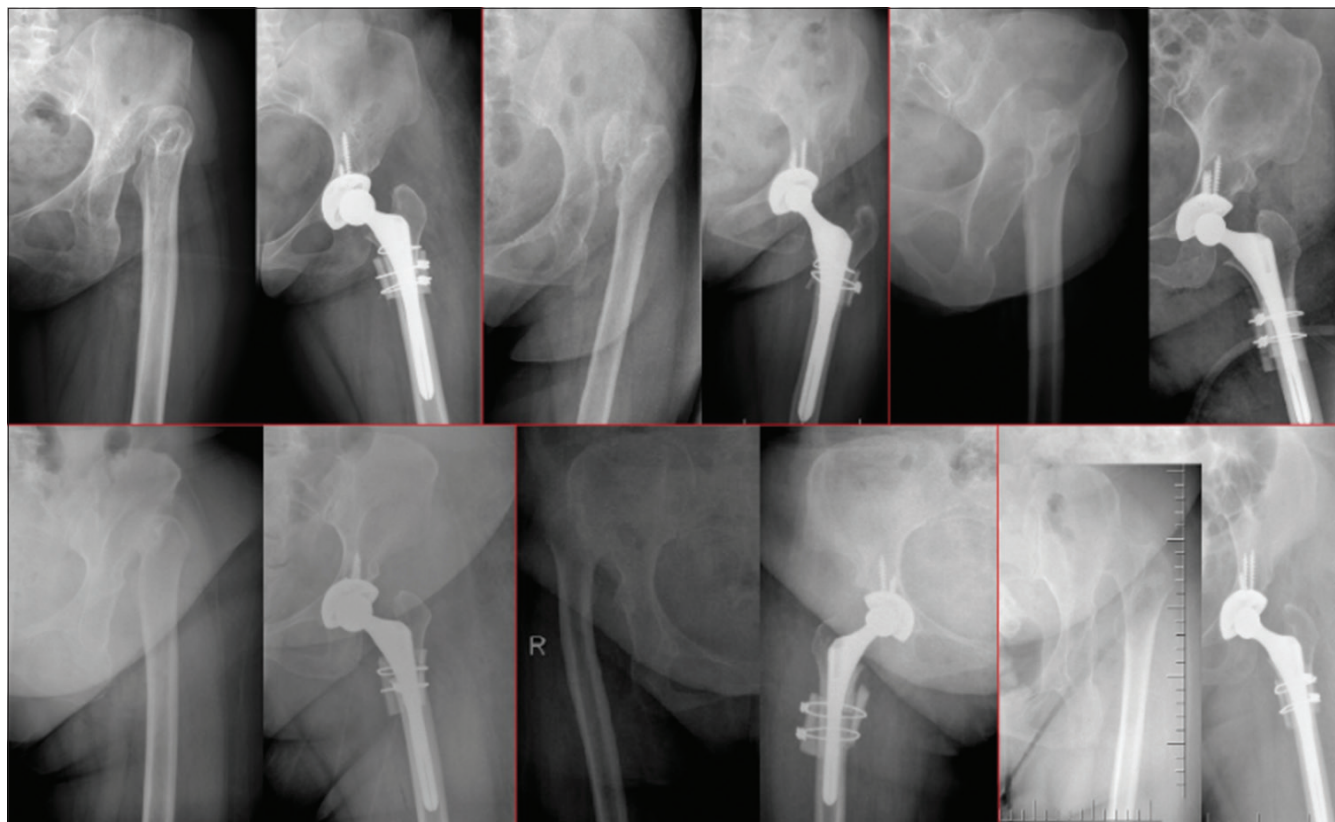


Figure 3: Pre- and postoperative X-rays anteroposterior view of six patients treated with subtrochanteric transverse osteotomy that were fixed by onlay split graft and distal fluted cementless stem showing healed osteotomies in all patients

rotational instability together with insufficient acetabular anteversion. Adequate rotational stability of this patient was achieved with revision using a long stem femoral component. Then, decreased acetabular anteversion was corrected. One (2.7%) of the patients was found to have Brooker Grade I heterotopic ossification and one (2.7%) to have acetabular osteolysis in Zone I. No case of infection in the short or long term was encountered.

Discussion

Fixation of the subtrochanteric osteotomy for shortening of the femur after THR of Crowe type IV dysplastic hips is challenging, and nonunion of the osteotomy leads to secondary interventions. Multiple techniques including step-cut, V-shaped, z-subtrochanteric, double Chevron, or oblique types as well as fixation of the osteotomy with plates have been described.⁶⁻⁹ One of these techniques is subtrochanteric transverse osteotomy, fixed by distally well-fitted cementless stem together with onlay intercalary autograft that was obtained from the femoral resection and fixed around the osteotomy site with two cables.

Our study has some limitations. This study demonstrates our experience of a surgical technique of THR for Crowe type IV hips and consequently cannot compare different techniques. However, our objective was to evaluate clinical and radiological results, and to this avail, we believe that we demonstrated well our experience in one of the complex procedures of orthopedic practice. In addition, radiographic union and additive effect of the graft on healing may be better determined after investigation of the osteotomy site by computerized tomography. We recognize this as a limitation of our study and believe additional investigation examining the osteotomy site would be a valuable addition to the literature.

When compared with those of primary arthroplasty, clinical and radiological results of THR applied to the patients with coxarthrosis secondary to DDH were more challenging. There have been several related studies aiming at describing surgical techniques, intraoperative challenges, management of these challenges, femoral shortening osteotomy methods, measurement of femoral shortening, calculation of osteotomy level, bleeding amount, operation time, and postoperative nerve injury together with its causes. According to studies, coxarthrosis secondary to DDH differs to a great extent from primary coxarthrosis with regard to complications. Reports of hip joint replacement applied to the patients with Crowe type IV DDH addressed problems of acetabular fixation, difficulties to determine appropriate implants and femoral osteotomy methods, challenges to achieve rotational stability, and complications such as hip joint luxation and nonunion at the osteotomy site.

In the study by Bao *et al.*, nonunion rate for transverse and step-cut osteotomy was reported to range between 0% and 14%. Nonunion at the site of osteotomy leads to early loosening of the implant. Furthermore, they used

distally fluted implant to achieve distal engagement.²⁴ To address nonunion problem, while positioning osteotomy line, we initially made small drill holes and performed the osteotomy, using Gigli wire saw. The purpose of this study was to avoid thermal necrosis caused by oscillating saw and associated nonunion problems. There have been reports in the literature regarding the thermal necrosis caused by sagittal saw.^{6,23} Securing this graft around the osteotomy line with wires contributed to adequate rotational stability, especially at the proximal site of the osteotomy where usually deformed metaphysis can be encountered in patients with DDH and prevented the problems of union. Nonunion was not encountered in any of the patients. Similar to the study by Bao *et al.*, we used distally fluted femoral hip stem, which enabled us to achieve rotational stability through distal engagement.²⁴

Femoral hip stem used in our study offered proximal and distal engagement. Every size of it also presents two different options for distal thickness. This helped distal engagement even though distal femoral segment happened to be thick after femoral osteotomy. Preparation of the distal femoral segment separately made possible to snug fit of the fluted part of the stem. Yet, despite these options, distal engagement and rotational stability could not be accomplished at some cases. Splitting femoral excess segment and combining those segments at the osteotomy site, functioning as a cover provided adequate rotational stability and bone union for this group of patients. Among other advantages of the approach were relatively early union time and operation duration.

Changes in hip center of rotation are observed in the cases of failed seating of acetabular component to the true acetabulum. This transforms the biomechanical state of the hip significantly and affects the durability of the reconstruction adversely.¹ We created hip center of rotation in the true acetabulum in the treatment of 37 cases of Crowe type IV DDH. In the related studies, THR, in case of dysplasia, was initiated with acetabular implantation, then proceeded with the femoral reaming and rasping; following, osteotomy was performed.^{15,25} After proper preoperative preparation and templating, we commenced the surgical operation with femoral osteotomy, and then proximal femoral segment was disposed. This sequence enabled the surgeon to access the true acetabulum with ease and to perform the implantation with adequate anteversion and inclination angles.

Current surgical techniques used to stabilize the osteotomy site either by plate fixation or osteotomy modifications can be either cumbersome and add operative time or put risk for delayed union or nonunion. We found that this modification of osteotomy fixation, which prevents rotation at the osteotomy site by both distally well-fitting fluted and cementless stem and fixation of the split intercalary autograft with two cables, allows adequate proximal and distal stability to the osteotomy site. Although no nonunion was encountered in this patient case series, larger

comparative studies are needed to investigate the effect of this approach.

Financial support and sponsorship

Nil.

Conflicts of interest

There are no conflicts of interest.

References

- Johnston RC, Brand RA, Crowninshield RD. Reconstruction of the hip. A mathematical approach to determine optimum geometric relationships. *J Bone Joint Surg Am* 1979;61:639-52.
- Charnley J, Feagin JA. Low-friction arthroplasty in congenital subluxation of the hip. *Clin Orthop Relat Res* 1973;91:98-113.
- Dunn HK, Hess WE. Total hip reconstruction in chronically dislocated hips. *J Bone Joint Surg Am* 1976;58:838-45.
- Linde F, Jensen J, Pilgaard S. Charnley arthroplasty in osteoarthritis secondary to congenital dislocation or subluxation of the hip. *Clin Orthop Relat Res* 1988;227:164-71.
- Yoder SA, Brand RA, Pedersen DR, O'Gorman TW. Total hip acetabular component position affects component losing rates. *Clin Orthop Relat Res* 1988;228:79-87.
- Li Y, Ma W, Sun J, Song X, An M, Zhang Q, *et al.* Becker V-shaped lateral rotation osteotomy in total hip arthroplasty for crowe type IV development dislocation of hip. *Zhongguo Xiu Fu Chong Jian Wai Ke Za Zhi* 2013;27:1032-6.
- Muratli KS, Karatosun V, Uzun B, Celik S. Subtrochanteric shortening in total hip arthroplasty: Biomechanical comparison of four techniques. *J Arthroplasty* 2014;29:836-42.
- Yalcin N, Kilicarslan K, Karatas F, Mutlu T, Yildirim H. Cementless total hip arthroplasty with subtrochanteric transverse shortening osteotomy for severely dysplastic or dislocated hips. *Hip Int* 2010;20:87-93.
- Dallari D, Pignatti G, Stagni C, Giavaresi G, Del Piccolo N, Rani N, *et al.* Total hip arthroplasty with shortening osteotomy in congenital major hip dislocation sequelae. *Orthopedics* 2011;34:e328-33.
- Yasgur DJ, Stuchin SA, Adler EM, DiCesare PE. Subtrochanteric femoral shortening osteotomy in total hip arthroplasty for high-riding developmental dislocation of the hip. *J Arthroplasty* 1997;12:880-8.
- Reikeraas O, Lereim P, Gabor I, Gunderson R, Bjerkreim I. Femoral shortening in total arthroplasty for completely dislocated hips: 3-7 year results in 25 cases. *Acta Orthop Scand* 1996;67:33-6.
- Becker DA, Gustilo RB. Double-chevron subtrochanteric shortening derotational femoral osteotomy combined with total hip arthroplasty for the treatment of complete congenital dislocation of the hip in the adult. preliminary report and description of a new surgical technique. *J Arthroplasty* 1995;10:313-8.
- Anwar MM, Sugano N, Masuhara K, Kadowaki T, Takaoka K, Ono K, *et al.* Total hip arthroplasty in the neglected congenital dislocation of the hip. A five- to 14-year followup study. *Clin Orthop Relat Res* 1993;295:127-34.
- Paavilainen T, Hoikka V, Paavolainen P. Cementless total hip arthroplasty for congenitally dislocated or dysplastic hips. Technique for replacement with a straight femoral component. *Clin Orthop Relat Res* 1993;297:71-81.
- Krych AJ, Howard JL, Trousdale RT, Cabanela ME, Berry DJ. Total hip arthroplasty with shortening subtrochanteric osteotomy in Crowe type-IV developmental dysplasia: Surgical technique. *J Bone Joint Surg Am* 2010;92 Suppl 1(Pt 2):176-87.
- Krych AJ, Howard JL, Trousdale RT, Cabanela ME, Berry DJ. Total hip arthroplasty with shortening subtrochanteric osteotomy in Crowe type-IV developmental dysplasia. *J Bone Joint Surg Am* 2009;91:2213-21.
- Whelan DB, Bhandari M, McKee MD, Guyatt GH, Kreder HJ, Stephen D, *et al.* Interobserver and intraobserver variation in the assessment of the healing of tibial fractures after intramedullary fixation. *J Bone Joint Surg Br* 2002;84:15-8.
- Erdemli B, Yilmaz C, Atalar H, Güzel B, Cetin I. Total hip arthroplasty in developmental high dislocation of the hip. *J Arthroplasty* 2005;20:1021-8.
- Beattie P, Isaacson K, Riddle DL, Rothstein JM. Validity of derived measurements of leg-length differences obtained by use of a tape measure. *Phys Ther* 1990;70:150-7.
- Gruen TA, McNeice GM, Amstutz HC. "Modes of failure" of cemented stem-type femoral components: A radiographic analysis of loosening. *Clin Orthop Relat Res* 1979;141:17-27.
- DeLee JG, Charnley J. Radiological demarcation of cemented sockets in total hip replacement. *Clin Orthop Relat Res* 1976;121:20-32.
- Brooker A, Bowerman JW, Robinson RA, Riley LH Jr. Ectopic ossification following total hip replacement incidence and a method of classification. *J Bone Joint Surg Am* 1973;55:1629-32.
- Park MS, Kim KH, Jeong WC. Transverse subtrochanteric shortening osteotomy in primary total hip arthroplasty for patients with severe hip developmental dysplasia. *J Arthroplasty* 2007;22:1031-6.
- Bao N, Meng J, Zhou L, Guo T, Zeng X, Zhao J, *et al.* Lesser trochanteric osteotomy in total hip arthroplasty for treating Crowe type IV developmental dysplasia of hip. *Int Orthop* 2013;37:385-90.
- Neumann D, Thaler C, Dorn U. Femoral shortening and cementless arthroplasty in crowe type 4 congenital dislocation of the hip. *Int Orthop* 2012;36:499-503.