



Autologous Immunoglobulin Therapy in Patients With Severe Recalcitrant Atopic Dermatitis: Long-Term Changes of Clinical Severity and Laboratory Parameters

Dong-Ho Nahm,* Areum Ahn, Myoung-Eun Kim, Su-Mi Cho, Mi Jung Park

Department of Allergy and Clinical Immunology, Ajou University School of Medicine, Suwon, Korea

This is an Open Access article distributed under the terms of the Creative Commons Attribution Non-Commercial License (<http://creativecommons.org/licenses/by-nc/3.0/>) which permits unrestricted non-commercial use, distribution, and reproduction in any medium, provided the original work is properly cited.

This report evaluated long-term changes in clinical severity and laboratory parameters in 3 adult patients with severe recalcitrant atopic dermatitis (AD) who were treated with intramuscular injections of 50 mg of autologous immunoglobulin G (IgG) twice a week for 4 weeks (autologous immunoglobulin therapy, AIGT) and followed up for more than 2 years after the treatment. We observed the following 4 major findings in these 3 patients during the long-term follow-up after AIGT. (1) Two of the 3 patients showed a long-term clinical improvement for more than 36 weeks after AIGT with a maximum decrease in clinical severity score greater than 80% from baseline. (2) These 2 patients also showed long-term decreases in serum total IgE concentrations and peripheral blood eosinophil count for more than 36 weeks after AIGT with a maximum decrease in the two laboratory parameters of allergic inflammatory greater than 70% from baseline. (3) No significant side effect was observed during the 2 years of follow-up period after the AIGT in all 3 patients. (4) Serum levels of IgG anti-idiotypic antibodies to the F(ab)₂ fragment of autologous IgG administered for the treatment were not significantly changed after AIGT in all 3 patients. These findings suggest that AIGT has long-term favorable effects on both clinical severity and laboratory parameters in selected patients with severe recalcitrant AD. Further studies are required to evaluate the clinical usefulness and therapeutic mechanism of AIGT for AD.

Key Words: Dermatitis, atopic; immunoglobulins; immunomodulation; therapy; antibodies; immunoglobulin G

INTRODUCTION

Atopic dermatitis (AD) is a common chronic allergic inflammatory skin disorder characterized by itching, dry skin, inflammation, and exudation which is frequently associated with a personal or familial history of atopic disease.¹ Recently, a randomized clinical trial showed significant clinical improvements in patients with moderate to severe AD after treatment with monoclonal antibody to interleukin (IL)-4 receptor.² This result suggests that immune dysfunction and hypersensitivity reaction play key roles in the pathogenesis of AD and could be critical therapeutic targets for AD.¹ The majority of patients with AD want a cure or long-term treatment-free clinical remission of AD.¹ However, there is no available therapeutic method that has been proven to modify the long-term clinical course of AD. This unmet need results in various medical and social problems associated with AD in many developed countries.³ Further development of new therapeutic modalities is required to change the long-term clinical course of AD.¹

Various complementary and alternative medicine modalities have been tried for the treatment of AD in many countries, in-

cluding Europe.⁴ Autologous blood therapy (ABT) is reportedly the most commonly used complementary and alternative medicine modality for AD by physicians in Germany, since its first report in 1913.^{4,5} ABT involves the repeated administration of small amounts of autologous blood (1-5 mL) by intramuscular injection immediately after sampling of venous blood.⁶ The positive clinical efficacy of ABT has been demonstrated in patients with AD based on randomized double-blind placebo-controlled study.⁶ A randomized placebo-controlled study showed that ABT induced significant clinical improvements in patients with chronic urticaria and a positive autologous serum skin test.⁷ Recently, autologous serum therapy (repeatedly ad-

Correspondence to: Dong-Ho Nahm, MD, Department of Allergy and Clinical Immunology, Ajou University School of Medicine, 164 Worldcup-ro, Yeongtong-gu, Suwon 16499, Korea.

Tel: +82-31-219-5152; Fax: +82-31-219-5154; E-mail: dhnahm@gmail.com

Received: November 27, 2015; Revised: December 30, 2015;

Accepted: January 15, 2016

- This work was supported by the National Research Foundation of Korea (NRF) grant funded by the Korea government (MSIP) (No. 2014R1A2A1A11049386).
- There are no financial or other issues that might lead to conflict of interest.

ministering small amounts of serum separated from clotted autologous venous blood of patients by intramuscular injection) was also reportedly effective in patients with chronic urticaria in a randomized double-blind placebo-controlled study.⁸ We hypothesized that the blood component mediating the therapeutic efficacy of ABT in patients with AD is the autologous immunoglobulin present in the serum and repeated intramuscular injections of autologous immunoglobulin (autologous immunoglobulin therapy, AIGT) can induce long-term clinical improvements in patients with AD by stimulating active immune responses to the antigen binding sites of pathogenic antibodies, thereby correcting immune dysfunction and hypersensitivity. To prove this hypothesis, we evaluated the clinical efficacy of intramuscular injections of 50 mg of autologous immunoglobulin G (IgG) twice a week for 4 weeks in 20 adult patients with severe AD. We reported a preliminary result of AIGT in 3 patients with severe recalcitrant AD, showing a decrease in clinical severity score of AD during short-term follow-up for 12-24 weeks after AIGT.⁹ In a subsequent study, we also reported that AIGT significantly decreased both clinical severity scores and serum total IgE concentrations in 17 adult patients with severe AD during the short-term follow-up for 12 weeks after AIGT.¹⁰

This report evaluated long-term changes in clinical severity and laboratory parameters for more than 2 years in the 3 adult patients with severe recalcitrant AD who were treated with AIGT.⁹ Additionally, we also tried to analyze changes in the serum levels of anti-idiotypic antibody before and after AIGT in these patients to explore therapeutic mechanisms of AIGT.

MATERIALS AND METHODS

Patients

Three adult patients (case 1, 23 year-old male; case 2, 36 year-old male; case 3, 30 year-old male at the initiation of AIGT) were compatible with severe recalcitrant AD as described in the previous report.⁹ All 3 patients showed the following baseline clinical and laboratory characteristics: (1) typical clinical features of AD compatible with diagnostic criteria for AD suggested by Hanifin and Rajka;¹¹ (2) a strong positive result for serum-specific IgE antibody to *Dermatophagoides farinae* (>35 kU/L) using the ImmunoCAP (Phadia US, Portage, MI, USA); (3) a high serum total IgE concentration (>10,000 kU/L); (4) severe AD with a clinical severity score of AD >50 measured using the standardized clinical severity scoring system for AD (SCORAD), as previously described,^{12,13} and (5) recalcitrant AD in which the clinical condition has not been effectively controlled by medical treatments (topical moisturizers, topical corticosteroids, topical calcineurin inhibitors, oral antihistamines, and others) for more than 2 years. All 3 patients in this report were treated with oral cyclosporine for more than 2 years before the initiation of AIGT. One patient (case 1) was also treated with subcutaneous allergen immunotherapy with house dust mite extract

for more than 2 years without significant clinical improvement before the initiation of AIGT. These all 3 patients had been treated with intramuscular injections of 50 mg of autologous immunoglobulin G twice a week for 4 weeks as described in the previous report,⁹ and these patients were further followed up for more than 2 years after the treatment.

Changes in clinical severity and medical treatments

Changes in the clinical severity score of AD were measured using the SCORAD.¹² The SCORAD value was assessed at baseline, every visit during AIGT, and every 4 weeks during the regular outpatient visits for the treatment. Standard medical therapies were maintained at the same doses during the short-term follow-up for 12-24 weeks after the initiation of the treatment and then were changed according to the clinical courses in each patient.

Laboratory parameters

Serum total IgE concentration was measured using the ImmunoCAP assay (Phadia US, Portage, MI, USA). Peripheral blood eosinophil count was measured using an automated hematology analyzer (Coulter Counter STKS; Beckman Coulter, Fullerton, CA, USA).

Measurement of IgG anti-idiotypic antibodies to the F(ab')₂ fragment of autologous IgG

Changes in serum levels of IgG anti-idiotypic antibodies to the F(ab')₂ fragment of autologous IgG administered were measured by enzyme-linked immunosorbent assay. Autologous immunoglobulin (mainly IgG with a purity ≥97%) used for AIGT was treated with equilibrated immobilized pepsin (Pierce, Rockford, IL, USA) to separate the F(ab')₂ and Fc fragments of IgG. The F(ab')₂ fragment of autologous IgG was purified by removing the Fc fragment and undigested IgG whole molecule from the digested sample using Protein A spin column. The purified F(ab')₂ fragment of IgG was coated in a 96-well plate. The plate was washed with phosphate-buffered saline with 0.05% Tween 20, and non-specific binding of plate was blocked with phosphate-buffered saline with 20% bovine serum albumin. Then, serial dilutions of serum samples obtained from patients before and after AIGT were added to each well. The bindings of IgG antibodies to the F(ab')₂ fragment of autologous IgG in serum samples were detected with affinity-purified goat-antibodies to the Fc fragment of human IgG conjugated with alkaline phosphatase and substrate for alkaline phosphatase (*p*-nitrophenyl phosphate; Sigma-Aldrich Co., St Louis, MO, USA).

RESULTS

Long-term changes in the clinical severity of AD

Two of the 3 patients (cases 1 and 2) showed long-term clinical improvements lasting for 100 weeks (from 8 to 108 weeks in

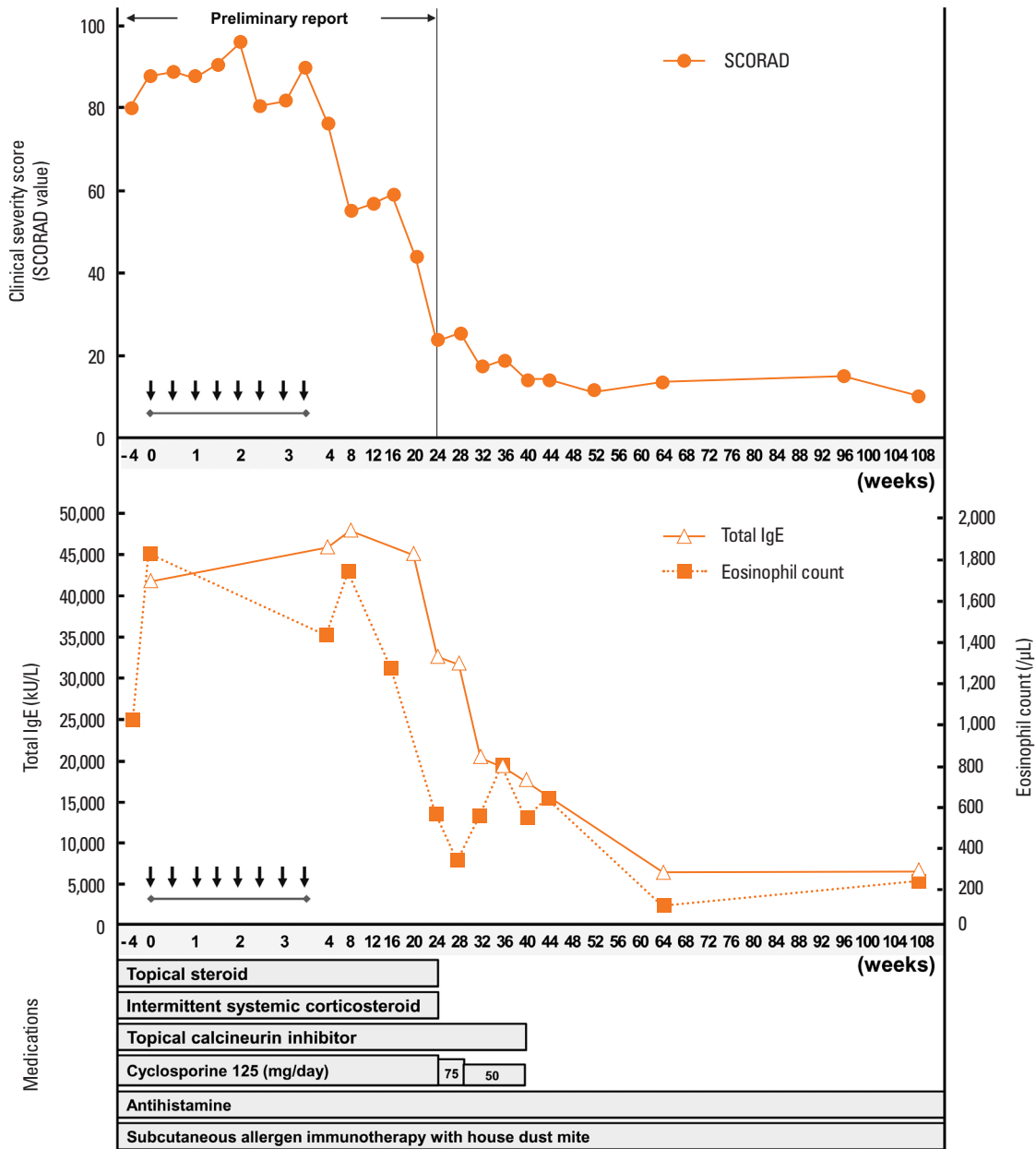


Fig. 1. Long-term changes in clinical severity scores (SCORAD value) and laboratory parameters in a patient with severe recalcitrant atopic dermatitis who was treated with intramuscular injections of 50 mg autologous immunoglobulin G twice a week for 4 weeks (case 1). The arrows indicate the timing of the injection of autologous immunoglobulin.

case 1) or 36 weeks (from 4 to 40 weeks in case 2) after AIGT (Figs. 1 and 2). In this report, we arbitrarily defined clinical remission when patients showed a decrease in clinical severity score greater than 80% from baseline. In 1 patient (case 1), clinical remission was observed at 40 weeks (SCORAD value 14.9 compared to 88.0 at baseline; 83.1% decrease) and remained in the status of clinical remission until 108 weeks after the initiation of AIGT (Fig. 1). In another patient (case 2), clinical remission was observed at 24 weeks (SCORAD value 10.6 compared to 60.7 at baseline; 82.5% decrease), at 28 weeks (83.4% de-

crease), and at 40 weeks (80.6% decrease) after the initiation of AIGT (Fig. 2). In the third patient (case 3), a significant clinical improvement (arbitrarily defined as a decrease in SCORAD value greater than 30% from baseline) was observed at 3 weeks (44.5% decrease in SCORAD value compared to baseline) and at 8 weeks (34.9% decrease in SCORAD value compared to baseline) after the initiation of AIGT (Fig. 3). Medical treatments, including cyclosporine, systemic corticosteroids, and methotrexate, were discontinued for more than 68 weeks in 2 patients who showed the long-term clinical improvements

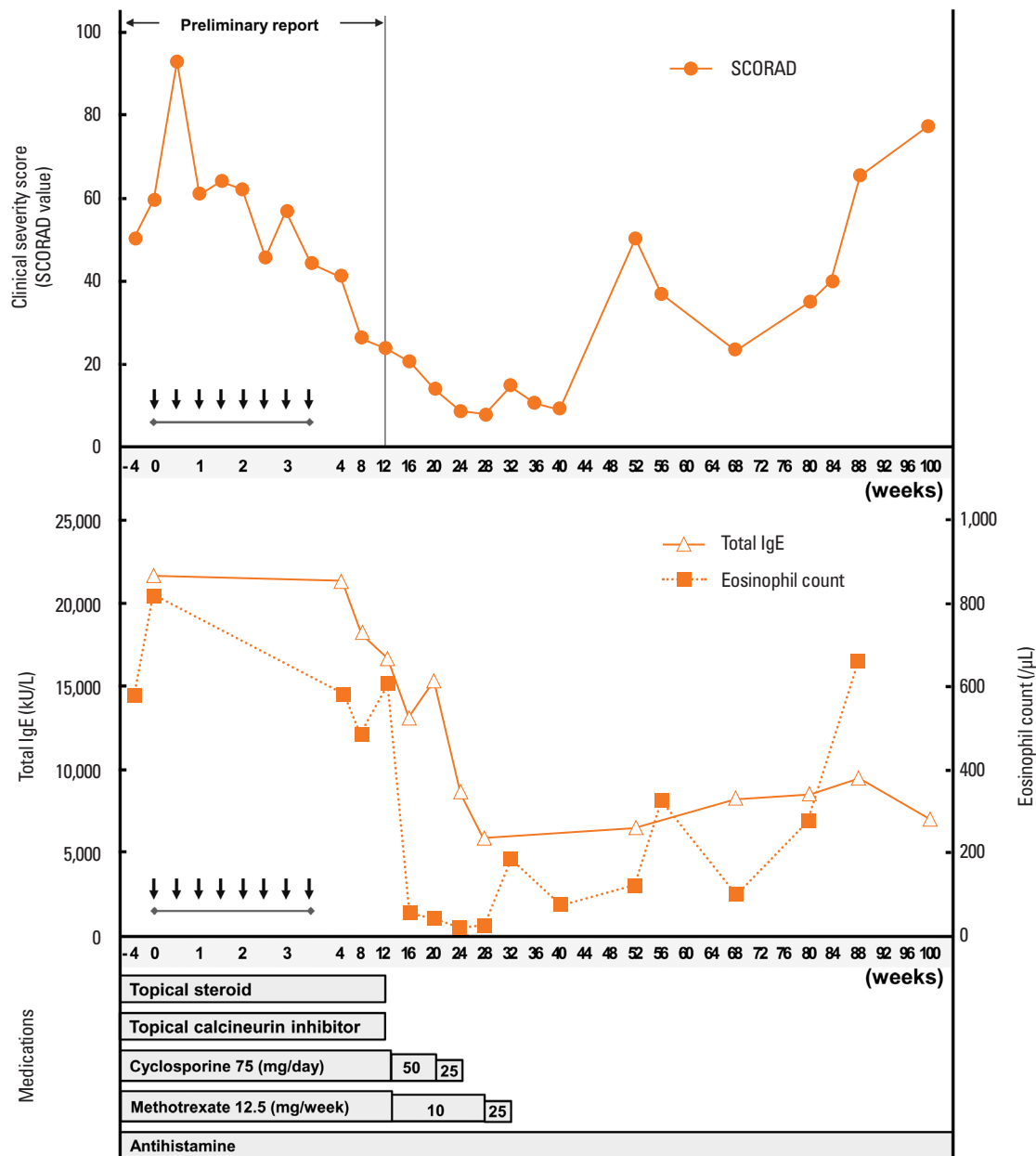


Fig. 2. Long-term changes in clinical severity scores (SCORAD value) and laboratory parameters in another patient with severe recalcitrant atopic dermatitis who was treated with intramuscular injections of 50 mg autologous immunoglobulin G twice a week for 4 weeks (case 2). The arrows indicate the timing of the injection of autologous immunoglobulin.

(Figs. 1 and 2). Marked changes in the gross appearance of skin were observed on the photographs of these 2 patients who showed long-term clinical improvements after AIGT (Fig. 4). No significant side effect was observed during the 2-year follow-up period after AIGT in all 3 patients.

Long-term changes in serum total IgE concentrations

In 1 patient (case 1) who showed a long-term clinical improvement for 100 weeks after the initiation of AIGT (Fig. 1), the serum total IgE concentration was also decreased from 24 to

108 weeks, a decrease of greater than 80% from baseline was observed at 64 weeks, and the maximum decrease was observed at 108 weeks after the initiation of AIGT (84.2% decrease from baseline) (Fig. 1). In another patient (case 2) who showed a long-term clinical improvement from 4 weeks after the initiation of AIGT (Fig. 2), the serum total IgE concentration was also decreased from 8 to 100 weeks, and the maximum decrease in serum total IgE concentration (72.1% decrease from baseline) was observed at 28 weeks after the initiation of AIGT (Fig. 2). In the third patient (case 3), a decreases in serum total IgE con-

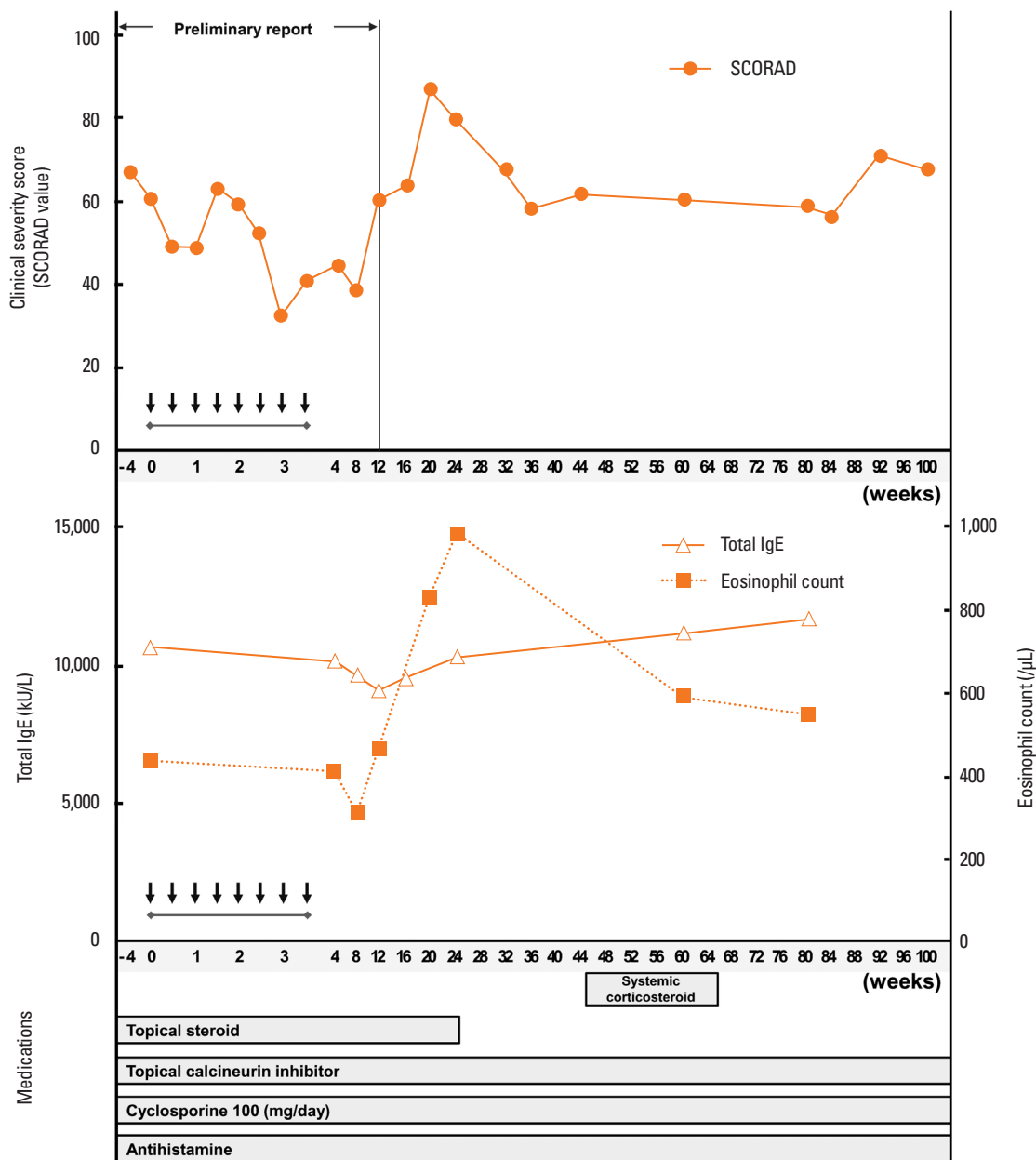


Fig. 3. Long-term changes in clinical severity scores (SCORAD value) and laboratory parameters in the third patient with severe recalcitrant atopic dermatitis who were treated with intramuscular injections of 50 mg autologous immunoglobulin G twice a week for 4 weeks (case 3). The arrows indicate the timing of the injection of autologous immunoglobulin.

centration compared to baseline was observed from 4 to 16 weeks, and the maximum decrease a maximum decrease in serum total IgE concentration was observed at 12 weeks after the initiation of AIGT (14.4% decrease from baseline) (Fig. 3).

Long-term changes in peripheral blood eosinophil count

In 1 patient (case 1) who showed a long-term clinical improvement for 100 weeks after the initiation of AIGT (Fig. 1), a decrease in peripheral blood eosinophil count was observed from 24 to 106 weeks, and the maximum decrease was ob-

served at 64 weeks (94.6% from baseline) after the initiation of AIGT (Fig.1). In another patient (case 2) who showed a long-term clinical improvement from 4 weeks after the initiation of AIGT (Fig. 2), a decrease in peripheral blood eosinophil count was observed from 16 to 80 weeks, and the maximal decrease were observed at 24 weeks (97.9% from baseline) after the initiation of AIGT (Fig. 2). In the third patient (case 3), a decrease in peripheral blood eosinophil count was observed from 4 to 8 weeks, and the maximum decrease was observed at 8 weeks (28.7% from baseline) after the initiation of AIGT (Fig. 3).

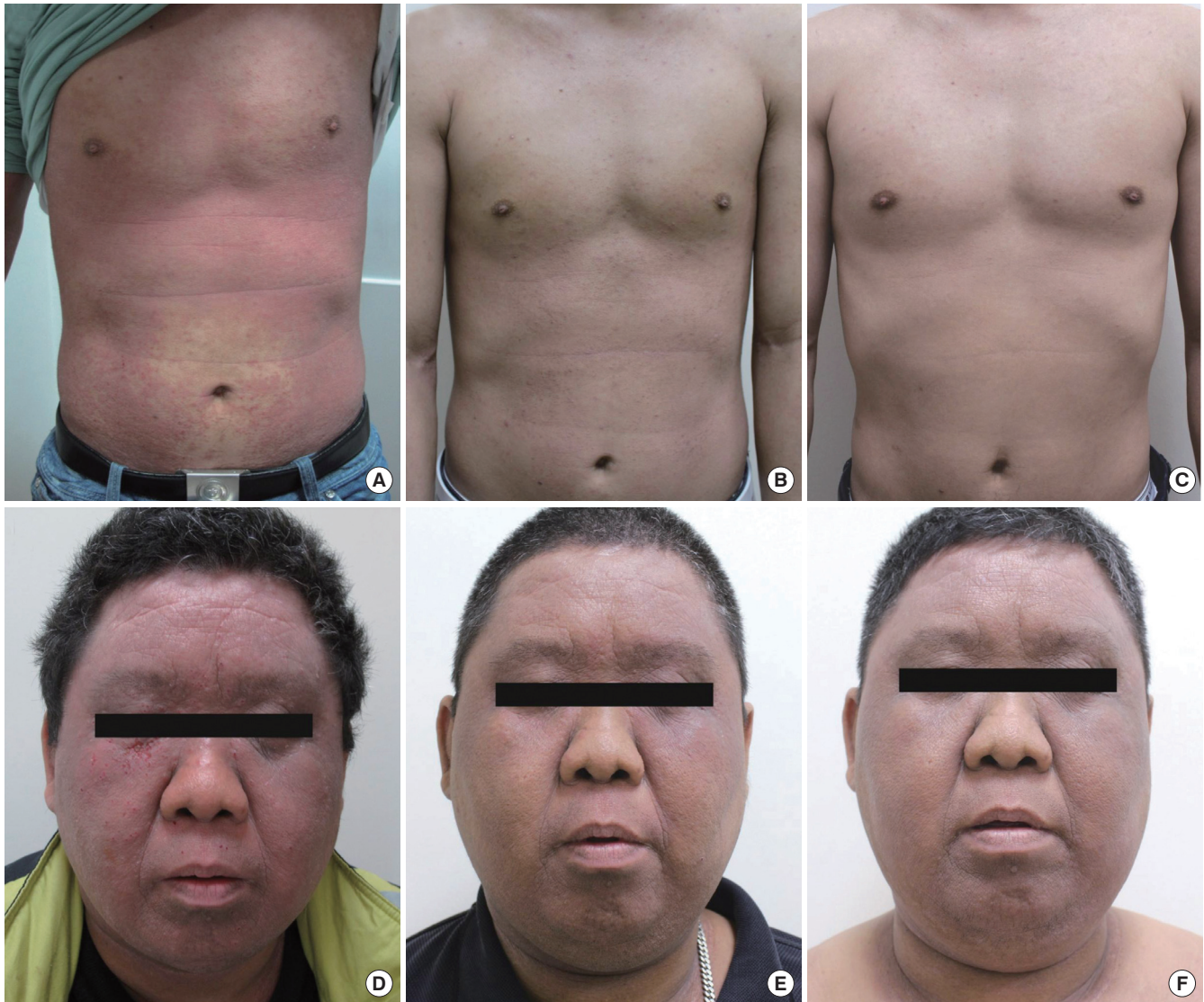

Fig. 4. Photographs of 2 patients with severe recalcitrant atopic dermatitis who were treated with intramuscular injections of 50 mg autologous immunoglobulin G twice a week for 4 weeks. Photographs of 1 patient (case 1) at baseline before the treatment (A), at 24 weeks (B), and at 96 weeks after the treatment (C). Photographs of another patient (case 2) at baseline before the treatment (D), at 24 weeks (E), and at 40 weeks after the treatment (F).

Serum levels of IgG anti-idiotype antibodies to the F(ab')₂ fragment of autologous IgG

The serum levels of IgG anti-idiotype antibodies to the F(ab')₂ fragment of autologous IgG administered were not significantly changed after the initiation of AIGT in any of the 3 patients with AD at 4, 8, and 12 weeks compared to baseline (Fig. 5). IgA or IgM anti-idiotype antibodies to the F(ab')₂ fragment of autologous IgG administered were not detected in the serum samples from any of the 3 patients with AD before and after AIGT (data not shown).

DISCUSSION

The main object of this report was to evaluate of the duration

of clinical efficacy of AIGT in patients with severe recalcitrant AD. In this report, AIGT for 4 weeks resulted in a significant long-term clinical improvement lasting for more than 36 weeks in 2 of the 3 adult patients with severe recalcitrant AD. In addition, AIGT was well tolerated and produced no significant side effects during the 2-year follow-up period. These results suggest that AIGT has a long-term clinical efficacy in selected patients with severe recalcitrant AD.

The durations of the clinical efficacy of current standard medical therapies for AD are relatively short, and regular maintenance therapies are essential for a long-term clinical improvement.¹ This incompleteness of current medical therapies for AD results in an important unmet medical need of patients with AD who want a cure or a long-term treatment-free clinical

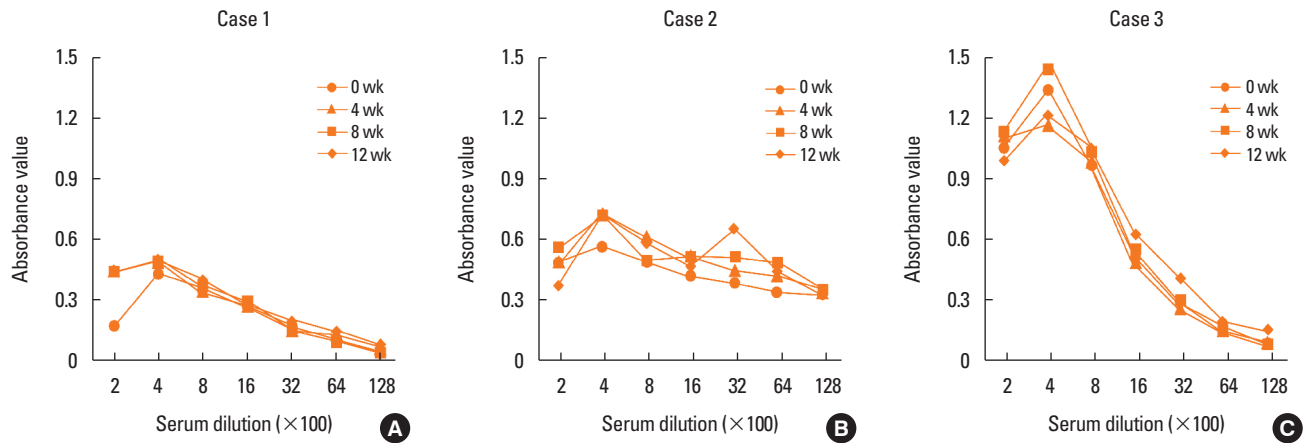


Fig. 5. Changes in the levels of IgG anti-idiotype antibodies to the F(ab')₂ fragment of autologous IgG administered in serum samples of 3 adult patients with severe recalcitrant atopic dermatitis who were treated with intramuscular injections of 50 mg autologous immunoglobulin G twice a week for 4 weeks. The levels of IgG anti-idiotype antibodies are expressed as absorbance value measured by enzyme-linked immunosorbent assay.

remission of AD.¹ Allergen immunotherapy could be a candidate for the disease-modifying therapy for AD as it has been proven to change long-term clinical courses in allergic rhinitis and allergic asthma.^{14,15} However, objective evidence supporting allergen immunotherapy as a candidate for disease-modifying therapy for AD is still not available.^{16,17} Additionally, there are several important practical limitations of allergen immunotherapy to become a standard treatment for AD in the aspects of clinical efficacy (unpredictability of efficacy), systemic side effects (anaphylaxis), selection of patients for the therapy (patients sensitized to multiple allergens or patients with no detectable sensitized environmental allergen), and absence of biomarker to predict of clinical efficacy. We propose that AIGT could be a new candidate for disease-modifying therapy for AD on the basis of our results showing a long-term clinical efficacy in selected patients with severe recalcitrant AD. Further long-term clinical studies with a larger sample size are required to confirm our results.

In this study, the long-term improvements of laboratory parameters, including serum total IgE concentration and peripheral blood eosinophil count, were observed after the initiation of AIGT in 2 patients with severe recalcitrant AD. These results suggest that AIGT has long-term immunomodulatory effects in selected patients with severe recalcitrant AD. We initially hypothesized that repeated intramuscular injections of autologous IgG induce active immune responses to the antigen-binding sites of pathogenic antibodies (anti-idiotypic immune response), thereby correcting immune dysfunction and hypersensitivity. However, we could not detect significant changes in the levels of IgG anti-idiotype antibodies to the F(ab')₂ fragment of autologous IgG in serum samples of the 3 adult patients with severe recalcitrant AD after AIGT. Interestingly, 1 patient with severe AD of this report (case 2) had a remarkable immediate subjective clinical improvement (decrease in itching sensation

and moisturizing of the skin from sweating) starting at 2 hours after initial intramuscular injection of autologous IgG, and the subjective clinical improvement persisted for less than 24 hours (unpublished data). However, objective improvements in the clinical severity score of AD and laboratory parameters were observed at 4 weeks after the initiation of AIGT in this patient (case 2). These findings suggest a possibility that an immunological factor other than immunoglobulin (such as activated idiotype-specific regulatory T cells) might be more important for the development of immediate clinical improvement after AIGT in this patient. Further studies on the detailed immunological therapeutic mechanisms of AIGT in patients with AD are warranted.

In conclusion, AIGT showed long-term favorable effects on both clinical severity and laboratory parameters in selected patients with severe recalcitrant AD. Further studies are required to evaluate the clinical usefulness and therapeutic mechanism of AIGT for AD.

REFERENCES

1. Nahm DH. Personalized immunomodulatory therapy for atopic dermatitis: an allergist's view. *Ann Dermatol* 2015;27:355-63.
2. Beck LA, Thaçi D, Hamilton JD, Graham NM, Bieber T, Rocklin R, et al. Dupilumab treatment in adults with moderate-to-severe atopic dermatitis. *N Engl J Med* 2014;371:130-9.
3. Carroll CL, Balkrishnan R, Feldman SR, Fleischer AB Jr, Manuel JC. The burden of atopic dermatitis: impact on the patient, family, and society. *Pediatr Dermatol* 2005;22:192-9.
4. Schäfer T. Epidemiology of complementary alternative medicine for asthma and allergy in Europe and Germany. *Ann Allergy Asthma Immunol* 2004;93:S5-10.
5. Asefi M, Augustin M. Regulatory therapy: treatment with nonspecific stimulants in dermatology in traditional and modern perspectives. *Forsch Komplementarmed* 1999;6 Suppl 2:9-13.
6. Pittler MH, Armstrong NC, Cox A, Collier PM, Hart A, Ernst E. Ran-

- domized, double-blind, placebo-controlled trial of autologous blood therapy for atopic dermatitis. *Br J Dermatol* 2003;148:307-13.
7. Staubach P, Onnen K, Vonend A, Metz M, Siebenhaar F, Tschentscher I, et al. Autologous whole blood injections to patients with chronic urticaria and a positive autologous serum skin test: a placebo-controlled trial. *Dermatology* 2006;212:150-9.
 8. Debbarman P, Sil A, Datta PK, Bandyopadhyay D, Das NK. Autologous serum therapy in chronic urticaria: a promising complement to antihistamines. *Indian J Dermatol* 2014;59:375-82.
 9. Nahm DH, Cho SM, Kim ME, Kim YJ, Jeon SY. Autologous immunoglobulin therapy in patients with severe recalcitrant atopic dermatitis: a preliminary report. *Allergy Asthma Immunol Res* 2014;6:89-94.
 10. Nahm DH, Kim ME, Cho SM. Effects of intramuscular injection of autologous immunoglobulin on clinical severity and serum IgE concentration in patients with atopic dermatitis. *Dermatology* 2015;231:145-51.
 11. Hanifin JM, Rajka G. Diagnostic features of atopic eczema. *Acta Derm Venereol Suppl (Stockh)* 1980;92 Suppl:S44-7.
 12. Stalder JF, Taïeb A; European Task Force on Atopic Dermatitis. Severity scoring of atopic dermatitis: the SCORAD index. Consensus Report of the European Task Force on Atopic Dermatitis. *Dermatology* 1993;186:23-31.
 13. Oranje AP, Glazenburg EJ, Wolkerstorfer A, de Waard-van der Spek FB. Practical issues on interpretation of scoring atopic dermatitis: the SCORAD index, objective SCORAD and the three-item severity score. *Br J Dermatol* 2007;157:645-8.
 14. Burks AW, Calderon MA, Casale T, Cox L, Demoly P, Jutel M, et al. Update on allergy immunotherapy: American Academy of Allergy, Asthma & Immunology/European Academy of Allergy and Clinical Immunology/PRACTALL consensus report. *J Allergy Clin Immunol* 2013;131:1288-1296.e3.
 15. Valenta R, Campana R, Marth K, van Hage M. Allergen-specific immunotherapy: from therapeutic vaccines to prophylactic approaches. *J Intern Med* 2012;272:144-57.
 16. Lee J, Park CO, Lee KH. Specific immunotherapy in atopic dermatitis. *Allergy Asthma Immunol Res* 2015;7:221-9.
 17. Tuft L. Studies in atopic dermatitis. V. Problems in inhalant hypersensitization and results of treatment. *J Allergy* 1960;31:1-11.