

REVIEW

A window on disease pathogenesis and potential therapeutic strategies: molecular imaging for arthritis

Luke L Gompels* and Ewa M Paleolog

Abstract

Novel molecular imaging techniques are at the forefront of both preclinical and clinical imaging strategies. They have significant potential to offer visualisation and quantification of molecular and cellular changes in health and disease. This will help to shed light on pathobiology and underlying disease processes and provide further information about the mechanisms of action of novel therapeutic strategies. This review explores currently available molecular imaging techniques that are available for preclinical studies with a focus on optical imaging techniques and discusses how current and future advances will enable translation into the clinic for patients with arthritis.

Introduction: requirement for novel molecular imaging techniques

The objectives of molecular imaging are the visualization, characterization and quantification of molecular and cellular processes non-invasively within intact living organisms. This can help evaluate physiological and pathophysiological processes, facilitate diagnosis and monitor the effects of therapy. At the preclinical stage novel molecular imaging techniques can facilitate the development of new therapies and understanding of novel mechanisms of action of biologically targeted agents.

Rheumatoid arthritis (RA) is a chronic systemic inflammatory disease, primarily characterised by inflamed synovial tissue in multiple joints leading to localised destruction of bone. Despite significant advances in conventional imaging strategies, such as the use of power doppler ultrasound scans and magnetic resonance imaging (MRI), the early diagnosis and monitoring of

inflammatory conditions such as RA remains challenging. Current imaging reflects irreversible pathological and anatomical change as opposed to perturbations in specific molecular pathways. Pathological change visualized on X-ray imaging may not be seen until many months after disease onset [1]. Osteoarthritis (OA) is characterised by joint pain, inactivity-related stiffness, impaired social role and reduced quality of life, which may be associated with radiographic abnormalities. It is the most prevalent joint disease and a major cause of disability [2-4]. While in some ways similar to RA, it is recognised that cartilage loss may occur for several years before even minor changes can be detected on plain radiographs in OA [5]. Molecular *in vivo* imaging in animal models of disease is also important in increasing our understanding of disease pathogenesis and in developing methods of monitoring disease activity *in vivo*. Robust disease monitoring will also allow for better appraisal of potential therapeutics. Ultimately, the aim is to translate molecular imaging techniques into functional systems for imaging of human diseases such as RA and OA.

Imaging modalities and their application to musculoskeletal disease

Radionuclide imaging: the past and the future

The following sections detail how different radionuclide imaging modalities have been utilized in musculoskeletal imaging practice and how they may be further deployed.

Radionuclide techniques have long been established for imaging in preclinical animal models as well as in RA and related autoimmune conditions. A variety of methods have been employed successfully for imaging leukocytes with ^{99m}Tc , ^{67}Ga and ^{111}In , with particular focus on their use in RA, where they remain in routine clinical use as diagnostic imaging techniques [6]. The oldest radiopharmaceutical proposed for imaging inflammation was ^{67}Ga citrate and this remains an established technique for imaging pulmonary and musculoskeletal inflammation, especially in sarcoidosis [7]. A

*Correspondence: l.gompels@imperial.ac.uk
Kennedy Institute of Rheumatology, Faculty of Medicine, Imperial College, Charing Cross Hospital Campus, 65 Aspenlea Road, London W6 8LH, United Kingdom

radionucleotide can also be applied to a macromolecule making use of the permeability change that is recognised to occur around sites of inflammation [8]. There are numerous examples of so-called non-targeted approaches, including radiolabelled liposomes, dextran, nanocolloid and human immunoglobulin [9-12]. While all these techniques have a low cost and are widely available, resolution and sensitivity are relatively low. As a further example, ^{99m}Tc -oxidronate (Tc-HDP) displays abnormal uptake over both currently inflamed and chronically damaged joints and is very sensitive for the detection of joint and subchondral bone abnormalities [13,14], but it cannot distinguish accurately between actively and chronically inflamed joints [15].

A radionucleotide can be applied to a specific molecular target to improve these issues. mAbs with high specificity and high affinity for their target antigens can be utilized for delivery of agents, including radionucleotides, enzymes, drugs, or toxins, *in vivo*. The Fab is a region on an antibody that binds to antigens. It is composed of one constant and one variable domain of each of the heavy and the light chain. This may benefit both targeting specificity, due to decreasing the size of labelled conjugate, and may also reduce immunogenicity as described below. Scintigraphy utilizing a ^{99m}Tc -anti-E-selectin-Fab has been used with good effect to image synovitis in patients with RA, in this case demonstrating improved specificity compared to a conventional tracer for bone and joint (Tc-HDP). This technique demonstrated particular specificity for targeting active joint inflammation [16]. The absence of signal uptake in normal joints by E-selectin targeted imaging described above allows for markedly improved detection of active joint disease in RA. The mAb described in this study is of murine origin, which raises the possibility of host immunogenicity. However, the small amounts of mAb required for imaging and also the use of the Fab fragment devoid of Fc portions, which are thought to be responsible for generating host immunity, may reduce the likelihood of a human anti-mouse antibody (HAMA) response. In this study patients were not tested for a HAMA response, but some were imaged again with ^{99m}Tc -anti-E-selectin-Fab 2 to 4 months later with no detectable change in the biodistribution of labelled antibody. In a previous study of 14 patients with RA that received ^{111}In -labelled F(ab')₂ fragment of E-selectin, HAMA responses were measured by ELISA comparing blood samples taken pre-immunisation and post-immunisation (14 days). No HAMAs were detectable following injection.

Other specific molecular targeting techniques have been developed but can be affected by the non-specific localization of agents to inflamed tissues. An example includes ^{111}I -labelled IL-1 receptor antagonist (IL-1ra),

which did not show increased localisation compared to radiolabelled albumin [17]. It would appear in this study that at the doses of labelled IL-1ra used, the most substantial effect was for local changes to reflect non-specific trafficking of the molecule due to local permeability changes in areas of inflammation. The therapeutic efficacy of IL-1ra (anakinra, which is licensed for treatment in RA) requires repeated administration at 1,000-fold the doses used in the above imaging study. If imaging was undertaken with much higher concentrations of labelled anakinra, greater specificity of signal compared to radiolabelled albumin may be achieved; however, increasing the dose of imaging agent to that level would lead to unacceptable levels of radiation.

The scintigraphic detection of radiolabelled TNF mAb has also been investigated. Twenty-five percent of the ^{99m}Tc labelled anti-TNF signal could be abrogated following prior administration of unlabelled anti-TNF [18]. This demonstrates a specific component to imaging, but also suggests that 75% of the signal was non-specific accumulation of labelled tracer at sites of inflammation.

Interestingly, in RA, other workers have demonstrated that ^{99m}Tc -anti-CD3 scintigraphy can be used to differentiate between autoimmune rheumatic diseases and strongly correlates with clinical findings for patients with RA [19]. More recently it has been demonstrated that anti-CD3 therapy is highly effective for the treatment of collagen-induced arthritis (CIA), a murine arthritis model, with the capacity to generate anti-arthritic CD8+ regulatory T cells (Tregs) and expand the relative numbers of CD4+ Tregs [20]. This highlights the potential of how both imaging and therapy could be synergised.

To determine whether overexpression of the high affinity folate receptor on activated macrophages can be utilised to selectively target imaging agents to sites of inflammation in rats with adjuvant-induced arthritis, folic acid was conjugated to a ^{99m}Tc chelator and its distribution was visualised using gamma scintigraphy in healthy rats, rats with adjuvant-induced arthritis and arthritic rats that had been depleted of macrophages [21]. Uptake was also confirmed by pre-administering unlabelled folate - this demonstrated that the folate imaging conjugate concentrated in the extremities of diseased rats but not in the extremities of healthy rats. Depletion of macrophages also reduced tissue folate receptor content with a concomitant reduction in the folate targeted signal. This study demonstrates that cell based labelling may also be viable for both functional imaging and targeted delivery of therapeutics [21].

Positron emission tomography and single photon emission tomography

Positron emission tomography (PET) imaging is based on imaging emission from isotopes such as ^{18}F and ^{64}Cu .

These decay and emit positrons that on collision with electrons emit λ -rays at 180 degrees to each other. These are detected when they reach a scintillator in the scanning device, creating a burst of light that is detected by photomultiplier tubes or silicon avalanche photodiodes.

PET imaging has been applied in *in vivo* models of arthritis. For example, in the K/BxN mouse model of RA, the transfer of autoantibodies specific for glucose-6-phosphate isomerase (GPI) into naïve mice rapidly induces joint inflammation similar to that seen in RA. The autoimmune target for the KRN T-cell and antibody response is GPI, which is involved in glycolysis and is ubiquitously present within the cytosol and within tissue at low levels. More than 50% of humans affected with RA have elevated levels of anti-GPI antibodies. In the K/BxN mouse model, Wipke and colleagues [22] have shown by PET imaging that purified anti-GPI IgG localizes specifically to the front and rear distal joints within minutes of intravenous injection, reaches saturation by 20 minutes and remains localized for at least 24 hours. By contrast, control IgG does not localize to joints or cause inflammation. For this study anti-GPI antibodies were labelled with ^{64}Cu and injected into the recipient mice, which were then imaged by micro-PET [22]. This work has been extended by Binstadt and colleagues [23], who have gone on to demonstrate by intravital imaging that anti-GPI antibodies caused macromolecular vasopermeability localized to sites destined to develop arthritis. These studies highlight how molecular *in vivo* imaging techniques can be used to dissect the dynamic and organ specificity of autoimmune attack.

Human studies have also been undertaken. ^{18}F fluorodeoxyglucose (^{18}F -FDG) PET imaging and methyl- ^{11}C -choline, an isotope of choline that is incorporated into cell membranes, can be used to image cellular proliferation. Roivainen and colleagues [24] compared ^{18}F -FDG PET and methyl- ^{11}C -choline PET with MRI measures of synovial proliferation at the knee in a study of ten patients with inflammatory arthritis including RA. They found that synovial volumes measured on contrast-enhanced T1-weighted MRI scans were highly correlated with PET measures of membrane turnover and glucose metabolism, including the standardized uptake value (SUV) for these isotopes (r values of 0.834 for ^{11}C -choline and 0.714 for ^{18}F FDG).

Single photon emission computed tomography (SPECT) is a nuclear medicine tomographic imaging technique that utilizes the emission of gamma rays. SPECT imaging is performed by using a gamma camera to acquire two-dimensional images from multiple angles. This is reconstructed into a three-dimensional dataset, similar to those obtained from other tomographic techniques such as MRI, computed tomography (CT), and PET. SPECT is similar to PET in its use of radioactive

tracer material and detection of gamma rays. In contrast with PET, however, the tracer used in SPECT emits gamma radiation that is measured directly. SPECT scans are significantly less expensive than PET scans, in part because they are able to use longer-lived, more easily obtained radioisotopes than PET. The widespread use of PET is limited by a shortage of centres able to generate positron radioisotopes that also have short half lives. SPECT uses isotopes that are already in widespread use, such as ^{111}In and $^{99\text{m}}\text{Tc}$. Rapid advances in SPECT, including the use of multiple pinhole collimators, allow high-resolution imaging to less than 1 mm. This enables mouse physiology to be quantified. This has been used to good effect in a humanized mouse model of arthritis. NanoSPECT/CT co-registration technology has been used to image the uptake of ^{111}In labelled anti-E-selectin antibody into human synovium that was transplanted into SCID mice following graft stimulation with TNF α . This demonstrated that activity could be detected in the graft at multiple time points following injection with clear delineation of the transplants in reconstructed images with significant differences to ^{111}In -labelled isotype control antibody [25]. These results have demonstrated that this may be a technique with significant promise for small animal imaging. A translational study of high resolution SPECT imaging in a murine arthritis model and in patients with RA co-registered with MRI has also been performed and this is described below.

MRI and high-resolution computed tomography

MRI scanning is the current gold standard modality in clinical practice for imaging synovitis and tenosynovitis in patients with inflammatory arthritis. Studies have shown correlations between the degree of inflammation and the vascularity of synovium obtained at biopsy and post-contrast enhancement on matching dynamic MRI scans. Scoring systems have been devised that are based on quantifying synovial membrane thickening and signal intensity on static post-contrast scans. Moderate to high reliability has been demonstrated with trained readers and quantification of synovitis in this way is being used increasingly as an outcome measure in clinical trials to assess response to therapy. MRI-observed synovitis is almost invariable in those with active RA, but recent studies have also demonstrated its presence in patients in clinical remission, emphasizing the sensitivity of this technique and the importance of subclinical joint inflammation [26]. Synovial inflammation determined by MRI has been shown to be common in OA [27]. However, MRI studies are complex and have a new range of variables, including different imaging sequences, protocols and hardware, but quantification is improving, allowing for a good level of accuracy and reliability in measurements of cartilage volume and thickness [28].

For example, a novel method of measurement of focal cartilage thickness change by MRI by detailed mapping of changes in cartilage thickness has been developed. This demonstrated marked focal changes in cartilage thickness over time and correlated with disability [29].

High-resolution delayed gadolinium-enhanced MRI of cartilage (dGEMRIC) is an alternative technique that can provide further information on the composition and structure of the cartilage matrix. Cartilage consists of relatively few cells and a hydrated extracellular matrix consisting mainly of proteoglycans and collagen, which are responsible for load distribution and compressive stiffness. Proteoglycans consist of numerous glycosaminoglycan (GAG) side chains that are negatively charged, providing the extracellular matrix with the majority of its fixed charge - this is referred to as the fixed charge density (FCD). An early feature of OA is the loss of GAGs and hence FCD from the tissue; T1 mapping of cartilage is performed after intravenous administration of gadolinium-based contrast agent, which is able to provide an indirect measurement of GAGs, and hence cartilage degradation, by detecting changes in the FCD [30-32]. In patients with knee pain, GAG depletion as measured by a dGEMRIC index has been shown to be predictive of development of knee OA in a 6-year follow-up. This technique may therefore act as a clinically relevant measure of cartilage integrity as well as provide information about underlying molecular perturbation [33].

Cartilage quality assessment in small joints may also be made using dGEMRIC. An initial study examined four patients with OA of the first carpometacarpal joint, demonstrating differences between asymptomatic and OA joints [34]. dGEMRIC may also help to assess cartilage degeneration in the metacarpal phalangeal joints of patients with RA. A study of 31 metacarpal joints in 10 patients with RA demonstrated significant changes in signal from the second and third metacarpal joints when compared to control subjects, whereas measurements of cartilage thickness were comparable in both groups [35].

Custom built high-resolution MRI devices have been developed to image small joint structures, including the bone trabeculae, cartilage, ligaments and tendons [36,37]. These have been developed to generate detailed anatomical assessment of the earliest stages of OA [38]. This has also added to understanding of the relative anatomical differences between OA and changes in spondyloarthritides such as psoriatic arthritis. Advances in imaging technology, such as high-resolution 'microscopy' MRI and whole body MRI, and improved protocols, such as ultrashort echo time, are expected to further delineate pathophysiology [39].

Paramagnetic contrast agents have also been utilised for cell tracking studies to monitor T-cell homing *in vivo* after loading T cells with superparamagnetic iron oxide

(CLIO) nanoparticles conjugated with a peptide sequence from the transactivator protein (Tat) of HIV-1. T cells were isolated from C57BL/6 (B6) mice and homing of T cells to the spleen was demonstrated by MRI following their re-injection. A similar technique was also used to image T-cell infiltrates in the pancreas of diabetic mice [40]. Both studies highlight the potential of MRI to track cellular events in deep tissues within living animals, although this technique may be hampered by the minimum number of cells that can be visualised during imaging. Ultrasmall superparamagnetic iron oxide (USPIO) nanoparticles are an MRI contrast agent that consists of an iron oxide core of about 5 nm in diameter that is surrounded by dextran, which increases the diameter to about 30 to 50 nm. Several USPIO preparations are in advanced stages of clinical trials, and their safety in humans has been increasingly established [41,42]. Conjugation of USPIO nanoparticles with ligands offers the possibility of MR imaging of molecular targets. Reynolds and colleagues [43] have demonstrated that *in vivo* expression of E-selectin during endothelial activation in an inflamed mouse ear model can be depicted with MR imaging and that the conjugate did not accumulate in non-inflamed endothelium.

Microfocal CT (micro-CT) is a three-dimensional high-resolution CT technique that allows volumetric assessment at peripheral skeletal sites. It can provide accurate depiction of structural changes in arthritides. For example, periarticular bone structure in RA patients was compared to healthy individuals using this technique and demonstrated exact detection of morphologic changes of juxtaarticular bone in healthy individuals and RA patients [44]. While not directly a functional imaging technique, this may hold promise as an anatomical co-registration modality with other forms of imaging so that anatomical and molecular change can be measured during the time course of arthritis.

Optical imaging: a viable alternative molecular technique

Optical imaging has already been developed for *in vitro* and *ex vivo* applications in molecular and cellular biology (for example, fluorescence confocal microscopy), and there are now significant advances in its development as a whole animal *in vivo* imaging technique, particularly in the context of arthritis [45]. The future holds considerable promise for non-invasive visualisation of specific molecular targets, which as with the other imaging techniques presented here can be synergised with other imaging modalities such as CT or MRI. The development of near infrared (NIR) fluorophores has also offered advantages for *in vivo* imaging. Significant tissue autofluorescence occurs at lower wavelengths and decreases signal sensitivity, whereas this is reduced in the NIR range. Hence, NIR *in vivo* imaging may offer a

unique window onto disease pathogenesis [46]. By contrast to the other techniques presented, it is comparatively low cost, does not require radiation, and multiple images can be acquired rapidly. The following sections detail how optical imaging may be utilised to visualise arthritic conditions *in vivo*.

Non-specific imaging agents detect permeability change in inflammatory states

Inflammatory arthritides such as RA are characterised by vascular inflammation and pathologic neoangiogenesis [47,48]. Disordered new vessels have increased vascular leakiness to macromolecules compared to normal vessels [8]. As the vascular permeability increases, this leads to plasma extravasation, oedema and swelling. This local permeability change has been utilised to explore the non-specific uptake and deposition of fluorescent dye within the arthritic joint *in vivo*. Enhanced localised deposition of free dye (not bound to a disease-specific antibody or other target) in the arthritic joints of animals with induced arthritis have been examined in several studies. The NIR fluorophore Cy5.5 was visualised in arthritic knee joints following induction of antigen-induced arthritis in mice [49], and demonstrated an approximately 1.5-fold increase in signal in arthritic compared to non-arthritic joints. Two other NIR dyes were evaluated in a murine *Borrelia*-induced Lyme arthritis model [50]. These techniques rely on the generalised increased blood perfusion and 'vascular leakiness' that are recognised to be present around the inflamed joint [51]. This may lead to as much as a 40-fold increase in macroglobulin permeability in the inflamed joint [8]. A number of different approaches have been deployed to make use of vascular permeability change in order to improve the therapeutic index of drug treatment. One possibility is the direct conjugation of a drug to another larger molecule - an example of this is conjugation to polyethylene glycol (PEG). This approach has been successfully deployed for a number of drugs in routine clinical use, such as the PEGylated forms of interferon- α and doxorubicin for the treatment of hepatitis C and breast cancer, respectively [52]. In RA this approach has demonstrated improved localisation to sites of inflammation by measuring increased levels of fluorescence in inflamed paws with a fluorescently labelled PEGylated anti-TNF α agent compared to a non-PEGylated TNF α inhibitor [53]. The pegylated anti-TNF α agent Certolizumab is licensed for clinical use in patients with active RA [54].

Targeted imaging agents

Antibody-ligand interactions: determining specificity of molecular targeting

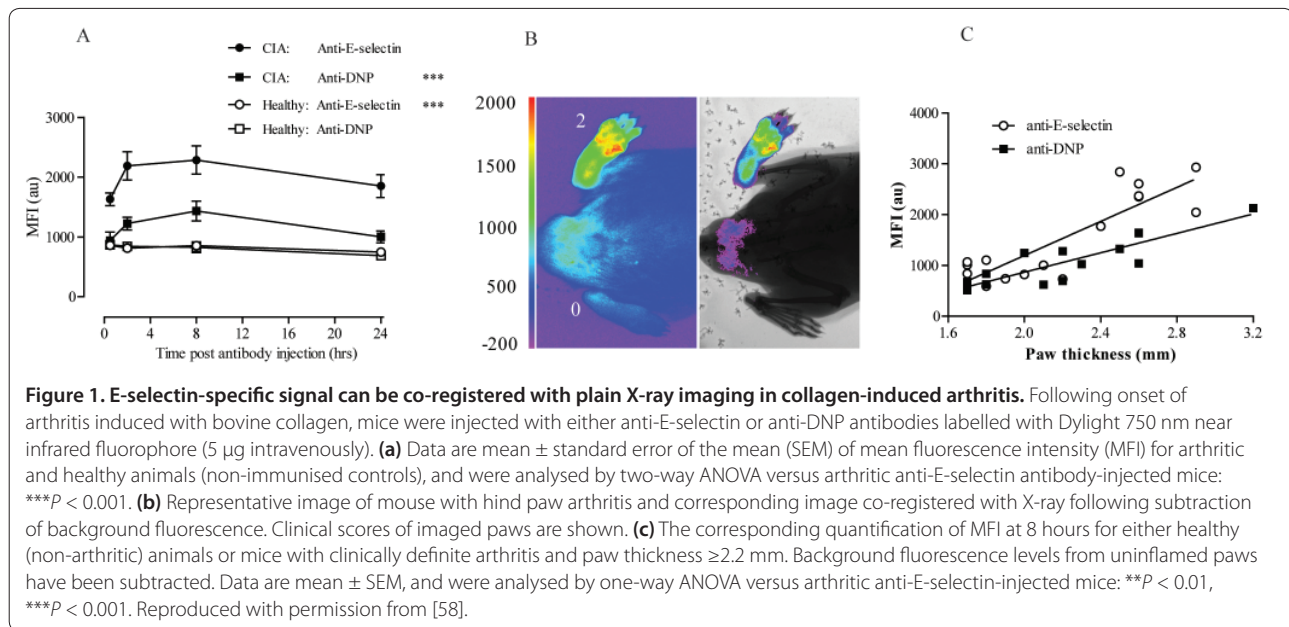
Specificity of dye trafficking may be enhanced by utilising an antibody, or its fragment, directed at a specific

molecular target. Specific deposition of dye in the arthritic joint of antigen-induced arthritic mice has been achieved by targeting macrophages with Cy5.5-labelled anti-F4/80 antigen. The F4/80 antigen is expressed on the macrophages when they accumulate in inflamed joints [55]. There was, however, a small increase in signal in the uninflamed contralateral knee joints as well as increased uptake in inflamed knee joints with the Cy5.5-labelled isotype control antibody. This highlights the challenge of identifying specific versus non-specific deposition of dye within the inflamed joint. Optical imaging of arthritis utilising a probe directed against folate receptors on activated macrophages demonstrated a 2.3-fold increase in signal in inflamed compared to uninflamed joints [56]. This increase was greater than that obtained following injection of free dye. Another study has examined *in vivo* fluorescent signal returned from allogeneic leukocytes that were labelled *ex vivo* with fluorescent dye and re-injected into arthritic mice [57]. Steroid reduced the signal intensity obtained; however, the degree of quantitative analysis was hampered by a relatively small change in signal intensity compared to the background signal.

In our laboratory, we have demonstrated that E-selectin-targeted *in vivo* imaging is a quantifiable method of detecting endothelial activation in arthritis and can potentially be applied to quantify disease and investigate the effects of novel therapies [58]. Figure 1 demonstrates that E-selectin-specific signal can be detected in collagen-induced arthritis, a mouse model of RA. Significant differences in anti-E-selectin antibody NIR fluorescent signal can be detected compared to signal received from an isotype control antibody. In addition, it is also possible to co-register the fluorescent signal with digital X-rays of the affected area taken concurrently. This technique has potential to be translated into a method of delineating the changes occurring to activated endothelium in health and in disease both prior to and following therapy.

Activatable imaging agents enable signal amplification

Amplification of fluorescent signal at the site of inflammation may be possible by using protease activatable probes. Here a cleavable peptide sequence is linked to fluorescent molecules that are quenched when in close proximity to each other, but unquenched following cleavage by local proteolytic activity [59]. This may be particularly useful for optical imaging of OA, as local perturbations in proteolytic activity may be comparatively small. Cathepsins have been associated with arthritis and bone degeneration [60]. A cathepsin B activatable NIR fluorescent probe was used in a mouse model of OA and showed a three-fold difference in signal intensity between normal and osteoarthritic joints [61,62]. This particular probe has also been applied to



tumour detection [63] as well as the localisation of atherosclerotic plaques *in vivo* [64]. A similar probe was used to demonstrate that methotrexate could abrogate some of the increased signal found in arthritic joints [65]. A further study also demonstrated that specific signal could be reduced and correlated with a decrease in clinical disease indices such as redness and measurable paw swelling [66]. However, these studies did not examine whether an uncleavable form of peptide demonstrated similar signal or whether any specific inhibitor of the protease could prevent cleavage in the arthritic joint.

At the preclinical stage a number of different advances in generating either fluorescence (for example, GFP expression) or light (bioluminescence) have become powerful tools to delineate disease pathogenesis over multiple time points. Bioluminescence is the conversion of chemical energy to light in living organisms, most commonly under control of the luciferase enzymatic system. These enzymes convert the luciferin substrate in the presence of several co-factors and adenosine triphosphate to generate oxyluciferin and light [67]. This technology has been most widely used in reporter gene assays, where the promoters of genes under study have been linked to the luciferase gene, and the resultant light is a direct measure of promoter activity. Because the luciferase enzyme needs to be transfected into cells or expressed in a transgenic line, its use is limited to animal models. Pioneering studies have demonstrated *in vivo* imaging of bone forming osteoblasts. Gazit and colleagues [68] generated a transgenic mouse model containing the luciferase promoter under control of an osteoblast-specific osteocalcin promoter fragment. In

this study, light emission correlated well with the activity of osteoblasts in parts of the bony skeleton, matching histological expression of osteocalcin expression and quantification by real time PCR. Furthermore, in two skeletal repair models, firstly by bone fracture and secondly by marrow ablation, quantitative measurements could be made *in vivo* [68]. Bioluminescence has also been used successfully to image and study animal arthritis models. Transgenic mice that express luciferase under control of the nuclear transcription factor NF- κ B have enabled real time imaging of NF- κ B expression during the course of an arthritis model in intact animals [69]. Imaging of arthritic joints revealed a strong activation of NF- κ B on day 6 post-arthritis induction and increased expression over the following 4 days. One particular advantage bioluminescence has over traditional fluorophores is that tracking can be monitored over longer periods (days to weeks) [70].

Image co-registration techniques combine anatomical and molecular data

The potential application of molecular imaging techniques is determined by the ability to both quantify sensitivity and specificity and map this signal to discrete tissue structures *in vivo*. Pre-clinical and clinical multiple imaging platforms have been developed, such as PET-CT, SPECT-CT or PET-MRI. For example, PET-MRI may allow for the analysis of one or more functional processes simultaneously along with the delineation of high-resolution morphology [71]. Hybrid cameras that combine SPECT and helical CT can be used to correlate scintigraphic information with morphologic information

in one session. Use of SPECT/CT hybrid imaging may significantly increase the diagnostic accuracy of skeletal scintigraphy in the staging of malignant disease but it has been little used for the interpretation of musculoskeletal disorders. A recent pilot study has demonstrated the potential benefits of this technique for improving diagnostic accuracy in differentiating the aetiology of musculoskeletal disorders - among 34 lesions classified as OA on planar and SPECT imaging, 7 were reclassified as fracture and one as a benign tumour [72]. This encourages further follow-up work comparing findings with other imaging modalities such as MRI, clinical outcomes and, where possible, histopathological correlates.

A combinatorial approach has also been developed for optical imaging co-registered to MRI. Concurrent MRI and diffuse optical tomography of the breast after indocyanine green enhancement has been undertaken [73]. This type of technology has developed in conjunction with suitably constructed probes. For example, Olson and colleagues [74] have developed activateable cell penetrating peptides linked to nanoparticles to serve as dual probes for *in vivo* fluorescence and MRI of proteases. This study reports on the use of *in vivo* visualization of matrix metalloproteinase activities by MRI and fluorescence of dendrimeric nanoparticles coated with activateable cell-penetrating peptides that have the potential to be labelled with both Cy5 and gadolinium. Uptake of such nanoparticles in tumours is 4- to 15-fold higher than for unconjugated activateable cell-penetrating peptides in a mouse tumour model. With fluorescent molecules, residual tumour and metastases as small as 200 μm were detected. In addition, once activated, the Gd-labelled nanoparticles deposit high levels (30 to 50 μM) of Gd in tumour parenchyma, with even higher amounts deposited in regions of infiltrative tumour, resulting in useful T1 signal contrast lasting several days after injection.

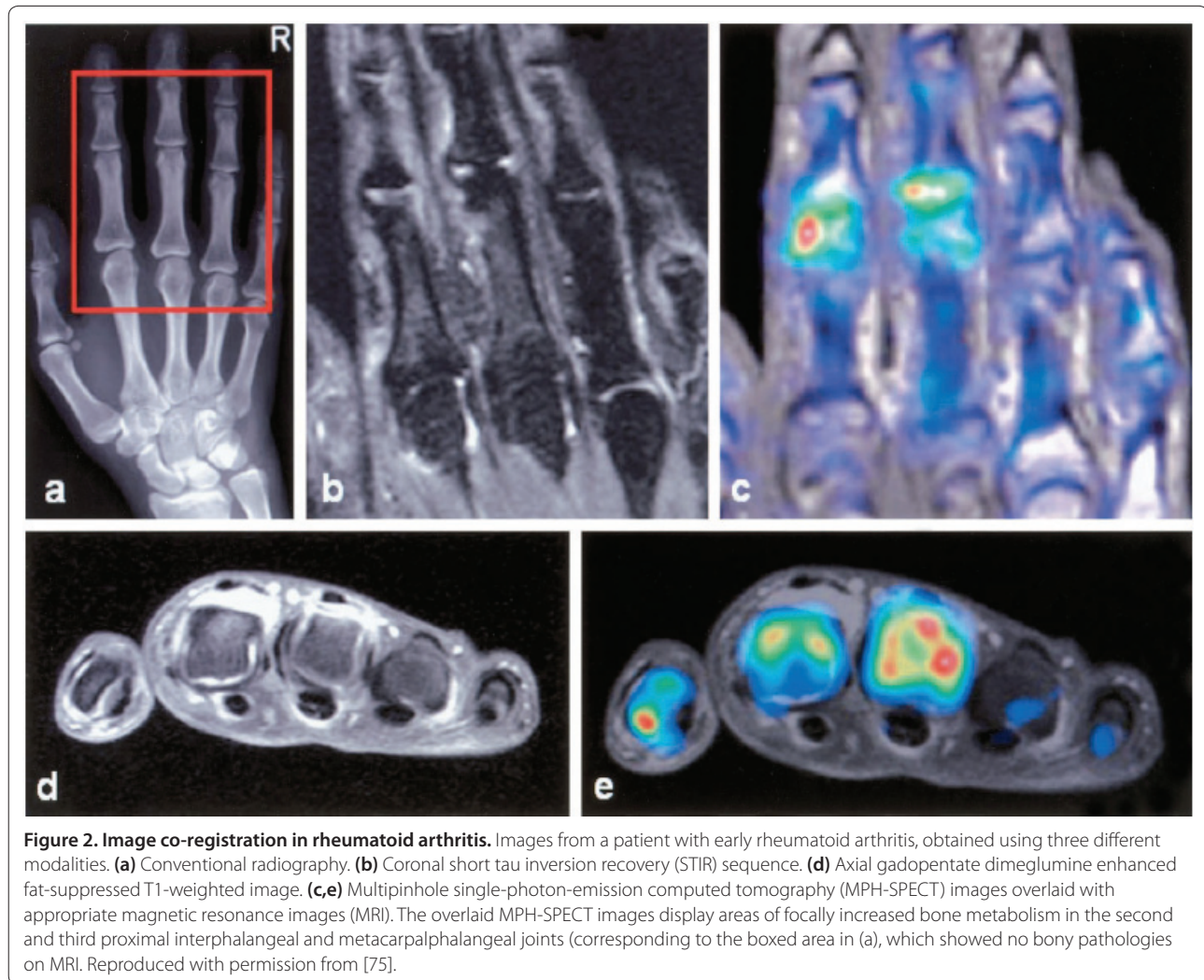
Inflammatory arthritic lesions have been imaged in experimental arthritis and in patients with RA using a high-resolution multi-pinhole (MPH)-SPECT technique [75]. In the human studies MPH-SPECT images depicted a detailed visualization of tracer accumulation in the bony structures of the hand and finger joints; these studies were also capable of imaging increased bone metabolism that had appeared normal with other imaging modalities. This is demonstrated in Figure 2. Ostendorf and colleagues [76] have also demonstrated that MPH-SPECT is sensitive to early changes in RA and OA and that the differences between them can be detected by different patterns of uptake. It is also interesting to note that this study used a conventional tracer, so it is possible that much greater sensitivity could be achieved by conjugating the tracer to molecules directed at specific molecular targets.

Future perspectives

Conventional and currently clinically available imaging strategies for detecting and monitoring arthritis have relied mainly on detecting the endpoints of autoimmune pathological processes. But molecular imaging now offers a new way of detecting and monitoring disease. Developments in radionucleotide imaging discussed here will result in methods of detecting radiolabelled agents directed at specific molecular targets. These have the advantage that many of the facilities are already in clinical practice. Further developments in software will mean that novel co-registration techniques will enable precise anatomical localisation of molecular change, but exposure to radiation, especially if multiple imaging points are required, may limit routine clinical use. Similarly, MRI scanning is in widespread clinical use and the development of novel imaging protocols and validation and qualification of their use means that these techniques can readily be translated into clinical practice. However, there is often heavy clinical demand for current scanning equipment and imaging can be time consuming. Furthermore, there may be issues related to the toxicity of contrast agents; it is well recognised that gadolinium contrast agents may be nephrotoxic [77], and superoxide particles may have effects on endothelial cells [78,79]. Optical imaging offers a viable alternative imaging strategy; images can be obtained rapidly and devices are relatively inexpensive. Furthermore, there is no exposure to radiation. Developments in fluorophore technology have enabled accurate and quantifiable measurement of molecular processes. This technique is also readily combined with other imaging strategies.

While it is recognized that joint damage is related to disease activity in RA, the degree of progression and the temporal associations between the two are unclear [80]. However, progression of joint destruction is not always directly coupled to the signs and symptoms of RA. Following anti-TNF α therapy it has been noted that joint disease can be retarded even if active disease is ongoing [81,82]. Conversely, there are also reports that joint damage can accrue even in states of remission [83,84]. Using molecular techniques to sensibly determine subclinical levels of joint inflammation due to the upregulation of specific molecular pathways may be one way of determining levels of disease activity and response to therapy. This was explored in the study by Brown and colleagues [84] where the long-term significance of subclinical synovitis was assessed in relation to overall structural outcomes. This was performed by analyzing musculoskeletal ultrasonography in addition to MRI scoring measures. Targeted functional imaging therefore offers a method of assessing disease parameters in a different way.

Rather than focusing on pathological outcome, changes in specific molecular pathways can be measured. Many of



the studies presented here have utilised an antibody targeted approach. There are several shortcomings of mAbs, including their immunogenicity, suboptimal targeting and pharmacokinetic properties, and practical issues of production and labelling. Genetic engineering provides a powerful approach for redesigning antibodies for use in oncologic applications *in vivo*. Recombinant fragments have been produced that retain high affinity for target antigens, and display a combination of high targeting specificity with concomitant clearance from normal tissues and the circulation in animal models. Synovium-specific peptides can also be generated by *in vivo* phage display selection. These may uniquely hone to sites of inflammation within the inflamed synovium [85]. Clustering of fluorophores onto a larger scaffold may also be used to amplify the fluorescent signal.

Aptamer-based technologies and nanoparticles are potential novel particles that could be deployed successfully for molecular imaging. As oligonucleotide ligands,

aptamers are comparable to antibodies in specificity and affinity for their target molecule, typically a protein [86,87]. At 8 to 15 kDa, aptamers are intermediate in size between antibodies (150 kDa) and small peptides (15 kDa) and are slightly smaller than sFv (25 kDa). As polyanions, aptamers are quite different in composition from sFv. As synthetic molecules, aptamers readily support site-specific modifications that maintain structure and activity. Aptamers can be coupled to diagnostic or therapeutic agents and to bioconjugates, such as PEG polymers, that can alter aptamer pharmacokinetics. The parameters for the *in vivo* activity of aptamers have been investigated in rats with an aptamer directed against L-selectin [88]. Previous therapeutic work with aptamers has focused on blocking protein function; by far the most advanced work is represented by the use of a vascular endothelial growth factor aptamer, pegaptanib sodium (Macugen; Pfizer and Eyetech) [89], now approved for treatment of macular degeneration [90]. The small size

and polyanionic nature of aptamers may lead to rapid blood clearance and tissue uptake and may minimize the residence in liver and kidney, providing some potentially useful features for imaging and radiotherapy. Initial experiments to address aptamer suitability for *in vivo* imaging have been reported [91,92]. Aptamers (small oligonucleotide ligands) combined with small particles called nanorods made out of gold and silver act as a platform to accommodate multiple weak binding reactions. Fluorescently labelled aptamers increase their affinity for different cancer cell lines by 26-fold, resulting in a 300-fold increase in fluorescence signal compared to conventional techniques [93]. The use of nanorods in this instance may also open potential for therapeutic options. Since the nanorods have strong infrared absorption, hyperthermia may be generated locally, which could specifically ablate tumour or neoangiogenic inflammatory tissue.

There are other examples of merging both imaging and intervention. In the adjuvant arthritis model of RA, folate labelled with fluorescein and conjugated with haptens (small immunogenic molecules) was used to identify activated macrophages and deliver immunotherapy to the activated cell population. In these experiments, fluorescein isothiocyanate (FITC)-labelled folate was administered orally to folate-depleted animals and taken up preferentially by these cells as a result of their high surface expression of a folic acid receptor [21,94]. The haptens attached were subsequently expressed on the macrophage cell surface, making them highly immunogenic. Induction of anti-hapten antibodies in these animals via a vaccination schedule resulted in selective depletion of activated macrophages, with an anti-inflammatory effect comparable to that achieved by methotrexate, etanercept and anakinra in this model. This kind of approach could be used to target a wide variety of cells with selectively toxic agents without exposing the patient to the risks of non-specific immunosuppression.

GFP from the hydroid jellyfish *Aequorea victoria* and GFP mutants and homologues are used intensely in biotechnology. They represent the only available fluorescent tag fully encoded in a single gene. GFP-like proteins are utilized for *in vivo* labelling of organisms, cells, organelles and proteins, as well as in molecular sensors that probe different aspects of the intracellular environment. The excitation and emission spectra of these fluorescent reporter proteins used thus far for bioluminescence imaging has not exceeded 598 nm and 655 nm [95]. This significantly hampers the penetration of excited light through tissue and therefore affects the resolution of images that may be obtained. More recently, however, mammalian expression of infrared fluorescent proteins has been engineered from a bacterial phytochrome. These higher wavelengths penetrate tissue well and may

This article is part of the series *Advances in the imaging of rheumatic diseases*, edited by Mikkel Østergaard. Other articles in this series can be found at <http://arthritis-research.com/series/imaging>

be extremely useful for further *in vivo* imaging studies [96]. Combined with tomographic imaging techniques, localisation may be made to precise anatomic sites. Most recently a novel multispectral opto-acoustic imaging technique has shown significant potential to image *in vivo* to resolutions of 20 to 100 μm with depth penetration that could range up to several centimetres. Combining the significant enhancements in reporter proteins suitable for *in vivo* use and novel hardware solutions holds significant promise [97].

Conclusion

This review has demonstrated that functional molecular imaging techniques have the potential to visualise pathobiology in a new way. They can act to delineate the mechanism of action of therapy and can also be used to monitor therapeutic outcomes in patients with arthritis and other inflammatory autoimmune conditions, holding much promise as future imaging modalities.

Abbreviations

CT, computed tomography; dGEMRIC, delayed gadolinium-enhanced MRI of cartilage; ELISA, enzyme-linked immunosorbent assay; Fab, fragment antigen-binding; FCD, fixed charge density; ^{18}F -FDG, ^{18}F fluorodeoxyglucose; GAG, glycosaminoglycan; GFP, green fluorescence protein; GPI, glucose-6-phosphate isomerase; HAMA, human anti-mouse antibody; IL, interleukin; IL-1ra, IL-1 receptor antagonist; mAb, monoclonal antibody; MPH, multi-pinhole; MRI, magnetic resonance imaging; NIR, near infrared; OA, osteoarthritis; PEG, polyethylene glycol; PET, positron emission tomography; RA, rheumatoid arthritis; SPECT, single photon emission computed tomography; TNF, tumour necrosis factor; USPIO, ultrasmall superparamagnetic iron oxide.

Competing interests

The authors declare that they have no financial or non-financial competing interests.

Acknowledgements

We gratefully acknowledge the kind permission from Dr Ostendorf to reproduce Figure 2. We also gratefully acknowledge Professor Dorian Haskard's assistance with E-selectin targeted *in vivo* imaging.

Published: 31 January 2011

References

1. van der Heijde DM, van Leeuwen MA, van Riel PL, van de Putte LB: Radiographic progression on radiographs of hands and feet during the first 3 years of rheumatoid arthritis measured according to Sharp's method (van der Heijde modification). *J Rheumatol* 1995, **22**:1792-1796.
2. Felson DT, Zhang Y: An update on the epidemiology of knee and hip osteoarthritis with a view to prevention. *Arthritis Rheum* 1998, **41**:1343-1355.
3. Felson DT, Lawrence RC, Dieppe PA, Hirsch R, Helmick CG, Jordan JM, Kington RS, Lane NE, Nevitt MC, Zhang Y, Sowers M, McAlindon T, Spector TD, Poole AR, Yanovski SZ, Ateshian G, Sharma L, Buckwalter JA, Brandt KD, Fries JF: Osteoarthritis: new insights. Part 1: the disease and its risk factors. *Ann Intern Med* 2000, **133**:635-646.
4. Creamer P, Hochberg MC: Osteoarthritis. *Lancet* 1997, **350**:503-508.
5. Jones G, Ding C, Scott F, Glisson M, Cicuttini F: Early radiographic osteoarthritis is associated with substantial changes in cartilage volume

- and tibial bone surface area in both males and females. *Osteoarthritis Cartilage* 2004, **12**:169-174.
6. de Bois MH, Pauwels EK, Breedveld FC: **New agents for scintigraphy in rheumatoid arthritis.** *Eur J Nucl Med* 1995, **22**:1339-1346.
 7. Oyen WJ, Boerman OC, van der Laken CJ, Claessens RA, van der Meer JW, Corstens FH: **The uptake mechanisms of inflammation- and infection-localizing agents.** *Eur J Nucl Med* 1996, **23**:459-465.
 8. Levick JR: **Permeability of rheumatoid and normal human synovium to specific plasma proteins.** *Arthritis Rheum* 1981, **24**:1550-1560.
 9. Dams ET, Oyen WJ, Boerman OC, Storm G, Laverman P, Kok PJ, Buijs WC, Bakker H, van der Meer JW, Corstens FH: **^{99m}Tc-PEG liposomes for the scintigraphic detection of infection and inflammation: clinical evaluation.** *J Nucl Med* 2000, **41**:622-630.
 10. Kaya M, Tuna H, Fatih Firat M, Tuna F, Seren G, Necmi Yigitbasi O: **(^{99m}Tc-dextran scintigraphy to detect disease activity in patients with rheumatoid arthritis.** *Nucl Med Commun* 2004, **25**:597-601.
 11. Arzu Gencoglu E, Aras G, Kucuk O, Atay G, Tutak I, Ataman S, Soyulu A, Ibis E: **Comparison of Tc-^{99m} HIG and three-phase Tc-^{99m} MDP bone scintigraphy for evaluating the efficacy of Yttrium-90 silicate radionuclide synovectomy.** *Clin Nucl Med* 2003, **28**:277-285.
 12. Adams BK, Al Attia HM, Khadim RA, Al Haider ZY: **⁹⁹Tc(m) nanocolloid scintigraphy: a reliable way to detect active joint disease in patients with peripheral joint pain.** *Nucl Med Commun* 2001, **22**:315-318.
 13. Desaulniers M, Fuks A, Hawkins D, Lacourciere Y, Rosenthal L: **Radiotechnetium polyphosphate joint imaging.** *J Nucl Med* 1974, **15**:417-423.
 14. Helfgott S, Rosenthal L, Esdaile J, Tannenbaum H: **Generalized skeletal response to ^{99m}technetium methylene diphosphonate in rheumatoid arthritis.** *J Rheumatol* 1982, **9**:939-941.
 15. Fogelman I: **Skeletal uptake of diphosphonate: a review.** *Eur J Nucl Med* 1980, **5**:473-476.
 16. Jamar F, Houssiau FA, Devogelaer JP, Chapman PT, Haskard DO, Beaujean V, Beckers C, Manicourt DH, Peters AM: **Scintigraphy using a technetium ^{99m}-labelled anti-E-selectin Fab fragment in rheumatoid arthritis.** *Rheumatology (Oxford)* 2002, **41**:53-61.
 17. Barrera P, van der Laken CJ, Boerman OC, Oyen WJ, van de Ven MT, van Lent PL, van de Putte LB, Corstens FH: **Radiolabelled interleukin-1 receptor antagonist for detection of synovitis in patients with rheumatoid arthritis.** *Rheumatology (Oxford)* 2000, **39**:870-874.
 18. Barrera P, Oyen WJ, Boerman OC, van Riel PL: **Scintigraphic detection of tumour necrosis factor in patients with rheumatoid arthritis.** *Ann Rheum Dis* 2003, **62**:825-828.
 19. Lopes FP, de Azevedo MN, Marchiori E, da Fonseca LM, de Souza SA, Gutflin B: **Use of ^{99m}Tc-anti-CD3 scintigraphy in the differential diagnosis of rheumatic diseases.** *Rheumatology (Oxford)* 2010, **49**:933-939.
 20. Notley CA, McCann FE, Inglis JJ, Williams RO: **ANTI-CD3 therapy expands the numbers of CD4+ and CD8+ Treg cells and induces sustained amelioration of collagen-induced arthritis.** *Arthritis Rheum*, **62**:171-178.
 21. Turk MJ, Breur GJ, Widmer WR, Paulos CM, Xu LC, Grote LA, Low PS: **Folate-targeted imaging of activated macrophages in rats with adjuvant-induced arthritis.** *Arthritis Rheum* 2002, **46**:1947-1955.
 22. Wipke BT, Wang Z, Kim J, McCarthy TJ, Allen PM: **Dynamic visualization of a joint-specific autoimmune response through positron emission tomography.** *Nat Immunol* 2002, **3**:366-372.
 23. Binstadt BA, Patel PR, Alencar H, Nigrovic PA, Lee DM, Mahmood U, Weissleder R, Mathis D, Benoist C: **Particularities of the vasculature can promote the organ specificity of autoimmune attack.** *Nat Immunol* 2006, **7**:284-292.
 24. Roivainen A, Parkkola R, Yli-Kerttula T, Lehto-Koivunen P, Viljanen T, Mottonen T, Nuutila P, Minn H: **Use of positron emission tomography with methyl-11C-choline and 2-18F-fluoro-2-deoxy-D-glucose in comparison with magnetic resonance imaging for the assessment of inflammatory proliferation of synovium.** *Arthritis Rheum* 2003, **48**:3077-3084.
 25. Garrod T, Blades M, Haskard DO, Mather S, Pitzalis C: **A novel model for the preclinical imaging of inflamed human synovial vasculature.** *Rheumatology (Oxford)* 2009, **48**:926-931.
 26. McQueen FM, Ostergaard M: **Established rheumatoid arthritis - new imaging modalities.** *Best Pract Res Clin Rheumatol* 2007, **21**:841-856.
 27. D'Agostino MA, Conaghan P, Le Bars M, Baron G, Grassi W, Martin-Mola E, Wakefield R, Brasseur JL, So A, Backhaus M, Malaise M, Burmester G, Schmidely N, Ravaud P, Dougados M, Emery P: **EULAR report on the use of ultrasonography in painful knee osteoarthritis. Part 1: prevalence of inflammation in osteoarthritis.** *Ann Rheum Dis* 2005, **64**:1703-1709.
 28. Eckstein F, Burstein D, Link TM: **Quantitative MRI of cartilage and bone: degenerative changes in osteoarthritis.** *NMR Biomed* 2006, **19**:822-854.
 29. Williams TG, Holmes AP, Bowes M, Vincent G, Hutchinson CE, Waterton JC, Maciewicz RA, Taylor CJ: **Measurement and visualisation of focal cartilage thickness change by MRI in a study of knee osteoarthritis using a novel image analysis tool.** *Br J Radiol* 2010, **83**:940-948.
 30. Bashir A, Gray ML, Burstein D: **Gd-DTPA2- as a measure of cartilage degradation.** *Magn Reson Med* 1996, **36**:665-673.
 31. Bashir A, Gray ML, Boutin RD, Burstein D: **Glycosaminoglycan in articular cartilage: in vivo assessment with delayed Gd(DTPA)(2)-enhanced MR imaging.** *Radiology* 1997, **205**:551-558.
 32. Gray ML, Burstein D, Kim YJ, Maroudas A: **2007 Elizabeth Winston Lanier Award Winner. Magnetic resonance imaging of cartilage glycosaminoglycan: basic principles, imaging technique, and clinical applications.** *J Orthop Res* 2008, **26**:281-291.
 33. Owman H, Tiderius CJ, Neuman P, Nyquist F, Dahlberg LE: **Association between findings on delayed gadolinium-enhanced magnetic resonance imaging of cartilage and future knee osteoarthritis.** *Arthritis Rheum* 2008, **58**:1727-1730.
 34. Williams A, Shetty SK, Burstein D, Day CS, McKenzie C: **Delayed gadolinium enhanced MRI of cartilage (dGEMRIC) of the first carpometacarpal (1CMC) joint: a feasibility study.** *Osteoarthritis Cartilage* 2008, **16**:530-532.
 35. Miese FR, Ostendorf B, Wittsack HJ, Reichelt DC, Mamisch TC, Zilkens C, Lanzman RS, Schneider M, Scherer A: **Metacarpophalangeal joints in rheumatoid arthritis: delayed gadolinium-enhanced MR imaging of cartilage - a feasibility study.** *Radiology* 2010, **257**:441-447.
 36. Lewis AR, Nolan MJ, Hodgson RJ, Benjamin M, Ralphs JR, Archer CW, Tyler JA, Hall LD: **High resolution magnetic resonance imaging of the proximal interphalangeal joints. Correlation with histology and production of a three-dimensional data set.** *J Hand Surg Br* 1996, **21**:488-495.
 37. Erickson SJ, Kneeland JB, Middleton WD, Jesmanowicz A, Hyde J, Lawson TL, Foley WD: **MR imaging of the finger: correlation with normal anatomic sections.** *AJR Am J Roentgenol* 1989, **152**:1013-1019.
 38. Tan AL, Grainger AJ, Tanner SF, Shelley DM, Pease C, Emery P, McGonagle D: **High-resolution magnetic resonance imaging for the assessment of hand osteoarthritis.** *Arthritis Rheum* 2005, **52**:2355-2365.
 39. Tan AL, McGonagle D: **Psoriatic arthritis: correlation between imaging and pathology.** *Joint Bone Spine* 2010, **77**:206-211.
 40. Moore A, Sun PZ, Cory D, Hogemann D, Weissleder R, Lipes MA: **MRI of insulinitis in autoimmune diabetes.** *Magn Reson Med* 2002, **47**:751-758.
 41. Taylor AM, Panting JR, Keegan J, Gatehouse PD, Amin D, Jhooti P, Yang GZ, McGill S, Burman ED, Francis JM, Firmin DN, Pennell DJ: **Safety and preliminary findings with the intravascular contrast agent NC100150 injection for MR coronary angiography.** *J Magn Reson Imaging* 1999, **9**:220-227.
 42. Sharma R, Saini S, Ros PR, Hahn PF, Small WC, de Lange EE, Stillman AE, Edelman RR, Runge VM, Outwater EK, Morris M, Lucas M: **Safety profile of ultrasmall superparamagnetic iron oxide ferumoxtran-10: phase II clinical trial data.** *J Magn Reson Imaging* 1999, **9**:291-294.
 43. Reynolds PR, Larkman DJ, Haskard DO, Hajnal JV, Kennea NL, George AJ, Edwards AD: **Detection of vascular expression of E-selectin in vivo with MR imaging.** *Radiology* 2006, **241**:469-476.
 44. Stach CM, Bauerle M, Englbrecht M, Kronke G, Engelke K, Manger B, Schett G: **Periarticular bone structure in rheumatoid arthritis patients and healthy individuals assessed by high-resolution computed tomography.** *Arthritis Rheum* 2010, **62**:330-339.
 45. Weissleder R, Pittet MJ: **Imaging in the era of molecular oncology.** *Nature* 2008, **452**:580-589.
 46. Gompels LL, Lim NH, Vincent T, Paleolog EM: **In vivo optical imaging in arthritis - an enlightening future?** *Rheumatology (Oxford)* 2010, **49**:1436-1446.
 47. Kulka JP, Bocking D, Ropes MW, Bauer W: **Early joint lesions of rheumatoid arthritis; report of eight cases, with knee biopsies of lesions of less than one year's duration.** *AMA Arch Pathol* 1955, **59**:129-150.
 48. Schumacher HR, Kitridou RC: **Synovitis of recent onset. A clinicopathologic study during the first month of disease.** *Arthritis Rheum* 1972, **15**:465-485.
 49. Hansch A, Frey O, Hilger I, Sauner D, Haas M, Schmidt D, Kurrat C, Gajda M, Malich A, Brauer R, Kaiser WA: **Diagnosis of arthritis using near-infrared fluorescence Cy5.5.** *Invest Radiol* 2004, **39**:626-632.
 50. Fischer T, Gemeinhardt I, Wagner S, Stieglitz DV, Schnorr J, Hermann KG, Ebert

- B, Petzelt D, Macdonald R, Licha K, Schirmer M, Krenn V, Kamradt T, Taupitz M: **Assessment of unspecific near-infrared dyes in laser-induced fluorescence imaging of experimental arthritis.** *Acad Radiol* 2006, **13**:4-13.
51. Andersson SE, Johansson A, Lexmuller K, Ekstrom GM: **Physiological characterization of mBSA antigen induced arthritis in the rat. II. Joint blood flow, glucose metabolism, and cell proliferation.** *J Rheumatol* 1998, **25**:1778-1784.
52. Harris JM, Chess RB: **Effect of pegylation on pharmaceuticals.** *Nat Rev Drug Discov* 2003, **2**:214-221.
53. Palframan R, Airey M, Moore A, Vugler A, Nesbitt A: **Use of biofluorescence imaging to compare the distribution of certolizumab pegol, adalimumab, and infliximab in the inflamed paws of mice with collagen-induced arthritis.** *J Immunol Methods* 2009, **348**:36-41.
54. Patel AM, Moreland LW: **Certolizumab pegol: a new biologic targeting rheumatoid arthritis.** *Expert Rev Clin Immunol* 2010, **6**:855-866.
55. Hansch A, Frey O, Sauner D, Hilger I, Haas M, Malich A, Brauer R, Kaiser WA: **In vivo imaging of experimental arthritis with near-infrared fluorescence.** *Arthritis Rheum* 2004, **50**:961-967.
56. Chen WT, Mahmood U, Weissleder R, Tung CH: **Arthritis imaging using a near-infrared fluorescence folate-targeted probe.** *Arthritis Res Ther* 2005, **7**:R310-317.
57. Simon GH, Daldrup-Link HE, Kau J, Metz S, Schlegel J, Piontek G, Saborowski O, Demos S, Duyster J, Pichler BJ: **Optical imaging of experimental arthritis using allogeneic leukocytes labeled with a near-infrared fluorescent probe.** *Eur J Nucl Med Mol Imaging* 2006, **33**:998-1006.
58. Gompels LL, Madden L, Lim NH, Inglis JJ, McConnell E, Vincent TL, Haskard DO, Paleolog EM: **In vivo fluorescence imaging of E-selectin: Quantitative detection of endothelial activation in arthritis.** *Arthritis Rheum* 2010 [Epub ahead of print].
59. Jiang T, Olson ES, Nguyen QT, Roy M, Jennings PA, Tsien RY: **Tumor imaging by means of proteolytic activation of cell-penetrating peptides.** *Proc Natl Acad Sci U S A* 2004, **101**:17867-17872.
60. Lang A, Horler D, Baici A: **The relative importance of cysteine peptidases in osteoarthritis.** *J Rheumatol* 2000, **27**:1970-1979.
61. Lai WF, Chang CH, Tang Y, Bronson R, Tung CH: **Early diagnosis of osteoarthritis using cathepsin B sensitive near-infrared fluorescent probes.** *Osteoarthritis Cartilage* 2004, **12**:239-244.
62. Bhaumik S, Gambhir SS: **Optical imaging of Renilla luciferase reporter gene expression in living mice.** *Proc Natl Acad Sci U S A* 2002, **99**:377-382.
63. Weissleder R, Tung CH, Mahmood U, Bogdanov A Jr: **In vivo imaging of tumors with protease-activated near-infrared fluorescent probes.** *Nat Biotechnol* 1999, **17**:375-378.
64. Chen J, Tung CH, Mahmood U, Ntziachristos V, Gyurko R, Fishman MC, Huang PL, Weissleder R: **In vivo imaging of proteolytic activity in atherosclerosis.** *Circulation* 2002, **105**:2766-2771.
65. Wunder A, Tung CH, Muller-Ladner U, Weissleder R, Mahmood U: **In vivo imaging of protease activity in arthritis: a novel approach for monitoring treatment response.** *Arthritis Rheum* 2004, **50**:2459-2465.
66. Izmailova ES, Paz N, Alencar H, Chun M, Schopf L, Hepperle M, Lane JH, Harriman G, Xu Y, Ocaim T, Weissleder R, Mahmood U, Healy AM, Jaffe B: **Use of molecular imaging to quantify response to IKK-2 inhibitor treatment in murine arthritis.** *Arthritis Rheum* 2007, **56**:117-128.
67. Wilson T, Hastings JW: **Bioluminescence.** *Annu Rev Cell Dev Biol* 1998, **14**:197-230.
68. Iris B, Zilberman Y, Zeira E, Galun E, Honigman A, Turgeman G, Clemens T, Gazit Z, Gazit D: **Molecular imaging of the skeleton: quantitative real-time bioluminescence monitoring gene expression in bone repair and development.** *J Bone Miner Res* 2003, **18**:570-578.
69. Carlsen H, Moskaug JO, Fromm SH, Blomhoff R: **In vivo imaging of NF-kappa B activity.** *J Immunol* 2002, **168**:1441-1446.
70. Nakajima A, Serogy CM, Sandora MR, Tarner IH, Costa GL, Taylor-Edwards C, Bachmann MH, Contag CH, Fathman CG: **Antigen-specific T cell-mediated gene therapy in collagen-induced arthritis.** *J Clin Invest* 2001, **107**:1293-1301.
71. Wehrl HF, Judenhofer MS, Wiehr S, Pichler BJ: **Pre-clinical PET/MR: technological advances and new perspectives in biomedical research.** *Eur J Nucl Med Mol Imaging* 2009, **36** Suppl 1:S56-68.
72. Linke R, Kuwert T, Uder M, Forst R, Wuest W: **Skeletal SPECT/CT of the peripheral extremities.** *AJR Am J Roentgenol* 2010, **194**:W329-335.
73. Ntziachristos V, Yodh AG, Schnall M, Chance B: **Concurrent MRI and diffuse optical tomography of breast after indocyanine green enhancement.** *Proc Natl Acad Sci U S A* 2000, **97**:2767-2772.
74. Olson ES, Jiang T, Aguilera TA, Nguyen QT, Ellies LG, Scadeng M, Tsien RY: **Activatable cell penetrating peptides linked to nanoparticles as dual probes for in vivo fluorescence and MR imaging of proteases.** *Proc Natl Acad Sci U S A* 2010, **107**:4311-4316.
75. Ostendorf B, Scherer A, Wirrwar A, Hoppin JW, Lackas C, Schramm NU, Cohnen M, Mödder U, van den Berg WB, Müller HW, Schneider M, Joosten LA: **High-resolution multipinhole single-photon-emission computed tomography in experimental and human arthritis.** *Arthritis Rheum* 2006, **54**:1096-1104.
76. Ostendorf B, Mattes-Gyorgy K, Reichelt DC, Blondin D, Wirrwar A, Lanzman R, Müller HW, Schneider M, Modder U, Scherer A: **Early detection of bony alterations in rheumatoid and erosive arthritis of finger joints with high-resolution single photon emission computed tomography, and differentiation between them.** *Skeletal Radiol* 2010, **39**:55-61.
77. Broome DR, Girguis MS, Baron PW, Cottrell AC, Kjellin I, Kirk GA: **Gadodiamide-associated nephrogenic systemic fibrosis: why radiologists should be concerned.** *AJR Am J Roentgenol* 2007, **188**:586-592.
78. Buyukhatipoglu K, Clyne AM: **Superparamagnetic iron oxide nanoparticles change endothelial cell morphology and mechanics via reactive oxygen species formation.** *J Biomed Mater Res A* 2010 [Epub ahead of print].
79. Buyukhatipoglu K, Miller TA, Clyne AM: **Flame synthesis and in vitro biocompatibility assessment of superparamagnetic iron oxide nanoparticles: cellular uptake, toxicity and proliferation studies.** *J Nanosci Nanotechnol* 2009, **9**:6834-6843.
80. Aletaha D, Funovits J, Breedveld FC, Sharp J, Segurado O, Smolen JS: **Rheumatoid arthritis joint progression in sustained remission is determined by disease activity levels preceding the period of radiographic assessment.** *Arthritis Rheum* 2009, **60**:1242-1249.
81. Smolen JS, Han C, Bala M, Maini RN, Kalden JR, van der Heijde D, Breedveld FC, Furst DE, Lipsky PE: **Evidence of radiographic benefit of treatment with infliximab plus methotrexate in rheumatoid arthritis patients who had no clinical improvement: a detailed subanalysis of data from the anti-tumor necrosis factor trial in rheumatoid arthritis with concomitant therapy study.** *Arthritis Rheum* 2005, **52**:1020-1030.
82. Landewe R, van der Heijde D, Klareskog L, van Vollenhoven R, Fatenejad S: **Disconnect between inflammation and joint destruction after treatment with etanercept plus methotrexate: results from the trial of etanercept and methotrexate with radiographic and patient outcomes.** *Arthritis Rheum* 2006, **54**:3119-3125.
83. Molenaar ET, Voskuyl AE, Dinant HJ, Bezemer PD, Boers M, Dijkmans BA: **Progression of radiologic damage in patients with rheumatoid arthritis in clinical remission.** *Arthritis Rheum* 2004, **50**:36-42.
84. Brown AK, Conaghan PG, Karim Z, Quinn MA, Ikeda K, Peterfy CG, Hensor E, Wakefield RJ, O'Connor PJ, Emery P: **An explanation for the apparent dissociation between clinical remission and continued structural deterioration in rheumatoid arthritis.** *Arthritis Rheum* 2008, **58**:2958-2967.
85. Lee L, Buckley C, Blades MC, Panayi G, George AJ, Pitzalis C: **Identification of synovium-specific homing peptides by in vivo phage display selection.** *Arthritis Rheum* 2002, **46**:2109-2120.
86. Gold L, Polisky B, Uhlenbeck O, Yarus M: **Diversity of oligonucleotide functions.** *Annu Rev Biochem* 1995, **64**:763-797.
87. Famulok M, Mayer G: **Aptamers as tools in molecular biology and immunology.** *Curr Top Microbiol Immunol* 1999, **243**:123-136.
88. Watson SR, Chang YF, O'Connell D, Weigand L, Ringquist S, Parma DH: **Anti-L-selectin aptamers: binding characteristics, pharmacokinetic parameters, and activity against an intravascular target in vivo.** *Antisense Nucleic Acid Drug Dev* 2000, **10**:63-75.
89. Ruckman J, Green LS, Beeson J, Waugh S, Gillette WL, Henninger DD, Claesson-Welsh L, Janjic N: **2'-Fluoropyrimidine RNA-based aptamers to the 165-amino acid form of vascular endothelial growth factor (VEGF165). Inhibition of receptor binding and VEGF-induced vascular permeability through interactions requiring the exon 7-encoded domain.** *J Biol Chem* 1998, **273**:20556-20567.
90. Csaky K: **Anti-vascular endothelial growth factor therapy for neovascular age-related macular degeneration: promises and pitfalls.** *Ophthalmology* 2003, **110**:879-881.
91. Charlton J, Sennello J, Smith D: **In vivo imaging of inflammation using an aptamer inhibitor of human neutrophil elastase.** *Chem Biol* 1997, **4**:809-816.
92. Hicke BJ, Stephens AW, Gould T, Chang YF, Lynott CK, Heil J, Borkowski S, Hilger CS, Cook G, Warren S, Schmidt PG: **Tumor targeting by an aptamer.**

- J Nucl Med* 2006, **47**:668-678.
93. Huang YF, Chang HT, Tan W: **Cancer cell targeting using multiple aptamers conjugated on nanorods.** *Anal Chem* 2008, **80**:567-572.
94. Paulos CM, Varghese B, Widmer WR, Breur GJ, Vlashi E, Low PS: **Folate-targeted immunotherapy effectively treats established adjuvant and collagen-induced arthritis.** *Arthritis Res Ther* 2006, **8**:R77.
95. Tsien RY: **Constructing and exploiting the fluorescent protein paintbox (Nobel Lecture).** *Angew Chem Int Ed Engl* 2009, **48**:5612-5626.
96. Shu X, Royant A, Lin MZ, Aguilera TA, Lev-Ram V, Steinbach PA, Tsien RY: **Mammalian expression of infrared fluorescent proteins engineered from a bacterial phytochrome.** *Science* 2009, **324**:804-807.
97. Razansky D, Distel M, Vinegoni C, Ma R, Perrimon N, Koster RW, Ntziachristos V: **Multispectral opto-acoustic tomography of deep-seated fluorescent proteins *in vivo*.** *Nat Photonics* 2009, **3**:412-417.

doi:10.1186/ar3197

Cite this article as: Gompels LL, Paleolog EM: **A window on disease pathogenesis and potential therapeutic strategies: molecular imaging for arthritis.** *Arthritis Research & Therapy* 2011, **13**:201.