

## Oncology

# Hand-assisted laparoscopic radical nephrectomy for renal cell carcinoma in a patient with situs inversus totalis

Eric M. Chevli<sup>a,\*</sup>, Tyler J. Maiers<sup>a</sup>, David J. Abramowitz<sup>a</sup>, Shervin Badkhshan<sup>a</sup>, John J. Bodkin III<sup>a,b</sup>

<sup>a</sup> Department of Urology, University at Buffalo, Jacobs School of Medicine and Biomedical Sciences, Buffalo General Medical Center, 100 High Street, Suite B280, Buffalo, NY, 14203, USA

<sup>b</sup> Western New York Urology Associates, 3085 Harlem Rd, Cheektowaga, NY, 14225, USA



## ARTICLE INFO

## Keywords:

Laparoscopy  
Oncology  
Renal cell carcinoma  
RCC  
Situs inversus totalis

## ABSTRACT

Situs inversus totalis (SIT) is a rare condition with left-right mirror imaging of both abdominal and thoracic organs. While this configuration is rarely of medical importance, an understanding of this unique anatomy is essential in the setting of surgical intervention. Here we review a case of renal cell carcinoma (RCC) in the setting of SIT. The patient underwent a hand-assisted laparoscopic radical nephrectomy. Pathology revealed pT3aNxMx Fuhrman Grade 2 clear cell RCC.

## Introduction

Situs inversus totalis (SIT) is the left-right inversion of both abdominal and thoracic organs resulting in a mirror-image appearance. SIT is a rare condition, with reported incidence ranging from 1 in 8000 to 1 in 25,000.<sup>1</sup> The incidence of SIT has increased over time, largely due to advancements in medical imaging leading to higher incidental detection rates. While SIT is rarely of medical significance, it is critically important to understand in the setting of surgical intervention. The mirror imaging of organs along the sagittal plane creates a more technically difficult procedural environment secondary to surgeon unfamiliarity of this atypical anatomy. There are few reported surgical interventions on patients with SIT, and even fewer reported cases of renal cell carcinoma (RCC) in the setting of SIT.<sup>2</sup> The present study reports a case of RCC in the setting of SIT successfully managed by left hand-assisted laparoscopic radical nephrectomy.

## Case presentation

A 70 year-old Hispanic female with past medical history significant for hypertension and hypothyroidism originally presented to the emergency room with flank pain and gross hematuria. The patient was referred to a urologist for further workup. She underwent cystoscopy under anesthesia which revealed no evidence of tumor, inflammation,

mucosal abnormality, or bloody efflux from ureteral orifices bilaterally. Magnetic resonance imaging (MRI) of the abdomen and pelvis (Fig. 1) as well as computed tomography (CT) Urogram (Fig. 2) was performed and revealed a 7.8-cm heterogeneous mass along the inferior aspect of the left kidney with associated protrusion into the lower renal sinus along with associated central hypodensity and a 5-mm focus of calcification. Also notable was the presence of left to right mirror imaging of the patient's thoracic and abdominal organs consistent with SIT. The recommendation for surgical extirpation of the left kidney due to concern for RCC was discussed in detail. The patient was agreeable to proceed with a left hand-assisted laparoscopic radical nephrectomy.

Surgical intervention proceeded uneventfully. Access was obtained via two 12-mm port sites placed in the patient's left lower quadrant approximately 10-cm apart as well as an 8-cm Gelpport system for hand assistance. The liver was readily identified on the patient's left side. The left kidney was partially visualized beneath the patient's ascending colon. The colon was reflected medially and further dissection around the kidney proceeded without complication. The left ureter was identified, clipped and severed. The vena cava was located on the patient's left, and care was taken to ensure this was not involved in the dissection. Inspection of the hilum revealed a very short left renal vein. A 16-mm Echelon linear stapler was used to free the hilum and the specimen was removed through the midline incision accommodating the Gelpport and was sent to pathology. The patient tolerated the procedure well, had

\* Corresponding author.

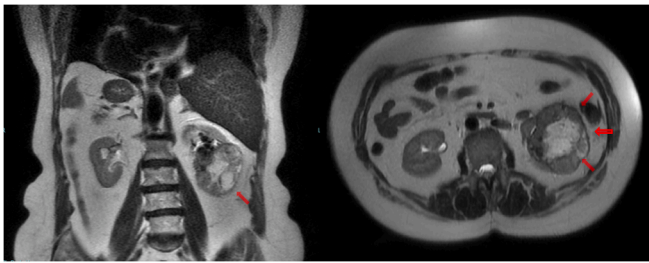
E-mail addresses: [ericchev@buffalo.edu](mailto:ericchev@buffalo.edu) (E.M. Chevli), [tmaiers@buffalo.edu](mailto:tmaiers@buffalo.edu) (T.J. Maiers), [dja23@buffalo.edu](mailto:dja23@buffalo.edu) (D.J. Abramowitz), [shervinb@buffalo.edu](mailto:shervinb@buffalo.edu) (S. Badkhshan), [jbodkin@buffalo.edu](mailto:jbodkin@buffalo.edu) (J.J. Bodkin).

<https://doi.org/10.1016/j.eucr.2019.101076>

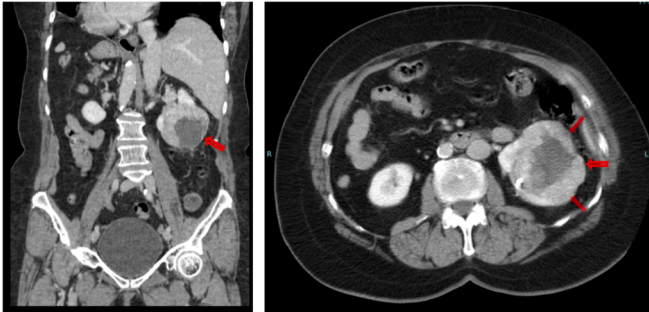
Received 23 August 2019; Received in revised form 18 November 2019; Accepted 20 November 2019

Available online 20 November 2019

2214-4420/© 2019 Published by Elsevier Inc. This is an open access article under the CC BY-NC-ND license (<http://creativecommons.org/licenses/by-nc-nd/4.0/>).



**Fig. 1.** Coronal and axial T2 MRI abdomen demonstrating a 7.8-cm heterogeneous left lower pole renal mass (red arrows) with mirror imaging of the abdominal and thoracic organs.



**Fig. 2.** Coronal and axial CT Abdomen/Pelvis demonstrating a heterogeneous 7.8-cm left lower pole renal mass with associated central hypodensity (red arrows) and 5-mm focus of calcification. Mirror imaging of abdominal organs is consistent with SIT.

an uncomplicated postoperative hospital course, and was discharged on postoperative day two.

Pathology subsequently revealed pT3aNxMx Fuhrman Grade 2 clear cell RCC measuring 6-cm in maximal dimension with invasion into the perirenal fat. There were no issues during routine postoperative follow-up visits.

## Discussion

There are few prior reports of surgical intervention for RCC in the setting of SIT. A review of the literature yielded ten published articles in which surgery was performed on patients with RCC in the setting of SIT; three stemming from the United States, one from Canada, one from Spain, one from Zambia, and four from Japan.<sup>1,3</sup> There were three laparoscopic interventions and seven open interventions described previously.<sup>1,3</sup> A single other case of RCC in a woman with SIT was reported in 1987.<sup>1</sup>

The underlying etiology and genetics of SIT is relatively unknown, however it has been hypothesized by Nonaka et al. that there may be a

correlation with the kinesin superfamily proteins 3B, which is consistent with the increased incidence in those with primary ciliary dyskinesia (20–25% of reported SIT cases), otherwise known as Kartagener Syndrome.<sup>4</sup> SIT may be associated with a wide variety of anatomic anomalies such as duodenal and biliary atresia, organ agenesis, cardiopulmonary abnormalities, and vascular anomalies such as aberrant or duplicated vessels.

In this case, the hand-assisted approach led to excellent visualization of the patient's unusual abdominal anatomy throughout the procedure and aided in highly efficient dissection. Surgeon preference, tumor size, and tumor location also contributed to the decision to pursue a hand-assisted laparoscopic approach. There were no significant vascular abnormalities such as duplication or aberrancy of vessels, other than venous branching and neovascularization proximal to the kidney, along with the expected mirror image lateralization of the inferior vena cava and the aorta. This resulted in a shorter left renal vein than would be typically found, which was important to recognize when approaching the renal hilum. In the setting of a shortened renal vein, tumor thrombus may have greater access for progression to the inferior vena cava due to the decreased distance involved. Fortunately, no tumor thrombus was present in this case. No intraoperative or postoperative complications occurred. This case highlights the importance in delineating preoperatively the mirror imaging of the patient's organs, along with the increased risk of vessel abnormalities to help facilitate successful intervention in the rare surgical environment of SIT.

## Conclusion

SIT is a rare anatomic abnormality that is critical to identify preoperatively to aid in surgical planning. This case demonstrates that RCC in the setting of SIT can be managed successfully via hand-assisted laparoscopic radical nephrectomy.

## Funding

This research did not receive any specific grant from funding agencies in the public, commercial, or not-for-profit sectors.

## References

- Oake J, Drachenberg D. A case of renal cell carcinoma in a patient with situs inversus: operative considerations and a review of the literature. *Can Urol Assoc J.* 2017;11(5): E233–E236. <https://doi.org/10.5489/cuaj.4290>.
- Douard R, Feldman A, Bary F, et al. Anomalies of lateralization in man a case of total situs inversus. *Surg Radiol Anat.* 2001;22:293. <https://doi.org/10.1007/s00276-000-0293-y>.
- Ito J, Kaiho Y, Iwamura H, Anan G, Sato M. Laparoscopic radical nephrectomy for a right renal tumor with renal vein tumor thrombus in a patient with situs inversus totalis. *Asian J Endosc Surg.* 2019;12:185–188. <https://doi.org/10.1111/ases.12608>.
- Wojcik J, Grodzki T, Bielewicz M, et al. Lung cancer in situs inversus totalis (SIT)—literature review. *Adv Med Sci.* 2013;58:1–8. <https://doi.org/10.2478/v10039-012-0083-x>.