

CASE REPORT



Necrotizing fasciitis of the breast managed by partial mastectomy and local tissue rearrangement

Ryan D. Konik^a, Adam D. Cash^b and Gregory S. Huang^a

^aDepartment of General Surgery, St. Elizabeth Health Center, Youngstown, OH, USA; ^bDepartment of Plastic and Reconstructive Surgery, St. Elizabeth Health Center, Youngstown, OH, USA

ABSTRACT

Necrotizing fasciitis (NF) of the breast is a rare occurrence that is routinely misdiagnosed as an abscess or cellulitis, resulting in treatment delays. A total mastectomy is required when delays occur. We present a 53-year-old female with breast NF managed with a partial mastectomy and local tissue rearrangement.

ARTICLE HISTORY

Received 9 May 2017
Accepted 31 July 2017

KEYWORDS

Necrotizing fasciitis; breast; partial mastectomy; local tissue rearrangement

Introduction

Necrotizing fasciitis (NF) is a life-threatening condition characterized by spreading necrosis of subcutaneous tissue and fascia. It mainly affects the extremities, abdominal wall or perineum [1]. The breasts are rarely affected, with most cases presenting after trauma or surgical intervention. Primary NF of the breast may be misdiagnosed for an abscess or cellulitis leading to treatment delays [2]. Prompt assessment is pivotal to preserve breast tissue. Many misdiagnosed cases require a total mastectomy. If recognized early, the robust blood supply makes salvaging the breast parenchyma possible [3]. In this report, we present a unique case of primary NF of the breast managed by partial mastectomy and local tissue rearrangement.

Case presentation

A 53-year-old woman was transferred to our facility with a left breast wound demonstrating signs of skin necrosis, erythema and severe pain. Past medical history included hypertension, asthma and obesity with a BMI of 41 kg/m². She reported a current smoking history. She denied a family history of breast cancer and never had a mammogram.

The patient was seen three days prior at an outside facility for an abscess overlying the lower inner quadrant of the left breast. An incision and drainage

was performed. The wound was packed, and the patient was discharged home with Sulfamethoxazole-Trimethoprim. She returned to the same facility two days later with worsening erythema, pain and malodorous drainage from the previous incision and drainage site. She had a heart rate of 111 bpm and a blood pressure of 96/53 mmHg. A CT scan of the chest demonstrated gas in the soft tissues of the left breast and anterior chest wall with no evidence of abscess formation. The patient was given one dose of Vancomycin and Piperacillin-Tazobactam, intravenous fluids, and transferred to our facility.

On exam, her left breast and sternum were erythematous, swollen, and tender to palpation. Purulent, foul smelling material was expressed from the prior incision site. Subcutaneous crepitus was appreciated. There was a 7.5 cm × 5.5 cm area of necrotic skin located inferior-medially within the breast at the location of the initial incision and drainage site (Figure 1). Her lab values demonstrated a leukocytosis of 15.6 × 10.9/L, hyponatremia of 128 mmol/L, elevated creatinine of 1.4 mg/dL, and elevated glucose of 113 mg/dL. A diagnosis of primary NF was concluded and emergency surgical intervention was arranged. Meanwhile, she was started on intravenous Meropenem, Vancomycin and Clindamycin.

The patient was taken to the operating theatre shortly after presentation. Excisional debridement of the left breast with a partial mastectomy of the lower

CONTACT Ryan D. Konik  rdkonik@mercy.com  1044 Belmont Ave, Youngstown, OH 44504, USA

© 2017 The Author(s). Published by Informa UK Limited, trading as Taylor & Francis Group.

This is an Open Access article distributed under the terms of the Creative Commons Attribution-NonCommercial License (<http://creativecommons.org/licenses/by-nc/4.0/>), which permits unrestricted non-commercial use, distribution, and reproduction in any medium, provided the original work is properly cited.

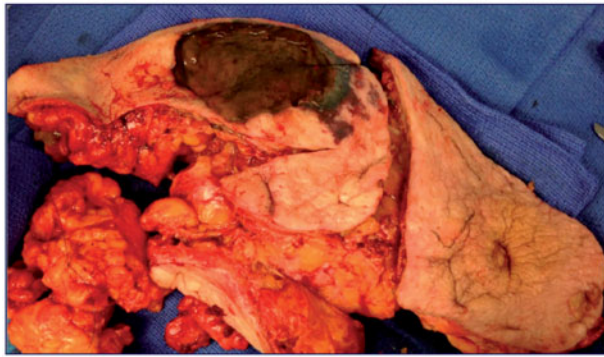


Figure 1. Left breast tissue and nipple-areolar complex with eschar.

breast tissue was performed. Nipple areolar complex was removed due to evidence of necrosis. An area of 22 cm × 15 cm × 5.5 cm was removed (Figure 2). The wound was packed and skin edges loosely approximated (Figure 3). Her wound was re-explored 24 hours later during a dressing change. No further areas of necrosis were identified for debridement.

Pathology results confirmed the diagnosis and demonstrated breast tissue with extensive acute inflammation, abscesses and necrosis with bacterial colonization of the skin and underlying subcutaneous adipose tissue (Figure 4). Specimen was negative for malignancy. Intraoperative wound cultures grew coagulase negative Staphylococci, and anaerobic cultures demonstrated light growth of beta lactamase gram-negative rods. Coagulase negative Staphylococci was susceptible to oxacillin, doxycycline, gentamicin, tigecycline and vancomycin. Further speciation of anaerobic cultures was not completed. The patient was started on IV Cefazolin on postoperative day 3 and oral Metronidazole on postoperative day 7 for anaerobic coverage according to infectious disease recommendations.

A plastic surgery consult was obtained for reconstruction of the left breast defect. The patient underwent local tissue rearrangement with complex closure of the left breast eight days after the index operation. Excess lateral breast tissue was rotated medially to fill the defect, a Blake drain was placed, and the wound closed in multiple layers. She was discharged home nine days after admission. She was seen in office 1 month later with no issues and a well-healing incision.

Discussion

Necrotizing fasciitis is a life-threatening, rapidly progressive infection involving the fascia and subcutaneous tissues. Clinical characteristics include erythema,

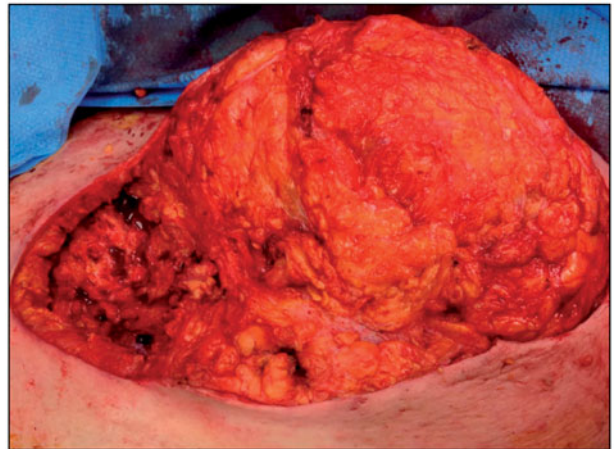


Figure 2. Left breast defect.

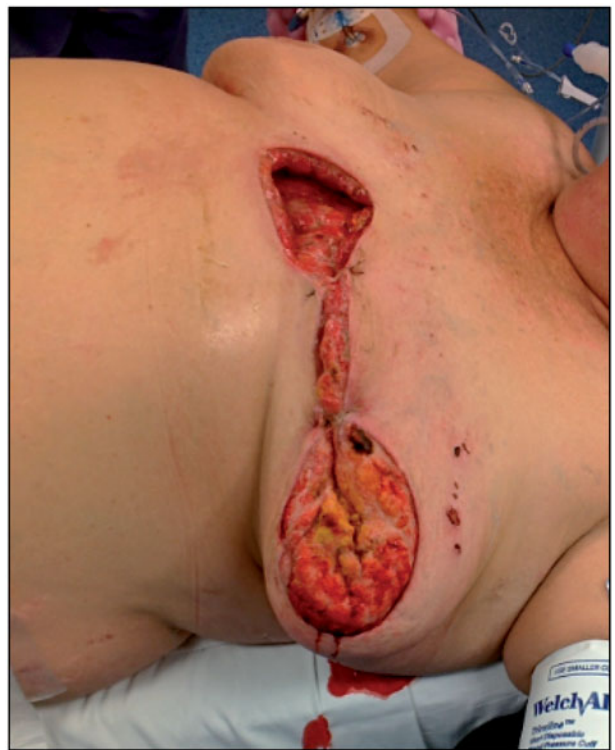

Figure 3. Left breast defect with loose approximation prior to reconstruction.

swelling, pain disproportionate to exam, necrosis, blisters/bullae formation, and crepitus. Patients may present in septic shock with multi-organ failure. Comorbidities associated with NF include diabetes mellitus, peripheral vascular disease, alcoholic liver disease, immunosuppression and obesity [4,5]. It most commonly affects the extremities followed by the trunk and perineum [5]. In the majority of cases, a trivial incident, such as a traumatic injury, insect bite or injection site, is identified as the cause of the infection [6]. NF of the breast has been reported following a

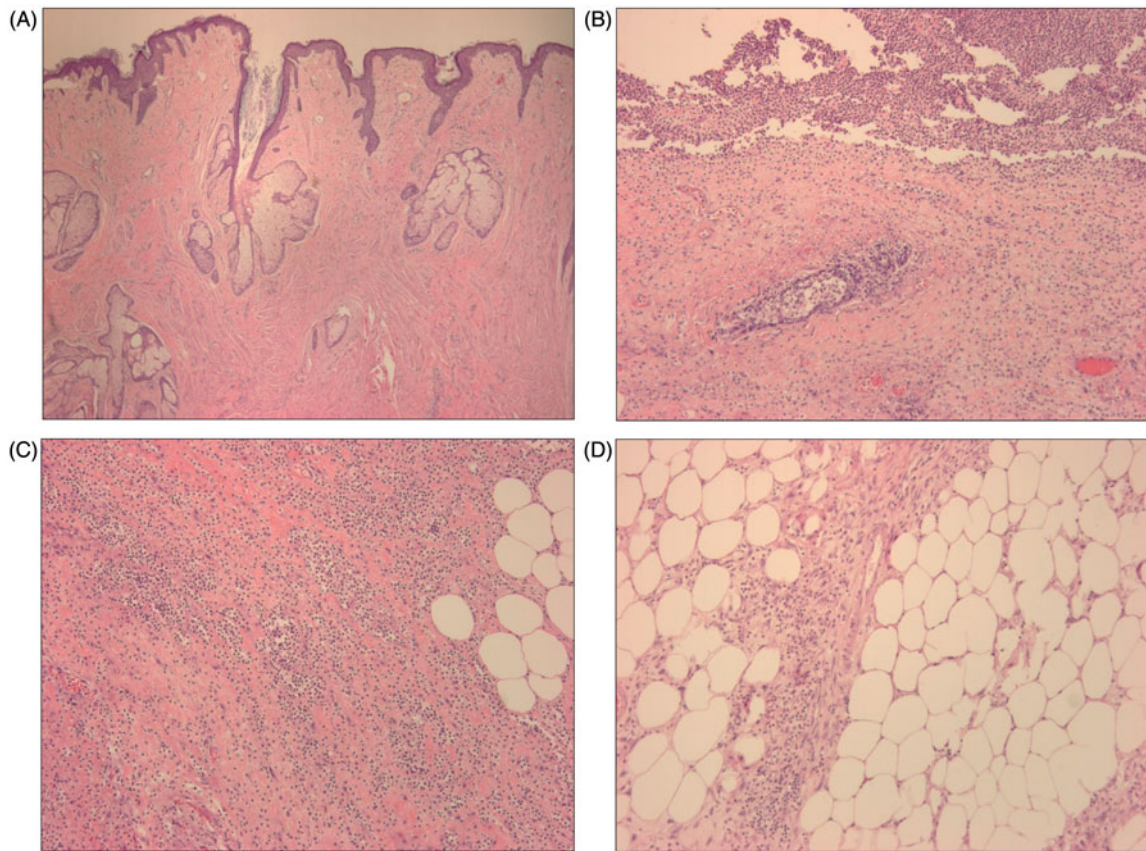


Figure 4. Histology of surgical specimen. (A) Nipple and areola (H&E stain, 40× magnification). (B) Abscess and surrounding breast parenchyma (H&E stain, 100× magnification). (C) Acute inflammation of breast stroma (H&E stain, 100× magnification). (D) Organizing fat necrosis (H&E stain, 100× magnification).

total mastectomy, core-needle biopsy and breast augmentation [7]. Primary NF of the breast is a rare occurrence. In this case, we present a patient with primary breast NF without an inciting event or evidence of underlying neoplasm.

There are two distinct types of NF based on microbiological cultures. Type I infections are polymicrobial consisting of non-group-A streptococci, aerobic organisms and anaerobic organisms. Type II infections are caused by *Streptococcus pyogenes* [5]. Wound cultures grew coagulase negative staphylococci and beta lactamase gram negative rods in the present case. It is odd for coagulase negative staphylococci to cause such a fulminant infection. The extensive necrotizing infection that resulted could have been secondary to inadequate gram-negative coverage from the initial treatment with Sulfamethoxazole-Trimethoprim.

The basis of treatment is fluid resuscitation, broad-spectrum antibiotics, and early surgical debridement. Prompt diagnosis is critical for survival. Delays in diagnosis are common and occur secondary to the lack of cutaneous findings. Many times, NF is mistaken for cellulitis or abscesses formation [5]. In cases of primary

NF of the breast, cutaneous findings may not be apparent because of the thicker tissue between the deep fascia and skin. By the time cutaneous signs are noticed, the damage is extensive and necessitates a mastectomy [3]. In the present case, the initial diagnosis was of breast abscess with cellulitis. She returned after failed treatment in a short period of time. Despite the delay, the patient only required a partial mastectomy. There has only been one case described in the literature in which a partial mastectomy was completed for the initial debridement [3]. This may have been possible due to the large amount of subcutaneous tissue and the robust blood supply of the breast parenchyma.

Shah et al. described the first case of primary NF of the breast in a 50-year-old diabetic female. Through his observations, a six-point management plan was advocated for the treatment of such an infection. In summary, the plan advocated for a radical 'pseudotumor' excision followed by re-exploration of the wound 24 hours later. Reconstructive measures were aimed at delayed skin closure several months after recovery [8]. The management of our

patient differed from these proposed guidelines. First, a partial mastectomy was performed, instead of a radical 'pseudotumor' excision. As for reconstruction, the defect was repaired with local tissue rearrangement and complex wound closure one week after debridement, instead of several months as suggested. Reconstructive measures in several other cases have been completed one to two weeks after devitalized tissues were removed [9]. In addition, many defects were repaired with split-thickness skin grafts, instead of delayed primary closure [9]. This is the first case reported in which local tissue rearrangement and complex closure was used to repair the defect.

Conclusions

Necrotizing fasciitis of the breast is a rare occurrence. The infection may be mistaken for cellulitis or an abscess due to delayed cutaneous findings. When delays occur, the damage may be extensive and a total mastectomy is required for source control. We present a patient with NF of the breast managed with a partial mastectomy. This case represents the importance of a multidisciplinary approach to the management of NF between general surgery and plastic surgery to obtain adequate source control and proper reconstruction.

Disclosure statement

No potential conflict of interest was reported by the authors.

References

- [1] Kaczynski J, Dillon M, Hilton J. Breast necrotizing fasciitis managed by partial mastectomy. *BMJ Case Rep.* 2012;2012. DOI:10.1136/bcr.02.2012.5816.
- [2] Lee JH, Lim YS, Kim NG, et al. Primary necrotizing fasciitis of the breast in an untreated patient with diabetes. *Arch Plast Surg.* 2016;43:613–614.
- [3] Wong CH, Tan BK. Necrotizing fasciitis of the breast. *Plast Reconstr Surg.* 2008;122:151e–152e.
- [4] Anaya DA, Dellinger EP. Necrotizing soft-tissue infection: diagnosis and management. *Clin Infect Dis.* 2007;44:705–710.
- [5] Wong CH, Chang HC, Pasupathy S, et al. Necrotizing fasciitis: clinical presentation, microbiology and determinants of mortality. *J Bone Joint Surg Am.* 2003;85A:14–60.
- [6] Edlich RF, Cross CL, Dahlstrom, JJ, et al. Modern concepts of the diagnosis and treatment of necrotizing fasciitis. *J Emerg Med.* 2010;39:261–265.
- [7] Subramanian A, Thomas G, Lawn A, et al. Necrotising soft tissue infection following mastectomy. *J Surg Case Rep.* 2010;2010:4.
- [8] Shah J, Sharma A, O'Donoghue JM, et al. Necrotising fasciitis of the breast. *Br J Plast Surg.* 2001;54:67–68.
- [9] Yang B, Connolly S, Ball W. Necrotising fasciitis of the breast: a rare primary care with conservation of the nipple and literature review. *JPRAS Open.* 2015;6:15–19.