

Community Eye Health Journal



Double vision is a distressing symptom that warrants investigation. **TANZANIA**

DANIEL ETYAALÉ
(ORIGINAL PHOTOGRAPH)

Neuro-ophthalmology

Understanding vision and the brain



Anand Moodley

Consultant neurologist
Greys Hospital
and University of
KwaZulu-Natal
Pietermaritzburg,
South Africa.

Diseases which affect the visual pathway or the nerves to the eye muscles are often serious. This article summarises the anatomy and function of the 2nd, 3rd, 4th and 6th cranial nerves and the signs and symptoms which are important in making a correct diagnosis.

Neuro-ophthalmology includes the specialties of neurology and ophthalmology. Skills of both specialties are needed to assess patients. A detailed history and clinical examination are needed in order to make a differential diagnosis and create a management plan.

There are two broad groups of neurological conditions that can affect someone's vision:

- 1 Those which affect the visual pathways in the brain and
- 2 Those which affect eye movements.

If the condition affects the visual pathways, there can be loss of visual acuity, loss of visual field, or difficulties

in understanding the visual world, depending on where the lesion is in the visual pathway. If the condition affects the 3rd, 4th or 6th cranial nerves, the main symptom is double vision (diplopia) due to restricted eye movements.

The visual pathways comprise the optic nerve, optic chiasm, optic tract, optic radiation and the visual cortex in the occipital lobes.

Nerve impulses arising in the retina travel via the optic nerve to the optic chiasm. In the optic chiasm there is "crossing over" of some visual information, so that images which fall on the right visual field of each eye

Continues overleaf ➤



About this issue

In this issue of the *Community Eye Health Journal* we briefly discuss the anatomy of vision, before explaining conditions presenting with double vision and/or sudden loss of vision which may be life and/or sight-threatening. There are articles on how to assess a patient with neuro-ophthalmological symptoms; the differential diagnosis of optic atrophy as well as how to counsel a patient with visual loss.

Large textbooks are written on neuro-ophthalmology and therefore it is not possible to discuss in detail the diagnosis and management of many neuro-ophthalmological diseases, but we trust this introduction will provide an insight to the important conditions and encourage you in further reading.

Contents

61 Understanding vision and the brain

Anand Moodley

64 Red flags in neuro-ophthalmology

Olufunmilola Ogun

66 Basic clinical examination of a patient with neuro-ophthalmology symptoms

Anand Moodley

68 How to test for a relative afferent pupillary defect (RAPD)

David C Broadway

70 Counselling patients with sudden, irreversible sight loss

Jasmine Thombs and Louise de Board

72 Differential diagnoses of the pale / white / atrophic disc

Vivian B Osaguona

75 TRACHOMA: New ways of working to support sustainable disease elimination

Geordie Woods, Yael Velleman and Virginia Sarah

76 Visual effects and rehabilitation after stroke

Dr Fiona Rowe

78 Questions and answers on neuro-ophthalmology

79 Picture quiz

79 Announcements and resources

80 KEY MESSAGES

go to left visual cortex via the optic tract and the optic radiation. Visual information from the left visual field in each eye goes to the right visual cortex.

Neurological conditions which affect visual function

Conditions which affect the visual pathways can lead to loss of visual acuity (ranging from blurred vision to complete visual loss), impaired colour vision, or visual field loss (which may be central, nasal or temporal) or affect the right or the left visual field. The type of visual field loss depends on which part of the visual pathway is affected.

Visual Loss

Loss of central visual acuity, with impaired colour vision and contrast sensitivity, suggest an optic nerve condition.

The two main clinical presentations are:

- **Optic neuritis**, with a decrease in vision over a few hours or days and sometimes pain on eye movement from inflammation of the optic nerve and surrounding sheath. Visual acuity is decreased, there is an afferent pupil defect (pupil on the affected side reacts poorly to light), and the optic disc may appear swollen (papillitis). It may be unilateral or bilateral. Causes include multiple sclerosis, some medications and toxins (e.g. cassava or methanol).
- **Optic atrophy**, in which the optic disc is pale. The visual acuity is reduced, colour vision is affected and there is an afferent pupil defect. There are many causes of optic atrophy (see page 69). Optic atrophy may develop slowly due to a progressive cause, or follow an episode of acute optic neuritis.

Visual field defects

Lesions along the visual pathway, from the optic nerve to the occipital lobe, can present with localising visual field defects (**Figure 1**).

- **Optic nerve lesions** cause central, centrocaecal or altitudinal field defects. Central vision is primarily affected.
- **Optic chiasm lesions** caused by space-occupying lesions around the sella turcica (e.g. pituitary tumours) typically cause bitemporal hemianopia. Central vision is usually spared.

Community Eye Health Journal

VOLUME 29 • NUMBER 96 • 2016



Editor

Elmien Wolvaardt
editor@cehjournal.org

Editorial committee

Allen Foster
Clare Gilbert
Nick Astbury
Daksha Patel
Richard Wormald
Matthew Burton
Hannah Kuper
Priya Morjaria
G V Murthy
Fatima Kyari
David Yorston
Sally Crook
Serge Resnikoff
Babar Qureshi
Janet Marsden
Noela Prasad

Regional consultants

Hugh Taylor (WPR)
Leshan Tan (WPR)
GVS Murthy (SEAR)
R Thulsiraj (SEAR)
Babar Qureshi (EMR)
Mansur Rabi (EMR)
Hannah Faal (AFR)
Kovin Naidoo (AFR)
Winjiku Mathenge (AFR)
Ian Murdoch (EUR)
Janos Nemeth (EUR)
Van Lansingh (AMR)
Andrea Zin (AMR)

Editorial assistant Anita Shah

Design Lance Bellers

Printing Newman Thomson

CEHJ online

Visit the *Community Eye Health Journal*

online. All back issues are available as HTML and PDF. Visit www.cehjournal.org

Online edition and newsletter
web@cehjournal.org

Consulting editors for Issue 96

Allen Foster and Nick Astbury

Please support us

We rely on donations/subscriptions from charities and generous individuals to carry out our work. We need your help.

Subscriptions in high-income countries cost UK £100 per annum.

Contact Anita Shah
admin@cehjournal.org

or visit our website:
www.cehjournal.org/donate

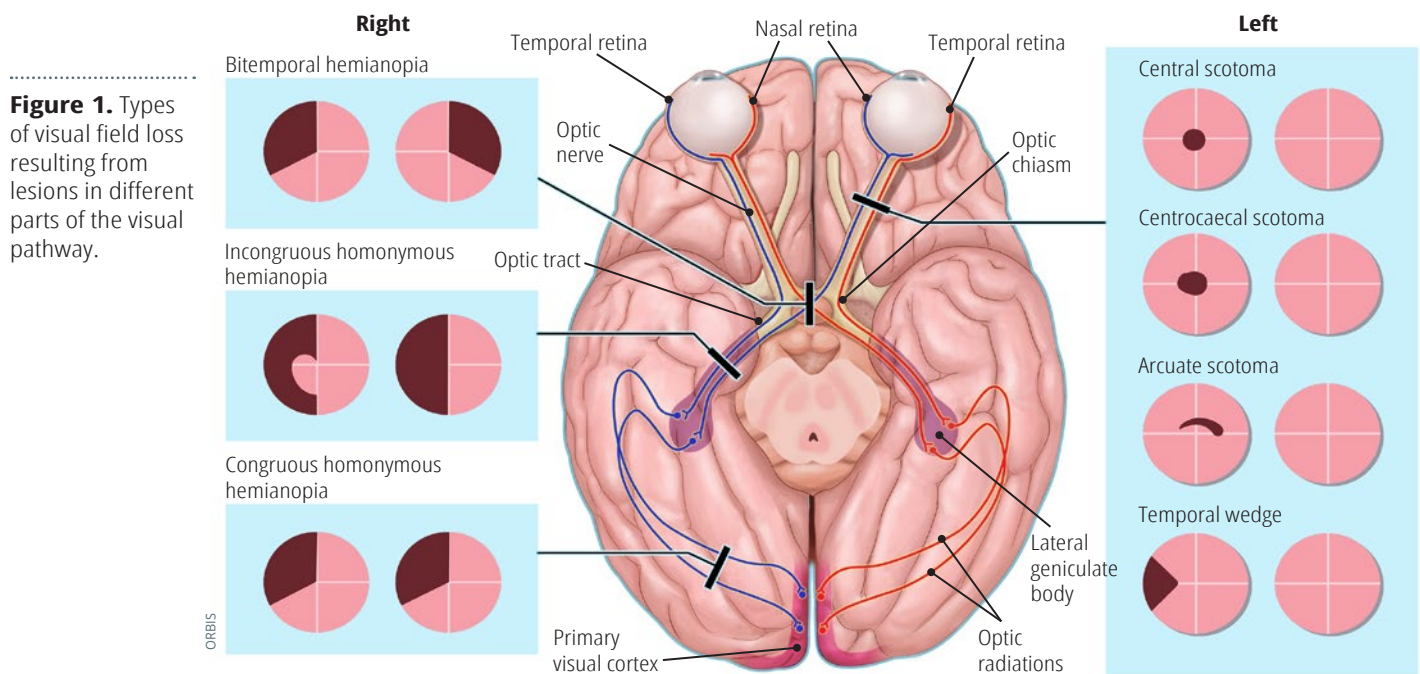


Figure 1. Types of visual field loss resulting from lesions in different parts of the visual pathway.

- **Optic tract, optic radiation and occipital lobe** lesions result in loss of vision in the opposite hemifield which patients experience as loss of vision on the right or left.

Higher visual centres

Visual information goes from the visual cortex to the 'visual association areas' where what we see is interpreted. For example, visual information which goes from the occipital lobe to the temporal lobe enables faces and objects to be recognised, while visual information which goes from the occipital lobe to the parietal lobe allows objects to be localised in space.

Neurological conditions which affect eye movement

(See Figure 1 on page 64)

Diplopia (double vision) is the commonest symptom and results from misalignment of the visual axes in the eyes.

- Disorders causing diplopia may arise due to lesions affecting any part of the 3rd, 4th and 6th cranial nerves, or due to diseases affecting the extra-ocular muscles, e.g. myasthenia gravis or dysthyroid eye disease.
- Diplopia is experienced as either images lying side by side (horizontal diplopia) from involvement of the medial and lateral rectus muscles, or images

lying one above the other (vertical diplopia) from involvement of the eye elevators.

- Separation of images is greatest in the direction of the action of the weak muscles and the false image created by the affected eye is usually the outermost image.

Associated neurological symptoms

- Facial numbness (especially over the forehead), occurring in conjunction with diplopia from 3rd, 4th or 6th cranial nerve lesions, suggests disease at the cavernous sinus or orbit.
- Impaired vision on the same side of 3rd, 4th and 6th cranial nerve lesions suggests an orbital apex lesion.
- Weakness of the lower half of the face, arm and leg unilaterally (hemiparesis) occurring with 3rd or 6th nerve palsy (diplopia) suggest a lesion of the brainstem.
- Dysphagia (difficulty swallowing), dysarthria (slurred speech) with fluctuating double vision and eyelid drooping (ptosis) is suggestive of myasthenia gravis; a disorder of the neuromuscular junction.
- Patients with thyroid eye disease may have diplopia, proptosis, lid retraction (staring gaze) and an enlarged thyroid gland from Grave's disease.

Subscriptions

Readers in low- and middle-income countries receive the journal free of charge. Send your name, occupation, and postal address to the address opposite. French, Spanish, and Chinese editions are available. To subscribe online, visit www.cehjournal.org/subscribe

Address for subscriptions

Anita Shah, International Centre for Eye Health, London School of Hygiene and Tropical Medicine, Keppel Street, London WC1E 7HT, UK.

Tel +44 (0)207 958 8336

Email admin@cehjournal.org

Correspondence articles

We accept submissions of 800 words about readers' experiences. Contact Anita Shah: correspondence@cehjournal.org

Published by the International Centre for Eye Health, London School of Hygiene & Tropical Medicine.

Unless otherwise stated, authors share copyright for articles with the Community Eye Health Journal. Illustrators and photographers retain copyright for images published in the journal.

Unless otherwise stated, journal content is licensed under a Creative Commons Attribution-NonCommercial (CC BY-NC) license which permits unrestricted use, distribution, and reproduction in any medium for non-commercial purposes, provided that the copyright holders are acknowledged.

ISSN 0953-6833

Disclaimer

Signed articles are the responsibility of the named authors alone and do not necessarily reflect the views of the London School of Hygiene & Tropical Medicine (the School). Although every effort is made to ensure accuracy, the School does not warrant that the information contained in this publication is complete and correct and shall not be liable for any damages incurred as a result of its use.

The mention of specific companies or of certain manufacturers' products does not imply that they are endorsed or recommended by the School in preference to others of a similar nature that are not mentioned. The School does not endorse or recommend products or services for which you may view advertisements in this Journal.

The *Community Eye Health Journal* is sponsored by:

