

## Case Report

# Tick anaphylaxis triggered by pulling out the tick

Noriya Takayama  and Yusaku Takagaki 

Susami Municipal Hospital, Wakayama, Japan

**Background:** Reports of tick anaphylaxis are extremely rare in Asian countries, with poor awareness in these regions. Herein, we report a case of tick anaphylaxis that was triggered by pulling out the tick.

**Case Presentation:** A 66-year-old man developed pruritus in his left toes after returning from a mountain. Three days later, he found a swollen tick biting at the skin between the second and third toes and pulled it out. Approximately 30 min after pulling out the tick, he started to feel a burning sensation in his chest and was brought to our hospital. He was diagnosed with anaphylactic shock (systolic blood pressure, 60 mmHg) and immediately received intramuscular adrenaline.

**Conclusion:** To our knowledge, this is the first case of tick anaphylaxis triggered by tick removal in an Asian country. A tick should be removed without pressure on its body, especially in patients with tick or bee allergy.

**Key words:** Anaphylaxis, bee, Japan, tick bite, tick

## INTRODUCTION

**T**ICK SPECIES ARE widely distributed worldwide, especially in warm places, and feed on their hosts, including humans, by biting and lodging in the host skin for days to weeks; the ticks show swelling to 5–10-times their original size (Fig. 1). Although tick-borne diseases, such as Rickettsial infections, are very important from a medical perspective, knowledge that a tick bite could induce allergic reactions, occasionally leading to anaphylaxis, is also important. Cases of tick anaphylaxis have been reported in Australia, the USA, and some European countries.<sup>1–4</sup> Importantly, in many cases, tick anaphylaxis was not induced by the tick bite but by removal of the tick from the skin, suggesting that squeezing the tick could result in injection of allergen-containing saliva. Therefore, the Australasian Society of Clinical Immunology and Allergy (ASCI) recommends appropriate tick removal. However, reports on tick anaphylaxis are extremely rare in Asian countries. Herein, we present the first case of tick anaphylaxis triggered by tick removal in an Asian country.

**Corresponding:** Noriya Takayama, MD, Susami Municipal Hospital, 2380 Susami, Nishimuro, Wakayama, 649-2621, Japan. E-mail: noriya.takkan@gmail.com.

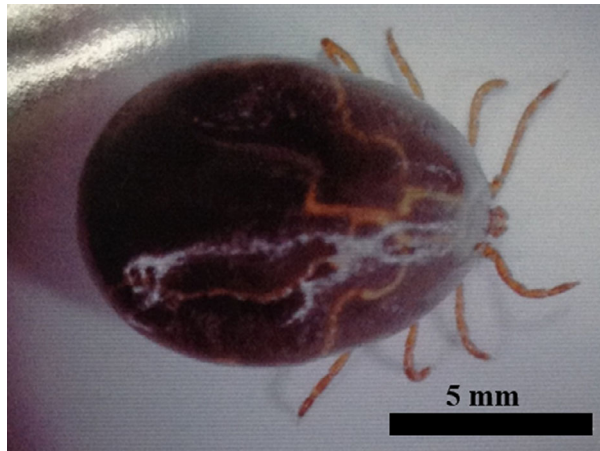Received 9 Nov, 2019; accepted 29 Feb, 2020

### Funding Information

No funding information provided.

## CASE REPORT

**T**HE PATIENT WAS a 66-year-old man with no comorbidities living in Susami, located in the southern part of Wakayama prefecture in Japan. His occupation was bee-keeping, and he had a history of bee anaphylaxis, for which an epinephrine auto-injector had been prescribed. Initially, he developed pruritus in his left toes after returning from a mountain. Three days later, he found a swollen tick lodging in the skin between the second and third toes. He pinched the tick and pulled it out as he had experienced many tick bites and had done the same thing. Approximately 30 min later, he started to feel a burning sensation in his chest and was brought to our hospital. He was in shock (systolic blood pressure, 60 mmHg; heart rate, 55 b.p.m.; SpO<sub>2</sub>, 91%) on arrival. A tick bite scar was observed on the skin between the second and third toes. The scar caused by the tick bite measured approximately 1 mm in diameter, was covered by a crust, and local erythema was observed around the scar. Laboratory data were normal except for slightly elevated levels of Cr (1.5 mg/dL). Based on his episode and physical examination findings, we diagnosed anaphylactic shock due to tick bite. Intramuscular adrenaline was given, followed by i.v. methyl prednisolone. He immediately recovered from shock and was admitted to our hospital for observation; he was discharged the next day without relapse of anaphylaxis. The time course of the case is shown in Figure 2. We could not obtain evidence of tick venom-specific immunoglobulin E (IgE) as tick extract was not available for allergen testing.



**Fig. 1.** A swollen tick after feeding on host blood. This tick (*Haemaphysalis*) was removed from another patient who attended our hospital.

The total serum IgE level increased to 504 IU/mL. However, the allergen-specific IgE screening test showed negative results, except for positive results for honey bee and yellow jacket antigens.

## DISCUSSION

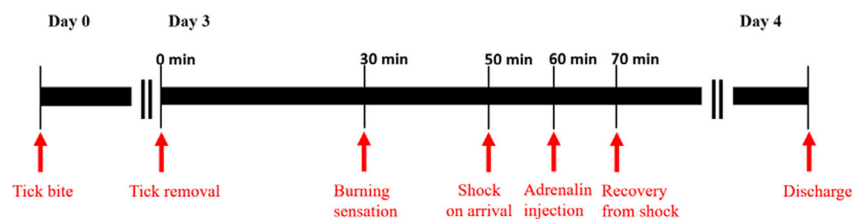
**T**O OUR KNOWLEDGE, this report is the first to describe anaphylaxis triggered by tick removal in an Asian country. Furthermore, in this case, tick anaphylaxis had not been induced when the tick was biting but was triggered when the tick was removed from the skin.

In the PubMed database, the first case of tick anaphylaxis was reported in Australia in the 1960s,<sup>1</sup> followed by some reports in the USA and Europe.<sup>2-4</sup> Compared to other countries, an overwhelming number of cases have been reported in Australia.<sup>5</sup> The overwhelming number of tick anaphylaxis cases in Australia is attributed to the suitable climate and environment for ticks and to the fact that many people live or work in tick-infested areas. In contrast, there are no English reports on tick anaphylaxis in Asian countries, including Japan, in the PubMed database. This case occurred in Susami, a rural area, which has a

high incidence of “Japanese spotted fever,” a tick-borne disease, in the summer; the incidence of this disease has been increasing in the past decades. This suggests that experiencing tick bites in this area is quite common, which led to the extremely rare occurrence of tick anaphylaxis in Japan.

Importantly, it has been reported that tick anaphylaxis often occurs when the tick is removed from the skin.<sup>6</sup> Unlike bee or yellow jacket stings, tick bites result in shallow and small wounds. Therefore, only a small amount of allergen-containing saliva is injected, leading to a weak allergic reaction. Although ticks penetrate the skin and continue to feed for at least several days, the small amount of allergen injected inside the human body is only sufficient for causing a local reaction around the bite and not enough for inducing anaphylaxis. However, when the tick is pinched during removal, a large amount of saliva enters the human body through the hypostome. This indicates that some amount of allergen might be injected into the skin on squeezing the tick body (squeezing is required because pulling out its head is difficult), which could precipitate the allergic reaction. This is a unique feature of tick anaphylaxis, whose onset is completely different from that of other insect-related anaphylaxis, such as bee anaphylaxis. It is possible to induce tick anaphylaxis by inappropriate tick removal. Therefore, we need to not only be aware of the possibility of tick anaphylaxis but also the appropriate method of tick removal. Ticks should not be removed forcibly or touched, which could cause further injection of allergen-containing saliva into the skin. For preventing tick-borne infections, forceps or local skin resection could be used for tick removal to ensure complete removal of the tick head from the skin. However, a recent study reported that killing ticks in situ before careful removal could reduce anaphylactic reactions.<sup>7</sup> Australia is the leading country to provide information related to tick bites, and the ASCIA recommends freezing and killing the tick with ether-containing spray (cold spray) and waiting for the tick to drop off.

Tick bites could induce anaphylaxis in susceptible patients with a history of tick bites.<sup>2,8,9</sup> Actually, more than half of the patients with tick anaphylaxis have a history of tick allergy, and some of the involved allergens have been identified in tick saliva. Furthermore, some patients with tick



**Fig. 2.** Time course of tick anaphylaxis in this case.

anaphylaxis have a history of bee anaphylaxis. An in vitro study suggested cross-reactivity between the antigens in tick saliva and bee venom.<sup>10</sup> Although our patient had no evident history of tick allergy, his history of tick bites and his allergy to bee venom could be risk factors for tick anaphylaxis.

## CONCLUSION

**WE ENCOUNTERED THE** first case of tick anaphylaxis triggered by tick removal in an Asian country. This case alerts clinicians, especially emergency physicians, that tick anaphylaxis can be triggered when the tick is pulled out of the skin. We recommend that tick removal should be carried out carefully without pressure on its body, especially in high-risk patients with a history of allergic reactions to ticks or bees.

## DISCLOSURE

Approval of the research protocol: N/A.

Informed consent: Obtained from the patient.

Registry and registration no. of the study/trial: N/A.

Animal studies: N/A.

Conflict of interest: None.

## REFERENCES

- Banfield JF. Tick bites in man. *Med. J. Aust.* 1966; 2: 600–1.
- Van Wye JE, Hsu YP, Terr AI, Moss RB, Lane RS. Anaphylaxis from a tick bite. *N. Engl. J. Med.* 1991; 324: 777–8.
- Van Wye JE, Hsu YP, Lane RS, Terr AI, Moss RB. IgE antibodies in tick bite-induced anaphylaxis. *J. Allergy. Clin. Immunol.* 1991; 88: 968–70.
- Fernandez-Soto P, Davila I, Laffond E, Lorente F, Encinas-Grandes A, Perez-Sanchez R. Tick-bite-induced anaphylaxis in Spain. *Ann. Trop. Med. Parasitol.* 2001; 95: 97–103.
- Rappo TB, Cottee AM, Ratchford AM, Burns BJ. Tick bite anaphylaxis: incidence and management in an Australian emergency department. *Emerg. Med. Australas.* 2013; 25: 297–301.
- McGain F, Welton R, Solley GO, Winkel KD. First fatalities from tick bite anaphylaxis. *J. Allergy Clin. Immunol. Pract.* 2016; 4: 769–70.
- Taylor BWP, Ratchford A, van Nunen S, Burns B. Tick killing in situ before removal to prevent allergic and anaphylactic reactions in humans: a cross-sectional study. *Asia Pac. Allergy* 2019; 9: e15.
- Schlosser R, Meissner M, Kaufmann R, Valesky EM. Recurrent anaphylaxis due to pigeon tick bites. *J. Dtsch. Dermatol. Ges.* 2019; 17: 195–6.
- Kleine-Tebbe J, Heinatz A, Graser I *et al.* Bites of the European pigeon tick (*Argas reflexus*): risk of IgE-mediated sensitizations and anaphylactic reactions. *J. Allergy Clin. Immunol.* 2006; 117: 190–5.
- Sanchez M, Venturini M, Blasco A, Lobera T, Bartolome B, Oteo JA. Tick bite anaphylaxis in a patient allergic to bee venom. *J. Investig. Allergol. Clin. Immunol.* 2014; 24: 284–5.