



Contents lists available at ScienceDirect

International Journal of Surgery Case Reports

journal homepage: www.casereports.com

Successful treatment for patients with chronic orchialgia following inguinal hernia repair by means of meshoma removal, orchiectomy and triple-neurectomy

Masato Narita^{a,*}, Koki Moriyoshi^b, Keita Hanada^a, Ryo Matsusue^a, Hiroaki Hata^a, Takashi Yamaguchi^a, Tetsushi Otani^a, Iwao Ikai^a

^a Department of Surgery, National Hospital Organization, Kyoto Medical Center, 1-1 Mukaihata-cho, Fukakusa, Fushimi-ku, Kyoto 612-8555, Japan

^b Department of Pathology, National Hospital Organization, Kyoto Medical Center, 1-1 Mukaihata-cho, Fukakusa, Fushimi-ku, Kyoto 612-8555, Japan

ARTICLE INFO

Article history:

Received 17 August 2015

Received in revised form

29 September 2015

Accepted 30 September 2015

Available online 19 October 2015

Keywords:

Testicular pain

Neuropathic pain

Nociceptive pain

Testicular atrophy

Genital branch of genitofemoral nerve

Ilioinguinal nerve

ABSTRACT

INTRODUCTION: Orchialgia following inguinal hernia repair is rare complication and still challenging since there has been no established surgical treatment because of complexity of nerve innervation to the testicular area. Herein we report a case of postoperative orchialgia following Lichtenstein repair, which was successfully treated by mesh removal, orchiectomy and triple neurectomy.

CASE PRESENTATION: A 65-year-old man was referred to our department because of chronic right orchialgia following Lichtenstein hernia repair. He walked with a limp and was unable to walk a long distance. Physical examination revealed the presence of meshoma in the groin area and hypoesthesia in the anterior skin of the right scrotum. His right testis was completely atrophic and located not in the scrotum but in the subcutaneous regions of right groin. He was diagnosed as both neuropathic and nociceptive orchialgia and underwent meshoma removal, triple-neurectomy, and orchiectomy to address these issues. Pathological examination revealed that meshoma was integrated with the structures of the spermatic cord, leading to foreign-body reaction and fibrosis around the genital branch of genitofemoral nerve. The resected right testis was completely-scarred without ischemic changes. Orchialgia disappeared immediately after operation and he was able to walk without a limp.

DISCUSSIONS: It is important to distinguish between nociceptive and neuropathic orchialgia. Neuroanatomic understanding is essential to guide treatment options. Orchiectomy is an option but should be reserved for refractory cases with evidence of nociceptive pain accompanied by anatomical changes.

CONCLUSIONS: Triple neurectomy should be considered in patients with neuropathic orchialgia.

© 2015 The Authors. Published by Elsevier Ltd. on behalf of Surgical Associates Ltd. This is an open access article under the CC BY-NC-ND license (<http://creativecommons.org/licenses/by-nc-nd/4.0/>).

1. Introduction

Orchialgia following inguinal hernia repair is a rare complication. However, once it occurs, it can worsen the patient's condition, leading to exercise restriction and depression. Most patients with postoperative orchialgia improve only by conservative or supportive pain management; however, in some patients, orchialgia becomes refractory to conservative treatment, and surgical intervention is necessary [1]. Although it is difficult to understand the surgical anatomy of inguinal hernias, once surgical exploration is performed, surgical repair is simple [2]. Surgical treatment of postoperative orchialgia still remains challenging because there is no established surgical treatment due to the complexity of the innervation of the testicular area [3].

Here, we report a case of postoperative orchialgia following a Lichtenstein repair, which was successfully treated by mesh removal, orchiectomy, and triple neurectomy.

2. Case presentation

A 65-year-old man was referred to our department because of chronic right orchialgia. The patient had undergone a right inguinal hernia repair by Marcy's method 4 years ago and underwent a second surgery due to relapsed inguinal hernia by the Lichtenstein method 3 years ago. He developed right orchialgia immediately after the second surgery but left it untreated. He visited our hospital 3 years after the second surgery to receive treatment for chronic orchialgia after undertaking a questionnaire survey of patients undergoing inguinal hernia repair at our department. He walked with a limp because of the pain in the right testis and was unable to walk long distances. Physical examination revealed a non-tender induration located just beneath the surgical wound in the right

* Corresponding author.

E-mail address: narinari@kuhp.kyoto-u.ac.jp (M. Narita).

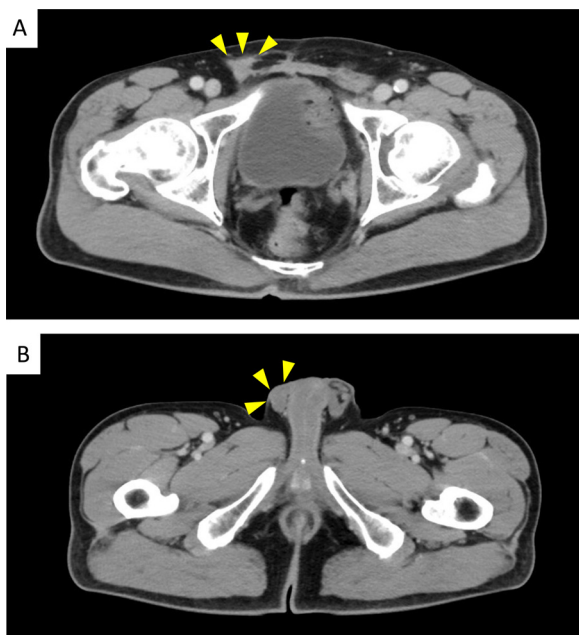


Fig. 1. Preoperative computed tomography.

(A) Arrowheads indicate focal increase in density of the subcutaneous fat with stranding along with the right spermatic cord.

(B) Arrowheads indicate that the right testis located in the subcutaneous region of the right groin.

inguinal region. He had hyperesthesia in the anterior skin of the right scrotum. His right testis was not located in the scrotum but was superficially located in the subcutaneous region of the right groin. It was considerably atrophic, and orchialgia was augmented by compression of the testis. Clinical urological examination indicated that the right testicular function was completely diminished and that there was no evidence of urological diseases, such as ischemic orchitis and epididymitis, which could lead to orchialgia. Contrast-enhanced computed tomography showed focal increase in the density of the subcutaneous fat with stranding along the right spermatic cord (Fig. 1A) corresponding to the location of the induration. The right testis was located in the subcutaneous region of the right groin (Fig. 1B). Collectively, these findings suggested that there might be the following two different phenomena involved in the occurrence of the chronic orchialgia: (1) the presence of meshoma and (2) testicular atrophy. To address these issues, we planned to perform a third surgery, including meshoma removal, triple-neurectomy, and orchiectomy.

During the surgery, an oblique incision was made just above the previous surgical wound. The external oblique aponeurosis was opened to reveal the inguinal canal. Dense fibrosis and scar formation were observed around the spermatic cord at the external inguinal ring, and the spermatic cord was circumferentially enveloped by a wrinkled mesh. Three nerves were identified (Fig. 2A), and each nerve was encircled with vessel tape. The entire length of both the iliohypogastric and ilioinguinal nerves was resected as far proximally and as far distally as possible. Each transected nerve end was ligated to close the neurilemmal sheath and to prevent neuroma formation. The spermatic cord and the right testis were dissected from the surrounding tissue as far as the inferior epigastric vessels (Fig. 2B) and were then ligated and divided. The genital branch of the genitofemoral nerve was concurrently resected with the spermatic cord. The nerve end was ligated with an absorbable thread. Posterior repair was performed using the Prolene Hernia System®.

Regarding the gross appearance of the resected specimens, the wrinkled mesh was integrated with the structures of the spermatic

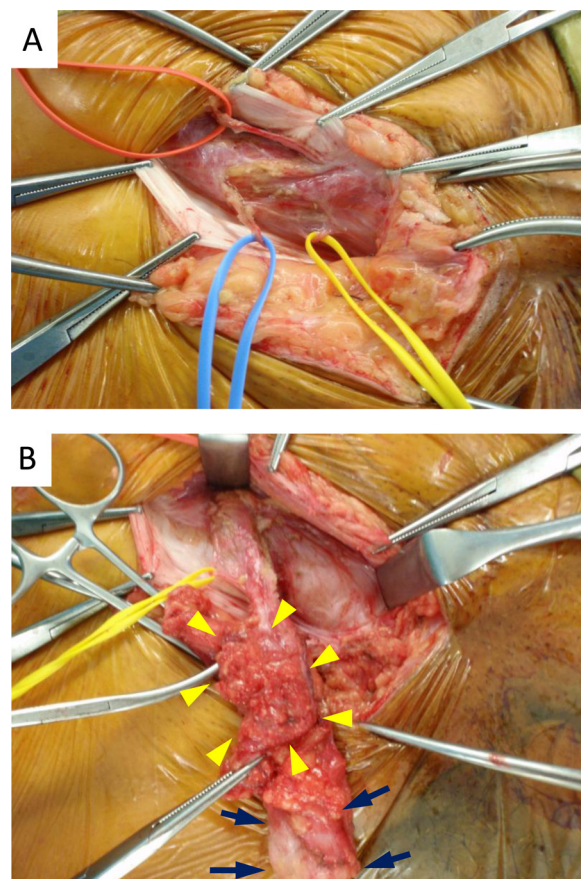


Fig. 2. Intraoperative photography.

(A) Each nerve is encircled by vessel tape. Blue, ilioinguinal nerve; red, iliohypogastric nerve; yellow, the genital branch of genitofemoral nerve

(B) Yellow arrowheads indicate meshoma circumferentially enveloping the spermatic cord with scar formation. Blue arrows indicate the right testis. It is completely atrophic and located at the subcutaneous tissue in the groin area.

cord (Fig. 3A). Pathological examination revealed fibrotic proliferation of the epineurium, and a foreign-body reaction and fibrosis was observed around the genital branch of the genitofemoral nerve; however, endoneural damage was not evident within this nerve (Fig. 3B). Perineural inflammation was present around both the iliohypogastric (Fig. 3C) and ilioinguinal nerves (Fig. 3D), but it was relatively mild. The resected right testis was completely scarred. There was no fibrotic reaction and inflammation around the paravasal nerves running along the vas deferens (Fig. 3E and F).

Orchialgia disappeared immediately after the surgery, and the patient was able to walk without a limp. Numbness of the right thigh was present for 6 months after surgery; however, it completely resolved 10 months after surgery.

3. Discussion

Post-inguinal hernia repair orchialgia can be due to various conditions, such as ischemic orchitis, epididymitis, edema, infection, cord fibrosis and scarring, varicocele or hydrocele formation, torsion, referred pain from radiculitis or ureteral pathology, and entrapment or disruption of the genital branch of the genitofemoral and ilioinguinal nerves, paravasal nerve fibers, or autonomic plexus within the cord [4]. Orchialgia is divided into neuropathic and nociceptive pain. Most patients with orchialgia have nociceptive pain, which is caused by intraoperative testicular tissue injury, including ischemia, edema, and infection. These patients can be rendered pain free by means of orchiectomy. However, for some

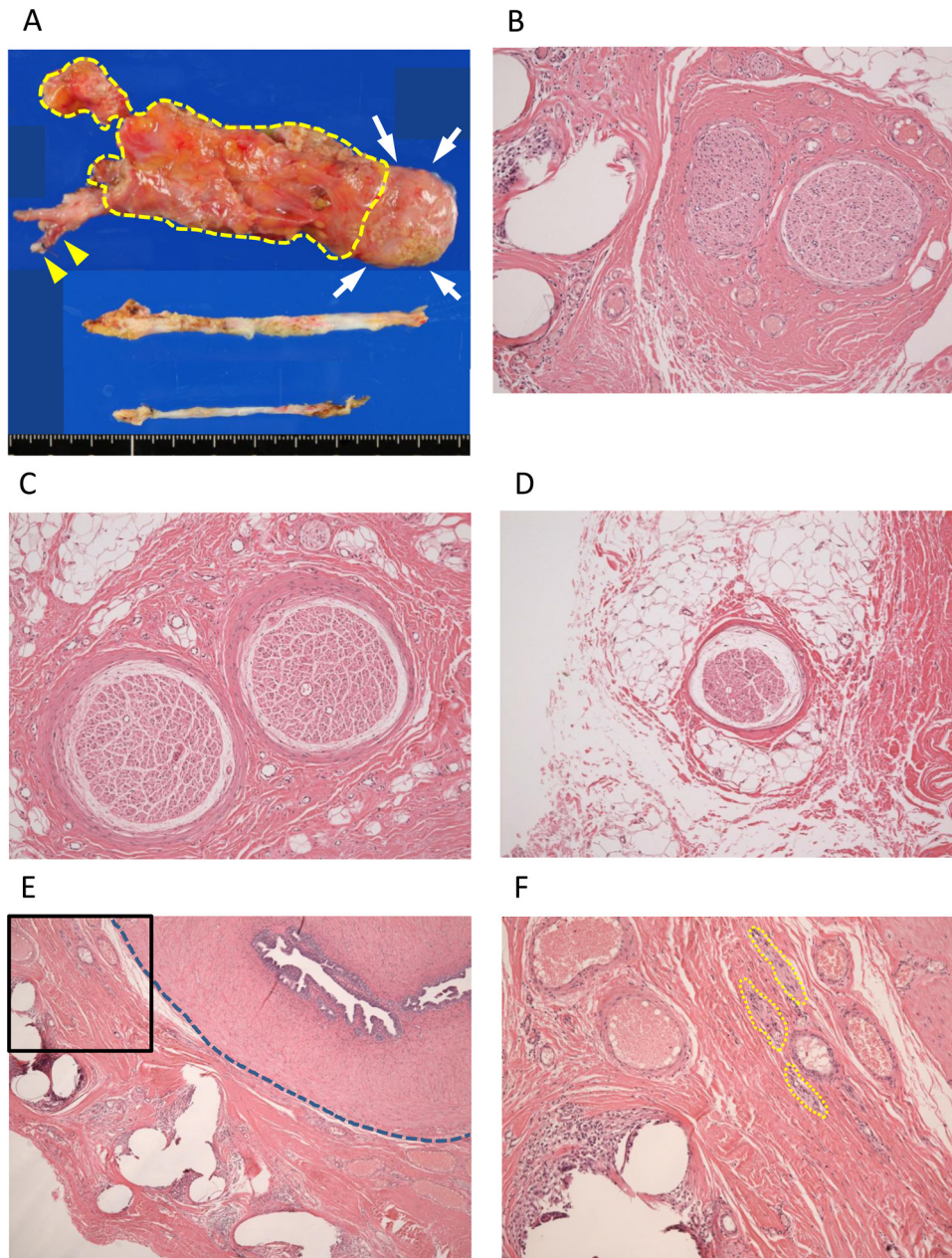


Fig. 3. The macro- and microscopic appearances of surgical specimens.

(A) The macroscopic appearances of surgical specimens. Upper, the right spermatic cord and testis. The area enclosed by dotted line indicates meshoma that is completely integrated with the spermatic cord. Yellow arrowheads indicate the genital branch of genitofemoral nerve. White arrows indicate atrophic testis. Middle, iliohypogastric nerve; lower, ilioinguinal nerve.

(B) Microscopic appearance of the genital branch of genitofemoral nerve (magnification; $\times 100$). Fibrosis of the epineurium and foreign-body reaction around this nerve is observed, while endoneural damage is not evident within it.

(C) Microscopic appearance of iliohypogastric nerve (magnification; $\times 100$).

(D) Microscopic appearance of ilioinguinal nerve (magnification; $\times 100$).

(E) Microscopic appearance of the spermatic cord (magnification; $\times 40$). The area enclosed by dotted line indicates the vas deference. The area enclosed by solid line is represented as magnified photograph in Fig. 3 Figure 3F.

(F) Microscopic appearance of the spermatic cord (magnification; $\times 100$), indicating magnification of the area enclosed by the solid line in Figure 3E. The areas enclosed by dotted line indicate nerve bundles of the paravasal nerve fibers. There was no fibrotic reaction and inflammation around these nerves.

patients, orchietomy is not effective. From the database of the Finnish Patient Insurance Center, Ronka et al. analyzed all the urological complications related to inguinal hernia repair. In that study, 17 of the 34 patients with chronic orchialgia caused by an ischemic or atrophic testis underwent orchietomy; however, 24% of these patients continued to have severe orchialgia after orchietomy [5]. These findings suggest that in some cases, orchietomy alone may not be sufficient to address orchialgia. The differences

between nociceptive and neuropathic orchialgia need to be understood because their treatment differs significantly. If the pain is neuropathic in nature, it is characterized by symptoms of burning, hyper- or hypoesthesia, and radiation of the pain to the skin of the corresponding scrotum. These symptoms are frequently triggered or aggravated by walking, stooping, or hyperextension of the hip and can be decreased by recumbency and flexion of the thigh [6]. Orchialgia elicited by compression of the testis is typically a noci-

ceptive sensation that is dull and aching. It may be accompanied by anatomical changes, such as testicular enlargement or atrophy [7]. In our case, the patient had hyperesthesia of the anterior skin of the right scrotum, testicular atrophy, and orchialgia evoked by compression of the testis. These findings suggest that both neuropathic and nociceptive orchialgia might occur due to the following two different phenomena: (1) The meshoma might have caused chronic inflammation and orchialgia because of entrapment of some sensory nerves, particularly the genital branch of the genitofemoral nerve. (2) The right testis was placed in an inappropriate position at the end of the second surgery, and it might have become atrophic from gradual compression by subcutaneous tissue, resulting in nociceptive orchialgia. Indeed, pathological examination revealed the entrapment of the genital branch of the genitofemoral nerve by the wrinkled mesh and the presence of testicular atrophy. There was fibrotic proliferation of the epineurium and foreign-body reaction and fibrosis around the genital branch of the genitofemoral nerve; however, endoneurial damage was not evident within this nerve. These findings indicated that neurapraxia (one of the nerve injuries in which the axons and myelin sheath remain intact [6]) developed in the genital branch of the genitofemoral nerve, leading to neuropathic orchialgia.

What is the adequate treatment for patients with neuropathic orchialgia? The testicular area has complicated innervation and adequate understanding of the innervation is necessary in order to address this issue. Nociceptive sensation is mediated by afferent autonomic nerve fibers on the testicular arteries, traversing the celiac plexus and the thoracic parts of the sympathetic chain to enter the T10–12 segments of the spinal cord [8]. The genital branch of the genitofemoral and ilioinguinal nerves provide sensory innervation for the anterior scrotal wall [4]. Although the iliohypogastric nerve does not directly provide sensory innervation for the scrotum per se, “triple neurectomy” is the primary surgical treatment of neuropathic orchialgia as selective neurectomy has limited efficacy because of the crisscross innervation of the scrotum by the three nerves.[3,6,7,9] On the other hand, there are some patients with neuropathic orchialgia who are not adequately addressed by triple neurectomy [9]. The testes have no somatic innervation and receive sensory fibers from paravasal nerves located just along the vas deferens (Fig. 3E), originating from the deep pelvic plexus [4]. Neuropathy of these nerve fibers is also involved in post-hernia repair orchialgia [3,7,9]. Patients with orchialgia who undergo preperitoneal repair may be at a risk of injury to the paravasal nerve fibers due to direct contact with the mesh [3]. In our case, the patient had previously undergone a Lichtenstein repair and pathological examination revealed no evidence of neuropathy of the paravasal nerve fibers.

Numbness in the distribution of the neurectomy is a predictable postoperative complication; however, its frequency and long-term outcome are not fully understood. Starling et al. reported that numbness occurred in some cases after neurectomy but not in all cases [10]. Madura et al. reported that only 2% of patients ($n = 2$) who underwent neurectomy complained of postoperative numbness [11]. On the other hand, a recent study from the Lichtenstein-Amid Hernia Clinic reported that all of their patients ($n = 20$) who underwent laparoscopic triple neurectomy had postoperative numbness [12]. However, these studies neither clarified how long the numbness persisted nor evaluated if the numbness was cured or not. In the present case study, our patient was followed as an outpatient for 2 years following surgery. On physical examination at 6 months after surgery, the patient had numbness only in the area surrounding the wound, which completely disappeared 10 months after surgery. From then onwards, physical examination revealed completely normal pain and temperature sensations in the distribution of the neurectomy without asymmetry. Although the exact mechanism for the resolution of the numbness is unclear, periph-

eral sensory nerves are known to be restored even in patients receiving autologous breast reconstruction, and this sensory reinnervation develops within the first 7 months [13]. Therefore, it can be assumed that sensory reinnervation also develops in the distribution of the neurectomy because triple neurectomy is thought to be equivalent to an iatrogenic peripheral nerve injury, and not a central nerve injury.

4. Conclusions

The management of orchialgia remains challenging. In the present case, aggressive surgical intervention was effective; however, large-scale studies are needed to investigate this further. It is important to distinguish between nociceptive and neuropathic orchialgia. Neuroanatomical understanding is essential to guide treatment options. Orchiectomy is an option; however, it should be reserved for refractory cases with evidence of nociceptive pain accompanied by anatomical changes. Triple neurectomy should be considered in patients with neuropathic orchialgia.

Conflict of interest

Authors have no conflict of interest to declare.

Funding

Authors have no sources of funding to declare.

Ethical approval

No ethical approval needed for this manuscript.

Author contribution

- 1) Study conception and design; Narita, and Ikai.
- 2) Drafting manuscript or critical revision of the manuscript; Narita, Ikai, Moriyoshi, Matsusue, Hata, Yamaguchi, and Otani.
- 3) Final approval of the manuscript; Narita, Moriyoshi, Matsusue, Hata, Yamaguchi, Otani, and Ikai.

Consent

Written informed consent was obtained from the patient for publication of this Case report and any accompanying images. A copy of the written consent is available for review by the Editor of this journal.

References

- [1] I. Ducic, A.L. Dellon, Testicular pain after inguinal hernia repair: an approach to resection of the genital branch of genitofemoral nerve, *J. Am. Coll. Surg.* 198 (2) (2004) 181–184.
- [2] R. Kassir, J. Dubois, S.A. Berremila, S. Baccot, A. Boueil-Bourlier, O. Tiffet, A rare variant of inguinal hernia: cryptorchid testis at the age of 50 years. Etiopathogenicity, prognosis and management, *Int. J. Surg. Case Rep.* 5 (7) (2014) 416–418.
- [3] P.K. Amid, D.C. Chen, Surgical treatment of chronic groin and testicular pain after laparoscopic and open preperitoneal inguinal hernia repair, *J. Am. Coll. Surg.* 213 (4) (2011) 531–536.
- [4] P. Kumar, V. Mehta, V.H. Nargund, Clinical management of chronic testicular pain, *Urol. Int.* 84 (2) (2010) 125–131.
- [5] K. Ronka, J. Vironen, H. Kokki, T. Liukkonen, H. Paajanen, Role of orchiectomy in severe testicular pain after inguinal hernia surgery: audit of the Finnish Patient Insurance Centre, *Hernia* 19 (1) (2015) 53–59.
- [6] P.K. Amid, A 1-stage surgical treatment for postherniorrhaphy neuropathic pain: triple neurectomy and proximal end implantation without mobilization of the cord, *Arch Surg.* 137 (1) (2002) 100–104.
- [7] D.C. Chen, P.K. Amid, Persistent orchialgia after inguinal hernia repair: diagnosis, neuroanatomy, and surgical management, *Hernia* 19 (1) (2015) 61–63, <http://dx.doi.org/10.1007/s10029-013-1150-3>, Invited comment to:

- role of orchiectomy in severe testicular pain and inguinal hernia surgery: audit of Finnish patient insurance centre. Ronka K, Vironen J, Kokki H, Liukkonen T, Paajanen H.
- [8] P. Mirilas, A. Mentessidou, J.E. Skandalakis, Secondary internal inguinal ring and associated surgical planes: surgical anatomy, embryology, applications, *J. Am. Coll. Surg.* 206 (3) (2008) 561–570.
- [9] P.K. Amid, J.R. Hiatt, New understanding of the causes and surgical treatment of postherniorrhaphy inguinodynia and orchalgia, *J. Am. Coll. Surg.* 205 (2) (2007) 381–385.
- [10] J.R. Starling, B.A. Harms, Diagnosis and treatment of genitofemoral and ilioinguinal neuralgia, *World J. Surg.* 13 (5) (1989) 586–591.
- [11] J.A. Madura, J.A. Madura 2nd., C.M. Copper, R.M. Worth, Inguinal neurectomy for inguinal nerve entrapment: an experience with 100 patients, *Am. J. Surg.* 189 (3) (2005) 283–287.
- [12] D.C. Chen, J.R. Hiatt, P.K. Amid, Operative management of refractory neuropathic inguinodynia by a laparoscopic retroperitoneal approach, *JAMA Surg.* 148 (10) (2013) 962–967.
- [13] N. Sinis, A. Lamia, H. Gudrun, T. Schoeller, F. Werdin, Sensory reinnervation of free flaps in reconstruction of the breast and the upper and lower extremities, *Neural Regener. Res.* 7 (29) (2012) 2279–2285.

Open Access

This article is published Open Access at scimedirect.com. It is distributed under the [IJSCR Supplemental terms and conditions](#), which permits unrestricted non commercial use, distribution, and reproduction in any medium, provided the original authors and source are credited.