

Malposition of Central Venous Catheter: Presentation and Management

Lin Wang, Zhang-Suo Liu, Chang-An Wang

Department of Nephropathy, The First Affiliated Hospital, Zhengzhou University, Zhengzhou, Henan 450052, China

Key words: Central Venous Catheter; Complications; Malposition

INTRODUCTION

Central venous catheters (CVCs) are commonly utilized to gain vascular access for varied clinical indications. These include administering drugs, renal replacement therapy, total parenteral nutrition, poor peripheral venous access, cardiac catheterization, and transvenous cardiac pacing.^[1] Central venous access involves a large bore catheter inserted in internal jugular, subclavian or femoral vein in the neck, and upper chest or groin (femoral) area.^[1] The preferred vein for CVCs is the right internal jugular vein (IJV) for its straight course to the right heart and the lowest risk of the venous stenosis and thrombosis.^[2-4] Successful catheter placement requires not only technical expertise but also awareness of the potential complications.^[5] Malposition of the catheter is a relatively common complication (5.01%), which results in the malfunction of catheters.^[6,7] Misplacement of the superior vena cava (SVC) can lead to the perforation of the cava or the right atrium, which are associated with serious sequelae.^[4,5] Multiple literatures are in the form of isolated case reports or small series, which are cumbersome or time-consuming to access and do not provide pragmatic guidance or solutions to the problem. This article outlines the normal and abnormal anatomy of the central veins in relation to CVCs, mainly for the IJV, similar advantages applying at all sites. In addition, it presents illustrated cases of the malposition and discusses practical management issues, avoiding the misplacement and following complications.

ANATOMY OF CENTRAL VEINS

CVCs are usually inserted in the internal jugular, subclavian or femoral veins, and are typically for short-term or long-term access.^[8] Selection of the insertion site should be based both on the ease of placement and on the risks associated with

the procedure. The branches and tributaries of SVC system are shown in Figure 1a and 1b.^[6] Physicians often prefer cannulation of the right IJV, the second best for the left IJV, to establish central venous access since it provides a more direct path to SVC.^[6] SVC lies in close anatomical proximity to the mediastinal pleura in the upper thorax.^[6,9] Perforation of the vein wall with a guidewire, dilator, or catheter may cause uncontrolled bleeding into the low-pressure pleural space. The left brachiocephalic vein receives lymph from the thoracic duct [Figure 2]. If the guidewire goes into the orifice of the duct, the catheter is advanced through the wire directly into the thoracic duct.^[6,10] A persistent left-sided SVC (PLSVC), including duplicate SVC, may occur in up to 2.1% of the general population.^[6,11] The left SVC usually drains into the right atrium via the coronary sinus.^[12,13]

CATHETER MALPOSITION

It is currently recommended that the tip of CVC is positioned at the level of mid-lower SVC to cavoatrial junction.^[14] Malposition of a CVC means a catheter lies outside of SVC, whose tip does not lie in the 'ideal' position. Misplaced catheters have been reported in almost every possible anatomical position, which can be of two types such as intra-cava malposition and extra-cava malposition on the base of the location of the catheter.^[6] The latter includes various structures such as mediastinum, pleura, pericardium,

Address for correspondence: Prof. Zhang-Suo Liu, Department of Nephropathy, The First Affiliated Hospital, Zhengzhou University, Zhengzhou, Henan 450052, China
E-Mail: zhangsuoliu@sina.com

This is an open access article distributed under the terms of the Creative Commons Attribution-NonCommercial-ShareAlike 3.0 License, which allows others to remix, tweak, and build upon the work non-commercially, as long as the author is credited and the new creations are licensed under the identical terms.

For reprints contact: reprints@medknow.com

© 2016 Chinese Medical Journal | Produced by Wolters Kluwer - Medknow

Received: 07-09-2015 **Edited by:** Yuan-Yuan Ji
How to cite this article: Wang L, Liu ZS, Wang CA. Malposition of Central Venous Catheter: Presentation and Management. Chin Med J 2016;129:227-34.

Access this article online

Quick Response Code:



Website:
www.cmj.org

DOI:
10.4103/0366-6999.173525

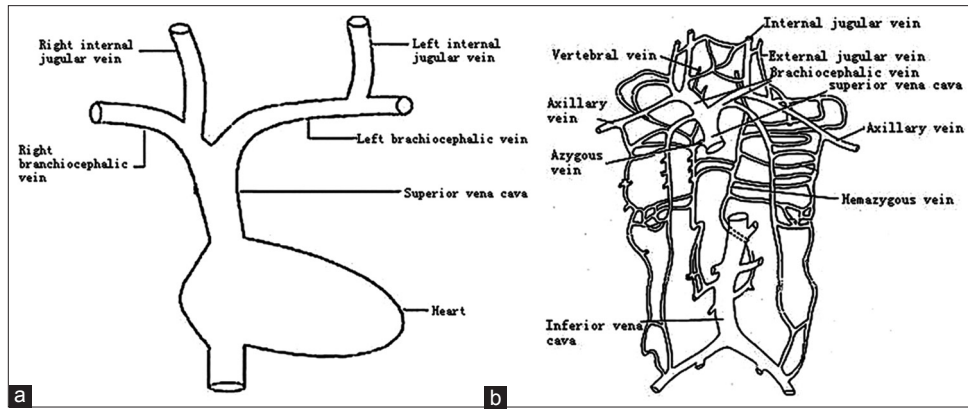


Figure 1: (a) The trunk of the superior vena cava system. It shows that left internal jugular vein negotiates two 90° turns. (b) Tributaries of the superior vena cava system. It shows that the superior vena cava drains venous blood from the upper half of the body in which there would be variable and complicated considerably.

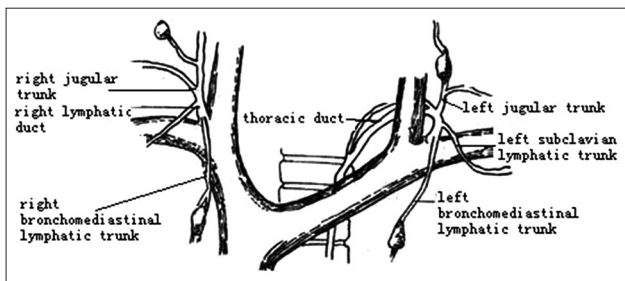


Figure 2: A anatomic illustration of the jugular lymphatic trunk. It indicates that the thoracic duct is medial close to the internal jugular vein in front of the internal jugular vein.

trachea, esophagus, subarachnoid space, and other aberrant sites. Catheter malposition is usually associated with serious consequences while some of them remain unrecognized resulting in incorrect diagnosis and delayed treatment. Recent methodological advances, increased availability of imaging, guidewire manipulation, and experience in the management of complications have a huge impact on morbidity and mortality in this area. We collected different case reports, discussed the clinical presentation and management of some of the more common sites for catheter misplacements in patients [Tables 1 and 2]. Some rare computed tomography (CT) or chest radiography images later in the text are presented to guide how to deal with different misplacements.

MECHANISMS OF MALPOSITION

Methodological inaccuracy, anatomical variation, and inter-operator variability are predisposed to catheter misplacement.^[15,16] Factors such as branches of the vein, vein tortuosity, acute angulations of vessels, congenital anatomical variation, and vein stenosis may result in misplacement.^[9] For example, the azygos vein would act as the bypass collateral to the right atrium during the insertion under the condition that SVC obstruction lies below the azygos vein.^[17,18] On the other side, the guidewire leads to an important role in steering the successful placement of the catheter.^[19,20] If the wire is unexpected to kink, entering into other vein inadvertently, the

catheter would tend to be misplaced or obstructed following the guidance, even to the other venous system, by following an abnormal path to neck, arm, thorax, or contralateral side.^[21] Furthermore, excessive force, which is used improperly as the guidewire run out of the veins, makes the catheter pass into the pleura, mediastinum, or other structures, which will bring out severe and fatal outcomes.^[22,23] Therefore, any resistance to passage should raise suspicion of a problem, and further imaging will be required. The following text illustrates clinically malpositioned cases with attached pictures for detailed descriptions and puts forward the corresponding managements as well.

Carotid artery

Artery cannulation during catheter insertion is one serious complication. It is believed that artery puncture is more common when placing CVC in jugular vein (14.28%) for veins run in close approximation to right carotid artery.^[24,25] When inadvertent puncture of the artery happens, the blood drawn from the lines is pulsatile, bright red, and high pressed. However, none of these is entirely reliable. Sometimes, the signs listed above are too ambiguous to give us accurate discrimination.^[24,26,27] A frontal chest radiograph shows the catheter tip projected to the left of the vertebral column [Figure 3a]. CT examination reveals the catheter position to be in the carotid artery [Figure 3b].^[9] Once a catheter is indwelled into the carotid artery, there will be continuous errhysis around the catheter port or hypotension occurs which results in hemorrhagic shock, while some asymptomatic.^[28] If the catheter is removed immediately, bleeding could not be stopped. Immediate removal of the misplaced catheter might not be the best choice. It is suggested to leave the misplaced catheter in artery until further intervention in consideration of complications and repair access. The routine use of ultrasound needle guidance should dramatically reduce the risk of these complications.^[28,29]

Azygos veins

Azygos veins system is quite variable in terms of anatomical course and drainage pattern. Sometimes, the accessory hemiazygos vein may drain either directly or after forming

Table 1: Analysis for the intra-cava misplacements during the catheterization

Sites	Cause	Chest X-ray	Consequence	Management
Carotid artery	Inaccuracy, penetration, anatomical variation	The catheter's tip projected to the left of the vertebral column	Asymptomatic, errhysis, hypotension, and hemorrhagic shock	Leave the catheter until further intervention
Azygos vein	Dilation of the azygos vein, high CVP, IVC, or SVC is blocked	Superior intercostal vein is to be cannulated with contrast filling the accessory hemiazygos vein	Catheter's dysfunction, pleural effusion, pulmonary edema, dyspnea, chest pain, back pain, and cardiac tamponade	Reposition under radiological guidance
Persistent left-sided SVC	Abnormal variation	The catheter is passing down the left side of the mediastinum	Dyspnea, chest pain, and cardiac tamponade	Surgical removal
Internal mammary vein	Blocked IVC or SVC	The catheter descends in the region of the mediastinum	Catheter's dysfunction, shoulder or arm pain	Remove the catheter under radiographic monitor
Vertebral vein	Excessive rotation of the patient's head	The catheter passes the transverse processes of the 6 th and the 7 th cervical vertebrae	Trapping catheter, thrombosis, endothelial damage, and fluid leakage	Remove the catheter moderately
Other veins	Narrowing IVC with split-tipped catheter, bent wire	One or both of lumens lose their routes to other veins	Catheter's dysfunction	Cautious removal, or using step-tipped catheter

SVC: Superior vena cava; IVC: Inferior vena cava; CVP: Central venous pressure.

Table 2: Analysis for the extra-cava misplacements during the catheterization

Sites	Cause	Chest X-ray	Consequence	Management
Extradural space	Too deep penetration	The line had penetrated the jugular vein and reached the spinal epidural space	Severe back pain	Penetrate in the lighter depth
Pericardium	Erosion of catheters through the lower SVC or right atrium	Much fluid is in the pericardium	Hemopericardium, fatal, ventricular fibrillation	Urgent pericardiocentesis, surgical repair
Pleural space	Inadvertent to azygos, hemiazygos, and internal thoracic veins	The catheter tip lies in the pleural cavity	Dyspnea, chest pain, and back pain	Removal referral to radiology
Mediastinum	Too deep penetration	Dilation of mediastinum	Chest pain	Removal referral to radiology
Thoracic duct	SVC is blocked	The catheter follows the course of the duct downward on a level with the cisterna chyli	Infusion mediastinum and chylothorax, clear yellow fluid is aspired	Subsequent surgical removal

SVC: Superior vena cava.

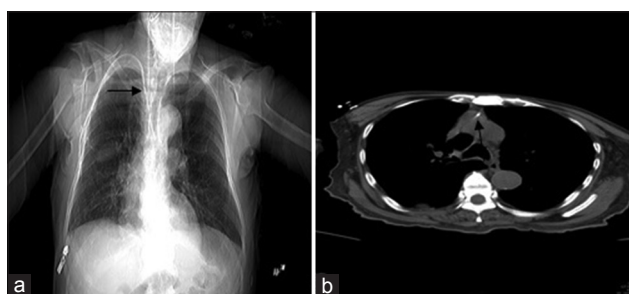


Figure 3: Catheter misplacement to intra-artery. (a) Chest film shows the tip of the catheter passing close to the aortic arch (arrow). (b) Further imaging indicates the tip of the catheter lying in the position of the arterial system (arrow).

a common trunk with the left superior intercostals vein into the left brachiocephalic vein.^[7] The frequency of accidental azygos vein cannulation during a central venous access through IJV is 0.7–1.2%.^[18] When misplacement to azygos veins, the insertion goes smoothly during the operation but afterward, blood cannot be aspirated from the catheter. It shows that the guidewire enters to azygos veins system

through the left IJV during catheterization [Figure 4]. Complications of the misplacement include pleural effusion, pulmonary edema, chest wall abscess, dyspnea, chest pain, back pain, and cardiac tamponade depending on the site of the catheter. The catheter will be pulled and repositioned under radiological guidance after confirmation.^[30] Contrast-enhanced CT, magnetic resonance imaging studies, and venography alone or in combination will provide definitive information about the location of the catheter.

Persistent left-sided superior vena cava

A PLSVC is due to an abnormal development of the sinus venosus in the early stages of fetal life, seen in 0.3–0.5% of the normal population.^[6] PLSVC is usually not recognized until a left superior approach to the heart is required as one anatomic finding.^[12] In fact, it complicates the placement of left-sided placement of central venous lines.^[31] Technical difficulties associated with PLSVC may lead to misplacement of the catheter and injury to the vessel wall. There is good flow in both arterial and venous lumens of

the dialysis catheter when indwelling in PLSVC. A routine postline insertion chest X-ray is performed [Figure 5a].^[32] The chest X-ray showed that the dialysis catheter is passing down the left side of the mediastinum rather than crossing the midline via the brachiocephalic vein to enter SVC on the right-side. The CT examinations show that the patient has a PLSVC, and the dialysis catheter tip is in the distal part of the left-sided SVC [Figure 5b and 5c].^[32] Misplacement to the vein will bring out serious complications such as pericardial and pleural effusion. Once the misplacement happens, the catheter needs to be removed by cardiothoracic surgeon.^[30]

Internal mammary vein

The internal mammary vein originates from the brachiocephalic vein. The mammary (internal thoracic) vein travels along the border to drain into the brachiocephalic vein. The insertion of the right mammary is often more proximal on the brachiocephalic vein on the left side than the right side.^[9] Because the right internal thoracic vein is often close to the origin, it can be by a catheter coming from either brachiocephalic vein.^[33] When inserting into the right internal mammary vein, no blood is aspirated from the line and the cannulation produce shoulder or arm pain with aspiration and flushing of the catheter.^[34] X-ray or CT examination to confirm the place of catheter indicates

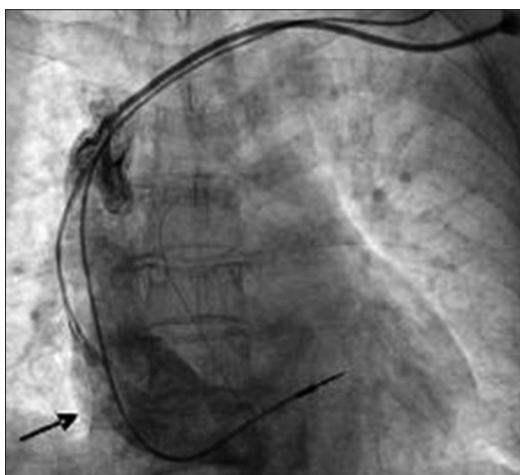


Figure 4: Chest film shows that the guide wire enters to azygos veins system through the left internal jugular vein during catheterization (arrow).

the catheter descends in the region of the mediastinum and places in the internal mammary vein [Figure 6a and 6b].^[33] The catheter should be removed under radiographic monitor with the moderate force.

Vertebral vein

The vertebral vein, posterior to the IJV, passes through the transverse foramina from the atlas to the 6th cervical vertebra.^[35] After exiting the transverse foramen of the 6th vertebra, the vein drains the brachiocephalic vein. The misplacement of a CVC into the vertebral vein is relatively rare, which might occur from excessive rotation of the patient's head, and from deep insertion of the puncture needle.^[36] Chest X-ray reveals that CVC is closely passing the right wall of the IJV and proceeding deep. Then, it passes the transverse processes of the 6th and the 7th cervical vertebrae, inserting the vertebral vein [Figure 7].^[37] In the case, nonpulsatile dark-colored blood flow is observed in the line, which is not different from the normal insertion, while the misinsertion increases the possibility of complications, including trapping of the catheter, thrombosis, endothelial damage, and leakage of infused fluid. Therefore, it is advised, for safe CVC insertion, to minimize a patient's head rotation and to make use of ultrasound when the anatomical structures cannot be clearly identified. Plain chest radiograph is also considered the proper method for confirming the location of the catheter tip.^[37,38]

Other veins

The misinsertion of the catheter into other veins cannot be easily distinguished from a successful CVC insertion, because it is a rare occurrence, and there is no difference in the color and pulsation of the regurgitated blood flow sometimes. A dual-lumen dialysis catheter with a split distal tip is inserted via the left IJV to the contralateral IJV with one or both of the lumens to the right side [Figure 8a and 8b]. Similar to the above finding, another case shows lumens' inadvertent insertion into the subclavian vein via the right IJV [Figure 9].^[39] As presented in previous reports, the tape of the catheter should be taken into account to avoid the lumen's bifurcation or offsetting during advancing catheter.^[40] The dual-lumen catheter is associated with a higher incidence of the divarication in comparison with the single-lumen

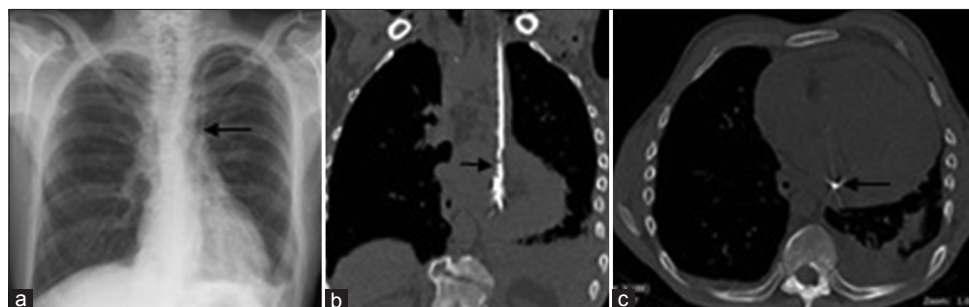


Figure 5: Catheter misplacement to the persistent left-sided SVC.^[32] (a) The chest X-ray demonstrates that dialysis catheter passes down the left side of the mediastinum with pleural effusion and subcutaneous emphysema over the left clavicle (arrow). (b) Computed tomography chest demonstrates the catheter in the persistent left-sided SVC, pericardial and pleural effusion from coronal view (arrow). (c) The arrow indicates the catheter in the persistent left-sided SVC from conventional view. SVC: Superior vena cava.

throughout the procedure. Cautious removal gives rise to no grave consequence usually. Roentgenography must be performed with or without contrast material to identify the position of the CVC.^[41]

Extradural space

Spinal epidural hematoma as a complication of CVC cannulation is very rare. It is reported that marked swelling around the right side of the patient's neck gradually worsened after the CVC via the right IJV uneventfully. Cervical CT demonstrated that the catheter tip of the central venous line had penetrated the jugular vein and reached the spinal epidural space [Figure 10a-10d].^[41] The catheter is carefully extracted immediately under fluoroscopy in operating room. While several minutes after the catheter removal, the patient complained of sudden severe back pain. Urgent imaging of the spine revealed a large spinal epidural hematoma extending compressing the dorsal spinal cord. The patient showed full recovery undergoing emergency surgical removal of the epidural hematoma. The possible reason is that the guidewire had penetrated the side wall of the IJV, and the following catheter is malpositioned to the extradural space. Any nearby structure is potentially at risk from needle puncture, guidewire, dilator, and catheter placement.^[42] It is generally safer to make a confirmation to the location of the catheter rather than a hasty removal with pressure applied to the access site.

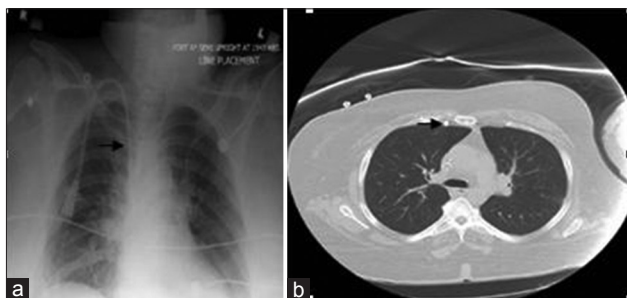

Figure 6: Catheter misplacement to the right internal mammary vein.^[33] (a) Chest X-ray: Anterior-posterior demonstrating what appears to be good position of catheter in the superior vena cava. (b) Computed tomography (axial image): Catheter malposition to the right of the sternum.

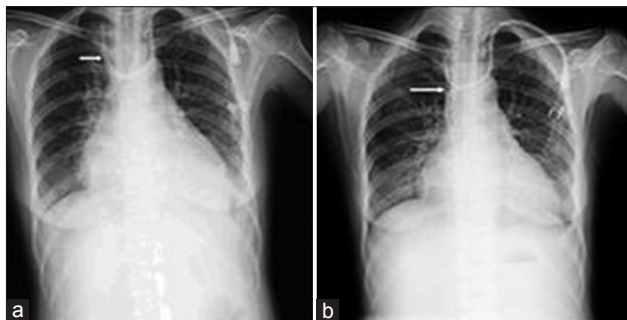


Figure 8: The misplacement of a left internal jugular vein catheter. (a) The chest film shows both of lumens' inadvertent insertion into the right internal jugular vein (arrow). (b) The chest film shows one of lumen dwelling into the right internal jugular vein (arrow).

Pericardium

The rare but often fatal complication of cardiac tamponade occurs in the context of a CVC when there is a perforation of the right atrium or lower SVC. This can occur after a period due to erosion by the catheter tip. Immediate postoperative chest radiograph shows that the tip of the catheter is seen to lie within the right atrium [Figure 11].^[6] Reported cases suggest that it is typically pressurized fluid infusion. If the tamponade is confirmed on echocardiography after clinical suspicion, timely treatment is indicated.^[15] Aspiration of the infused fluid should be attempted through the catheter, followed by urgent pericardiocentesis and stenting or surgical repair if required.

Pleural space

The right border of SVC, azygos, hemiazygos, and internal thoracic veins are immediately adjacent to the pleura. Damage to these or adjacent arteries can cause significant bleeding into the low-pressure pleural space. In

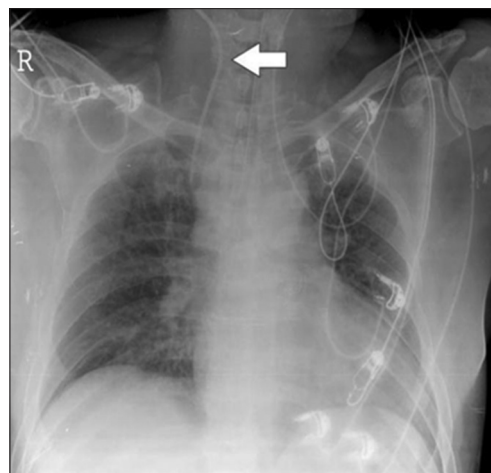

Figure 7: Catheter misplacement to the vertebral vein.^[37] Chest X-ray shows that the central venous catheter passes the transverse processes of the 6th and the 7th cervical vertebrae (arrow).

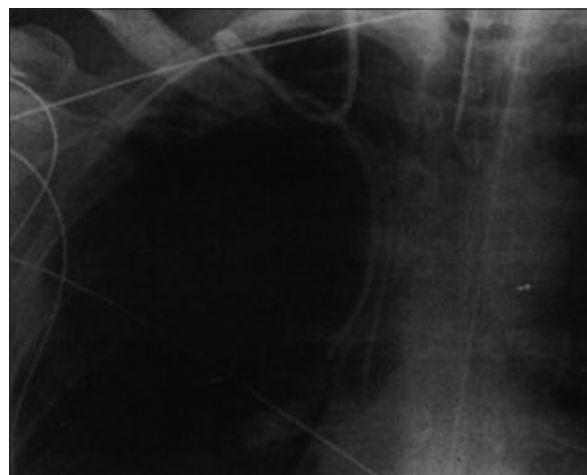


Figure 9: Catheter misplacement to the subclavian vein.^[39] Chest radiograph shows that the catheter is inserted via the right internal jugular vein and loops in the subclavian vein.

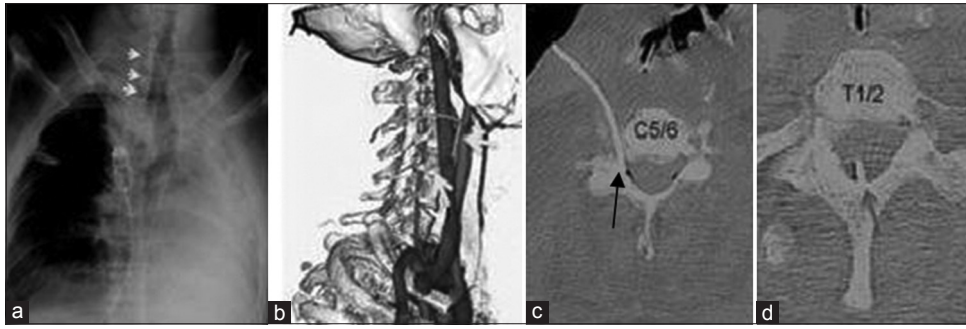


Figure 10: Catheter misplacement to the extradural space.^[41] Cervical computed tomography scans demonstrate that the central venous catheter has penetrated the posterior aspect of the internal jugular vein. (a) Chest radiograph reveals that the tip of the central venous line (arrows) runs inside the normal route of the internal jugular vein and appears to overlap with the cervical spine (arrows). (b) The cervical computed tomography scan demonstrates that the catheter travels posterior to the carotid artery (arrows). (c) The cervical computed tomography scan shows that the catheter penetrates the prevertebral fascia (arrow). (d) The image indicates that the catheter enters the intervertebral foramen (arrow).

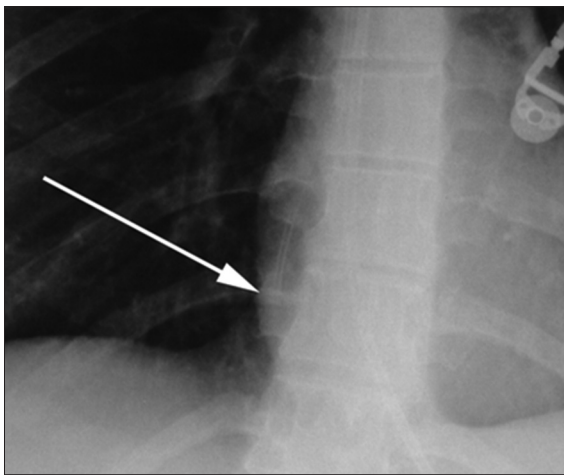


Figure 11: Catheter misplacement to the pericardium.^[6] Chest radiograph reveals that the tip of the catheter is seen to lie within the right atrium (arrow).

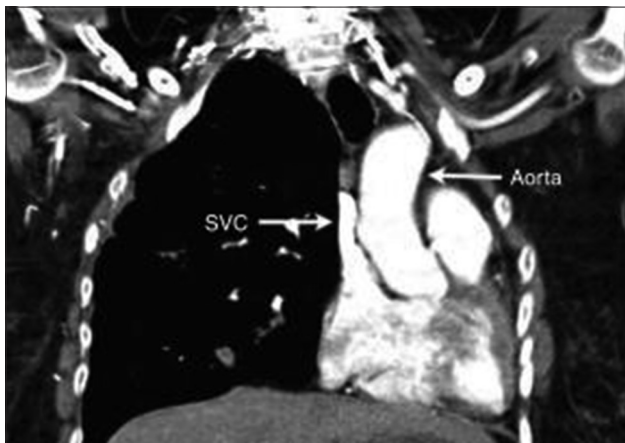


Figure 13: Catheter misplacement to the mediastinum.^[6] The computed tomography image shows the mediastinum grows for the huge hematoma. SVC: Superior vena cava.

Figure 12a and 12b,^[6] left-sided dialysis catheter has perforated through the right wall of SVC and entered the pleural space.^[6] If the catheter tip lies in the pleural cavity, hemothorax or pleural effusions may result from the infusion of blood or fluids through the catheter. It is

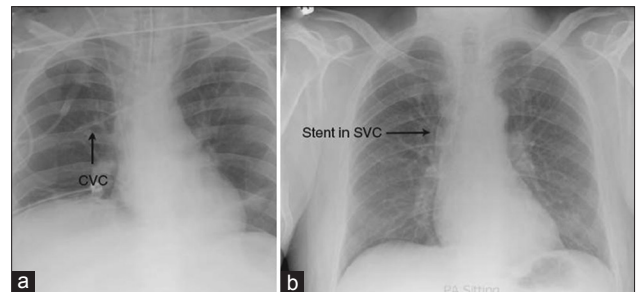


Figure 12: Catheter misplacement to the pleural space.^[6] (a) The left-sided dialysis catheter has perforated through the right wall of SVC, and the tip has entered the right pleural space (arrow). (b) The left-sided dialysis catheter has perforated through the right wall of SVC and kink in the right pleural space (arrow). CVC: Central venous catheter; SVC: Superior vena cava.

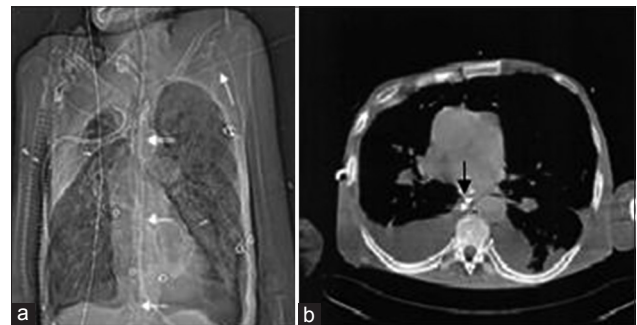


Figure 14: Catheter misplacement to the thoracic duct.^[44] (a) Scout view of the chest computed tomography shows the guidewire (arrows) takes a straight craniocaudal course projecting on the vertebral column reaching caudal to the diaphragm. (b) Computed tomography cross-sectional image at the level of the middle mediastinum. The guidewire (arrow) can be seen in a prevertebral position adjacent to the descending aorta and posterior to the esophagus.

dangerous to remove catheter for bleeding risk. The catheter should be removed referral to radiology.^[42]

Mediastinum

A CVC may perforate through a vessel wall entering the mediastinum. There is a particular risk if excessive force has been used to advance the guidewire, dilator, or catheter. It shows an example of a CVC passing into the mediastinum

as confirmed with contrast injection [Figure 13].^[6] Infusion of pressurized fluid through such an opening will lead to extravasation with a risk of swelling, compression of mediastinal or neck structures, or tissue necrosis.^[31] During next insertion after the catheter's extraction, it is as well under the real-time screening or other aids.^[43]

Thoracic duct

The thoracic duct drains into the distal portion of the left brachiocephalic vein. If the needle punctures the thoracic duct directly at the orifice of the duct into the left brachiocephalic vein, the guidewire is advanced through the needle directly into the thoracic duct and then followed the course of the duct downward on a level with the cisterna chili.^[43] If malposition of CVC in the thoracic duct is not recognized and CVC is used for infusion, the potential complication would be an infusion mediastinum [Figure 14a and 14b].^[44] In addition, laceration of the thoracic duct can also result in chronic chylothorax even after the removal of the central venous line. This laceration may require subsequent surgical removal.^[45-47]

In conclusion, there are multiple reasons for the procedural malposition of CVC, operators should make intensive analysis of catheter's location through much of anatomical acknowledgment. Correct diagnoses and timely managements, under the supervision of chest radiography or CT examination, can often prevent permanent or severe damage.

Acknowledgments

We would like to thank the authors of references 6,32,33,37,39,41,44 for the permission for using their published figures in the present study.

Financial support and sponsorship

This study was supported by grants from the National Key Technology Research and Development (R and D) Program of the Ministry of Science and Technology of China (No. 2013BAI09B04), and National Basic Research Program of China 973 Program (No. 2012CB517606).

Conflicts of interest

There are no conflicts of interest.

REFERENCES

1. Tan PL, Gibson M. Central venous catheters: The role of radiology. *Clin Radiol* 2006;61:13-22.
2. Trerotola SO, Kuhn-Fulton J, Johnson MS, Shah H, Ambrosius WT, Kneebone PH. Tunneled infusion catheters: Increased incidence of symptomatic venous thrombosis after subclavian versus internal jugular venous access. *Radiology* 2000;217:89-93.
3. Bourquelot P. Vascular access for haemodialysis. *Nephrol Ther* 2009;5:239-48. doi: 10.1016/j.nephro.2009.02.003.
4. Ruesch S, Walder B, Tramèr MR. Complications of central venous catheters: Internal jugular versus subclavian access – A systematic review. *Crit Care Med* 2002;30:454-60.
5. Shannon D. Central venous catheter-induced pericardial effusion in a neonate: A case study and recommendations for practice. *Neonatal Netw* 2014;33:341-8. doi: 10.1891/0730-0832.33.6.341.
6. Gibson F, Bodenham A. Mislplaced central venous catheters: Applied anatomy and practical management. *Br J Anaesth* 2013;110:333-46. doi: 10.1093/bja/aes497.

7. Ambesh SP, Pandey JC, Dubey PK. Internal jugular vein occlusion test for rapid diagnosis of misplaced subclavian vein catheter into the internal jugular vein. *Anesthesiology* 2001;95:1377-9.
8. Polderman KH, Girbes AJ. Central venous catheter use. Part 1: Mechanical complications. *Intensive Care Med* 2002;28:1-17.
9. Bannon MP, Heller SF, Rivera M. Anatomic considerations for central venous cannulation. *Risk Manag Healthc Policy* 2011;4:27-39. doi: 10.2147/RMHP.S10383.
10. Djamel Z. The trauma of the thoracic duct is a rare complication of jugular catheterization with fistula lymphatico-cutaneous. *Saudi J Kidney Dis Transpl* 2012;23:351-2.
11. Bader M, Bromley P, Jester I, Bennett J, Arul GS. Central venous catheters in the left-sided superior vena cava: Clinical implications. *J Pediatr Surg* 2013;48:400-3. doi: 10.1016/j.jpedsurg.2012.11.023.
12. Schummer W, Schummer C, Hoffmann E, Gerold M. Persistent left superior vena cava: Clinical implications for central venous cannulation. *Nutr Clin Pract* 2002;17:304-8.
13. Povoski SP, Khabiri H. Persistent left superior vena cava: Review of the literature, clinical implications, and relevance of alterations in thoracic central venous anatomy as pertaining to the general principles of central venous access device placement and venography in cancer patients. *World J Surg Oncol* 2011;9:173. doi: 10.1186/1477-7819-9-173.
14. Hsu JH, Wang CK, Chu KS, Cheng KI, Chuang HY, Jaw TS, *et al.* Comparison of radiographic landmarks and the echocardiographic SVC/RA junction in the positioning of long-term central venous catheters. *Acta Anaesthesiol Scand* 2006;50:731-5.
15. Bodenham A. Reducing major procedural complications from central venous catheterisation. *Anaesthesia* 2011;66:6-9. doi: 10.1111/j.1365-2044.2010.06583.x.
16. Cook TM. Litigation related to central venous access by anaesthetists: An analysis of claims against the NHS in England 1995-2009. *Anaesthesia* 2011;66:56-7. doi: 10.1111/j.1365-2044.2010.06569.x.
17. Harish K, Madhu YC. Inadvertent port: Catheter placement in azygos vein. *Int J Angiol* 2012;21:103-6. doi: 10.1055/s-0032-1315628.
18. Bankier AA, Mallek R, Wiesmayr MN, Fleischmann D, Kranz A, Kontrus M, *et al.* Azygos arch cannulation by central venous catheters: Radiographic detection of malposition and subsequent complications. *J Thorac Imaging* 1997;12:64-9.
19. Haygood TM, Brennan PC, Ryan J, Yamal JM, Liles L, O'Sullivan P, *et al.* Central venous line placement in the superior vena cava and the azygos vein: Differentiation on posteroanterior chest radiographs. *AJR Am J Roentgenol* 2011;196:783-7. doi: 10.2214/AJR.10.4681.
20. Nayeemuddin M, Pherwani AD, Asquith JR. Imaging and management of complications of central venous catheters. *Clin Radiol* 2013;68:529-44. doi: 10.1016/j.crad.2012.10.013.
21. Pikwer A, Bååth L, Davidson B, Perstoft I, Akesson J. The incidence and risk of central venous catheter malpositioning: A prospective cohort study in 1619 patients. *Anaesth Intensive Care* 2008;36:30-7.
22. Wu A, Helo N, Moon E, Tam M, Kapoor B, Wang W. Strategies for prevention of iatrogenic inferior vena cava filter entrapment and dislodgement during central venous catheter placement. *J Vasc Surg* 2014;59:255-9. doi: 10.1016/j.jvs.2013.07.116.
23. Gallieni M, Martina V, Rizzo MA, Gravello L, Mobilia F, Giordano A, *et al.* Central venous catheters: Legal issues. *J Vasc Access* 2011;12:273-9. doi: 10.5301/JVA.2011.7745.
24. Hodzic S, Golic D, Smajic J, Sijercic S, Umihanic S, Umihanic S. Complications related to insertion and use of central venous catheters (CVC). *Med Arch* 2014;68:300-3. doi: 10.5455/medarh.2014.68.300-303.
25. Powers CJ, Zomorodi AR, Britz GW, Enterline DS, Miller MJ, Smith TP. Endovascular management of inadvertent brachiocephalic arterial catheterization. *J Neurosurg* 2011;114:146-52. doi: 10.3171/2009.10.JNS09940.
26. Ho L, Spanger M, Hayward P, McNicol L, Weinberg L. Missed carotid artery cannulation: A line crossed and lessons learnt. *Anaesth Intensive Care* 2014;42:793-800.
27. Chirinos JC, Neyra JA, Patel J, Rodan AR. Hemodialysis catheter insertion: Is increased PO₂ a sign of arterial cannulation? A case report. *BMC Nephrol* 2014;15:127. doi: 10.1186/1471-2369-15-127.
28. Akkan K, Cindil E, Kilic K, Ilgit E, Onal B, Erbas G. Mislplaced central venous catheter in the vertebral artery: Endovascular treatment

- of foreseen hemorrhage during catheter withdrawal. *J Vasc Access* 2014;15:418-23. doi: 10.5301/jva.5000267.
29. Kaitzis DG, Balitas AG, Skandalos IK, Hatzibaloglou AK. Carotid artery repair after erroneous insertion of a hemodialysis catheter: Case report. *J Vasc Access* 2006;7:136-8.
 30. Varghese A, Pienaar W, Vandervelde C, Rankin S. RE: CT appearances of congenital and acquired abnormalities of the superior vena cava. *Clin Radiol* 2008;63:839-40. doi: 10.1016/j.crad.2008.01.013.
 31. Sheikh AS, Mazhar S. Persistent left superior vena cava with absent right superior vena cava: Review of the literature and clinical implications. *Echocardiography* 2014;31:674-9. doi: 10.1111/echo.12514.
 32. Balasubramanian S, Gupta S, Nicholls M, Laboi P. Rare complication of a dialysis catheter insertion. *Clin Kidney J* 2014;7:194-6. doi: 10.1093/ckj/sfu006.
 33. Stone PA, Hass SM, Knackstedt KS, Jagannath P. Malposition of a central venous catheter into the right internal mammary vein: Review of complications of catheter misplacement. *Vasc Endovascular Surg* 2012;46:187-9. doi: 10.1177/1538574411433288.
 34. Ghafoor H, Fatimi Sh, Ali M. Unusual malposition of dialysis catheter in the left internal mammary vein – A case report. *Middle East J Anaesthesiol* 2011;21:139-41.
 35. Gu X, Paulsen W, Tisnado J, He Y, Li Z, Nixon JV. Malposition of a central venous catheter in the right main pulmonary artery detected by transesophageal echocardiography. *J Am Soc Echocardiogr* 2009;22:1420.e5-7. doi: 10.1016/j.echo.2009.07.009.
 36. de Bucourt M, Braum L, Teichgräber U, Hamm B. Central venous catheter insertion via the vertebral vein and the sixth transverse foramen. *J Vasc Interv Radiol* 2011;22:577-8. doi: 10.1016/j.jvir.2010.11.008.
 37. Yang SH, Jung SM, Park SJ. Misinsertion of central venous catheter into the suspected vertebral vein: A case report. *J Vasc Access* 2014;15:418-23. doi: 10.4097/kjae.2014.67.5.342.
 38. Ide S, Kawamata T, Imai N, Ando A, Kawamata M. Misplacement of a guidewire into the vertebral vein through the internal jugular vein. *J Cardiothorac Vasc Anesth* 2012;26:e17-8. doi: 10.1053/j.jvca.2011.11.004.
 39. Bhatia P, Saied NN, Comunale ME. Management of an unusual complication during placement of a pulmonary artery catheter. *Anesth Analg* 2004;99:669-71.
 40. Lee HJ, Park SW, Chang IS, Jo YI, Park JH, Lee JH, *et al.* A comparison of standard dual-tip hemodialysis catheter split lumen hemodialysis catheter. *Clin Imaging* 2013;37:251-5. doi: 10.1016/j.clinimag.2012.06.001.
 41. Yokoyama K, Kawanishi M, Yamada M, Tanaka H, Ito Y, Kuroiwa T. Spinal epidural hematoma following removal of incorrectly placed jugular central venous catheter. *J Neurosurg Spine* 2011;15:206-9. doi: 10.3171/2011.3.SPINE10900.
 42. Thomopoulos T, Meyer J, Staszewicz W, Bagetakos I, Scheffler M, Lomessy A, *et al.* Routine chest X-ray is not mandatory after fluoroscopy-guided totally implantable venous access device insertion. *Ann Vasc Surg* 2014;28:345-50. doi: 10.1016/j.avsg.2013.08.003.
 43. Avila JO, Smith BC, Seaberg DC. Use of echocardiography to identify appropriate placement of a central venous catheter wire in the vena cava prior to cannulation. *Acad Emerg Med* 2014;21:E1-2. doi: 10.1111/acem.12430.
 44. Teichgraber UK, Nibbe L, Gebauer B, Wagner HJ. Inadvertent puncture of the thoracic duct during attempted central venous catheter placement. *Cardiovasc Intervent Radiol* 2003;26:569-71.
 45. Kawashima S, Itagaki T, Adachi Y, Ishii Y, Taniguchi M, Doi M, *et al.* Inadvertent thoracic duct puncture during right axially central venous cannulation. *Masui* 2010;59:1298-300.
 46. Hughes ME. Peripherally inserted central catheters – A ‘serious’ complication. *Br J Nurs* 2013;22:S4, S6-8.
 47. Jadhav AP, Stahlheber C, Hofmann H. Traumatic chyle leak: A rare complication of left internal jugular venous cannulation. *Am J Med Sci* 2011;341:238-9. doi: 10.1097/MAJ.0b013e3182070cf4.