



Case report

Acute retinal necrosis secondary to Varicella Zoster Virus

Archana Vasudevan^{a,*}, Christian Rojas-Moreno^{a,*}, Tushar Tarun^b^a Division of Infectious Diseases, Department of Medicine, University of Missouri, One Hospital Drive, Columbia, MO, 65212, United States^b Division of Cardiology, Department of Medicine, University of Missouri, One Hospital Drive, Columbia, MO, 65212, United States

ARTICLE INFO

Article history:

Received 3 June 2019

Received in revised form 26 June 2019

Accepted 26 June 2019

Keywords:

Retinal necrosis

Acute

Progressive

Varicella Zoster

ABSTRACT

A 54 year old female presented to the ophthalmology clinic with pain and decreased vision in her left eye. No past medical history other than primary varicella zoster infection, in her childhood. The eye exam revealed a macular region with scattered areas of retinal opacity along with patches of necrosis on the periphery. She was started on valganciclovir and referred to the infectious disease clinic. Cell Count, blood chemistry and HIV were negative. Serum was sent for polymerase chain reaction (PCR) for Varicella Zoster Virus (VZV), Herpes Simplex Virus (HSV) and Cytomegalovirus (CMV). The VZV PCR was positive. She had decreased vision on the right eye two days later, and exam revealed peripheral retinal whitening. She was admitted and started on intravenous acyclovir. VZV is one of the most common causes of ARN and has been described in both immunocompetent and immunocompromised persons.

Visual changes are usually noted weeks to months after the antecedent herpes zoster. Retinal involvement is bilateral in over half of cases, suggesting that VZV reaches the central nervous system hematogenously. The retinal exam reveals multifocal necrotizing lesions, often initially involving the peripheral retina. Therapy includes intravenous acyclovir with consideration of intravitreal foscarnet and other antivirals for progressing disease.

© 2019 Published by Elsevier Ltd. This is an open access article under the CC BY-NC-ND license (<http://creativecommons.org/licenses/by-nc-nd/4.0/>).

A 54-year-old Caucasian female with no significant comorbidities presented with one week history of left eye pain and irritation, hazy vision and headache. The patient had been previously seen by an ophthalmologist at the onset of her symptoms and was started on topical steroids for uveitis without any improvement. She did not have any other symptoms. She specifically denied previous ocular surgeries, trauma, visual changes in the right eye, oral ulcers, genital ulcers, diarrhea, rashes, weight loss, sick contacts, fevers, chills or fatigue. She lived on a Missouri farm with cows and horses but denied contact with birth products. She also owned a dog and a cat but denied any bites or scratches. There was no travel outside of the United States. She reported an unprotected sexual encounter in the recent past. Patient had varicella during her childhood and had “cold sores” in the past.

Visual acuity was 20/20 on the right and 20/60 on the left. The anterior segment of right eye was normal. The anterior segment of left eye showed moderate cells. The fundus examination of the right eye was normal, while fundus examination of left eye showed mild vitritis, a flat and pink disc and focal areas of deep retinal opacities in the macula, the peripheral retina was flat, attached

with scattered areas of retinal opacities more pronounced in the periphery and present posteriorly (Figs. 1 and 2). No vasculitis was noted. A fluorescein angiogram showed scattered fluorescein blockage with late staining and macular edema in the left eye (Fig. 3). Her physical exam was otherwise unremarkable. Laboratory findings showed normal blood cell counts and normal serum chemistries. Erythrocyte sedimentation rate was 11 mm/h. Human immunodeficiency virus (HIV) antibody/antigen testing was negative. Serum was evaluated for Herpes Simplex Virus (HSV), Varicella Zoster Virus (VZV) and Cytomegalovirus (CMV) by polymerase chain reaction (PCR). The serum VZV PCR was found to be positive while the others were negative. The VZV PCR quantitation was not done as it would not change the management. Additionally, testing for toxoplasmosis and syphilis were also negative. Aspiration of vitreous fluid was not done as serum VZV PCR was positive and ophthalmologic findings were consistent with acute retinal necrosis secondary to VZV.

Ophthalmology suspected viral retinal necrosis and started oral valganciclovir 900 mg twice a day. The patient experienced some initial improvement on valganciclovir, however, three weeks later, she presented to ophthalmology clinic with worsening vision in her left eye and new floaters and decreased vision of the right eye. Visual acuity was 20/40 on the right and 20/400 on the left. In addition to worsening retinitis in left eye, new areas of retinitis were noted in right eye as well. Patient was admitted for initiation

* Corresponding authors.

E-mail addresses: archana.vasudevan@yahoo.com (A. Vasudevan), rojasch@health.missouri.edu (C. Rojas-Moreno).

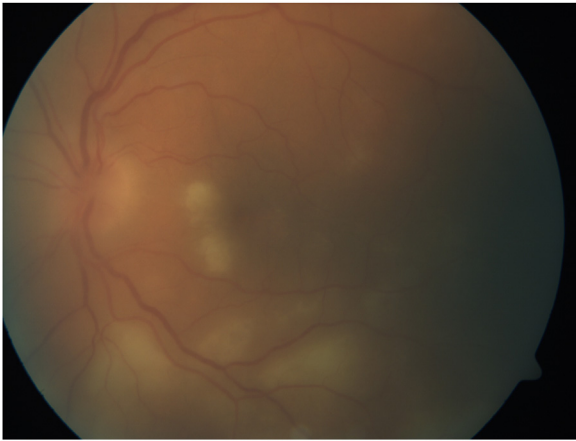


Fig. 1. Fundus exam of left eye showing the retinal opacities affecting the macula.

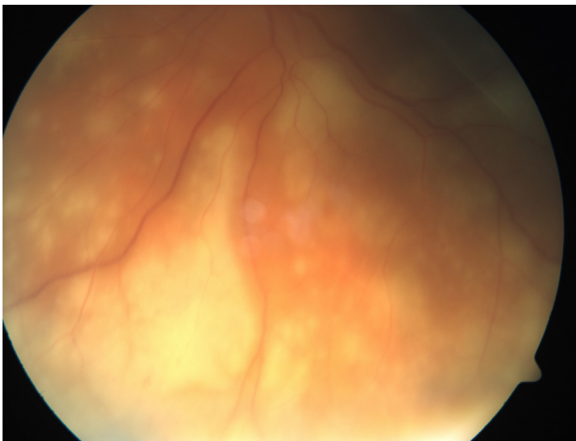


Fig. 2. Fundus exam of left eye showing the retinal opacities involving the periphery.

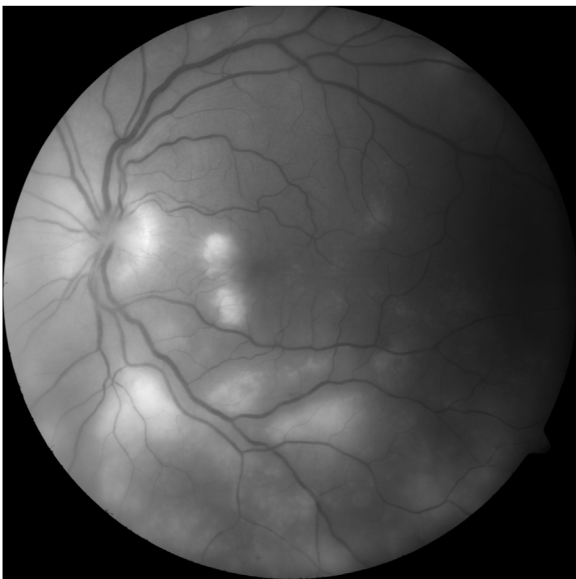


Fig. 3. Fluorescein angiogram of the left eye.

of intravenous acyclovir at 15 mg/kg every 8 h. Patient's vision in right eye stabilized and vision in the left eye started improving. She completed 2 weeks of intravenous acyclovir after which she was transitioned to long-term oral valacyclovir which she continued for

an additional three months. About 3 weeks after discharge from the hospital, patient developed worsening vision on the left eye. Visual acuity was 20/25 on the right and hand motion on the left. The fundus exam on the right showed near complete resolution of peripheral areas of necrosis. The fundus of left eye was hazy and she was found to have a retinal detachment for which she underwent vitrectomy and barrier endolaser. Follow up at six months demonstrated visual acuity with correction of 20/25 on the right eye and light perception/hand motion on the left. The fundus exam on the right showed healthy macula and no signs of retinal necrosis. The fundus exam on the left showed atrophic disc, intact macula with fibrosis across superior macula and atrophic peripheral retina.

Retinal necrosis or necrotizing retinopathy can be acute or progressive and usually happens as a sequel of herpetic viral infections [1]. These are two separate entities with the differences summarized in Table 1. Acute retinal necrosis (ARN) is seen in immunocompetent individuals, occurring after VZV and HSV infections. Cases of immunocompromised patients presenting with ARN secondary to CMV have also been reported. In ARN, there are multifocal necrotic areas with discrete borders spreading circumferentially and posteriorly from mid peripheral retina. ARN can present with pain due to iridocyclitis, vitritis, retinal vasculitis, in addition to retinal necrosis [2]. Patients initially present with unilateral involvement and up to 65% go on to have bilateral involvement [3]. Pathophysiology is mainly immune mediated and can cause vaso-occlusive disease involving retinal and choroidal vessels. Retinal detachment can occur in up to 75% of patients, within few weeks to few months. Diagnosis is based on criteria proposed by American Uveitis Society which includes chorioretinal vasculitis, retinal necrosis, anterior uveitis, and vitritis. This patient was immunocompetent, had childhood history of varicella, and had positive serum PCR for VZV. She had involvement of posterior retina and macula on presentation making it atypical for ARN. The patient's unusual presentation could be attributed to a secondary to a differential immune response. The presence of immune complexes containing viral antigens in the aqueous or serum, the presence of antigens on vitreous cells [4] and the retinal infiltration with lymphocytes and plasma cells suggest provocation of an inflammatory response by the presence of viral antigens. We hypothesize that antiviral agents used systemically and intra-vitreally reduce the viral antigens thereby decreasing the duration of active disease and subsequent retinal necrosis. Progressive outer retinal necrosis (PORN) is a rapidly progressive retinitis that involves the outer layers of the retina and occurs mainly in HIV patients with CD4⁺ T-cell counts <100/ μ L. Some case studies of VZV induced PORN has also been reported in organ transplant recipients. It is most often due to VZV, although CMV and HSV have been described. Review of literature published on PORN shows that VZV has been associated with PORN, usually with an active cutaneous presentation or a prior history of it [5]. VZV has been detected in aqueous vitreous by PCR and viral cultures [6].

Table 1
Differences between ARN and PORN.

Acute Retinal Necrosis	Progressive Outer Retinal Necrosis
Occurs in immunocompetent individuals	Occurs in Immunocompromised individuals
Incidence of painful eye during either presentation or course of disease	Decreased incidence of pain
Involves retina and usually spares macula	Usually involves retina including macula
Vaso-occlusive disease involving both arteries and veins	Vaso-occlusive disease absent

In contrast to ARN, PORN usually has less inflammation, multifocal onset in the posterior retina with faster progression and worse outcomes. Both presentations can be followed by retinal detachment. Pathophysiology of PORN is hypothesized to be due to varicella-zoster virus infection of the retina [7]. One possible hypothesis is that patient's immunosuppressed state allows the VZV destruction of the retina, to go unchallenged. PORN can present as a painless acute loss of vision, dizziness or visual field constriction [7]. It can present unilaterally at onset and subsequently can involve the contralateral eye [5]. Differential diagnosis include lymphoma with retinal involvement, other viral retinopathies like acute retinal necrosis, and CMV retinopathy. Diagnosis is based on clinical features, history of immunosuppression or prior VZV infection.

Early initiation of IV antivirals is essential to curb the destructive progression of retinal necrosis. Retinal detachment is a known complication noted in majority of the patients with retinal necrosis. While monotherapy with IV acyclovir alone has shown poor results, combination therapy with multiple antivirals including IV foscarnet and ganciclovir or acyclovir has shown better preservation of visual activity in patients [8].

The patient was treated with oral valganciclovir, valacyclovir and subsequently intravenous acyclovir despite which she developed retinal detachment. However, with early initiation of antivirals, vision was preserved in patient's right eye and progression of disease was halted in her left eye.

Authorship contributions

A. Vasudevan, C. Rojas, T. Tarun: Conception and design of study; acquisition of data; Analysis and/or interpretation of data;

Drafting the manuscript; Revising the manuscript critically for important intellectual content; Approval of the version of the manuscript to be published (the names of all authors must be listed).

Acknowledgements

We would like to thank our ophthalmology colleagues, of Dr. Dean Hainsworth and Dr. Erica Ballard, University of Missouri Department of Ophthalmology, Columbia, MO, for providing us with the images and with intellectual assistance.

References

- [1] Culbertson WW, Blumenkranz MS, Pepose JS, Stewart JA, Curtin VT. Varicella zoster virus is a cause of the acute retinal necrosis syndrome. *Ophthalmology* 1986;93(5):559–69.
- [2] Fisher JP, Lewis ML, Blumenkranz M, et al. The acute retinal necrosis syndrome. Part 1: clinical manifestations. *Ophthalmology* 1982;89(12):1309–16.
- [3] Culbertson WW, Clarkson JG, Blumenkranz M, Lewis ML. Acute retinal necrosis. *Am J Ophthalmol* 1983;96(5):683–5.
- [4] Margolis TP, Lowder CY, Holland GN, et al. Varicella-zoster virus retinitis in patients with the acquired immunodeficiency syndrome. *Am J Ophthalmol* 1991;112(2):119–31.
- [5] Engstrom Jr. RE, Holland GN, Margolis TP, et al. The progressive outer retinal necrosis syndrome. A variant of necrotizing herpetic retinopathy in patients with AIDS. *Ophthalmology* 1994;101(9):1488–502.
- [6] Tran TH, Rozenberg F, Cassoux N, Rao NA, LeHoang P, Bodaghi B. Polymerase chain reaction analysis of aqueous humour samples in necrotizing retinitis. *Br J Ophthalmol* 2003;87(1):79–83.
- [7] Mueller NH, Gilden DH, Cohrs RJ, Mahalingam R, Nagel MA. Varicella zoster virus infection: clinical features, molecular pathogenesis of disease, and latency. *Neurol Clin* 2008;26(3):675–97 viii.
- [8] Spaide RF, Martin DF, Teich SA, Katz A, Toth I. Successful treatment of progressive outer retinal necrosis syndrome. *Retina* 1996;16(6):479–87.