

## RESEARCH ARTICLE

# The interrelation between clinical presentation and neurophysiology of posthypoxic myoclonus

Jonathan C. van Zijl<sup>1</sup> , Martijn Beudel<sup>1</sup>, Bauke M. de Jong<sup>1</sup>, Joukje van der Naalt<sup>1</sup>, Rodi Zutt<sup>1</sup>, Fiete Lange<sup>1,2</sup>, Walter M. van den Bergh<sup>3</sup>, Jan-Willem J. Elting<sup>1,2</sup> & Marina A. J. Tijssen<sup>1</sup>

<sup>1</sup>Department of Neurology, University Medical Center Groningen (UMCG), University of Groningen, Hanzeplein 1, 9700 RB Groningen, Netherlands

<sup>2</sup>Department of Clinical Neurophysiology, University Medical Center Groningen (UMCG), University of Groningen, Hanzeplein 1, 9700 RB Groningen, Netherlands

<sup>3</sup>Department of Critical Care, University Medical Center Groningen (UMCG), University of Groningen, Hanzeplein 1, 9700 RB Groningen, Netherlands

## Correspondence

Marina A. J. Tijssen, Department of Neurology, UMCG, Mailbox: 30.001, Hanzeplein 1, 9700 RB Groningen, Netherlands.  
Tel: +31-50-3612175;  
Fax: +31-50-3611707;  
E-mail: m.a.j.de.koning-tijssen@umcg.nl

## Funding Information

Dr. van Zijl received the MD/PhD scholarship from the University of Groningen and Dr. Beudel received funding from the Dutch Brain Foundation for research purposes.

Received: 3 November 2017; Accepted: 20 November 2017

*Annals of Clinical and Translational Neurology* 2018; 5(4): 386–396

doi: 10.1002/acn3.514

## Abstract

**Objective:** Posthypoxic myoclonus (PHM) in the first few days after resuscitation can be divided clinically into generalized and focal (uni- and multifocal) subtypes. The former is associated with a subcortical origin and poor prognosis in patients with postanoxic encephalopathy (PAE), and the latter with a cortical origin and better prognosis. However, use of PHM as prognosticator in PAE is hampered by the modest objectivity in its clinical assessment. Therefore, we aimed to obtain the anatomical origin of PHM with use of neurophysiological investigations, and relate these to its clinical presentation. **Methods:** This study included 20 patients ( $56 \pm 18$  y/o, 68% M, 2 survived, 1 excluded) with EEG-EMG-video recording. Three neurologists classified PHM into generalized or focal PHM. Anatomical origin (cortical/subcortical) was assessed with basic and advanced neurophysiology (Jerk-Locked Back Averaging, coherence analysis). **Results:** Clinically assessed origin of PHM did not match the result obtained with neurophysiology: cortical PHM was more likely present in generalized than in focal PHM. In addition, some cases demonstrated co-occurrence of cortical and subcortical myoclonus. Patients that recovered from PAE had cortical myoclonus (1 generalized, 1 focal). **Interpretation:** Hypoxic damage to variable cortical and subcortical areas in the brain may lead to mixed and varying clinical manifestations of myoclonus that differ of those patients with myoclonus generally encountered in the outpatient clinic. The current clinical classification of PHM is not adequately refined to play a pivotal role in guiding treatment decisions to withdraw care. Our neurophysiological characterization of PHM provides specific parameters to be used in designing future comprehensive studies addressing the potential role of PHM as prognosticator in PAE.

## Introduction

Myoclonus in the first few days after hypoxic brain damage is in general considered to predict an unfavorable prognosis in patients who remain comatose after cardiopulmonary resuscitation (CPR).<sup>1–3</sup> The incidence of posthypoxic myoclonus (PHM) in resuscitated patients with postanoxic encephalopathy (PAE) is 19%, and only 9–14% of these patients recover with mild to no cognitive deficits.<sup>4–6</sup>

In terms of prognosis, there appears to be a distinction between focal PHM (unifocal and multifocal) and generalized PHM. The survival of comatose patients with generalized PHM admitted at an intensive care unit (ICU) is reported to be poor ( $\pm 3\%$ ) in comparison with focal PHM patients ( $\pm 17\%$ ).<sup>4,5</sup> Generalized PHM is associated with a subcortical origin. In this type of PHM the jerks are generalized and synchronous with predominant involvement of the proximal musculature.<sup>7–11</sup> In contrast, focal PHM is associated with a primary cortical origin. In

the latter, more subtle, asynchronous jerks occur predominantly in distal musculature.<sup>9–11</sup>

Despite recent improvements in the specificity of PAE prognostication, there is still a need for more sensitive prognostic parameters in PAE,<sup>12,13</sup> and the clinical subtype of PHM might serve as one. However, one of the challenges for the use of PHM as prognosticator is that the clinical distinction between focal and generalized PHM is complicated; the assessment is hampered by the dynamic and intermittent character of PHM, hypothermia and medication effects.<sup>13–16</sup> In contrast to the current American guideline for postanoxic coma, the presence of PHM is not included as a criterion for poor prognosis in the European guideline.<sup>17</sup> This guideline states that the various clinical and neurophysiological features of PHM need to be established before PHM can be reliably used for prognostication.<sup>17</sup> The rationale is that in order to prevent incorrect treatment decisions (false positives), it is important to obtain more quantitative measurements on the different clinical manifestations of PHM pathophysiology.

In myoclonus patients, EEG-EMG investigations can help to differentiate between a cortical (CM) and subcortical (SM) origin of myoclonus.<sup>11</sup> The first step in analyzing the origin of PHM is the visual analysis of EEG in relation to the myoclonic jerks. EEG spike discharges preceding myoclonic jerks are a sign of CM.<sup>10</sup> In addition to EEG, burst duration on EMG can discriminate as CM is typically below 75 msec, whereas SM is more likely to have a longer burst duration.<sup>9</sup> Furthermore, in polymyographic EMG the pattern of muscle activation during a myoclonic jerk is different between CM and SM. In SM, muscles innervated by cranial nerves close to the reticular formation contract first, followed by muscles up- and downstream from the (caudal) brainstem.<sup>11,18,19</sup> A strictly downstream (i.e., cranio-caudal) muscle recruitment pattern is more likely to originate from the cortex.<sup>11</sup> Finally, a combined EEG-EMG approach permits identifying the origin of myoclonus by Jerk-Locked Back Averaging (JLBA) and coherence analysis.<sup>11,18,20–23</sup>

To proceed in evaluating PHM as potential prognosticator in PAE, and to provide new insights into the pathophysiology of PHM, we aimed to objectify the interrelation between the clinical and neurophysiological manifestations of PHM. For this reason, we conducted comprehensive EEG-EMG-video recordings in a cohort of patients with PHM.

## Methods

### Patients

Twenty adult patients with PHM occurring within 5 days after CPR were consecutively included between February

2009 and November 2014 as part of the usual PHM work-up in the ICU. In nine patients EEG-EMG recordings along with concurrent video recording were assessed prospectively, and in 11 patients the recordings were derived from the EEG database of the Department of Clinical Neurophysiology. The exclusion criteria were: a Glasgow Coma Score above eight, traumatic brain injury, epilepsy, history of myoclonus, possible origin of myoclonus other than PAE, and medication overdose. All patients received target temperature management (target: 32°C *n* = 13, 36°C *n* = 6) and were sedated during the first ~24 h of ICU admission. The etiology and location of cardiac arrest, first monitored rhythm, time to return of spontaneous circulation, time to onset, presence of sedation at time of onset, initial treatment of PHM and clinical outcome were obtained from patients' medical records. Clinical outcome was assessed one year after CPR and expressed in Cerebral Performance Category (CPC, range 1–5).<sup>24</sup> In patients who had died, cause of death was determined. In case treatment was withdrawn, it was verified whether this was due to a neurological or nonneurological reason.

### Clinical assessment

Clinical characteristics of PHM were assessed using fragments of video. In each patient 3 min of video was selected, including myoclonic jerks and a pain and auditory stimulus. The videos were evaluated by three neurologists (BMJ, JN, RZ) with expertise in neurocritical care and movement disorders. Raters were blinded for clinical outcome, and classified the following PHM characteristics: clinical subtype (generalized or focal, unifocal/multifocal), localization (proximal or distal), stimulus sensitivity (present or absent) and severity of PHM.<sup>10</sup> Myoclonus solely present in the face was evaluated as “distal” localized, due to the large representation of the (oral area of the) face in the motor homunculus.<sup>25</sup> PHM severity was assessed with the Clinical Global Impression of Severity scale (CGI-S) (range 1–7)<sup>26</sup> and the 2nd part of the Unified Myoclonus Rating Scale (UMRS).<sup>27</sup> The latter quantifies myoclonus severity in resting state by multiplying the amplitude and frequency of PHM in eight different body parts (range 0–128). The higher the CGI-S and UMRS scores, the more severe the myoclonus is. PHM characteristics were classified based on the score of two or three similar ratings. The CGI-S and UMRS scores were averaged.

### Clinical neurophysiology

The EEG-EMG was recorded using BrainRT software (OSG BVBA, Rumst, Belgium). In 12 patients a sample rate of 1000 Hz was used and in seven 250 Hz. EEG

electrodes were placed according to the International 10–20 system (19 scalp electrodes; Fz referenced, impedance <10 k $\Omega$ ). EMG was performed with bipolar referenced Ag/AgCl surface electrodes (impedance: <50 k $\Omega$ ) located  $\pm 3$  cm adjacent to each other on the muscle. The number of EMG channels varied from four to nine. In eight patients a standardized 9-channel EMG protocol was used, which consisted of measurements at the following muscles: masseter, orbicularis oculi, sternocleidomastoid, biceps brachii, abductor pollicis brevis, rectus abdominis, rectus femoris, tibialis anterior, and a muscle of choice with myoclonus. EMG channels were placed at one side of the body, a restriction that did not hold for the muscle of choice. In the other 11 patients without standardized EMG protocol, a more targeted muscle selection approach was used in which muscles with myoclonus were chosen (6-channel EMG, three patients; 4-channel EMG, seven patients). In case multiple EEG-EMGs were performed, the first recording with myoclonus was used. EEG-EMGs were performed a median value of (*M*) 1 day (IQR 1) after first appearance of PHM. The duration of the recordings was (*M*) 38 min (range 10–120 min).

EEG background patterns were categorized as (1) iso-electric, (2) low voltage, (3) burst suppression, (4) generalized status epilepticus, (5) diffuse slowing, and (6) mild encephalopathic or normal.<sup>6,28</sup> EEGs were visually inspected for motor cortex potentials before the onset and in direct relation with PHM (Fig. 1A). If present, mean duration of the motor cortex potential before the onset of the myoclonic jerk was assessed using 10 randomly assessed events.

### Somatosensory-evoked potentials

Somatosensory-evoked potentials (SSEP) were obtained by median nerve stimulation and considered absent if the cortical N20 response was bilaterally absent (specific for poor neurologic outcome in PAE).<sup>29</sup> SSEP results were derived from the database of the Department of Clinical Neurophysiology.

### Jerk-locked back averaging

JLBA was performed with BrainVision Analyzer 2 (Brain Products GmbH, Gilching, Germany). Drift and movement artifacts were removed using a Butterworth high-pass filter (48 dB/octave) of 2 Hz (EEG) and 10 Hz (EMG). EEG signals were re-referenced to a Hjorth (local average) montage, and artifacts directly after and related to PHM were accepted (since only EEG prior to PHM was evaluated). PHM bursts on EMG were selected with markers placed consistently at EMG onset. To prevent muscle artifact contamination from previous myoclonic

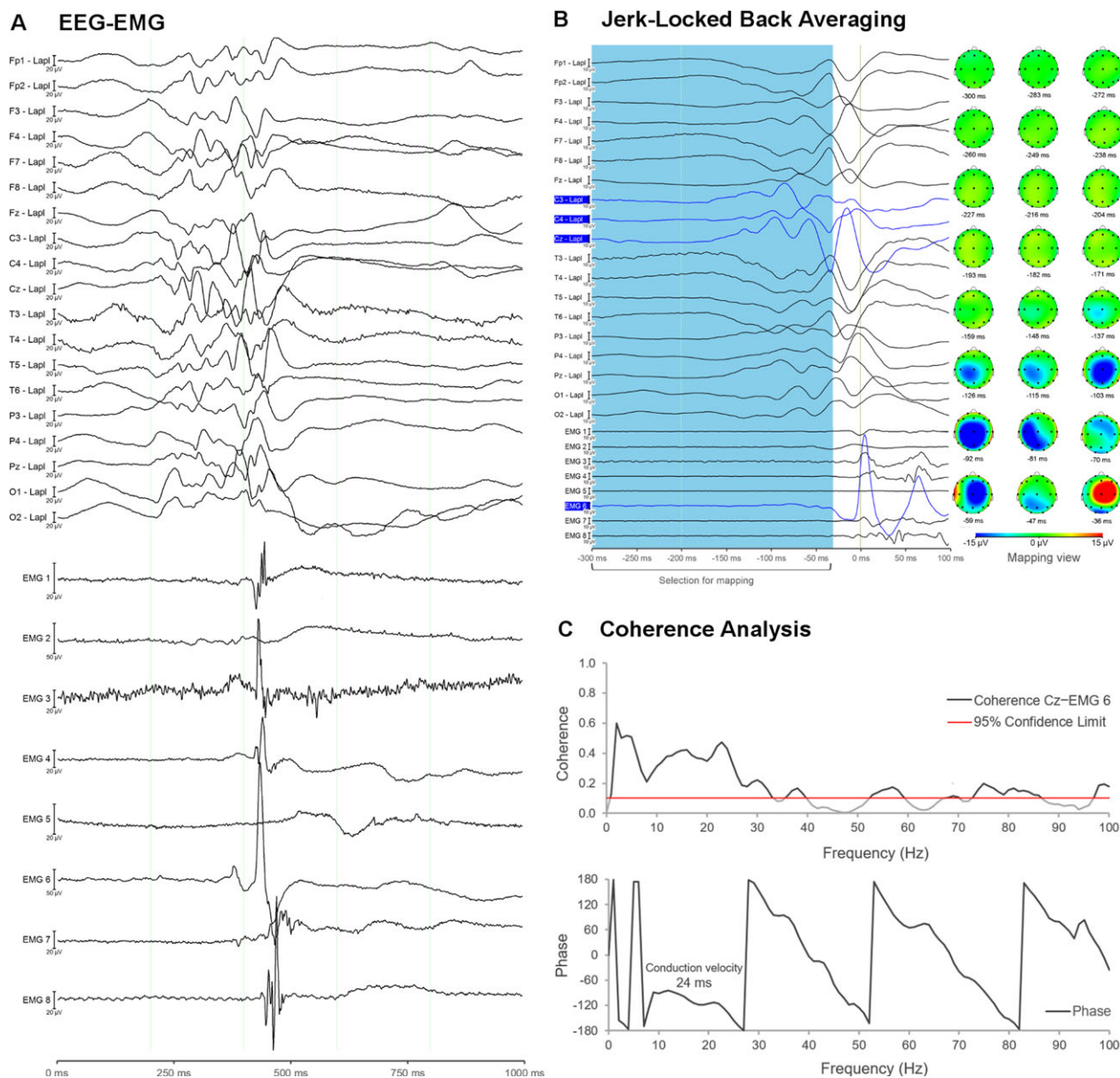
jerks, only EMG bursts were included with an interval to the prior burst longer than 80 msec (*M* 250 msec, range 80–2000). The averaged EEG (*M* 127, range 30–675) was evaluated in a window starting 300 msec before and 100 msec after PHM onset. Reproducibility of JLBA results was checked using odd/even averaging.<sup>21</sup> In “synchronous” jerks with multiple muscle involvement, the first contracting muscle was used for further analyses. In “nonsynchronous” jerks, the EMG-channel with most prominent myoclonus was selected. Additionally, an EMG-channel with second most prominent myoclonus (not involved in an “synchronous” jerk) was examined as well in order to evaluate whether CM and SM might co-occur in PHM. JLBA was considered positive (CM presumed) if a replicable potential was present at the contralateral motor cortex 10–40 msec preceding the myoclonic jerk, and if absent SM was suspected (Fig. 1B).<sup>11,21</sup>

### Coherence analysis

Coherence analysis was performed using in-house written software build in LabVIEW (National Instruments 2014, Austin, Texas, United States) based on the description of Halliday and colleagues (1995).<sup>23</sup> The same EEG-EMG filter and re-referencing method used for JLBA were applied. Additionally, the EMG channels were rectified to enhance the firing rate information of the signal.<sup>30</sup> The EEG-EMG was segmented into nonoverlapping epochs of 1-second based on the position of the JLBA markers. A Fourier transformation of the epochs was performed using a Hanning window and averaged (*M* 84 averages, range 29–249) to obtain the frequency autospectra of motor cortex EEG and contralateral EMG. Coherence (range 0–1) was calculated and considered significant if exceeding the 95% confidence level at four or more consecutive 1 Hz bins. Phase lag and corticomuscular conduction time were assessed for the significant coherence bins.<sup>23,31</sup> CM was considered present (coherence positive) if coherence was found between motor cortex and contralateral myoclonus muscle with appropriate phase (EMG follows EEG) and conduction time.<sup>23</sup> SM was concluded (coherence negative) if no corticomuscular coherence, or corticomuscular coherence with inappropriate phase (EEG follows EMG) was present (Fig. 1C).

### Neurophysiological classification

To classify the anatomical origin of PHM, five different neurophysiological methods were used, namely: (1) visual inspection of EEG, (2) EMG burst-duration, (3) muscle recruitment order, (4) JLBA, and (5) coherence analysis.<sup>6,9–11,18–22</sup> Cortical PHM was presumed if (1) an EEG



**Figure 1.** A posthypoxic myoclonus patient with generalized jerks from cortical origin. (A) The EEG shows spiking activity before onset of the EMG bursts of the generalized jerk, and on EMG a cranio-caudal recruitment order is present with on average a burst duration of  $\pm 90$  msec (EMG-channel 6). (B) Jerk-Locked Back Averaging of the right abdominis muscle (EMG-channel 6, 30 segments) with a clear motor cortex EEG potential before the onset of muscle activation. (C) Corticomuscular coherence of Cz (Hjorth-montage) versus right abdominis muscle (EMG-channel 6) with correct phase lag (EMG follows EEG signal) and reliable conduction velocity (24 msec). A (EEG spikes), B and C affirm a cortical origin of the myoclonus (PHM case 5, Table 2).

spike prior PHM was visible on EEG, (2) a mean burst duration  $< 75$  msec was present (10 randomly assessed jerks), (3) a cranio-caudal muscle recruitment order or only single myoclonic jerk(s) were present, (4) JLBA was positive, or (5) reliable corticomuscular coherence was present. On the contrary, subcortical PHM was suspected if the aforementioned criteria were absent, and/or a

“lower-brainstem first” recruitment pattern was present (Table 1).

Methods i, ii and iii were considered as *basic* neurophysiological methods. Two or three identical findings considering PHM origin determined the overall conclusion of basic neurophysiology (i.e. cortical or subcortical PHM). *Advanced* neurophysiology consisted of JLBA and

coherence analysis (iv-v). If both techniques were in line, an overall conclusion for *advanced* neurophysiology could be obtained.

## Statistical analysis

Clinical characteristics and neurophysiological findings of PHM were classified into (1) generalized/focal, (2) SSEP<sup>N20</sup> present/absent, (3) JLBA positive/negative and (4) coherence positive/negative. Differences were described and tested using a one-sided Mann-Whitney U-test for numerical data, and a one-sided Fisher's exact test for binary data. In case a parameter could only be derived from a selected number of patients, statistical analyses were conducted only in the patients in whom the parameter was described. *P*-values < 0.05 were considered statistical significant. To assess agreement among clinical, basic, and advanced neurophysiological analyses of PHM, Cohen and Fleiss kappa was used. Kappa results were classified as; *k* < 0 "poor," 0–0.2 "slight," 0.21–0.4 "fair," 0.41–0.6 "moderate," 0.61–0.8 "substantial," >0.81 "almost perfect."<sup>32</sup>

## Results

### Patient characteristics

Twenty PHM patients were included, but one was excluded for further analyses as no EMG discharges were found in relation to the myoclonic jerks. Mean age at ICU admission was 56 (range 21–86) and 13 were male (68%). Cardiac arrest occurred out-of-hospital in 14 patients (74%). In six patients (32%) PHM appeared while sedation was still applied. In two patients (11%) (mild) sedation was continued during the recording, since otherwise the severity of myoclonus would have negatively influenced mechanical ventilation. PHM was treated with either single or combined medication in 17 patients

(89%) (sodium valproate 71%, propofol 47%, clonazepam 24%, levetiracetam 12%, phenytoin 6%). Two patients (11%) survived with mild to no cognitive deficits, the other 17 died. One patient had recurrent cardiac arrest during ICU admission and cardiac output could not be restored. In the other 16 patients (94%), neurological prognosis was considered poor. Mean time to treatment withdrawal in the deceased patients was 5 days (range 2–10). Detailed patient characteristics are provided in Table 2.

### Clinical assessment

PHM was evaluated as generalized in seven (37%) and focal in 12 (63%) patients. In 10 patients (53%) the proximal muscle involvement was rated as more prominent than in distal muscles. Auditory and pain stimuli were assessed in 17 patients. None of the auditory stimuli had an effect on PHM, however, pain stimuli-evoked myoclonic jerks in 6/17 cases (35%). PHM severity was on average 3.8 (SD 1.3) CGI-S and *M* 14 (IQR 26) UMRS. In generalized PHM, 6/7 cases (86%) had more pronounced proximal muscle involvement, 2/7 (29%) were sensitive to pain stimuli and severity was on average 5.0 (SD 0.7) CGI-S and *M* 33 (IQR 20) UMRS. In contrast, focal PHM was localized more distally in 4/12 cases (33%), sensitivity to pain in 4/10 (40%) cases and its severity was on average 3.1 (SD 1.1) CGI-S and *M* 9.7 (IQR 11) UMRS. In generalized PHM, significantly more proximal (*P* = 0.04) and severe (CGI-S; *P* = 0.004, UMRS; *P* = 0.001) myoclonic jerks were present compared to focal PHM. Time to PHM onset and initial rhythm did not differ statistically between generalized and focal PHM (Table 3).

### Electroencephalography

The distribution of EEG background patterns is depicted in Table 2. Four patients (21%) had a spike in EEG prior PHM onset, and the potentials started *M* 40 msec (range 17–124) before the myoclonic jerk. The occurrence of status epilepticus and EEG spikes prior to myoclonic bursts did not differ significantly between generalized and focal PHM (Table 3).

### Electromyography

EMG burst duration was *M* 55 msec (range 36–130), in which 15 patients (79%) had a burst duration below 75 msec (Table 2). Muscle recruitment of PHM started in the lower brainstem with up- and downstream muscle activation in two cases (11%). In the other patients, three showed myoclonus following a cranio-caudal recruitment

**Table 1.** Neurophysiological criteria cortical and subcortical posthypoxic myoclonus.

Method	Cortical PHM	Subcortical PHM
Visual inspection of EEG	EEG spike before jerk	EEG spike not present
Burst duration	Mean duration of <75 msec	Mean duration of >75 msec
Muscle recruitment	Cranio-caudal, single muscle jerk(s)	Lower-brainstem first
Jerk-Locked	Averaged EEG potential before jerk	Absent EEG potential
Back Averaging	Coherence and correct phase	Coherence absent or incorrect phase

**Table 2.** Characteristics of posthypoxic myoclonus patients.

#	Cause	ECG	ROSC	PHM	Type	UMRS	CM signs	SM signs	EEG	SSEP	CPC
1	Cardiac	VF	40	day 2	MF	3	S+ B+ R+ J+ C+		DS	N/A	1
2	Cardiac	VF	N/A	day 2	GZ	33	R+ J+ C+	S- B-	SE	N20+	5
3	Cardiac	Asys	75	day 1	MF	3	B+	S- R- J- C-	DS	N20-	5
4	Cardiac	VF	29	day 1	MF	14	B+ R+	S- J- C-	BS	N20-	5
5	Cardiac	VF	N/A	day 2	GZ	14	S+ R+ J+ C+	B-	SE	N/A	2
6	Cardiac	VF	N/A	day 1	GZ	48	B+ R+ J+ C+	S-	BS	N20+	5
7	Cardiac	VF	N/A	day 5	MF	11	R+	S- B- J- C-	LV	N20+	5
8	Cardiac	VF	N/A	day 1	MF	3	B+ R+ J+	S- C-	SE	N/A	5
9	Hypoxic	PEA	N/A	day 1	GZ	56	B+ R+	S- J- C-	SE	N20-	5
10	Hypoxic	Asys	N/A	day 1	GZ	28	S+ B+ R+ J+ C+		DS	N20+	5
11	Hypoxic	Asys	24	day 1	MF	20	R+	S- B- J- C-	BS	N20-	5
12	Hypoxic	PEA	N/A	day 2	MF	4	B+ R+	S- J- C-	SE	N20-	5
13	Hypoxic	VT	15	day 2	GZ	45	S+ B+ R+ J+ C+		BS	N20+	5
14	Hypoxic	Asys	20	day 1	MF	8	B+ R+	S- J- C-	BS	N20-	5
15	Hypoxic	Asys	55	day 2	GZ	31	B+ R+ J+ C+	S-	DS	N/A	5
16	Other	PEA	N/A	day 3	MF	7	B+ R+ J+ C+	S-	SE	N/A	5
17	Other	PEA	20	day 1	MF	12	B+ J+	S- R- C-	BS	N/A	5
18	Other	PEA	10	day 1	MF	13	B+ R+	S- J- C-	BS	N/A	5
19	Other	PEA	N/A	day 1	MF	38	B+ R+	S- J- C-	SE	N20+	5
N	Cardiac	VF/VT	<i>t</i> (m) (SD)	<24 h	GZ	<i>M</i> (IQR)	JLBA+	JLBA-	LV/BS	N20-	CPC 1-2
19	8 (42%)	8 (42%)	32 (21)	11 (58%)	7 (37%)	14 (26)	10 (53%)	9 (47%)	8 (42%)	6 (50%)	2 (11%)

Asys, Asystole; B, burst duration; BS, burst-suppression; C, coherence analysis; CM, cortical myoclonus; CPC, cerebral performance category; DS, diffuse slowing; ECG, electrocardiography initial rhythm; GZ, generalized PHM; IQR, Interquartile range; J, Jerk-locked Back Averaging (JLBA); LV, low-voltage; MF, unifocal+multifocal PHM; Other=#16-septic shock #17-hyperkalemia #18-hemoptoe #19-air embolisms, PEA, pulseless electrical activity, R, recruitment order; ROSC, return of spontaneous circulation (time in minutes after cardiac arrest); S, EEG spike; SD, standard deviation; SE, generalized status epilepticus; SM, subcortical myoclonus; SSEP, somatosensory-evoked potentials; VF, ventricular fibrillation; VT, ventricular tachycardia.

pattern (16%), five presented myoclonus only in a single EMG-channel (26%), and nine had myoclonus in multiple EMG-channels without a specific pattern (47%). Burst duration and brainstem recruitment order did not differ significantly between generalized and focal PHM (Table 3).

### Somatosensory-evoked potentials

In 12/19 PHM patients (63%) SSEP recordings were performed. N20 responses were bilaterally absent in six patients (50%), and the other six had an N20 response in at least one hemisphere. In SSEP<sup>N20-</sup> patients, 1/6 (17%) had generalized PHM, and SSEP<sup>N20+</sup> 4/6 (67%) focal PHM (Table 3).

### Jerk-locked back averaging

Analysis with JLBA showed presence of CM in 10/19 patients (53%) (Table 2). In generalized PHM, 6/7 patients (86%) had JLBA-proven CM, whereas focal PHM exhibited 4/12 (33%) CM. This distribution of CM among PHM subtypes was significantly different ( $P = 0.04$ ). An EEG spike(s) before onset of PHM was

present in 4/10 patients (40%) with positive JLBA. In case JLBA was negative, no prejerker EEG spikes were seen ( $P = 0.05$ ). In addition, SSEP<sup>N20-</sup> patients did not show CM with JLBA. Contrarily, in SSEP<sup>N20+</sup> patients, significantly more CM was found (4/6 patients, 67%) ( $P = 0.03$ ) (Table 3).

### Coherence analyses

Eight patients (42%) presented corticomuscular coherence with appropriate phase lag (i.e. CM) (Table 2). In patients with onset of PHM <24 h after CPR SM was found in 9/11 cases (81%). If PHM occurred >24 h after CPR, SM was only present in 2/8 cases (25%), which was significantly different ( $P = 0.02$ ). Coherence analysis identified CM in 6/7 (86%) generalized PHM patients (86%), whereas focal PHM patients showed significantly less CM (4/12, 17%;  $P = 0.006$ ). No prejerker EEG spikes were seen in coherence negative (SM) patients, whereas such spikes were seen in 4/8 (50%) patients with corticomuscular coherence (CM) ( $P = 0.02$ ). In SSEP<sup>N20-</sup> patients CM was absent, whereas in SSEP<sup>N20+</sup> CM was present in 4/6 cases (67%) ( $P = 0.03$ ). In all coherence positive patients, JLBA showed CM as well. In the patients with no

**Table 3.** Comparisons between subgroups of posthypoxic myoclonus patients.

	Clinical assessment		Advanced neurophysiology		
	GZ MF	SSEP- SSEP+	JLBA- JLBA+	COH- COH+	
Patients, <i>n</i>	7–12	6–6	9–10	11–8	
Clinical assessment					
Outcome, %survived	14–8%	0–0%	0–20%	0–20%	
Cause CPR, %cardiac	43–42%	33–50%	33–50%	36–50%	
Initial rhythm, %VF/VT	57–33%	17–67%	22–60%	27–63%	
Onset PHM, %<24 h	43–67%	83–50%	78–40%	81–25%*	
CGI-S, mean	5.0–3.1*	3.3–4.8	3.5–4.0	3.5–4.2	
UMRS, median	36–12*	18–34	13–22	17–26	
Localization, %proximal	86–33%*	50–80%	55–50%	45–63%	
Stimulus sensitive, %yes	29–40% <sup>n=10</sup>	33–33%	33–38% <sup>n=8</sup>	40 <sup>n=10</sup> –29% <sup>n=7</sup>	
PHM type, %GZ	n/a–n/a	17–67%	11–60%*	9–75%*	
Basic neurophysiology					
EEG pattern, %SE	43–33%	33–33%	33–40%	36–38%	
EEG spike, %yes	43–8%	0–33%	0–40%	0–50%*	
EMG bursts, %<75 msec	71–83%	83–67%	78–80%	82–75%	
Recruitment, %brainstem	0–17%	17–0%	13–11%	18–0%	
Advanced neurophysiology					
SSEP, %N20-	20 <sup>n=5</sup> –71% <sup>n=7</sup>	n/a–n/a	75 <sup>n=8</sup> –0% <sup>n=4</sup> *	75 <sup>n=8</sup> –0% <sup>n=4</sup> *	
JLBA, %+ (CM)	86–33%*	0–67%*	n/a–n/a	18–100%*	
Coherence, %+ (CM)	86–17%*	0–67%*	0–80%*	n/a–n/a	

COH, coherence; "+" present, "-" absent; CM, cortical myoclonus; CPR, cardiopulmonary resuscitation; CGI-S, Clinical Global Impression of Severity scale; GZ, generalized PHM; JLBA, Jerked-Locked Back Averaging; "+" cortical potential present, "-" potential absent, MF, unifocal+multifocal PHM; SE, status epilepticus; SSEP, Somatosensory-evoked potentials; "+" N20 response present, "-" N20 bilaterally absent, UMRS, Unified Myoclonus Rating Scale (2nd part); VF/VT, ventricular fibrillation/tachycardia; \* =  $P < 0.05$ .

corticomuscular coherence, 2/11 (18%) patients showed CM with JLBA (Table 3).

### Intermethod agreement

In only two patients (11%) the clinical interpretation, basic- and advanced neurophysiological findings of PHM origin were in line with one another. The agreement between "clinic versus basic neurophysiology" ( $\kappa = -0.20$ , 95% CI =  $-0.59$  to  $0.19$ ) and "clinic versus advanced neurophysiology" ( $\kappa = -0.63$ , 95% CI =  $-1.00$  to  $-0.25$ ) were poor. The "basic versus advanced neurophysiology" comparison had fair agreement ( $\kappa = 0.20$ , 95% CI =  $-0.18$  to  $0.58$ ) (Fig. 2). In addition, JLBA and coherence analysis showed substantial agreement ( $\kappa = 0.79$ , 95% CI =  $0.52$  to  $1.00$ ), whereas the other comparisons between the different neurophysiological methods showed low intermethod agreement (Table S1).

### Co-occurrence of cortical and subcortical posthypoxic myoclonus

Seven of 19 patients (37%) presented on EMG another muscle with myoclonic jerks, who were not involved in a "synchronous" jerk, secondary prominent, and suitable

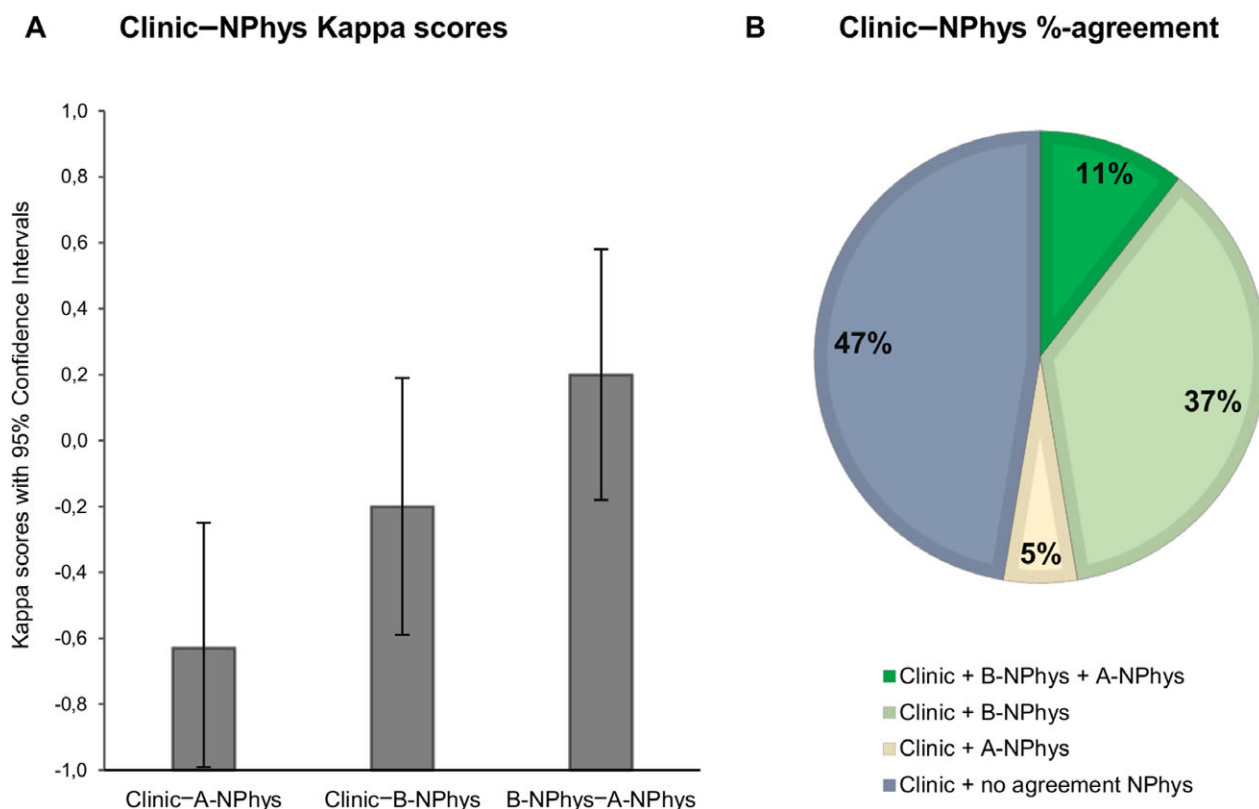
for advanced neurophysiological assessment. Analyses showed in 5/7 (71%) of these patients an identical anatomical origin compared to the first examined EMG-channel with (most prominent) myoclonic jerks. In the other two patients, CM and SM co-occurred.

### Outcome

Two patients (11%) survived. One patient exhibited clinically focal PHM (Case 1, Table 2) and the other generalized PHM (Case 5, Table 2, Fig 1). Neurophysiological analyses of the first patient revealed a diffuse slow EEG pattern and an EEG spike  $\pm 17$  msec before the onset of PHM. The muscle recruitment consisted of a single twitching muscle with on average a burst duration of  $\pm 54$  msec. The other patient had a status epilepticus, EEG spikes starting  $\pm 120$  msec before PHM onset, a cranio-caudal muscle recruitment pattern, and an averaged burst duration of  $\pm 90$  msec. JLBA and coherence analysis showed CM in both patients. SSEP<sup>N20</sup> responses were not obtained for these patients.

### Discussion

In this study we investigated the relation between the clinical presentation and anatomical origin of PHM with



**Figure 2.** Agreement between the clinical, basic and advanced neurophysiological assessment of posthypoxic myoclonus origin. (A) Kappa scores with 95% confidence intervals between the clinical interpretation of PHM origin (generalized = subcortical, focal (unifocal and multifocal) = cortical) and the basic (B-NPhys) or advanced neurophysiological (A-NPhys) assessment of PHM origin. (B) Percentage agreement between the aforementioned modalities.

use of comprehensive EEG-EMG-video recording in a cohort of 19 patients. The main finding was that the clinical interpretation of PHM origin poorly matched with the origin based on the neurophysiological investigations. The agreement between “clinical presumed” and “neurophysiological obtained” cortical or subcortical PHM was poor. In addition, CM was more likely present in generalized PHM compared to focal PHM.

### Clinical versus neurophysiological findings of posthypoxic myoclonus

The presumed anatomical origin of PHM based on the clinical presentation of myoclonus had poor agreement with the neurophysiologically determined origin of PHM (Fig. 2). PHM case 5, illustrated in Figure 1, is an example of a patient in which clinically a subcortical origin was suspected (generalized myoclonus) and a cortical origin was found with JLBA and coherence analysis. Most importantly, this patient survived with only mild cognitive deficits. Moreover, in this cohort CM was more likely

present in patients with generalized PHM than in focal PHM. This result is in line with earlier studies who demonstrated that generalized PHM can arise from the cortex.<sup>5,6,33</sup> These findings suggest that the clinical model of typical CM and SM phenomenology that physicians encounter in noncomatose myoclonus patients at the outpatient clinic does not apply for PHM in the first few days after resuscitation.<sup>10,11</sup> In addition, the aforementioned emphasizes that the acute stage of PAE with PHM is unique and different from the late type of PHM (Lance Adams) and reticular reflex myoclonus that can be found in “chronic” survivors.

### Pathophysiology of cortical generalized posthypoxic myoclonus

Cortical generalized myoclonus was repeatedly found in the current cohort of PHM patients. In contrast, in the general outpatient clinic population, patients with cortical generalized myoclonus are uncommon.<sup>10</sup> This discrepancy might be caused by the presence of variable anoxic/



hypoxic damage to the architecture of brain motor pathways in PHM patients. This damage may pave the way for a variety of mechanisms in which cortical generalized PHM can occur.<sup>3,7,33</sup> For example, in some cases, a generalized jerk could arise from seizures wherein generalized ictal discharges act as the cortical source of PHM.<sup>33,34</sup> Another explanation for cortical-produced generalized myoclonus is that a focal discharge in the cortex spreads and activates the ipsilateral motor cortex (intra-hemispheric excitation spread). However, meanwhile, via the corpus callosum the contralateral motor cortex is activated as well (interhemispheric excitation spread), finally effectively producing a bilateral generalized jerk.<sup>33–35</sup> Certainly, generalized PHM can arise from the brainstem.<sup>8</sup> However, it is not clear if in every case damage to the brainstem is causative for its manifestation. Brainstem PHM might in some cases be a result of hypoxic/anoxic cortex damage, in which the latter is unable to generate inhibitory activity on spontaneous brainstem discharges.<sup>34</sup> In addition, CM and SM may co-occur in PHM (present study 11%),<sup>35</sup> which in conjunction with the above illustrates the complexity of this movement disorder.

### Posthypoxic myoclonus as outcome predictor in postanoxic encephalopathy

Generalized PHM has been correlated with poor outcome in PAE and included as prognosticator of poor outcome in the American postanoxic coma guideline.<sup>1,3</sup> It is thought that the CM or SM represents the localization of anoxic brain decay in PHM patients.<sup>8,33–35</sup> The general hypothesis is that damage to the brainstem is worse in terms of prognosis compared to cortical lesions in PAE.<sup>1,7</sup> Generalized myoclonus has been associated with a subcortical origin,<sup>7–11</sup> however in this study we showed that generalized PHM can be of cortical origin as well. Interestingly, Gentsch and colleagues (2015) found that the total amount of brain damage predicts outcome in PAE.<sup>36</sup> This finding suggests that patients with a multiple lesioned cortex (and CM) could have a worse outcome compared to patients with a singular, small brainstem lesion (and SM). In addition, studies that correlated the generalized and focal PHM phenotype to outcome found that the severity of myoclonus, and not per se the presence or absence of brainstem damage, was related to poor outcome.<sup>1,5,6</sup> Yet in contrast, another finding of this study was that in patients presenting PHM within 24 h after CPR, significantly less CM occurred (Table 3). This may indicate that the presence of SM is related to poor outcome, since early appearance of PHM has been correlated to poor outcome in various studies.<sup>3,6,17</sup> Moreover, the two patients that survived had CM, which suggests that the anatomical location or the presence of corticomuscular coupling could be a predictor of good

outcome in PAE. However, in general there are no sufficiently large sized studies correlating the exact anatomical location of brain damage with PHM phenotype, origin and outcome.

The above considerations suggest that the exact role of PHM as PAE prognosticator has not been adequately refined yet to play a pivotal role in treatment decisions to withdraw life support. If the origin of PHM turns out to be the key for outcome prognostication in PAE, JLBA and coherence analysis can be used for a reliable assessment. In addition, the specific PHM EEG background patterns proposed by Elmer and colleagues (2016) may have a role in the outcome prediction as well.<sup>37</sup> In case severity of PHM is the factor that predicts outcome, the UMRS might be a suitable tool to use.<sup>16,27</sup> It may be possible to add the aforementioned factors into a multi-model algorithm that results in one prognostic score for PAE.<sup>12,38</sup> An example of this is the recently introduced Cerebral Recovery Index.<sup>39</sup>

### Limitations

A limitation of this study was the absence of a gold standard in identifying PHM origin. Moreover, the sensitivity and specificity of the neurophysiological methods used are unknown (except for SSEP as prognosticator in PAE). On the other hand, JLBA and coherence analysis have proven their role in clinical practice in evaluating anatomical origin of myoclonus and can therefore be seen as a reliable marker.<sup>11,18,20–22,31</sup> Indeed, the agreement between JLBA and coherence analysis turned out to be substantial: 17/19 patients had identical findings. Furthermore, in SSEP<sup>N20-</sup> patients CM was absent with JLBA and coherence analysis. This result speaks in favor of the reliability of these techniques, despite that SSEP and JLBA/coherence are indirectly related to each other.<sup>11,29</sup>

Another limitation was that the sample size of this study was too small to prove a direct relation between the occurrence of CM in PHM patients and outcome. Moreover, the study consisted of prospective and retrospective included patients. However, a bias is unlikely since the distribution of generalized and focal PHM did not differ between the prospective and retrospective group.

A different source of uncertainty in this study was that the clinical assessment of PHM might have been challenging due to the dynamic and intermittent character of PHM and the use of video recordings leading to an observation that is less vivid.<sup>13,14,16</sup> To circumvent this issue, three instead of one experienced neurologist interpreted the clinical videos. In addition, video recording with simultaneous EEG-EMG ensures that the same jerks were assessed by both the physicians and the clinical neurophysiological analyses, which is an advantage.

## Conclusion

In summary, the main finding of this study was that the clinical presumed anatomical origin of PHM poorly matched the result obtained with neurophysiology. It is possible that hypoxic damage to variable cortical and subcortical areas in the brain lead to mixed and varying clinical manifestations of myoclonus that differ of those patients with myoclonus generally encountered in the outpatient clinic. The current clinical classification of PHM is not adequately refined to play a pivotal role in guiding treatment decisions to withdraw care. To further explore the potential role of PHM as prognosticator in PAE, comprehensive studies combining clinical, neurophysiological, imaging, and pathological data are needed.

## Acknowledgments

This study was not funded. Dr. van Zijl received the MD/PhD scholarship from the University of Groningen and Dr. Beudel received funding from the Dutch Brain Foundation for research purposes.

## Author Contributions

JCvZ, MB, JWJE, and MAJT conceived of and designed the study. All authors contributed to data acquisition and analysis. JCvZ drafted the manuscript and prepared the figures.

## Conflicts of Interest

The authors report no conflict of interest.

## References

- Wijdicks EF, Parisi JE, Sharbrough FW. Prognostic value of myoclonus status in comatose survivors of cardiac arrest. *Ann Neurol* 1994;35:239–243.
- Hui ACF, Cheng C, Lam A, et al. Prognosis following postanoxic myoclonus status epilepticus. *Eur Neurol* 2005;54:10–13.
- Wijdicks EF, Hijdra A, Young GB, et al. Quality Standards Subcommittee of the American Academy of Neurology. Practice parameter: prediction of outcome in comatose survivors after cardiopulmonary resuscitation (an evidence-based review): report of the Quality Standards Subcommittee of the American Academy of Neurology. *Neurology* 2006;67:203–210.
- Seder DB, Sunde K, Rubertsson S, et al. International cardiac arrest registry: Neurologic outcomes and postresuscitation care of patients with myoclonus following cardiac arrest. *Crit Care Med* 2015;43:965–972.
- Bouwes A, van Poppelen D, Koelman JH, et al. Acute posthypoxic myoclonus after cardiopulmonary resuscitation. *BMC Neurol* 2012;12:63.
- van Zijl JC, Beudel M, Vd Hoeven HJ, et al. Electroencephalographic findings in posthypoxic myoclonus. *J Intensive Care Med* 2016;31:270–275.
- Young GB, Gilbert JJ, Zochodne DW. The significance of myoclonic status epilepticus in postanoxic coma. *Neurology* 1990;40:1843–1848.
- Hallett M, Chadwick D, Adam J, Marsden CD. Reticular reflex myoclonus: a physiological type of human posthypoxic myoclonus. *J Neurol Neurosurg Psychiatry* 1977;40:253–264.
- Hallett M. Physiology of human posthypoxic myoclonus. *Mov Disord* 2000;15(suppl 1):8–13.
- Caviness JN, Brown P. Myoclonus: current concepts and recent advances. *Lancet Neurol* 2004;3:598–607.
- Cassim F, Houdayer E. Neurophysiology of myoclonus. *Neurophysiol Clin* 2006;36:281–291.
- Hofmeijer J, van Putten MJAM. EEG in postanoxic coma: Prognostic and diagnostic value. *Clin Neurophysiol* 2016;127:2047–2055.
- Rossetti AO. EEG for outcome prediction after cardiac arrest: when the quest for optimization needs standardization. *Intensive Care Med* 2015;41:1321–1323.
- Samaniego EA, Mlynash M, Caulfield AF, et al. Sedation confounds outcome prediction in cardiac arrest survivors treated with hypothermia. *Neurocrit Care* 2011;15:113–119.
- NVN. Richtlijn Postanoxisch coma.doc. 2011;1-23.
- van Zijl JC, Beudel M, Elting JJ, et al. The inter-rater variability of clinical assessment in post-anoxic myoclonus. *Tremor Other Hyperkinet Mov* 2017;7:470.
- Sandroni C, Cariou A, Cavallaro F, et al. Prognostication in comatose survivors of cardiac arrest: an advisory statement from the European Resuscitation Council and the European Society of Intensive Care Medicine. *Resuscitation* 2014;85:1779–1789.
- Rossi SD, Soliveri P, Panzica F, et al. Cortical myoclonus in childhood and juvenile onset Huntington's disease. *Parkinsonism Relat Disord* 2012;18:794–797.
- Beudel M, Elting JWJ, Uyttenboogaart M, et al. Reticular myoclonus: it really comes from the brainstem. *Mov Disord Clin Pract* 2014;1:258–260.
- Barrett G. Jerk-locked averaging: technique and application. *J Clin Neurophysiol* 1992;9:495–508.
- Maurits NM. From neurology to methodology and back: an introduction to clinical neuroengineering Chapter 6. New York: Springer, 2012: 132-139.
- Brown P, Farmer SF, Halliday DM, et al. Coherent cortical and muscle discharge in cortical myoclonus. *Brain* 1999;122(Pt 3):461–472.
- Halliday DM, Rosenberg JR, Amjad AM, et al. A framework for the analysis of mixed time series/point

- process data–theory and application to the study of physiological tremor, single motor unit discharges and electromyograms. *Prog Biophys Mol Biol* 1995;64:237–278.
24. Brain Resuscitation Clinical Trial I Study Group. Randomized clinical study of thiopental loading in comatose survivors of cardiac arrest. *N Engl J Med* 1986;314:397–403.
  25. Penfield W, Boldrey E. Somatic motor and sensory representation in the cerebral cortex of man as studied by electrical stimulation. *Brain* 1937;60:389–443.
  26. Busner J, Targum SD. The clinical global impressions scale: applying a research tool in clinical practice. *Psychiatry (Edgmont)* 2007;4:28–37.
  27. Frucht SJ, Leurgans SE, Hallett M, Fahn S. The unified myoclonus rating scale. *Adv Neurol* 2002;89:361–376.
  28. Cloostermans MC, van Meulen FB, Eertman CJ, et al. Continuous electroencephalography monitoring for early prediction of neurological outcome in postanoxic patients after cardiac arrest: a prospective cohort study. *Crit Care Med* 2012;40:2867–2875.
  29. Bouwes A, Binnekade JM, Zandstra D, et al. Somatosensory evoked potentials during mild hypothermia after cardiopulmonary resuscitation. *Neurology* 2009;73:1457–1461.
  30. Myers LJ, Lowery M, O'Malley M, et al. Rectification and non-linear pre-processing of EMG signals for cortico-muscular analysis. *J Neurosci Methods* 2003;124:157–165.
  31. van Rootselaar AF, Maurits NM, Koelman JHTM, et al. Coherence analysis differentiates between cortical myoclonic tremor and essential tremor. *Mov Disord* 2006;21:215–222.
  32. Landis JR, Koch GG. The measurement of observer agreement for categorical data. *Biometrics* 1977;33: 159–174.
  33. Brown P, Day BL, Rothwell JC, et al. Intrahemispheric and interhemispheric spread of cerebral cortical myoclonic activity and its relevance to epilepsy. *Brain* 1991;114(Pt 5):2333–2351.
  34. Brown P, Thompson PD, Rothwell JC, et al. A case of postanoxic encephalopathy with cortical action and brainstem reticular reflex myoclonus. *Mov Disord* 1991;6:139–144.
  35. Gupta HV, Caviness JN. Post-hypoxic myoclonus: current concepts, neurophysiology, and treatment. *Tremor Other Hyperkinet Mov* 2016;6:409.
  36. Gentsch A, Storm C, Leithner C, et al. Outcome prediction in patients after cardiac arrest: a simplified method for determination of gray-white matter ratio in cranial computed tomography. *Clin Neuroradiol* 2015;25:49–54.
  37. Elmer J, Rittenberger JC, Faro J, et al. Clinically distinct electroencephalographic phenotypes of early myoclonus after cardiac arrest. *Ann Neurol* 2016;80:175–184.
  38. Rossetti AO, Rabinstein AA, Oddo M. Neurological prognostication of outcome in patients in coma after cardiac arrest. *Lancet Neurol* 2016;15:597–609.
  39. Tjepkema-Cloostermans MC, van Meulen FB, Meinsma G, van Putten MJ. A Cerebral Recovery Index (CRI) for early prognosis in patients after cardiac arrest. *Crit Care* 2013;22:17:R252.

## Supporting Information

Additional Supporting Information may be found online in the supporting information tab for this article:

**Table S1.** Agreement between neurophysiological analyses of PHM origin.