



# Use of Intraoperative Computed Tomography for Revisional Procedures in Patients with Complex Maxillofacial Trauma

Mansher Singh, MD  
Joseph A. Ricci, MD  
Edward J. Caterson, MD, PhD

**Background:** In patients with panfacial fractures and distorted anatomic landmarks of zygomatic and orbital complex, there is a risk of zygomaticomaxillary complex (ZMC) malpositioning even with the best efforts for surgical repair. This results in increased number of additional procedures to achieve accurate positioning.

**Methods:** We describe the usage of intraoperative C-arm cone-beam computed tomographic (CT) scan for ZMC malpositioning in a representative patient with panfacial fractures.

**Results:** We have successfully used intraoperative CT scan for ZMC malpositioning in 3 patients. The representative patient had ZMC malposition after the initial attempt of surgical repair without any intraoperative imaging. On using intraoperative CT scan during the next attempt, we were able to reposition the ZMC accurately.

**Conclusions:** Intraoperative CT scan might improve the accuracy of ZMC positioning and decrease the chances of potential additional surgeries. In patients with distorted anatomical landmarks and panfacial fractures, it can be especially helpful toward correcting ZMC malposition. (*Plast Reconstr Surg Glob Open* 2015;3:e463; doi: 10.1097/GOX.0000000000000455; Published online 21 July 2015.)

Zygomaticomaxillary complex (ZMC) fractures are extremely common in patients with facial trauma, due to the prominent position of the zygoma on the face.<sup>1-3</sup> Displaced ZMC fractures often require prompt surgical reduction at all articulation points to restore facial symmetry and prevent the development of enophthalmos.<sup>4</sup> However, in some cases, posttraumatic swelling or the severe distortion of

anatomic landmarks in patients with multiple facial fractures can adversely affect the intraoperative assessment of the operating surgeon, resulting in non-anatomic reduction and subsequent need for more challenging revisional procedures.

Intraoperative C-arm cone-beam computed tomography (CBCT) imaging has been evaluated as an aid to improve the accuracy of ZMC fracture repair multiple studies.<sup>5-9</sup> Intraoperative CBCT scan is not without risks, however, including: radiation exposure, increased operative time, and increased costs. To mitigate these challenges, we propose reserving the use of intraoperative CBCT scan to aid in the reduction of complex or secondary ZMC repositioning after a failure of conventional techniques rather than for all cases as suggested by others.<sup>5-9</sup> We have successfully used it in 3 patients with distorted anatomical landmarks and ZMC malpositioning after

*From the Division of Plastic Surgery, Department of Surgery, Brigham and Women's Hospital, Harvard Medical School, Boston, Mass.*

*Received for publication May 7, 2015; accepted June 11, 2015.*

*Copyright © 2015 The Authors. Published by Wolters Kluwer Health, Inc. on behalf of The American Society of Plastic Surgeons. All rights reserved. This is an open-access article distributed under the terms of the Creative Commons Attribution-Non Commercial-No Derivatives License 4.0 (CCBY-NC-ND), where it is permissible to download and share the work provided it is properly cited. The work cannot be changed in any way or used commercially.*

DOI: 10.1097/GOX.0000000000000455

**Disclosure:** *The authors have no financial interest to declare in relation to the content of this article. The Article Processing Charge was paid for by the authors.*

initial attempt of surgical repair. A representative case is described below.

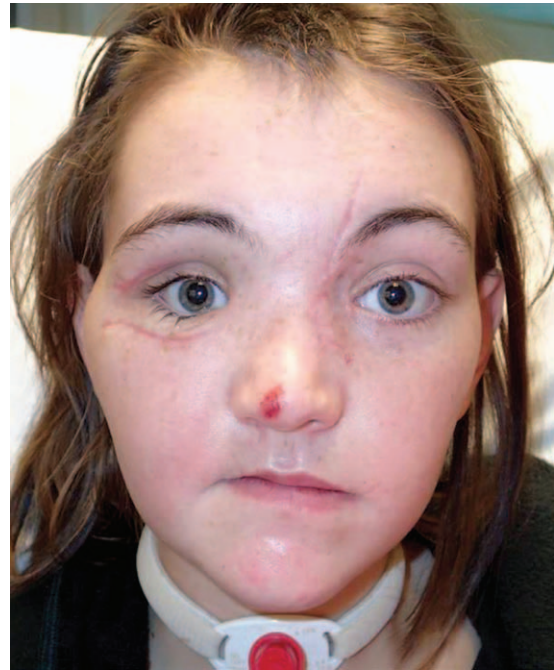### INDEX CASE

A 20-year-old woman was referred to our institution 1 year after initial repair of severe panfacial fractures secondary to a motor vehicle accident at an outside facility. Her complaints on presentation included telecanthus, enophthalmos, and facial widening, sequela of incomplete reduction of her right ZMC (Fig. 1). Using conventional techniques, zygomatic repositioning was attempted at our institution to correct these deformities and restore facial symmetry. Given the time since her original trauma, and scarring from previous surgery, zygoma osteotomies were required and mobilization was challenging. Even though she demonstrated significant clinical improvement once her postoperative swelling decreased, she was noted to still have an incompletely reduced right ZMC on postoperative imaging (Fig. 2). This was attributed to the case difficulty, loss of her original anatomic landmarks from severe initial injuries, and prior surgical interventions. A second repositioning procedure was attempted, but this time with the use of intraoperative CT scan.

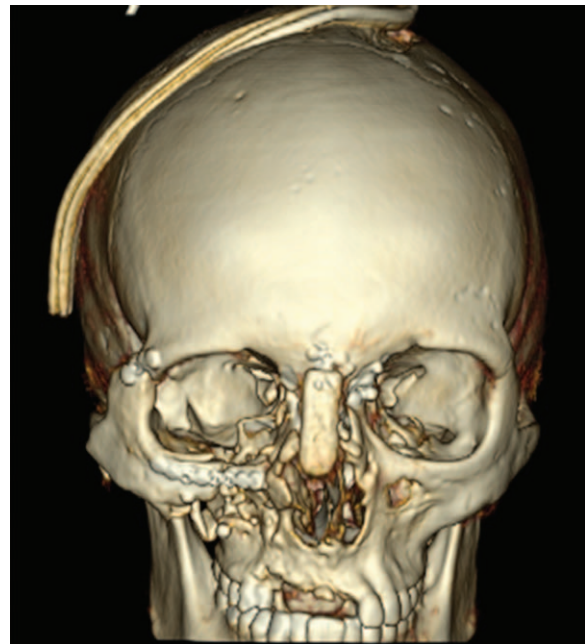An initial scan was taken at the beginning of the procedure (Fig. 3). The transverse and vertical dimensions of the orbit as well as the volume were assessed in real time, with comparison between the right and the left. Exposure was obtained through prior incisions and prior hardware was removed. Again osteotomies were performed to allow for mobilization of the zygoma. Based on the intraoperative comparison of her orbital measurements, additional osteotomies were performed to shrink the zygoma, compressing the orbital volume upon medial translation of the bone. The zygoma was held in reduction and plated. The incisions were closed in a standard fashion. A 2-week postoperative CT scan confirmed the correct positioning of the ZMC (Fig. 4).

### DISCUSSION

Operative fractures of the zygoma are found in a large subset of patients with facial trauma. A study by van den Bergh et al<sup>10</sup> demonstrated that up to 5.5% of patients required a second procedure for ZMC repositioning within 4 weeks of initial repair due to inadequate reduction. In patients with panfacial fractures or ZMC malpositioning after initial repair, the key-fit of the bony fractures is lost and the zygomaticofrontal sutures, orbital rim, and lateral buttress of the maxilla are used as landmarks for accurate repair. Even with the best efforts, the posterior rotational component of ZMC can result in inaccurate

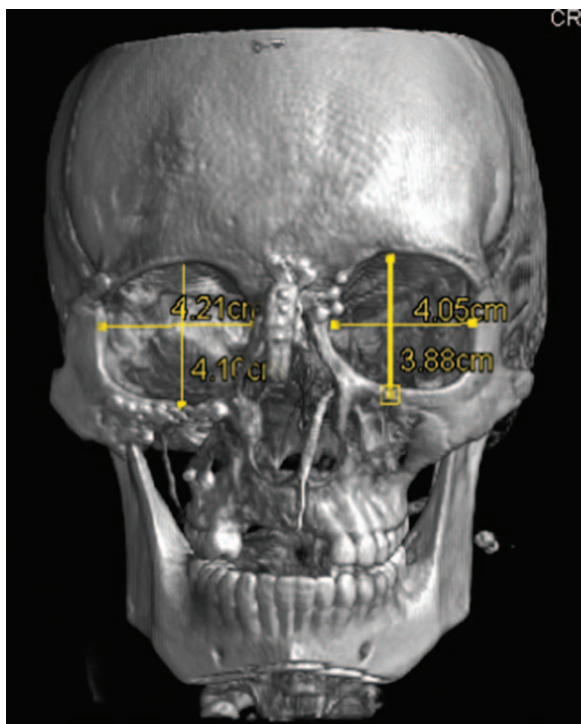


**Fig. 1.** Anteroposterior view of the patient at the time of initial presentation. Note the apparent facial widening, telecanthus, and enophthalmos on the right side of the patient.

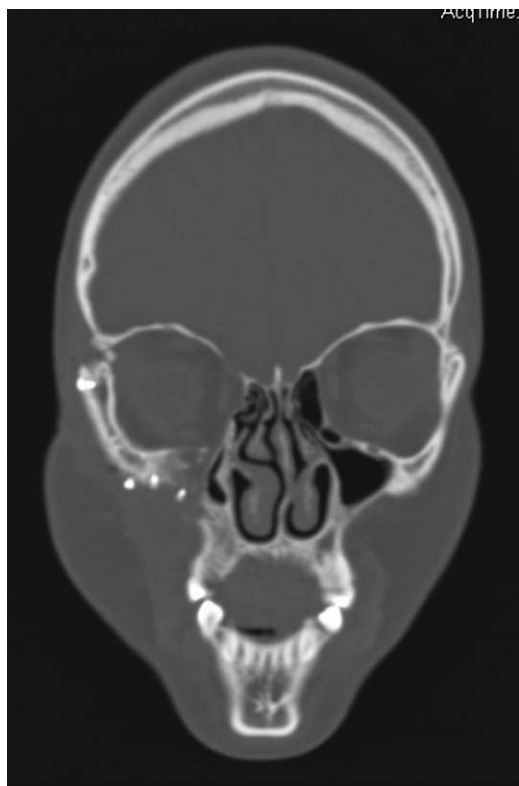


**Fig. 2.** Postoperative CT scan after initial revisional procedure without the use of intraoperative imaging. Note the position of the right zygoma compared with the left with increase in the right-sided orbital volume.

approximation. The use of intraoperative imaging allows for immediate repositioning during the initial procedure if needed, thereby preventing a potential reoperation. Among the available modalities, C-arm



**Fig. 3.** Initial intraoperative CT scan at the start of the procedure with measurements taken of both orbits for comparison.



**Fig. 4.** Postoperative (2 weeks) CT scan demonstrating adequate reduction of the right zygoma and similar orbital measurement [32.97 mm × 33.93 mm (R) vs 32.97 mm × 34.41 mm (L)] and volumes.

fluoroscopy is most commonly available but is unable to assess the orbital floor.<sup>11</sup> The orbital floor can be assessed with ultrasonography but with less accuracy than CT scans.<sup>12,13</sup> Additionally, the maxillozygomatic and sphenozygomatic articulations are difficult to assess with both fluoroscopy and ultrasonography.<sup>11</sup> Overall, all articulation points of the zygoma, the zygomatic arch contour, and the orbital floor are most accurately assessed with CT scan. Intraoperative spiral CT has been described for ZMC fractures, but practical limitations such as the weight and the size of the equipment significantly restrict its usage.<sup>7,8</sup> Instead, CBCT scanners, with a size similar to a traditional C-arm, have been found to be comparable to spiral CT in terms of accuracy with the advantage of low radiation exposure.<sup>5,6</sup>

However, there are significant limitations to the use of routine intraoperative imaging in patients undergoing facial fracture repair: cost of use, exposure of patients to unnecessary radiation (especially pertinent in the population of younger adults who represent the majority of patients with these fractures), and additional time spent in the operating room. One large study, evaluating intraoperative CBCT, reported an additional 15 minutes per case on average, with some of the more inexperienced surgeons reporting an additional 30 minutes per scan.<sup>14</sup> Clearly, the cumulative cost of the extra time in the operating room and the extra exposure to anesthesia could become prohibitive if multiple scans are needed for a given procedure. This fact is confirmed in our own experience: our first procedure on the index patient without the use of intraoperative imaging required less time in the operating room than the second procedure, in which the CBCT scanner was used.

To mitigate the challenges associated with intraoperative imaging, the use of intraoperative CBCT scan should be reserved as a tool only to aid in the reduction of complex or secondary ZMC repositioning after a failure of conventional techniques rather than for all cases. In the case of the patient presented above, by the time of her most recent operation, her anatomic landmarks were completely lost in the setting of 2 previous surgical procedures. Despite our best efforts, her postoperative CT scan demonstrated an incomplete reduction of her zygoma after our first attempt for repair. With the usage of intraoperative CT scan, we were able to definitively correct her deformities, which potentially would have otherwise proven impossible.

## CONCLUSION

Although the use of intraoperative CT scan might improve the accuracy of ZMC positioning and

decrease the chances of potential additional surgeries, concerns over cost, additional OR time, and often unnecessary radiation exposure should limit its usage to patients with distorted anatomic landmarks from panfacial fractures and those undergoing revisional repairs.

**Edward J. Caterson, MD, PhD**

Division of Plastic Surgery  
Department of Surgery  
Brigham and Women's Hospital  
Harvard Medical School, 75 Francis Street  
Boston, MA 02115  
E-mail: [ecaterson@partners.org](mailto:ecaterson@partners.org)

### REFERENCES

- van den Bergh B, Karagozoglu KH, Heymans MW, et al. Aetiology and incidence of maxillofacial trauma in Amsterdam: a retrospective analysis of 579 patients. *J Craniomaxillofac Surg.* 2012;40:e165–e169.
- van Hout WM, Van Cann EM, Abbink JH, et al. An epidemiological study of maxillofacial fractures requiring surgical treatment at a tertiary trauma centre between 2005 and 2010. *Br J Oral Maxillofac Surg.* 2013;51:416–420.
- Forouzanfar T, Salentijn E, Peng G, et al. A 10-year analysis of the “Amsterdam” protocol in the treatment of zygomatic complex fractures. *J Craniomaxillofac Surg.* 2013;41:616–622.
- Salentijn EG, Boverhoff J, Heymans MW, et al. The clinical and radiographical characteristics of zygomatic complex fractures: a comparison between the surgically and non-surgically treated patients. *J Craniomaxillofac Surg.* 2013;4:214–218.
- Wilde F, Lorenz K, Ebner AK, et al. Intraoperative imaging with a 3D C-arm system after zygomatico-orbital complex fracture reduction. *J Oral Maxillofac Surg.* 2013;71:894–910.
- Heiland M, Schulze D, Blake F, et al. Intraoperative imaging of zygomaticomaxillary complex fractures using a 3D C-arm system. *Int J Oral Maxillofac Surg.* 2005;34:369–375.
- Hoffmann J, Krimmel M, Dammann F, et al. [Feasibility of intraoperative diagnosis with a mobile computed tomography scanner]. *Mund Kiefer Gesichtschir.* 2002;6:346–350.
- Stanley RB Jr. Use of intraoperative computed tomography during repair of orbitozygomatic fractures. *Arch Facial Plast Surg.* 1999;1:19–24.
- Gülicher D, Krimmel M, Reinert S. The role of intraoperative ultrasonography in zygomatic complex fracture repair. *Int J Oral Maxillofac Surg.* 2006;35:224–230.
- van den Bergh B, Goey Y, Forouzanfar T. Postoperative radiographs after maxillofacial trauma: sense or nonsense? *Int J Oral Maxillofac Surg.* 2011;40:1373–1376.
- van Hout WM, Van Cann EM, Muradin MS, et al. Intraoperative imaging for the repair of zygomaticomaxillary complex fractures: a comprehensive review of the literature. *J Craniomaxillofac Surg.* 2014;42:1918–1923.
- Jank S, Siegfried J, Deibl M, et al. Interrater reliability of sonographic examinations of orbital fractures. *Eur J Radiol.* 2005;54:344–351.
- Jenkins CN, Thuau H. Ultrasound imaging in assessment of fractures of the orbital floor. *Clin Radiol.* 1997;52:708–711.
- Shaye DA, Tollefson TT, Strong EB. Use of intraoperative computed tomography for maxillofacial reconstructive surgery. *JAMA Facial Plast Surg.* 2015;17:113–119.