

Risk of Lower Eyelids Malposition in Subciliary Compared to Transconjunctival Approach in Maxillofacial Fractures Management: A Systematic Review and Meta-Analysis

I Gusti Putu Hendra Sanjaya¹, Agus Roy Rusly Hariantana Hamid¹, I Made Suka Adnyana¹, I Gusti Ayu Putri Purwanthi^{1*}, Paulina Magdalena¹, Putu Eka Mardhika²

¹Division of Plastic, Reconstructive and Aesthetic, Department of Surgery, Faculty of Medicine, Udayana University, Sanglah General Hospital, Bali, Indonesia; ²Department of Neurosurgery, Faculty of Medicine, Udayana University, Sanglah General Hospital, Bali, Indonesia

Abstract

Citation: Sanjaya IGPH, Hamid RRH, Adnyana IMS, Purwanthi IGAP, Magdalena P, Mardhika PE. Risk of Lower Eyelids Malposition in Subciliary Compared to Transconjunctival Approach in Maxillofacial Fractures Management: A Systematic Review and Meta-Analysis. Open Access Maced J Med Sci. 2019 Sep 15; 7(17):2953-2957. https://doi.org/10.3889/oamjms.2019.726

Keywords: Lower eyelids malposition; Subciliary; Transconjunctival; Maxillofacial fractures

***Correspondence:** I Gusti Ayu Putri Purwanthi, Division of Plastic, Reconstructive and Aesthetic, Department of Surgery, Faculty of Medicine Udayana University / Sanglah General Hospital, Bali, Indonesia. E-mail: purwanthiputri@gmail.com

Received: 31-May-2019; **Revised:** 23-Jul-2019; **Accepted:** 24-Jul-2019; **Online first:** 30-Aug-2019

Copyright: © 2019 I Gusti Putu Hendra Sanjaya, Agus Roy Rusly Hariantana Hamid, I Made Suka Adnyana, I Gusti Ayu Putri Purwanthi, Paulina Magdalena, Putu Eka Mardhika. This is an open-access article distributed under the terms of the Creative Commons Attribution-NonCommercial 4.0 International License (CC BY-NC 4.0)

Funding: This research did not receive any financial support

Competing Interests: The authors have declared that no competing interests exist

Abbreviations: PICO = Patients, Intervention, Comparator, Outcome; ORIF = Open Reduction Internal Fixation; DOAJ = Directory of Open Access Journal; RR = Risk Ratio; JBI = Joanna Briggs Institute; PRISMA = Preferred Reporting Items for Systematic Review and Meta-Analyses; RCT = Randomized Control Trial; Ec = Ectropion; En = Entropion; ZMC = Zygomaticomaxillary Complex; CI = Confidence Interval

BACKGROUND: Both subciliary and transconjunctival approaches have been used for decades to visualise the site of the maxillofacial fracture. The most common complication following those procedures is lower eyelids malposition.

AIM: This meta-analysis will analyse which approach (subciliary and transconjunctival approaches) is more favourable to decrease lower eyelids malposition incidence.

METHOD: This meta-analysis was conducted based on PRISMA guidelines. The electronic search was conducted using keywords ("Lower Eyelids Malposition" OR "Complications" OR "Ectropion" OR "Entropion") AND (Transconjunctival) AND (Subciliary) AND (Maxillofacial Fractures) in PubMed, The Cochrane Library, and Directory of Open Access Journal (DOAJ). This review included full-text studies (observational and randomised controlled trials) in English comparing subciliary and transconjunctival approach in patients with maxillofacial fractures in the last 10 years. The data collected were the type of fractures and approaches, ectropion and entropion incidence as well as follow-up duration. The risk of bias was assessed using Joanna Briggs Institute critical appraisal checklist. Statistical analysis was done using Review Manager 5.3 (Cochrane, Denmark).

RESULT: This study included 3 cohort studies and 2 Randomized Controlled Trial (RCT) studies from 2012 to 2017 with a total of 574 samples. Subciliary approach had a significant higher ectropion incidence when compared to transconjunctival approach (RR = 4.64, 95% CI: 1.68-12.81, p = 0.003). There was also a significant reduction of entropion incidence in patients with subciliary approach compared to transconjunctival approach (RR = 0.16, 95% CI: 0.04 – 0.69, p = 0.01).

CONCLUSION: There was no superiority between one procedure toward another since each procedure related to different lower eyelids malpositions.

Introduction

Maxillofacial fractures is a common entity in the urban setting that rarely life-threatening. Despite the impact on physiologic function, maxillofacial fractures may also have an unfavourable effect on facial aesthetics of the trauma victim. Challenges in the comprehensive management of facial bone fractures are not only how to achieve a physiologic union of the bones, but also to manage all of the effects caused by the broken bones [1], [2].

Different approaches have been developed especially to access the infraorbital rim and the orbital floor to fix the fractures [3]. The conventional approaches including cutaneous infraciliary or subciliary incisions, mid-lower eyelid or subtarsal and infraorbital incisions. These conventional techniques produce a scar which may be cosmetically unfavourable. Transconjunctival incisions is an alternative technique that provides adequate exposure of the bone and avoids the visible scar at the same time because the incision that made through the conjunctiva [4].

Both subciliary and transconjunctival approaches have been used for decades. The most common complications following those procedures are lower eyelids malposition comprises of ectropion, entropion and scleral show. Ectropion is the most frequent problem results in aesthetically and functionally disturbances of the eyes such as outdoor runny eyes. Entropion can also result in pain as the cilia can irritate the cornea of the patients [1], [5].

Given the frequency and associated morbidity of the lower eyelids malposition, identifying approaches to minimise the unwanted complication may be an important contribution to enhance the treatment outcome. This study presented a systematic review and meta-analysis using the available evidence to understand further which one of two surgical approaches (subciliary and transconjunctival) is more favourable focusing in terms of lower eyelids malposition risk (ectropion, entropion).

Methods

Eligibility criteria

Eligibility criteria were created based on the PICO framework. PICO criteria can be seen in Table 1.

Table 1: PICO criteria of the study

Patient	Maxillofacial Fractures
Intervention	Subciliary Incision
Comparator	Transconjunctival Incision
Outcome	Lower Eyelids Malposition

Type of studies

This review included full-text studies in English comparing subciliary and transconjunctival approach in patients with maxillofacial fractures in the last 10 years. We exclude case report, review, animal, anatomic, cadaveric, qualitative and economic studies. Studies that do not report the information required for performing a meta-analysis were excluded. Articles made by the same author in the same institution were performed sample evaluation to prevent sample duplication.

Type of participants

This review included studies with patients of all ages and gender who underwent Open Reduction Internal Fixation (ORIF) for maxillofacial fractures management with subciliary and transconjunctival approach. Maxillofacial fractures refer to any injury that results in a broken bone or bones of the face that required subciliary or transconjunctival incision to reach the site of the fracture.

Type of interventions

The reviewed surgical interventions were subciliary approach in comparison to the transconjunctival approach for maxillofacial fractures management. In this context, the preseptal or septal transconjunctival incision with or without lateral canthotomy was included. All of the subciliary incision techniques were also included in this study (the skin only type, skin-muscle type and stepped technique).

Type of outcomes

The results investigated in this review was lower eyelids malposition. Lower eyelid malposition was defined as abnormal positioning of lower eyelids that were observed post-operatively before any treatment or correction is given to reduce the complications. The types of abnormalities included were ectropion and entropion.

Information sources

We extracted the eligibility criteria (PICO) into keywords using Boolean operator. In this study, we used keywords ("Lower Eyelids Malposition" OR "Complications" OR "Ectropion" OR "Entropion") AND (Transconjunctival) AND (Subciliary) AND (Maxillofacial Fractures) in PubMed database, The Cochrane Library and Directory of Open Access Journal (DOAJ) as search engine to find eligible journals.

Study selection

The study selection process was conducted by three authors (PP, PM and EM) to reduce the possibility of disposing of relevant studies. The decision of the first, second and third author was considered when disagreement occurred. The study selection began with the removal of duplicate records. The irrelevant studies then excluded by screening the titles and abstracts. Studies that passed the first screening were further evaluated for the compliance of the inclusion and exclusion criteria of this review. Finally, the studies were further evaluated for their quality before eventually included.

Data collection process

Electronic data collection form was used to collect data from each author. The collected data by each author was merged and managed with software Review Manager 5.3.

Data items

The data items were the author's name, year of publication, type of study, sample size, type of

fractures, surgical approaches, lower eyelids malposition incidence, and follow – up duration. Lower eyelids malposition incidence was calculated for risk ratio (RR) and were performed the meta-analysis.

Assessment of quality of study

Studies that complied with inclusion and exclusion criteria are assessed for their quality to ensure the validity and reliability of the studies. This process was done independently by two authors (PP and PM) using a standardised critical appraisal tool to minimise the possibility of bias in study selection. The critical appraisal tool in this study was the Joanna Briggs Institute (JBI) critical appraisal tool based on study design. The decision of the first, second and third author was used when disagreement occurred. Cut off point was defined to determine the quality of the study. Cut off point in this review was half of the total score in each JBI critical appraisal checklist. The low-quality study was defined as a score below the cut-off point while otherwise referred to as high-quality study.

Synthesis of result

The RR of lower eyelid malposition were pooled and analysed. Meta-analysis was conducted using software Review Manager 5.3.

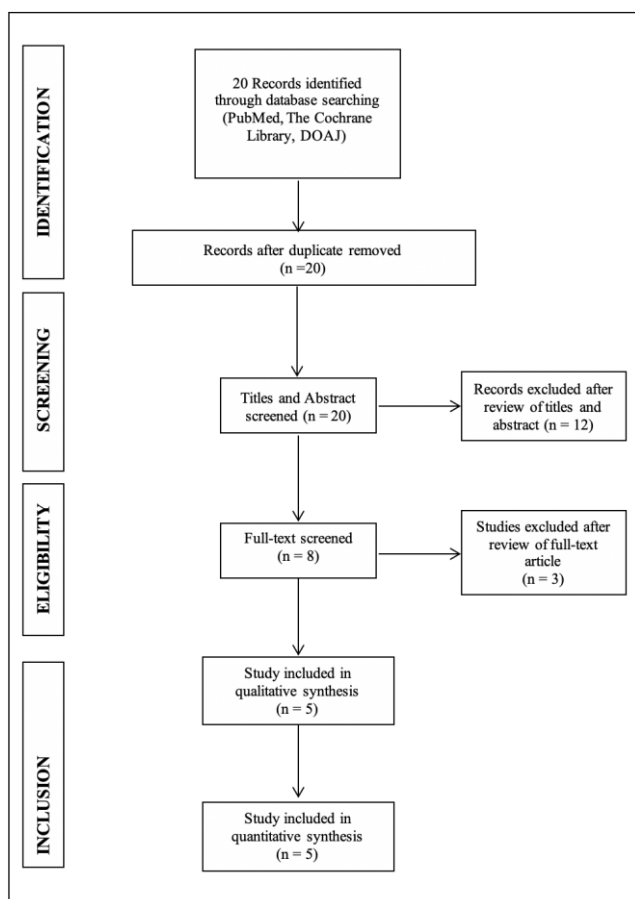


Figure 1: PRISMA Flow Diagram

Results

Study Selection

Using the initial search strategy, we found a total of 20 studies. Based on the title and abstract screening, we excluded 12 articles. That left us 8 relevant studies. Studies that didn't provide all the information needed in this meta-analysis were excluded. After screening and qualitative evaluation were done, we finally have 5 articles that further used in this study. PRISMA study flow diagram is described in Figure 1.

Study Characteristics

We included 5 full-text articles which are 2 retrospective cohort studies, 1 prospective cohort studies and 2 Randomized Control Trial (RCT). The publication year of these articles varied between 2012 to 2017 with a total of 574 samples included. The summary of finding and studies characteristics can be seen in Table 2.

Table 2: Summary of Findings and Studies Characteristics

Author	Type of Study	Level of Evidence	Fractures Type	Intervention (n)	Outcome (n)	Control (n)	Outcome (n)	Follow Up
Giraddi et al. (2012) [4]	Prospective Cohort	2a	Orbital Floor and Rim Fractures	Subciliary Skin Muscle Flap (10)	Ec: 3 En: 0	Perceptual Transconjunctival with Lateral Canthotomy (10)	Ec: 1 En: 3	3 Months
Pausch et al. (2015) [5]	Retrospective Cohort	2b	Orbital Floor Fractures	Subciliary Skin Muscle Flap (225)	Ec:12 En: 0	Transconjunctival (121)	Ec:1 En:5	6 Months
Vaibhav et al. (2015) [6]	RCT	1b	Infraorbital Rim Fractures	Subciliary (20)	Ec:2 En:0	"Sutureless" Preseptal Transconjunctival (20)	Ec:0 En:1	3 Months
Neovius et al. (2016) [3]	Retrospective Cohort	2b	Facial Fractures	Subciliary (37)	Ec:3 En:0	Transconjunctival (91)	Ec:2 En:0	6 Months
El-Anwar et al. (2017) [7]	RCT	1b	ZMC Fractures	Subciliary (20)	Ec:2 En:0	Transconjunctival with Lateral Canthotomy (20)	Ec:0 En:4	6 Weeks

Ec: Ectropion; En: Entropion.

Risk of bias within studies

The risk of bias was analysed using JBI critical appraisal tool for cohort and RCT studies. All 5 articles included in this study were passed the quality evaluation. Complete result of bias risk was described in Table 3.

Table 3: Risk of Bias Summary

Study (Year)	Question no.													Total
	1	2	3	4	5	6	7	8	9	10	11	12	13	
Reviewer: PP														
Giraddi et al. (2012)	Y	Y	Y	Y	N	Y	Y	Y	Y	N	Y			9/11
Pausch et al. (2015)	Y	Y	Y	Y	Y	N	Y	Y	N	Y				9/11
Vaibhav et al. (2015)	Y	Y	Y	Y	N	N	Y	Y	Y	Y	Y	Y	Y	11/13
Neovius et al. (2016)	Y	Y	Y	N	N	Y	Y	Y	N	Y				8/11
El-Anwar et al., (2017)	Y	Y	Y	Y	N	N	Y	N	Y	Y	Y	Y	Y	10/13
Reviewer: PM														
Giraddi et al., (2012)	Y	Y	Y	Y	Y	Y	Y	Y	N	Y				10/11
Pausch et al. (2015)	Y	Y	Y	Y	Y	Y	Y	Y	N	Y				10/11
Vaibhav et al. (2015)	Y	Y	Y	Y	N	N	Y	Y	Y	Y	Y	Y	Y	11/13
Neovius et al. (2016)	Y	Y	Y	Y	Y	Y	Y	Y	N	Y				10/11
El-Anwar et al., (2017)	Y	Y	Y	Y	N	N	Y	Y	Y	Y	Y	Y	Y	11/13

Ectropion

As shown in Figure 2, incidence of ectropion between subciliary and transconjunctival approach were 7.0% and 1.5%, respectively. Based on fixed effect model with low heterogeneity ($I^2 = 0\%$; $\chi^2 = 0.34$; $p = 0.99$), pooled risk ratio between subciliary and transconjunctival approach on ectropion incidence was 4.64 ($p = 0.003$; 95% CI: 1.68-12.81).

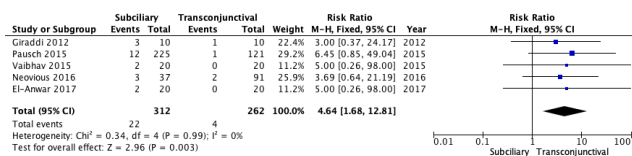


Figure 2: Forest plot comparing subciliary and transconjunctival approach on ectropion incidence

Entropion

As shown in Figure 3, the incidence of entropion in the transconjunctival group was 4.7% while there was no event in subciliary group. We excluded study by Neovius *et al.* in the analysis due to ectropion incidence absence in both subciliary and transconjunctival group. Based on fixed effect model with low heterogeneity ($I^2 = 0\%$; $\chi^2 = 0.28$; $p = 0.96$), pooled risk ratio between subciliary and transconjunctival approach on entropion incidence was 0.16 ($p = 0.01$; 95% CI: 0.04 – 0.69).

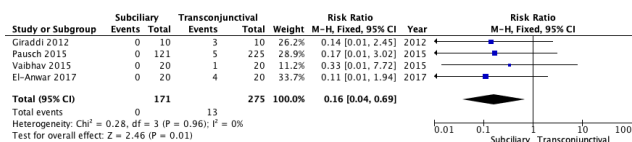


Figure 3: Forest plot comparing subciliary and transconjunctival approach on entropion incidence

Discussion

This study aimed to compare the frequencies of lower eyelids malposition including ectropion and entropion after the use of subciliary or transconjunctival approach in maxillofacial fractures management. Subciliary approach is usually made by a few millimetres' parallel incision below the ciliary line from medial punctum to the lateral canthus. There are three types of subciliary incision comprise of the skin only type, skin-muscle type and stepped technique. The transconjunctival approach is made by eversion of the inferior lid while conjunctiva is incised below the tarsus. The incision then continued to the orbital rim in a preseptal or retroseptal technique [8]. Using transconjunctival incision with a lateral canthotomy for infraorbital rim and floor fractures give wider exposure of the entire lower orbital rim and zygoma [4].

In this study, the incidence of ectropion between subciliary and transconjunctival approach were 7.0% and 1.5%, respectively. This result is consistent with all of the studies in this review that stated the subciliary approach was significantly associated with the higher rates of ectropion and the lower rates of entropion. Most of the studies included in this study concluded that there was no superior technique between approaches, except one study that favoured the transconjunctival approach due to its overall minimum complications. This study also showed that each approach is associated with different complication where pooled risk ratio of the ectropion in subciliary group was 4.64 ($p < 0.05$) and the pooled risk ratio of the entropion in subciliary group was 0.16 ($p < 0.05$). In the other hand, the incidence of ectropion in the transconjunctival group was 3.5% while there was no event in subciliary group. These findings are also by a meta-analysis by Ridgway *et al.*, showing that the risk of ectropion was highest in subciliary incisions (14%) compared with subtarsal (3.8%) and transconjunctival incisions (1.5%) ($P < 0.001$) [9]. The possible underlying mechanism of postoperative ectropion and entropion is scarring at the anterior and middle lamella of the eyelid after a subciliary incision while post-operative scar of the posterior lamella can occur after the transconjunctival incision. By the time the scar becomes mature, it can create the outward retraction in the former and the inward retraction in the latter [1], [2], [5].

Pausch *et al.*, used a skin muscle flap for the subciliary approach instead of skin-only technique because the later technique is more susceptible to soft tissue complication [5]. The skin – only type involves the skin dissection from the orbicularis oculi muscle, is often linked with a higher risk of several complications such as cutaneous necrosis, ecchymosis, and ectropion [8]. Subciliary incision that is made too close to the lid margin can increase the risk of ectropion and epiphora while a visible scar and massive oedema caused by lymphatic drainage impairment can happen if the incision is placed too far from the lid margin [10], [11].

In contrast to the subciliary approach, the conjunctival incision results in less conspicuous scar except in the skin lateral to the lateral canthus [10], [12], [13]. The transconjunctival approach doesn't emphasise in the involvement of the lower eyelid skin and orbicularis oculi muscle so that reduced the risk for postoperative lower eyelid retraction, scleral show, and ectropion. In this review, most studies performed transconjunctival incision with lateral canthotomy to get enough exposure and visibility [2]. Despite its cosmetic advantages, the main disadvantages of this approach are its technique sensitivity, a relatively limited exposure when used alone but relatively higher rates of lower eyelid malposition when combined with a lateral canthotomy [3]. A study by Neovius *et al.* described that when combined with lateral

canthotomy, a transconjunctival approach often result in canthal malposition that needs surgery correction (2.2%). Therefore, they performed a transconjunctival approach to reduce the risk of ectropion and scleral show without lateral canthotomy as much as possible to eliminate Chantal malposition risk on their practice [4].

Because of its every advantage and disadvantages, most studies recommend using both approaches interchangeably depends on the surgeon as well as an individual patient basis. The subciliary approach gives wider exposure of the infraorbital rim and is better used to repair extensively displaced fractures. The transconjunctival approach gives better aesthetic results and less overall postoperative complications but requires an additional lateral canthotomy in cases extension of exposure needed [6].

The limitation of this review is the limited number of randomised controlled trial study (2 studies). Cohort study might be susceptible to some biases including selection, confounding, and information biases. Some studies also acknowledge the limited number of samples in their studies and the possibility of bias due to different surgical operators and outcome evaluators. Also, the search strategy of this review possibly missed other relevant articles to be included in the analysis.

In conclusion, there was no superiority between one procedure toward another since each procedure related to different complication. More prospective studies should be done to determine the best approaches with their modification in preventing lower eyelid malposition in maxillofacial fractures management.

Reference

1. Sharabi SE, Koshy JC, Thornton JF, Hollier LH. Facial fractures. *Plast Reconstr Surg.* 2011; 127:25e-34e. <https://doi.org/10.1097/PRS.0b013e318200cb2d> PMID:21285753
2. Louis M, Agrawal N, Kaufman M, Truong TA. Midface fracture I. *Semin Plast Surg.* 2017; 31:85-93. <https://doi.org/10.1055/s-0037-1601372> PMID:28496388 PMCid:PMC5423805
3. Neovius E, Clarliden S, Farnemo F, Lundgren TK. Lower eyelid complications in facial fracture surgery. *J Craniofac Surg.* 2017; 28:391-393. <https://doi.org/10.1097/SCS.00000000000003314> PMID:28027188
4. Giraddi GB, Syed MK. Giraddi GB, Syed MK. Preseptal transconjunctival vs. subciliary approach in treatment of infraorbital rim and floor fractures. *Ann Maxillofac Surg.* 2012; 2:136-40. <https://doi.org/10.4103/2231-0746.101338> PMID:23482434 PMCid:PMC3591055
5. Pausch NC, Srintawat N, Wagner R, Halama D, Dhanuthai K. Lower eyelid complications associated with transconjunctival versus subciliary approaches to orbital floor fractures. *Oral Maxillofac Surg.* 2015; 20(1):51-55. <https://doi.org/10.1007/s10006-015-0526-1> PMID:26337055
6. Vaibhav N, Madan RK, Ashwin NDP. Comparison of "sutureless" transconjunctival and subciliary approach for treatment of infraorbital rim fractures: a clinical study. *J Maxillofac Oral Surg.* 2016; 15(3):355-62. <https://doi.org/10.1007/s12663-015-0835-9> PMID:27752207 PMCid:PMC5048312
7. El-Anwar MW, Elsheikh E, Hussein AM, Tantawy AA, Abdelbaki YM. Transconjunctival versus subciliary approach to the infraorbital margin for open reduction of zygomaticomaxillary complex fractures: a randomized feasibility study. *Oral Maxillofac Surg.* 2017; 21(2):187-192. <https://doi.org/10.1007/s10006-017-0617-2> PMID:28316023
8. Haghghat A, Moaddabi A, Soltani P. Comparison of subciliary, subtarsal and transconjunctival approaches for management of zygomaticoorbital fractures. *BJMMR.* 2017; 20(4):1-9. <https://doi.org/10.9734/BJMMR/2017/31843>
9. Ridgway EB, Chen C, Colakoglu S, Gautam S, Lee BT. The incidence of lower eyelid malposition after facial fracture repair: a retrospective study and meta-analysis comparing subtarsal, subciliary, and transconjunctival incisions. *Plastic and Reconstructive Surgery.* 2009; 124(5):1578-86. <https://doi.org/10.1097/PRS.0b013e3181babb3d> PMID:20009844
10. Motamed al Shariati SM, Dahmardeh Zahedan M, Ravari H. Subciliary approach for inferior orbital rim fractures; case series and literature review. *Bull Emerg Trauma.* 2014; 2(3):121-124.
11. Ben Simon GJ, Molina M, Schwarcz RM, McCann JD, Goldberg RA. External (subciliary) vs internal (transconjunctival) involutional entropion repair. *Am J Ophthalmol.* 2005; 139(3):482-7. <https://doi.org/10.1016/j.ajo.2004.10.003> PMID:15767057
12. Subramanian B, Krishnamurthy S, Suresh Kumar P, Saravanan B, Padhmanabhan M. Comparison of various approaches for exposure of infraorbital rim fractures of zygoma. *J Maxillofac Oral Surg.* 2009; 8(2):99-102. <https://doi.org/10.1007/s12663-009-0026-7> PMID:23139484 PMCid:PMC3453937
13. Kothari NA, Avashia YJ, Lemelman BT, Mir HS, Thaller SR. Incisions for orbital floor exploration. *J Craniofac Surg.* 2012; 23(7 Suppl 1):1985-9. <https://doi.org/10.1097/SCS.0b013e31825aaa03> PMID:23154363