

CASE REPORT

Disseminated histoplasmosis with oral and cutaneous manifestations

S Vidyanath, PM Shameena, S Sudha, Resmi G Nair

Department of Oral and Maxillofacial Pathology, Government Dental College, Calicut, India

Address for correspondence:

Dr. S Vidyanath,
Department of Oral and Maxillofacial Pathology,
Government Dental College, Calicut, India.
E-mail: drvidyanath@gmail.com

ABSTRACT

Histoplasmosis is a systemic mycotic infection caused by the dimorphic fungus, *Histoplasma capsulatum*. Systemic histoplasmosis has emerged as an important opportunistic infection in human immunodeficiency virus (HIV) patients and those in endemic areas. Reported cases of histoplasmosis have been low in India with less than 50 cases being reported. We are reporting a case of disseminated histoplasmosis with oral and cutaneous involvement in an HIV seronegative patient.

Key words: Disseminated, histoplasmosis, human immunodeficiency virus

INTRODUCTION

Histoplasmosis is a systemic mycotic infection caused by the dimorphic fungus, *Histoplasma capsulatum*. It develops as a branching hyphal form in the soil and assumes a yeast form in the host tissue.^[1] The organism is commonly found in warm, humid environment that contains bird and bat excreta. *H. capsulatum* is acquired by inhalation of mycelial fragments of the fungus. Histoplasmosis is endemic in the central eastern united states, especially the Ohio and Mississippi River Valleys, in Central and South America, and Africa, but is less frequently reported in Asia and Europe.^[2,3] Reported cases of histoplasmosis have been low in India with less than 50 cases being reported.^[2,4]

Histoplasmosis may occur in three forms: (i) Primary acute pulmonary form, (ii) chronic pulmonary and (iii) disseminated form.^[5] In human immunodeficiency virus (HIV) positive patients, 95% of histoplasmosis appears as disseminated infection.^[3] Occurrence of disseminated form of histoplasmosis is rare in HIV seronegative patients. The disease is rarely fatal and usually manifests as self-limited pneumonia. However, in immune deficiency situations, it could be widespread and potentially fatal.

The manifestations of disseminated form of histoplasmosis are fever, weakness, weight loss, hepatosplenomegaly, and

mucocutaneous lesions.^[3] The oral lesions may occur in any part of the oral cavity and the lesions vary from nodules to painful shallow or deep ulcers.^[3] The incidence of oral manifestation is 25-45% in the disseminated form of the disease.^[1]

Skin lesions of histoplasmosis are lesser than 10% in the USA but it had occurred in 38-85% of reported cases in Latin America. Skin lesions range from papules and plaques with or without crusts, pustules and nodules to mucosal ulcers and erosions, molluscum contagiosum-like lesions, acneiform eruptions, erythematous papules and keratotic plaques.^[6] In this article we are reporting a case of disseminated histoplasmosis with oral and cutaneous involvement in an HIV seronegative patient.

CASE REPORT

A 73-year-old man was referred from a private practitioner to Govt. Dental College, Calicut with ulcers in his oral cavity, fever, chest pain and cough since 2 weeks and he also noticed skin lesions over face and forearm.

Oral examination revealed ulcerated and necrotic lesions located on the labial mucosa, lateral borders of tongue, hard and soft palate [Figures 1a and b]. The lesions were covered by a pseudomembrane and were extremely painful to palpation. Bilateral submandibular lymphadenopathy was noted. Extraoral examination revealed multiple nodular lesions on the chin, right side of the face and upper lip with an erythematous surface [Figure 1c]. Hair loss was noticed on the chin, upper lip and the eyebrows. Multiple plaques were seen on the ventral surface of the forearm and dorsal aspect of thigh [Figures 1d and e]. They were pale in color compared to the surrounding skin and there was a

Access this article online**Quick Response Code:**

Website:
www.jomfp.in

DOI:
10.4103/0973-029X.110722

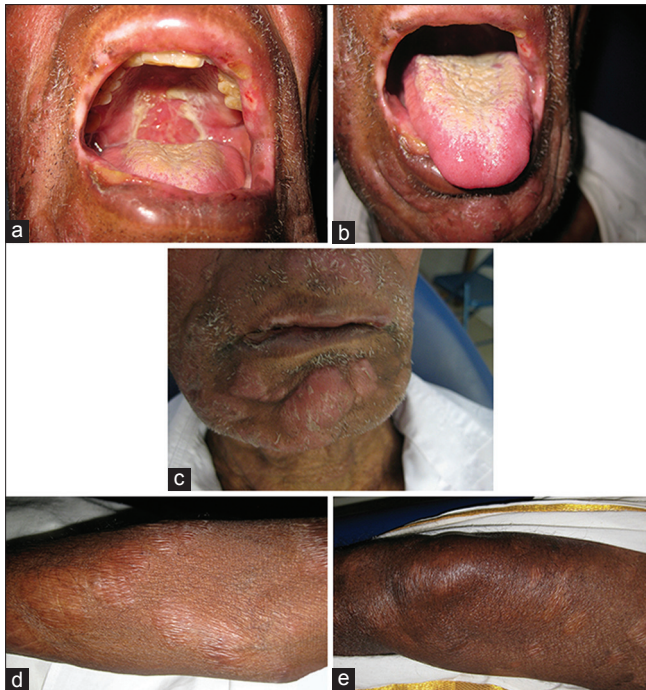


Figure 1: (a) Intraoral examination shows ulcerated and necrotic lesions, (b) Intraoral examination shows coating of the tongue, (c) Extraoral examination shows multiple nodular lesions on the chin, right side of the face and upper lip with an erythematous surface, (d) Multiple plaques like areas on the ventral surface of the forearm, (e) Multiple plaques like areas on the dorsal aspect of thigh

rise in local temperature. A firm consistency was felt while palpating these lesions.

The patient had malaise and fatigue at the time of examination, with a body temperature of 38.2°C, pulse rate of 82/min, respiratory rate of 18 cycles/min and blood pressure of 140/86 mm/Hg. Routine blood investigation showed a hemoglobin level of 9.4 g/dl, 7800 leucocytes (60% neutrophils, 36% lymphocytes and 4% eosinophils) and an elevated erythrocyte sedimentation rate (24 mm/h). Acid fast bacillus (AFB) examination of sputum did not reveal any acid fast bacilli (Zeihl Neelson stain)

An incisional biopsy of the labial mucosa showed the presence of epithelioid cell granulomas in the connective tissue with numerous histiocytes, many of which formed multinucleated giant cells. The cytoplasm of the histiocytes showed the presence of small round to oval basophilic bodies surrounded by a clear halo, which is the characteristic feature of *histoplasma capsulatum* [Figures 2a-c]. These organisms stained highly positive with Gomori's Methanamine Silver stain [Figures 3a and b]. The patient was found to be HIV negative (comb and tridot tests).

Antifungal therapy was started with intravenous liposomal amphotericin B at 0.7 mg/kg/day administered for 10 days which was replaced by oral itraconazole 200 mg BD for 6 months. Patient's respiratory symptoms showed marked improvement

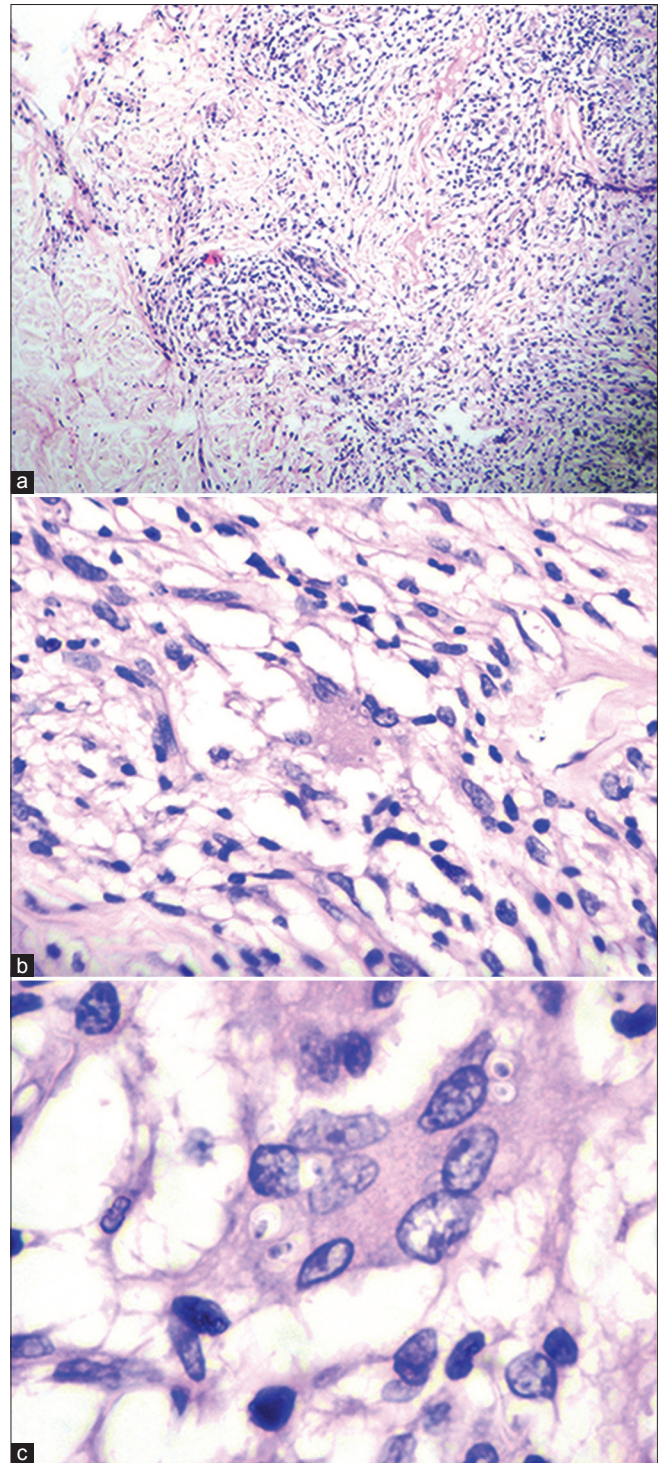


Figure 2: (a) Histopathology shows presence of epithelioid cell granulomas in the connective tissue with numerous histiocytes and multinucleated giant cells. The cytoplasm of the histiocytes shows the presence of small round to oval basophilic bodies surrounded by a clear halo (H and E, ×40), (b) Small round to oval basophilic bodies surrounded by a clear halo is seen in the cytoplasm of histiocytes (H and E, ×100), (c) High power view of the same field (H and E, ×400)

after 3 days of medication. The oral and cutaneous lesions resolved after 2 months. Patient is under regular follow up and was free of symptoms at the end of 1 year.

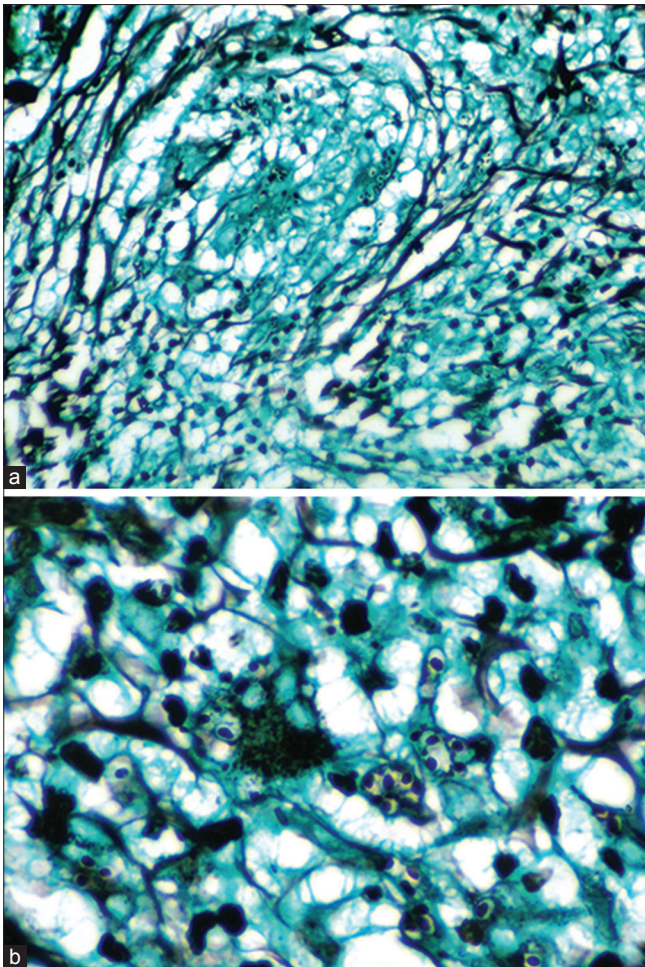


Figure 3: (a) Round to oval basophilic bodies surrounded by a clear halo in the histiocytes (Gomori's methanamine silver, $\times 100$), (b) High power view of the same field (GMS, $\times 400$)

DISCUSSION

Systemic histoplasmosis has emerged as an important opportunistic infection among patients with HIV and those in endemic areas. While the illness is subclinical or presents as a mild self-limited pulmonary infection in healthy individuals, the majority of cases involving acquired immunodeficiency syndrome and immunocompromised patients show signs of a life-threatening disseminated infection.^[7]

The main risk factors for disseminated histoplasmosis are exposure to sites which harbor high levels of *H. capsulatum*, like chicken coops, bird roosts, caves and building sites and a simultaneous advanced immunosuppression.^[8] The patient in our case report was working as a carpenter in a building site and he was handling damp logs of wood stored in the adjacent river. The cause of immunosuppression could be old age and chronic alcoholism.

In non-endemic areas, where clinical suspicion is low and standard diagnostic tests for histoplasmosis are not established, the correct diagnosis of disseminated histoplasmosis is usually

arrived at accidentally. It is important for physicians outside the endemic areas to identify the conditions associated with exposure to histoplasmosis, its clinical manifestations, approach to diagnosis and treatment.^[9]

Systemic histoplasmosis has various clinical presentations and is of special concern in immunocompromised patients. The clinical features simulate other systemic febrile illnesses and most of the times the initial diagnosis is either tuberculosis or malignancy.^[10] When it is involving the oral cavity, the most commonly involved sites are tongue, palate, buccal mucosa, gingiva and pharynx and the differential diagnoses should include squamous cell carcinoma, hematologic malignancy, tuberculosis, other deep fungal infections, oral lesions of Crohn's disease, necrotizing sialometaplasia of the palate and chronic traumatic ulcers.^[1] The palatal ulcers present in our case report resembled squamous cell carcinoma and also the patient had respiratory symptoms similar to tuberculosis.

Biopsy of a mucosal or cutaneous lesion might be the most rapid method of arriving at a specific diagnosis of disseminated histoplasmosis.^[11] This may allow for the rapid institution of life saving therapy, as culture may require up to a 4-week incubation period.

Histopathology is the prime investigative modality, as identification of histoplasma organism in the section provides conclusive evidence of the disease.^[12] In histopathology, the diagnostic feature of histoplasmosis is the presence of tiny 2-4 μm spores within the cytoplasm of macrophages and variably within giant cells. The spores of *H. capsulatum* are visualized in sections stained with hematoxylin and eosin and special stains like periodic acid schiff (PAS) or Giemsa stain. The spores appear as round or oval bodies surrounded by a clear space that was originally interpreted as a capsule, giving rise to the name *H. capsulatum*. Studies using silver impregnation techniques and electron microscopy showed that *H. capsulatum* does not possess a capsule. The inner portion of the clear space represents the cell wall of the fungus and the clear space itself is filled with granular material that separates the cell wall of the fungus from the cytoplasm of the macrophage.^[11] Microscopically, the differential diagnosis of histoplasmosis includes Leishmaniasis, *Penicillium marneffei*, *Cryptococci neoformans* and *Candida glabrata* infections. Leishmaniasis can be differentiated from histoplasmosis by the absence of a clear halo around spores. *Penicillium marneffei* is distinguished by the septate appearance of the yeast forms; replicate by binary fission, whereas *H. capsulatum* divides by budding.^[13] *Cryptococci* are encapsulated, spherical to oval yeasts that measure 5-10 μm in diameter as compared to *H. capsulatum*, which measures about 2-4- μm in diameter. *Candida glabrata* may show more size variability than in histoplasmosis.

Antifungal medications are used to treat severe cases of acute histoplasmosis and all cases of chronic and disseminated

disease. Amphotericin B is still the drug of choice for disseminated histoplasmosis.^[9] Patients who cannot tolerate amphotericin B, itraconazole is an effective and alternative therapy and it may be given as a prophylaxis for patients with advanced HIV infection.^[8,9]

In summary, histoplasmosis is a rare opportunistic infection in India, but it must be included in the differential diagnosis of ulcerative lesions in the oral cavity even in the non-endemic countries. Even though oral lesions of histoplasmosis are common in immunocompromised individuals; it may affect the immunocompetent also. Biopsy of the oral lesions might be the most rapid method of diagnosing histoplasmosis, thereby helps in arriving at an earlier diagnosis and prompt treatment.

REFERENCES

- Mignogna MD, Fedele S, Lo Russo L, Ruoppo E, Lo Muzio L. A case of oral localized histoplasmosis in an immunocompetent patient. *Eur J Clin Microbiol Infect Dis* 2001;20:753-5.
- Rappo U, Beitler JR, Faulhaber JR, Firoz B, Henning JS, Thomas KM, *et al.* Expanding the horizons of histoplasmosis: Disseminated histoplasmosis in a renal transplant patient after a trip to Bangladesh. *Transpl Infect Dis* 2010;12:155-60.
- Ferreira OG, Cardoso SV, Borges AS, Ferreira MS, Loyola AM. Oral histoplasmosis in Brazil. *Oral Surg Oral Med Oral Pathol Oral Radiol Endod* 2002;93:654-9.
- Viswanathan S, Chawla N, D'Cruz A, Kane SV. Head and neck histoplasmosis: A nightmare for clinicians and pathologists! Experience at a tertiary referral cancer centre. *Head Neck Pathol* 2007;1:169-72.
- Hernández SL, López De Blanc SA, Sambuelli RH, Roland H, Cornelli C, Lattanzi V, *et al.* Oral histoplasmosis associated with HIV infection: A comparative study. *J Oral Pathol Med* 2004;33:445-50.
- Cunha VS, Zampese MS, Aquino VR, Cestari TF, Goldani LZ. Mucocutaneous manifestations of disseminated histoplasmosis in patients with acquired immunodeficiency syndrome: Particular aspects in a Latin-American population. *Clin Exp Dermatol* 2007;32:250-5.
- Matulionyte R, Garbino J, Uçkay I, Lambert JF, Hirschel B. Disseminated histoplasmosis in an HIV-infected patient discovered by routine blood smear staining. *Eur J Clin Microbiol Infect Dis* 2005;24:361-3.
- Calza L, Manfredi R, Donzelli C, Marinacci G, Colangeli V, Chiodo F. Disseminated histoplasmosis with atypical cutaneous lesions in an Italian HIV-infected patient: Another autochthonous case. *HIV Med* 2003;4:145-8.
- Wheat LJ. Histoplasmosis: A review for clinicians from non-endemic areas. *Mycoses* 2006;49:274-82.
- Wang TL, Cheah JS, Holmberg K. Case report and review of disseminated histoplasmosis in South-East Asia: Clinical and epidemiological implications. *Trop Med Int Health* 1996;1:35-42.
- Elder DE, Elenitsas R, Johnson BL Jr, Murphy GF. *Fungal diseases. Lever's Histopathology of the Skin*. 9th ed. Philadelphia, PA: Lippincott Williams and Wilkins; 2005. p. 623-24.
- Patil K, Mahima VG, Prathibha Rani RM. Oral histoplasmosis. *J Indian Soc Periodontol* 2009;13:157-9.
- Golda N, Feldman M. Histoplasmosis clinically imitating cutaneous malignancy. *J Cutan Pathol* 2008;35:26-8.

How to cite this article: Vidyanath S, Shameena PM, Sudha S, Nair RG. Disseminated histoplasmosis with oral and cutaneous manifestations. *J Oral Maxillofac Pathol* 2013;17:139-42.

Source of Support: Nil. **Conflict of Interest:** None declared.