

Clinical and radiographic features of facial cosmetic materials: A systematic review

Noura Alsufyani^{1,2,*}, Reem Aldosary³, Rasha Alrasheed⁴, Mohammed Alsufyani⁵

¹Department of Oral and Maxillofacial Radiology, Oral Medicine and Diagnostic Sciences, College of Dentistry, King Saud University, Riyadh, Kingdom of Saudi Arabia

²Department of Medicine and Dentistry, School of Dentistry, University of Alberta, Canada

³General Dentist, Riyadh, Kingdom of Saudi Arabia

⁴Department of Oral Medicine and Pathology, Dental University Hospital, College of Dentistry, King Saud University, Riyadh, Kingdom of Saudi Arabia

⁵Department of Dermatology and Dermatologic Surgery, Prince Sultan Military Medical City, Riyadh, Kingdom of Saudi Arabia

ABSTRACT

Purpose: The aim of this study was to systematically screen the literature for studies reporting cosmetic material in the oral and maxillofacial complex to shed light on the types of cosmetic materials, their radiographic appearance, and possible complications.

Materials and Methods: Five electronic databases were reviewed for eligible studies. The general search terms were “cosmetic,” “filler,” “face,” and “radiograph.” Demographics, material types, clinical and radiographic presentation, and complications were recorded.

Results: Thirty-one studies with 53 cases met the inclusion criteria. The mean age was 52.6 ± 15.4 years with a 4 : 3 female-to-male ratio. The most common material was calcium hydroxyapatite (CaHa) (n = 14, 26.4%), found incidentally. The materials were generally located within the upper cheek and zygoma (n = 35, 66.0%), radiographically well-defined (n = 44, 83%), and had no effects on the surrounding structures (n = 27, 50.9%). The internal structure was radiopaque (calcification, hyperdensity) for gold wires, CaHa, bone implants, and secondary calcification or ossification. Outdated cosmetic materials or non-conservative techniques were infiltrative, had effects on the surrounding structures, and presented with clinical signs, symptoms, or complications.

Conclusion: Conventional radiography, cone-beam computed tomography, and multi-detector computed tomography are useful to differentiate several cosmetic materials. Their magnetic resonance imaging appearance was highly variable. The infrequent inclusion of cosmetic materials in the differential diagnosis implies that medical and dental specialists may be unfamiliar with the radiographic appearance of these materials in the face. (*Imaging Sci Dent* 2022; 52: 155-64)

KEY WORDS: Dermal Fillers; Diagnostic Imaging; Face; Systematic Review

Introduction

Cosmetic fillers now constitute the majority of facial rejuvenation procedures, and this will probably continue to be the case in the future.¹ With the increased demand for these aesthetic procedures, cosmetic fillers have become

widely available, and procedures using cosmetic fillers are performed not only by dermatologists and plastic surgeons, but also by dentists and maxillofacial surgeons.¹⁻³ Fillers can be permanent or temporary and made from different products and by many brands.⁴ The most commonly used materials are autologous fat, collagens, hyaluronic acid, and synthetic polymers.^{5,6} The technique of filler administration for soft tissue augmentation depends on multiple factors such as composition and longevity.⁴ Some materials are injected, while others are placed in a surgical procedure as implants.⁵

Received December 9, 2021; Revised January 15, 2022; Accepted January 15, 2022
Published online March 15, 2022

*Correspondence to : Prof. Noura Alsufyani
Building 10, College of Dentistry, King Saud University, Riyadh 12371, Saudi Arabia
Tel) 966-118052311, E-mail) alsufyan@ualberta.ca

Copyright © 2022 by Korean Academy of Oral and Maxillofacial Radiology

This is an Open Access article distributed under the terms of the Creative Commons Attribution Non-Commercial License (<http://creativecommons.org/licenses/by-nc/3.0>) which permits unrestricted non-commercial use, distribution, and reproduction in any medium, provided the original work is properly cited.

Imaging Science in Dentistry · pISSN 2233-7822 eISSN 2233-7830

Despite the safety of most of these filler materials, complications are not uncommon and similar to many medical procedures. Side effects can vary from mild foreign body reactions to severe complications.⁴ Some are inevitable, while other adverse effects can be avoided by strict adherence to proper techniques and guidelines.⁷ Thus, knowledge of the facial anatomy is essential for every practitioner, especially unlicensed providers.⁸

Many of the filler materials used for facial rejuvenation have different radiographic presentations, which can present a dilemma when discovered incidentally by practicing dentists.⁹ In some cases, differential diagnoses can lead to unnecessary investigations.¹⁰ This is especially true as some patients are reluctant to disclose a history of receiving cosmetic filler treatment. Therefore, it is imperative to update practitioners in light of these rapid changes to recognize these materials on medical imaging.

The main aim of this review was to systematically analyze the clinical and radiographic presentation of cosmetic fillers in the face. The secondary aim was to assess the features of materials presenting with complications.

Materials and Methods

This review was registered in PROSPERO, the International Prospective Register of Systematic Reviews (#CRD42020196750).

Following the Preferred Reporting Items for Systematic Reviews and Meta-Analyses (PRISMA) guidelines,¹¹ the 3 phases of the search were conducted as follows:

Phase I: identification and screening

The following databases were searched during June 2020 and updated in November: PubMed, Scopus, Web of Science, Embase via Ovid, and Google Scholar. The inclusion criteria were studies describing the radiographic appearance of cosmetic materials in the maxillofacial and mandibular region. Editorials/letters to the editor, reviews, and articles published prior to 1990 were excluded.

The keyword search for each database was conducted as follows: [cosmetic, filler, thread, augmentation, hyaluronic acid, injection, injected, dermal, gold wire], AND [face, facial, midface, maxilla, mandible, zygoma, zygomatic], AND [radiopacity, radiopacities, radiograph, radiographic, panoramic, cone beam, CBCT, CT, dental radiograph], NOT sinus. The keyword search for Google Scholar was as follows: cosmetic AND filler AND cosmetic AND implant AND dentistry AND face AND radiograph (all in title). The titles and abstracts of the articles were reviewed for inclu-

sion in the next phase.

Phase II: eligibility

The reviewers independently reviewed the full articles and applied the inclusion criteria. Using the references of the included articles, the reviewers completed a manual search for relevant articles possibly missed from the electronic search.

Phase III: included studies

The tool developed by Murad et al.¹² for methodological quality and risk of bias assessment was customized and used in this review. Specifically, questions #4, 5, 6 and 7 of the tool developed by Murad et al.¹² are relevant to cases of adverse drug events and, as such, were not used in this review. The reviewers collected information on demographic data, the type of cosmetic material, clinical presentation, imaging modality, radiographic features, differential diagnosis, reasons for imaging, and follow-up period for each study. Two reviewers (RM, RS) individually conducted the review. Consensus was reached between those reviewers, and the supervisor (NA) resolved any cases of disagreement.

Results

Database search

The PRISMA flowchart shows the total number of articles that were obtained from the systematic search (Fig. 1). A total of 398 articles resulted from the database search (n=319), manual search and Google Scholar (n=79). There were 55 duplicates, and 312 were excluded per the above-listed criteria or not retrieved. The final studies included were 31 articles published from 1990 to June to November 2022.

Quality assessment

Seventeen case reports, 6 retrospective analyses, 4 case series, and 4 prospective cohort studies were included in this review. Twelve articles received a score of 4, with an excellent presentation of the reported cases.^{10,13-23} Nineteen articles scored 3.5,^{9,20,24-39} primarily due to a lack of confirmation by a dermatologist or cosmetic surgeon of the history and type of procedure done.

Data analysis

There were 40 female patients (75.5%) and 13 male patients (24.5%), and the mean age was 52.6 ± 15.4 years. The clinical features are presented in Table 1, and the fa-

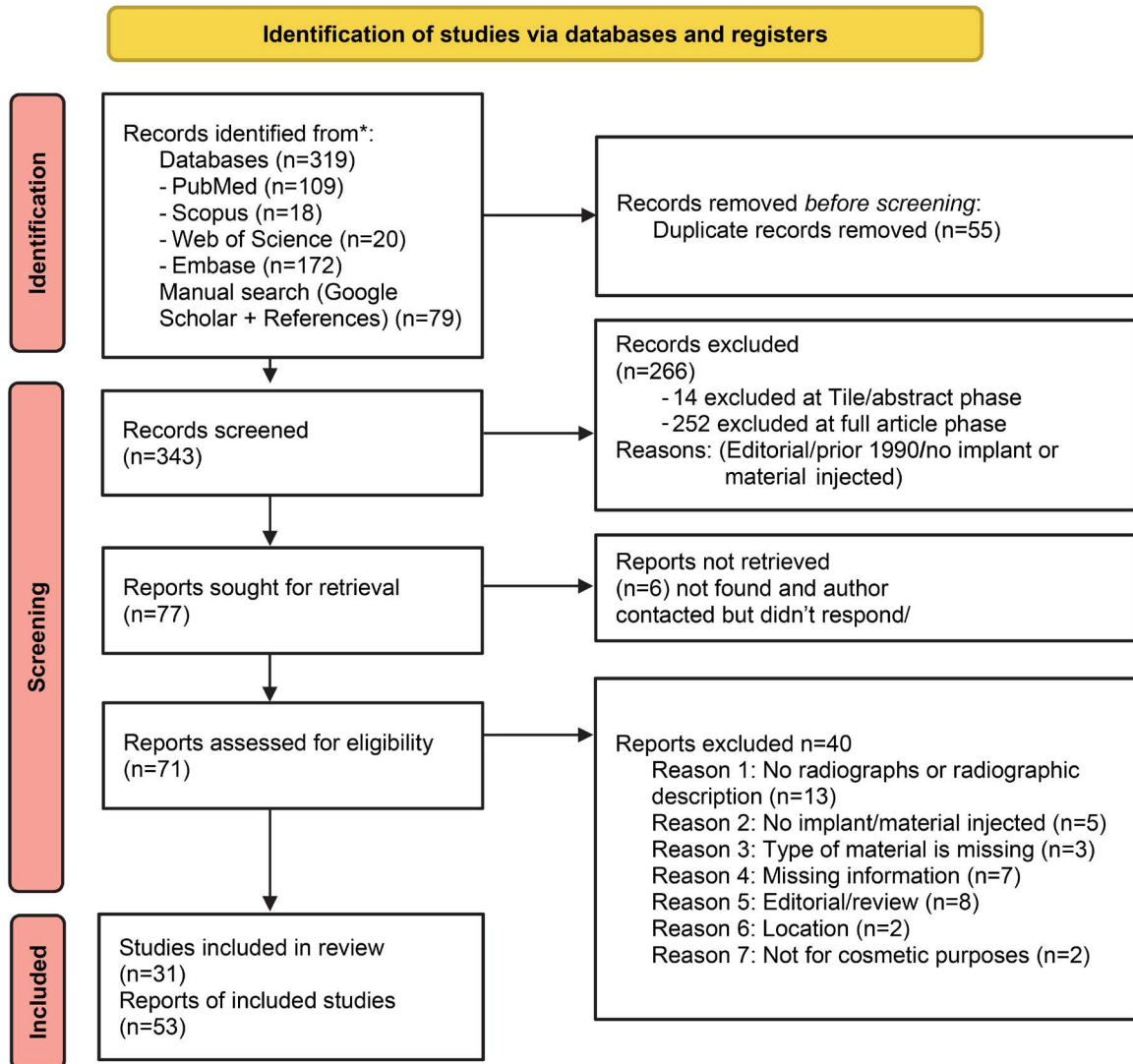


Fig. 1. PRISMA flowchart of article inclusion.

cial distribution of the cosmetic materials is illustrated in Figure 2. Among the 53 cosmetic procedures, 8 (15.0%) were silicone injections^{13,24,26,28,32} 2 (3.8%) were silicone implants,^{30,39} 6 (11.3%) were paraffin injections,^{25,31} 10 (18.9%) were fat injections,^{15,20,22,34,35,40} 4 (7.5%) were gold wires,^{9,18,27,38} 14 (26.4%) involved calcium hydroxyapatite (CaHa),^{10,14,19,21,29,33,37,41} 1 (1.9%) was an autogenous costochondral graft,³⁶ 4 (7.5%) involved polyalkylimide gel,¹⁷ and 4 (7.54%) involved hyaluronic acid.^{16,23} The cases mostly presented with either swelling (18/53, 34.0%) or no symptoms (15/53, 28.3%), and were found incidentally (19/53, 35.8%). The material was usually bilateral (42/53, 79.2%) and in the cheek and zygoma area (35/53, 66.0%).

The radiographic features are presented in Table 2. Most cases were imaged using multi-detector computed tomography (MDCT) (21/53, 39.6%),^{13,14,18,22-24,28,30-33,35,37,41}

and presented radiographically as well-defined (44/53, 83.0%), hyperdense on MDCT and conventional radiography (28/53, 77.7%), isointense on T1-weighted magnetic resonance imaging (MRI) (6/18, 33.3%), hypointense on T2-weighted MRI (6/18, 33.3%), or foci (14/53, 26.4%). Three cases used MRI enhancement (3/18, 16.6%) and all positron emission tomography-computed tomography (PET-CT) scans showed high uptake (6/6, 100%). Most cases reported no effects on surrounding structures (27/53, 51%). The studies did not present the differential diagnosis for most cases (37/53, 69.0%). Table 3 summarizes the frequencies of the clinical and radiographic features of cases that associated with clinical symptoms and/or complications. Symptoms and complications were predominantly present in female patients (22/25, 88.0% and 16/20, 80.0%), patients with permanent fillers (10/25, 40.0% and

Table 1. Clinical presentation of facial cosmetic materials

Material (N = 53)	Location	Clinical symptoms*	Reason for imaging	Migration
Injected silicone ^{13,24,26,28,32} n = 8 (Permanent filler)	U = 6 (75.0%) M = 4 (50.0%) L = 3 (37.5%)	Swelling 4 (50.0%) Erythema 3 (37.5%) Pain 2 (25.0%) Impaired mobility 1 (12.5%) Not reported 3 (37.5%)	Complication 5 (62.5%) Post-op 3 (37.5%)	Not reported
Implant ^{30,39} n = 2 (Synthetic material)	U = 0 (0.0%) M = 0 (0.0%) L = 2 (100.0%)	Swelling 1 (50.0%) Asymptomatic 1 (50.0%)	Incidental 2 (100.0%)	Migration 1 (50.0%)
Injected paraffin ^{25,31} n = 6 (Permanent filler)	U = 1 (16.7%) M = 6 (100.0%) L = 0 (0.0%)	Swelling 2 (33.3%) Asymptomatic 4 (66.6%)	Incidental 6 (100.0%)	Not reported
Injected fat ^{15,20,22,34,35,40} n = 10 (Autologous material)	U = 7 (70.0%) M = 4 (40.0%) L = 1 (10.0%)	Swelling 7 (70.0%) Erythema 2 (20.0%) Impaired mobility 2 (20.0%) Defect 1 (10.0%) Not reported 2 (20.0%)	Complication 7 (70.0%) Post-op 3 (30.0%)	Not reported
Wires ^{9,18,27,38} n = 4 (Synthetic material)	U = 0 (0.0%) M = 4 (100.0%) L = 2 (50.0%)	Pain 2 (50.0%) Paresthesia 1 (25.0%) Asymptomatic 1 (25.0%)	Incidental 3 (75.0%) Complication 1 (25.0%)	Not reported
CaHa ^{10,14,19,21,29,33,37,41} n = 14 (Temporary filler)	U = 7 (50.0%) M = 12 (85.7%) L = 5 (35.7%)	Asymptomatic 7 (50.0%) Swelling 2 (14.3%) Impaired mobility 2 (14.3%) Pain 1 (7.1%) Paresthesia 1 (7.1%) Erythema 1 (7.1%) Not reported 4 (28.6%)	Complication 2 (14.3%) Post-op 4 (28.6%) Incidental 8 (57.1%)	Not reported
Autogenous costochondral graft ³⁶ n = 1 (Autologous material)	U = 0 (0.0%) M = 0 (0.0%) L = 1 (100.0%)	Asymptomatic 1 (100.0%)	Incidental 1 (100.0%)	Not reported
Polyalkylimide Gel ¹⁷ n = 4 (Permanent filler)	U = 0 (0.0%) M = 4 (100.0%) L = 0 (0.0%)	Swelling 2 (50.0%) Erythema 3 (75.0%) Pain 1 (25.0%) Asymptomatic 1 (25.0%)	Complication 4 (100.0%)	Migration 1 (25%)
Hyaluronic acid ^{16,23} n = 4 (Temporary filler)	U = 1 (25.0%) M = 4 (100.0%) L = 3 (75.0%)	Not reported 4 (100.0%)	Complication 1 (25.0%) Post-op 3 (75.0%)	Migration 3 (75%)

*: Many cases have more than one symptom, so the percentages do not add up to 100%.
U: upper 1/3, M: middle 1/3, L: lower 1/3, post-op: postoperative

9/20, 45.0%), cases that were injected bilaterally (16/25, 64% and 13/20, 65.0%), and in cases where the material was found in the middle third of the face (17/25, 68.0% and 13/20, 65.0%), respectively. Radiographically, the material was predominantly well-defined (18/25, 72.0% and 13/20, 65.0%), in the form of small foci (11/25, 44.0% and 10/20, 50.0%), and affected the surrounding structures (19/25, 76.0% and 20/20, 100.0%), respectively.

Discussion

There were 9 different materials used in the face, the most common of which was CaHa (14/53) (Table 1). This proportion did not reflect the most common material used for cosmetic purposes in the face (i.e., hyaluronic acid, followed by botulinum toxin).⁴² This is due to the radiopacity of CaHa, which is a feature unique to CaHa compared to all cosmetic materials in the face, causing its frequent inci-

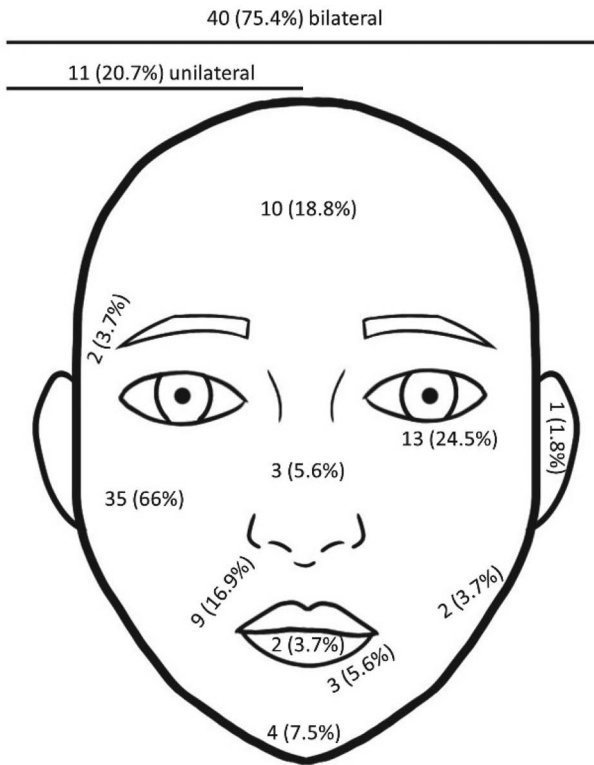


Fig. 2. Illustration showing the distribution of cosmetic materials in the face.

dental finding on radiographic images.

Conceptually, many cosmetic procedures are done bilaterally to maintain facial symmetry. This review revealed that 79.2% of procedures were bilateral, and the most common location was the cheek and zygomatic area (66.0%, Fig. 2). This distribution did not reflect the most common site of facial cosmetic procedures (i.e., the eyelid [surgical] and lip augmentation).⁴² Unlike the lips, cosmetic material in the cheek and zygomatic area could be radiopaque (CaHa). Moreover, cosmetic materials in the middle one-third of the face were near the orbits; therefore, procedural errors or consequent complications were not minor and would necessitate radiographic investigation.

There was a slight preponderance of cases with symptoms (25/53, 47.2%), commonly swelling (18/53, 34.0%), compared to those with no symptoms (15/53, 28.3%). Clinical signs or symptoms were found in patients who had received treatment with permanent fillers (mostly injected silicone) and autologous materials (mostly injected fat) (Table 1). Silicone is a permanent filler with a significant likelihood of microbial biofilm formation and foreign body reaction.⁴³ Fat injections in the facial area require harvesting from the body, processing, and then re-injecting in the desired area, under general anesthesia or sedation.⁴⁴

Procedural errors or aseptic techniques increase the risk of secondary inflammation, in addition to the possibility of fat necrosis or ossification, and thus require a radiographic assessment.⁴⁵

Radiographically, most cosmetic materials presented a well-defined periphery (83.0%). An ill-defined periphery was evident in some cases of injected silicone or fat, and in few CaHa or hyaluronic acid cases (Table 2). The shape or distribution pattern was not unique for any material except wires (fragmented lines) and implants (bone or silicone usually take on the shape of the chin, zygoma, or nasal bridge). The wires reported in this review were gold thread therapy implanted in the subdermal skin. These implanted pure gold threads (0.1 mm diameter) are braided with polyglycolic acid and are expected to trigger the production of elastin and collagen fibers, despite weak evidence of therapeutic efficacy.⁴⁶ The most common pattern was foci (groups of small collections) (Table 2). Nodular (groups of large collections), cystic/mass (one large lump), and infiltrative presentations were not as common.

Interestingly, an infiltrative pattern was noted for injected silicone and fat, where an ill-defined radiographic periphery was also recorded. Unlike other cosmetic materials, silicone oil/gel and fat were injected in aliquots rather than a bolus. This method was performed to avoid fat necrosis and reflects the older technique used with outdated silicone oil/gel.

Studies of incidental findings did not employ MRI. MDCT was used in all studies except one of polyalkylimide gel,³⁰ where only MRI was used for all four cases presenting with complications. Most cosmetic materials were partially or completely hyperdense on MDCT or cone-beam computed tomography (CBCT) (Table 2). CaHa, bone grafts, and gold wires presented higher attenuation than soft tissue, whereas the remaining materials were similar to muscle or fat in attenuation. Unlike MDCT, fat cannot be differentiated from muscle on CBCT due to the low soft-tissue contrast in CBCT. Studies of injected paraffin^{25,31} reported heterogeneous density with calcifications. Paraffin is an outdated cosmetic material that is wax/petroleum-based and, thus, is radiolucent or similar to fat in density. The calcified material was usually in a circular pattern, as secondary calcification forms surrounding the droplets of oil/wax over long durations, such as 20 years.^{25,31} Paraffin was more frequently used in body parts other than the face. However, its use was heavily discouraged due to granulomatous mass formations known as paraffinomas.⁴⁷ Hyaluronic acid is a naturally occurring non-protein glycosaminoglycan, with a radiolucent/hypodense radiograph-

Table 2. Radiographic features of facial cosmetic materials

Material N = 53	Internal structure					Differential diagnosis
	Well-defined periphery	Shape	Conventional radiographs, CBCT, MDCT (N = 36)	MRI (N = 18)	Enhancement	
Injected silicone n = 8 (Permanent filler) ^{13,24,26,28,32}	5 (62.5%)	Nodular 3 (37.5%) Infiltrate 5 (62.5%)	Hyperdense (MS) 4 (100.0%)	Hyperintense on T1 2 (50.0%) Isointense on T1 1 (25.0%) Hypointense on T2 2 (50.0%)	1 MDCT: NR	Inflammation 4 (50.0%) Damage to the orbit 1 (12.5%) Impaired function 1 (12.5%) None 3 (37.5%) Foreign body/granuloma 1 (12.5%) Inflammation 2 (25%) Cosmetic material 1 (12.5%) Benign tumor 1 (12.5%) Malignant tumor 1 (12.5%) NA/NR 5 (62.5%)
Implant ^{30,39} n = 2 (Synthetic material)	2 (100.0%)		Hyperdense 1 (50.0%) Hypodense 1 (50.0%)	–	NA	Foreign body/granuloma 1 (50.0%) Benign tumor 2 (100.0%) Malignant tumor 2 (100.0%)
Injected paraffin ^{25,31} n = 6 (Permanent filler)	6 (100.0%)	Nodular 6 (100.0%) Cystic 5 (83.3%)	Heterogeneous with calcifications 6 (100.0%)	–	2 MDCT: NR	Foreign body/granuloma 5 (83.3%) Cosmetic material 1 (16.6%) Benign tumor 1 (16.6%) Others 1 (16.6%)
Injected fat ^{15,20,22,34,35,40} n = 10 (Autologous material)	6 (60.0%)	Cystic 1 (10.0%) Infiltrate 1 (10.0%)	Hyperdense (MS) 3 (75.0%) Hypodense 1 (25.0%)	Hypointense on T1 1 (16.6%) Heterogeneous on T1 2 (33.3%) Isointense on T1 1 (16.6%) Hypointense on T2 4 (66.6%) Heterogeneous on T2 1 (16.6%)	4 MRI: heterogeneous enhancement 2 No enhancement 2 1 MDCT: NR	Foreign body/granuloma 1 (10.0%) NA/NR 9 (90.0%)
Wires ^{9,18,27,38} n = 4 (Synthetic material)	4 (100.0%)	Fragmented 3 (75.0%) Lines 1 (25.0%)	Hyperdense (C) 4 (100.0%)	–	NA	Benign tumor 2 (50.0%) Others 2 (50.0%) NA/NR 2 (50.0%)
CaHa ^{10,14,19,21,29,33,37,41} n = 14 (Temporary filler)	14 (100.0%)	Foci 13 (92.8%) Mass 1 (7.1%)	Hyperdense (C) 13 (100.0%)	Heterogeneous on T1 2 (100.0%) Heterogeneous on T2 2 (100.0%)	PET: high uptake 5 MRI: enhancement 1	Cosmetic material 1 (7.1%) Others 1 (7.1%) NA/NR 13 (92.8%)
Autogenous costochondral graft ³⁶ n = 1 (Autologous material)	Mass 1 (100.0%)	Mass 1 (100.0%)	Hyperdense (C) 1 (100.0%)	–	NA	Benign tumor 1 (100.0%) Bone thinning or destruction 1 (100.0%)

MS: muscle, C: calcified, CBCT: cone-beam computed tomography, MDCT: multidetector computed tomography, MRI: magnetic resonance imaging, NA: not applicable, NR: not reported

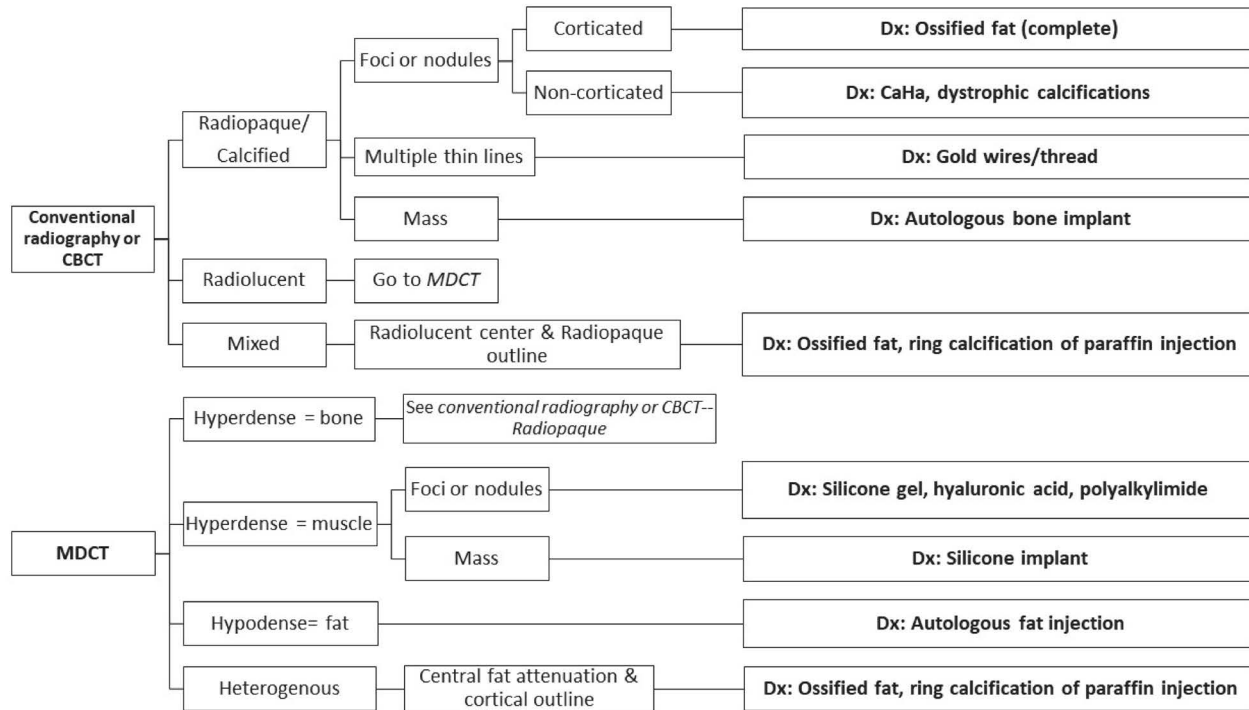


Fig. 3. The radiographic diagnostic scheme of facial cosmetic materials. CBCT: cone-beam computed tomography, MDCT: multidetector computed tomography, Dx: diagnosis.

ic appearance as a result. Ho et al.¹⁶ depicted calcified nodules on MDCT that did not reconcile with the chemical content of hyaluronic acid. The radiopacities could have been dystrophic calcifications as a long-term reaction or CaHa erroneously reported as hyaluronic acid. The information discussed above on internal density was formulated into a diagnostic algorithm in Figure 3.

None of the studies using contrast-enhanced MDCT confirmed or denied internal enhancement, while the studies using MRI and PET showed contrast enhancement in cases with secondary inflammation or complication. The signal intensity on MRI was variable across the different materials in T1- or T2-weighted images (Table 2). The concomitant presence of scar tissue, local inflammation, and variability in commercial content of the material possibly contributed to the inconsistency in signal intensity. MRI may be an optimal modality to assess the impact on surrounding tissues, but not to verify the internal content except for fat in T1-weighted images.

Effects on surrounding structures were commonly noted for injected fat, silicone gel, and polyalkylimide gel (Table 2). The main effects were inflammation of soft tissue and erosion of adjacent bone. Migration of cosmetic material could occur in hyperdynamic areas of the face or aging, and it is considered a complication if it disrupts function or

esthetics. Polyalkylimide gel has been reported to migrate from the cheek or temple to the eyelids and requires surgical excision.⁴⁸ The studies included in this review did not thoroughly report aspects of migration, such as the duration of follow-up since the cosmetic procedure, migration within the same anatomical unit or dermal layers, or whether the material was deep or superficial.

The differential diagnosis was described in 27 of 53 cases. The most common was foreign body/granuloma (8/27, 29.6%), followed by benign tumor (7/27, 26%). Interestingly, only few reports (3/27, 11.1%) considered cosmetic material in the differential diagnosis. Of the 31 studies included, 20 were from the field of medicine, and 11 were from dentistry. These numbers show that both educational backgrounds were equally unfamiliar with the radiographic features of facial cosmetic materials. Malignancy was considered in 3 cases: 1 case of injected silicone (fibrosarcoma) and 2 implant cases (osteosarcoma and liposarcoma in the mental area) (Table 2). Materials that cause tissue displacement (e.g., exophthalmos), bone erosion due to pressure effect, and elicited secondary inflammation in the soft tissues and fat planes could mimic an aggressive lesion.

Most reports were based on incidental radiographic findings of injected paraffin, wires, and CaHa. This distribution did not reflect the most common materials used for cos-

Table 3. Summary of cases with signs and symptoms or complications

		Sign and symptoms (n = 25)	Complications (n = 20)
Sex	Male	3 (12.0%)	4 (20.0%)
	Female	22 (88.0%)	16 (80.0%)
Cosmetic material	Permanent filler	10 (40.0%)	9 (45.0%)
	Temporary filler	3 (12.0%)	3 (15.0%)
	Autologous material	8 (32.0%)	7 (35.0%)
	Synthetic material	4 (16.0%)	1 (5.0%)
Location*	Facial upper 1/3	13 (52.0%)	12 (60.0%)
	Facial middle 1/3	17 (68.0%)	13 (65.0%)
	Facial lower 1/3	7 (28.0%)	4 (20.0%)
Side	Unilateral	9 (36.0%)	7 (35.0%)
	Bilateral	15 (64.0%)	13 (65.0%)
Radiographic periphery	Well-defined	18 (72.0%)	13 (65.0%)
	Ill-defined	7 (28.0%)	7 (35.0%)
Radiographic shape	Large mass(es)	6 (24.0%)	4 (20.0%)
	Small foci	11 (44.0%)	10 (50.0%)
	Not reported	8 (32.0%)	6 (30.0%)
Radiographic effects on surrounding structures	Yes	19 (76.0%)	20 (100.0%)
	No	4 (16.0%)	0 (0.0%)
	Not reported	2 (8.0%)	0 (0.0%)

*: Most cases had the cosmetic material at multiple areas of the face, so the percentages do not add up to 100% for the location.

metic purposes in the face (i.e., hyaluronic acid) or other materials not included in this review, such as collagen, poly-L-lactic acid (PLLA), and polylactide/glycolide resorbable copolymer (PLGA).

Clinical signs/symptoms or complications were mostly observed in patients who had received treatment with permanent fillers (injected silicone and polyalkylimide gel) and in cases where the material substantially affected the surrounding structures based on radiographic assessment (Table 3). Both materials are outdated and have been replaced by pre-packaged, semi-permanent, or temporary fillers that are better tolerated. The predominance of female patients, materials in the middle one-third of the face, bilateral distribution, small foci pattern, and well-defined radiographic periphery were likely due to original skewness in the frequency.

The shortcomings of this review include the lack of systematic reporting of the radiographic features in some studies and inadequate reporting of material migration.

In conclusion, facial cosmetic materials detected on radiographic imaging were commonly found in female patients, bilaterally, and in the middle third of the face. Calcified materials were mostly incidentally found, whereas

hypodense materials were mostly imaged due to complications. Permanent fillers showed a radiographically infiltrative pattern, affected the surrounding structures, and were associated with clinical signs/symptoms and complications. Conventional radiographs, CBCT, and MDCT were useful to differentiate several cosmetic materials. The MRI appearance of cosmetic material was highly variable, except for fat.

Acknowledgments

We appreciate Ms. Sara Alsaleh’s help with the illustrations.

Conflicts of Interest: None

References

1. Akinbiyi T, Othman S, Familusi O, Calvert C, Card EB, Percec I. Better Results in Facial Rejuvenation with Fillers. *Plast Reconstr Surg Glob Open* 2020; 8: e2763.
2. Equizi F. The real world of cosmetic practice. *Faculty Dent J* 2014; 5: 74-7.
3. Nayyar P, Kumar P, Nayyar PV, Singh A. Botox: broadening

- the horizon of dentistry. *J Clin Diagn Res* 2014; 8: ZE25-9.
4. Boulos M, Halepas S, Ferneini EM. Facial fillers. In: Ferneini EM, Goupil MT. Office-based maxillofacial surgical procedures: a step-by-step approach. Cham, Switzerland: Springer; 2019. p. 325-37.
 5. Chuang J, Barnes C, Wong BJ. Overview of facial plastic surgery and current developments. *Surg J(N Y)* 2016; 2: e17-28.
 6. Ballin AC, Brandt FS, Cazzaniga A. Dermal fillers: an update. *Am J Clin Dermatol* 2015; 16: 271-83.
 7. Funt D, Pavicic T. Dermal fillers in aesthetics: an overview of adverse events and treatment approaches. *Clin Cosmet Investig Dermatol* 2013; 6: 295-316.
 8. Chayangsu O, Wanitphakdeedecha R, Pattanaprichakul P, Hidajat IJ, Evangelista KE, Manuskiatti W. Legal vs. illegal injectable fillers: the adverse effects comparison study. *J Cosmet Dermatol* 2020; 19: 1580-6.
 9. Alsaadi G, Jacobs R, Quirynen M, van Steenberghe D. Soft tissue augmentation of the cheeks detected on intra- and extra-oral radiographs: a case report. *Dentomaxillofac Radiol* 2008; 37: 117-20.
 10. Valiyaparambil J, Rengasamy K, Mallya SM. An unusual soft tissue radiopacity - radiographic appearance of a dermal filler. *Br Dent J* 2009; 207: 211-2.
 11. Page MJ, McKenzie JE, Bossuyt PM, Boutron I, Hoffmann TC, Mulrow CD, et al. The PRISMA 2020 statement: an updated guideline for reporting systematic reviews. *BMJ* 2021; 372: n71.
 12. Murad MH, Sultan S, Haffar S, Bazerbachi F. Methodological quality and synthesis of case series and case reports. *BMJ Evid Based Med* 2018; 23: 60-3.
 13. Mathews VP, Elster AD, Barker PB, Buff BL, Haller JA, Greven CM. Intraocular silicone oil: in vitro and in vivo MR and CT characteristics. *AJNR Am J Neuroradiol* 1994; 15: 343-7.
 14. Carruthers A, Liebeskind M, Carruthers J, Forster BB. Radiographic and computed tomographic studies of calcium hydroxylapatite for treatment of HIV-associated facial lipoatrophy and correction of nasolabial folds. *Dermatol Surg* 2008; 34 Suppl 1: S78-84.
 15. Swanson E. Malar augmentation assessed by magnetic resonance imaging in patients after face lift and fat injection. *Plast Reconstr Surg* 2011; 127: 2057-65.
 16. Ho L, Seto J, Ngo V, Vuu H, Wassef H. Cosmetic-related changes on ¹⁸F-FDG PET/CT. *Clin Nucl Med* 2012; 37: e150-3.
 17. Kadouch JA, Tutein Nolthenius CJ, Kadouch DJ, van der Woude HJ, Karim RB, Hoekzema R. Complications after facial injections with permanent fillers: important limitations and considerations of MRI evaluation. *Aesthet Surg J* 2014; 34: 913-23.
 18. Keestra JA, Jacobs R, Quirynen M. Gold-wire artifacts on diagnostic radiographs: a case report. *Imaging Sci Dent* 2014; 44: 81-4.
 19. Pavicic T. Complete biodegradable nature of calcium hydroxylapatite after injection for malar enhancement: an MRI study. *Clin Cosmet Investig Dermatol* 2015; 8: 19-25.
 20. Seo JW, Sa HS. Periorbital lipogranuloma following facial autologous fat injections: non-surgical treatment. *Aesthetic Plast Surg* 2015; 39: 946-52.
 21. Koka S, Shah K, Mallya S. Dermal filler presenting as lobular radiopacities in an edentulous patient: a clinical report. *J Prosthodont* 2017; 26: 670-1.
 22. Lazzarotto A, Franz L, Stella E, Tel A, Sembronio S, Costa F, et al. Volumetric analysis of fat injection by computerized tomography in orthognathic surgery: preliminary report on a novel volumetric analysis process for the quantification of aesthetic results. *J Craniofac Surg* 2019; 30: 771-6.
 23. Micheels P, Besse S, Vandeputte J. Cohesive Polydensified Matrix[®] cross-linked hyaluronic acid volumizing gel: a magnetic resonance imaging and computed tomography study. *Clin Cosmet Investig Dermatol* 2019; 12: 1-10.
 24. Raszewski R, Guyuron B, Lash RH, McMahon JT, Tuthill RJ. A severe fibrotic reaction after cosmetic liquid silicone injection: a case report. *J Craniofac Surg* 1990; 18: 225-8.
 25. Mupparapu M, Mozaffari E. Bilateral calcifications secondary to synthetic soft tissue augmentation of the cheeks: report of a case. *Dentomaxillofac Radiol* 2002; 31: 388-90.
 26. Grippaudo FR, Spalvieri C, Rossi A, Onesti MG, Scuderi N. Ultrasound-assisted liposuction for the removal of siliconomas. *Scand J Plast Reconstr Surg Hand Surg* 2004; 38: 21-6.
 27. Stark GB, Bannasch H. The "golden thread lift": radiologic findings. *Aesthetic Plast Surg* 2007; 31: 206-8.
 28. Anastasov GE, Schulhof S, Lumerman H. Complications after facial contour augmentation with injectable silicone. Diagnosis and treatment. Report of a severe case. *Int J Oral Maxillofac Surg* 2008; 37: 955-60.
 29. Feeney JN, Fox JJ, Akhurst T. Radiological impact of the use of calcium hydroxylapatite dermal fillers. *Clin Radiol* 2009; 64: 897-902.
 30. Gonçalves ES, Almeida AS, Soares S, Oliveira DT. Silicone implant for chin augmentation mimicking a low-grade liposarcoma. *Oral Surg Oral Med Oral Pathol Oral Radiol Endod* 2009; 107: e21-3.
 31. Gu DH, Yoon DY, Chang SK, Lim KJ, Cha JH, Seo YL, et al. CT features of foreign body granulomas after cosmetic paraffin injection into the cervicofacial area. *Diagn Interv Radiol* 2010; 16: 125-8.
 32. Mandel L, Addison S, Clark M. Buccal reaction to silicone cosmetic filler. *J Am Dent Assoc* 2010; 141: 162-6.
 33. Vazquez J, Rosenthal DI. Bilateral, symmetrical soft tissue calcifications in the face. *Skeletal Radiol* 2010; 39: 387-9.
 34. Paik JS, Cho WK, Park GS, Yang SW. Eyelid-associated complications after autogenous fat injection for cosmetic forehead augmentation. *BMC Ophthalmol* 2013; 13: 32.
 35. Park YR, Choi JA, Yoon La T. Periorbital lipogranuloma after cryopreserved autologous fat injection at forehead: unexpected complication of a popular cosmetic procedure. *Can J Ophthalmol* 2013; 48: e166-8.
 36. Badr FF, Mintline M, Ruprecht A, Cohen D, Blumberg BR, Nair MK. Long-standing chin-augmenting costochondral graft creating a diagnostic challenge: a case report and literature review. *Imaging Sci Dent* 2016; 46: 279-84.
 37. Kitahara T. A case of multiple calcification foci under the epidermis observed on facial CT. *Showa Univ J Med Sci* 2016; 28: 369-72.
 38. Garg R, Fernandes B, Sunil MK. Unusual radiopacities spotted in a dental radiograph: case report. *J Indian Acad Oral*

- Med Radiol 2017; 29: 138-40.
39. Caovilla Felin G, De Carli JP, Ericson Flores M, Bernardon Pretto JL, Copatti Dogenski L, De Conto F. Foreign body reaction simulating mandibular osteosarcoma - case report. *Int J Surg Case Rep* 2019; 60: 58-62.
40. Sa HS, Woo KI, Suh YL, Kim YD. Periorbital lipogranuloma: a previously unknown complication of autologous fat injections for facial augmentation. *Br J Ophthalmol* 2011; 95: 1259-63.
41. Lee MJ, Sung MS, Kim NJ, Choung HK, Khwarg SI. Eyelid mass secondary to injection of calcium hydroxylapatite facial filler. *Ophthalmic Plast Reconstr Surg* 2008; 24: 421-3.
42. Goodman G, Liew S, Callan P, Hart S. Facial aesthetic injections in clinical practice: pretreatment and posttreatment consensus recommendations to minimise adverse outcomes. *Australas J Dermatol* 2020; 61: 217-25.
43. Slettengren M, Mohanty S, Kamolvit W, van der Linden J, Brauner A. Making medical devices safer: impact of plastic and silicone oil on microbial biofilm formation. *J Hosp Infect* 2020; 106: 155-62.
44. Lam SM, Glasgold RA, Glasgold MJ. Fat harvesting techniques for facial fat transfer. *Facial Plast Surg* 2010; 26: 356-61.
45. Yoshimura K, Coleman SR. Complications of fat grafting: how they occur and how to find, avoid, and treat them. *Clin Plast Surg* 2015; 42: 383-8.
46. Shin KC, Bae TH, Kim WS, Kim HK. Usefulness of gold thread implantation for crow's feet. *Arch Plast Surg* 2012; 39: 42-5.
47. Mundada P, Kohler R, Boudabbous S, Toutous Trelu L, Platon A, Becker M. Injectable facial fillers: imaging features, complications, and diagnostic pitfalls at MRI and PET CT. *Insights Imaging* 2017; 8: 557-72.
48. AlHarbi ZA, Alkatan HM, Alsuhaibani AH. Long-term outcomes of surgically removed migrated polyalkylimide (bio-alcamid) filler to the periorbital area. *Saudi J Ophthalmol* 2019; 33: 251-4.