

# The Use of Nontreated Mosquito-Net Mesh Cloth for a Tension Free Inguinal Hernia Repair: Our Experience

Felix O Oribabor, Oluwasegun A Amao<sup>1</sup>, Saheed O Akanni<sup>1</sup>, Samuel O Fatidinu<sup>1</sup>

Departments of Surgery, <sup>1</sup>General Surgery Division, Federal Medical Centre, Ido-Ekiti, Ekiti, Nigeria

## ABSTRACT

**Introduction:** The prohibitive costs and scarcity of the imported prosthetic mesh for hernioplasty, has prevented its widespread use in most developing countries. We then set out to ascertain the outcome, complications (undue pain, wound infection, recurrence, and mesh extrusion) and cost implications in the use of a nontreated mosquito-net for inguinal hernioplasty. **Materials and Methods:** A prospective study of all consecutive adult patients with uncomplicated inguinal hernia who were admitted for open herniorrhaphy between January 2012 and December, 2013 at the Federal Medical Centre, Ido – Ekiti, South West, Nigeria. A sheet of the nontreated mosquito-net mesh 10 cm × 8 cm, autoclaved, a day prior to surgery was used for each patient’s hernia repair. The operation sites were exposed and examined 3<sup>rd</sup> and 6<sup>th</sup> postoperative days. Findings were documented for analysis. **Result:** A total of 130 adult patients were recruited for this study of which 115 of the patients were males and 15 were females. Forty-four (41.53%) had inguinal hernia and 76 (58.46%) of them had inguinoscrotal hernia. They all had successful repair and were followed-up for complications for a period of 6 weeks to 6 months at the surgical out-patient department. **Conclusion:** Locally-sourced and autoclaved mosquito-net mesh is an effective alternative for hernioplasty especially in situations where commercial mesh is not readily available or affordable.

**KEYWORDS:** An effective alternative, locally-sourced autoclaved nontreated mosquito-net mesh, readily available and affordable

## INTRODUCTION

Inguinal herniorrhaphy is the most frequently performed abdominal operation accounting for 10–15% of operations in General Surgery.<sup>[1]</sup> For most parts of the 20<sup>th</sup> century, Edoardo Bassini hernia operation was considered the “gold standard” for inguinal hernia repairs. Although his concept of posterior wall re-enforcement is still universally accepted and remains valid surgically until date, this technique has however been variously criticized for its high recurrence rate, which is about 15% in general practice. Furthermore, the technique is also considered relatively painful. The reason for these is due to the tension created by apposing tissues that are not naturally in apposition.<sup>[2]</sup>

### Address for correspondence:

Dr. Felix O Oribabor,  
Department of Surgery, Federal Medical Centre, Ido-Ekiti, Ekiti, Nigeria.  
E-mail: onosedebafelix@yahoo.com

### Access this article online

#### Quick Response Code:



Website: [www.nigerianjsurg.com](http://www.nigerianjsurg.com)

DOI:  
10.4103/1117-6806.152726

Lichtenstein in 1987, theorized that by using a mesh prosthesis to bridge the hernia defect, rather than to close it with sutures, as with the Bassini and its modifications, tension is avoided. This ostensibly results in a less painful operation and a reduced incidence of suture pulling out, thus leading to a lower recurrence rate.<sup>[3,4]</sup>

A Lichtenstein type of operation has now become the method of choice in most developed nations of the world, especially in the USA.<sup>[2]</sup> In the developing world, as well as in Africa and Nigeria, the traditional Bassini operation is still being performed in most centers due largely to the scarcity and expensive nature of the commercial prosthetic mesh.<sup>[1]</sup> The effectiveness and reliability of the mosquito-net mesh for hernioplasty has recently been published by workers from centers in the developing world. We then set out to report our experience with the use of a nonchemically treated sterilized mosquito-net mesh in hernia repair in a Nigerian tertiary health center.

## MATERIALS AND METHODS

This is a prospective study of 130 consecutive patients that were admitted with uncomplicated inguinal and inguinoscrotal hernia for tension free herniorrhaphy, using a nonchemically treated, sterilized mosquito-net mesh between January 2012 and December, 2013 at the Federal Medical Centre, Ido – Ekiti, South West, Nigeria. Ethical approval for the study was obtained from the Hospital’s Ethical Committee on Research.

All patients were admitted via the surgical out-patient clinic and emergency unit depending on the mode of presentation. The patients admitted via the emergency were fully stabilized by resuscitation before they had surgery. Each patient was assessed, and the inguinal hernia was classified preoperatively by Shillcutt *et al.*<sup>[5]</sup> method based on its size (H1 – H4) [Table 1].

Also, all the patients were clinically examined to rule out any cardiopulmonary, abdominal and genitourinary predisposing factors. Those patients with strangulated hernia that were resected at surgery, debilitating medical conditions, like diabetes mellitus and immune-compromised states that may negate the use of prosthesis as well as may impair normal wound healing, were excluded from the study. The procedures were performed with local anesthesia except those with inguinoscrotal hernia who had spinal anesthesia.

Consent was obtained from each patient after an explanation. All patients had open hernia surgery which consisted of a skin crease incision about 2–3 cm above the inguinal ligament, opening of the inguinal canal, dissection and separation of the sac from the cord. The sac was emptied of its content, transfixated at its neck, the excess of the sac excised and the stump was returned into the peritoneum. The deep ring was then narrowed with a 2/0 absorbable suture (indirect hernia), the posterior walls repaired (direct and indirect hernias) in preparation to receive the mosquito-net mesh [Figure 1].

A piece of the sterilized (autoclaved) mosquito-net mesh 10 cm × 8 cm was cut out, and placed on the posterior wall of the inguinal canal after trimming it to size with its lower and lateral edges sutured to the inguinal ligament up to the level of the deep inguinal ring using a nonabsorbable nylon O suture [Figure 2]. The upper edge of the mesh was likewise sutured to the internal oblique muscle and transversalis fascia with the same nylon suture [Figure 3].

The lateral end of the mesh was then slit to create a passage for the cord. The two limbs of the slit, was then doubled-crossed

around the cord and sutured using the nylon-O suture, so that it encircled the cord snugly.<sup>[2,6]</sup>

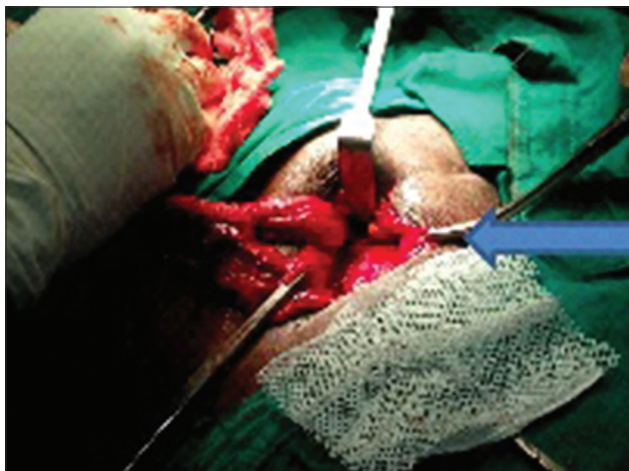
The cord and its structures were returned to the inguinal canal which was then reconstituted [Figure 4]. All patients were placed on oral analgesics and antibiotic postoperatively. They were admitted and monitored closely for undue pains. The wounds were exposed on the 3<sup>rd</sup> and 6<sup>th</sup> postoperative day for inspection, for wound and scrotal edema, hematoma and other signs of infections. Patients were discharged on the 7<sup>th</sup> postoperative day to the surgical out-patient clinic for further assessment and follow-up.

## RESULTS

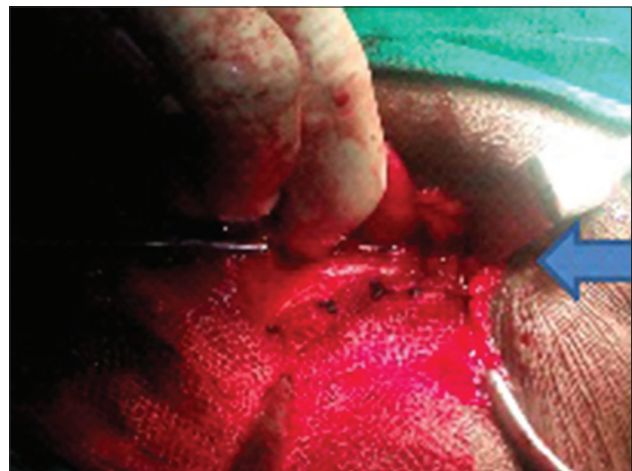
A total of 130 adult patients were admitted and operated during this study. Fifty-four (41.53%) of the patients had inguinal hernia while 76 (58.46%) had inguinoscrotal hernia. Hernia of 100 patients (76.92%) was reducible, and 30 (23.07%) were irreducible, but were not strangulated. There were 115 males and 15 females. Their age ranges from 18 to 85 years (mean 52.27-year); male: Female ratio was 7.66:1. The number of frequency of each hernia grade is as shown in The notable complication observed was scrotal edema/hematoma in 10 patients (7.69%) who had inguinoscrotal hernia that resolved after 8 weeks of conservative treatment. Furthermore, 6 (4.61%) of the patients had superficial wound infections, which also resolved after a further course of antibiotic for 1-week, with daily change of wound dressing at the center. All patients were followed-up at the surgical out-patient department (SOPD) for a period of 6 months before being lost to follow-up. In all the patients, there was no hernia recurrence or extrusion of the mesh.

## DISCUSSION

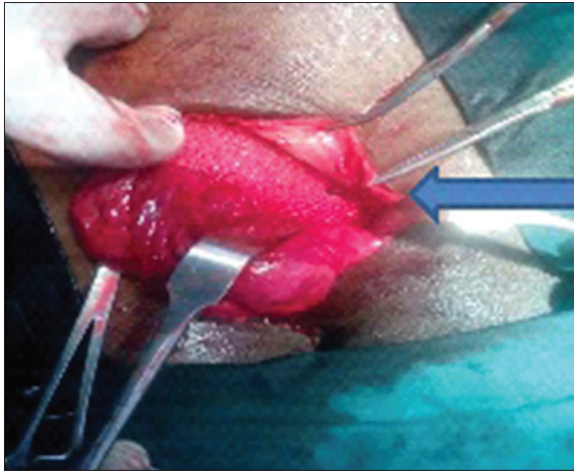
Inguinal and inguinoscrotal hernia is very common in the Nigerian environment<sup>[1]</sup> and its repair is one of the most commonly performed surgical operations. Traditional



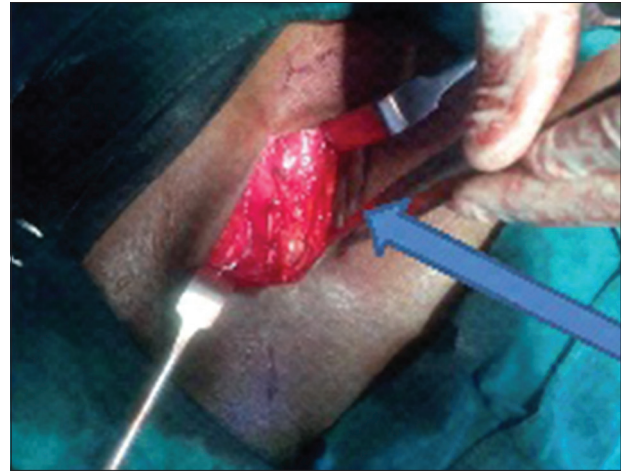
**Figure 1:** Preparation for mesh insertion



**Figure 2:** Attachment to inguinal ligament



**Figure 3:** Attachment to conjoint tendon



**Figure 4:** Reconstitution

**Table 1: Kingsnorth classification of groin hernia**

Hernia	Number	Percentage	Definition
H1	20	15.38	Groin only; reduces spontaneously when lying down
H2	34	26.15	Groin only reduces completely with gentle manual pressure
H3a	18	13.8	Inguinoscrotal hernia reduces with manual Manipulation
H3b	12	9.2	
H3c	16	12.3	
H4a	10	7.7	Irreducible inguinoscrotal hernia
H4b	8	6.15	
H4c	12	9.23	

Subgrades: a=<10 cm, b=10-12 cm, c=>20 cm

herniorrhaphy Bassini repair (including its modifications) is still largely practiced in many communities in the developing world and Nigeria, as well as in the study center, as the commercial prosthetic mesh is generally not readily available and when found, is considered too expensive.

Elective groin hernia surgery with sterilized<sup>[5]</sup> mosquito-net mesh has recently been described by workers mainly from developing countries who face the above similar challenges.<sup>[5,7-11]</sup> Pioneering a work involving mosquito-net mesh herniorrhaphy, Tongaonkar *et al.* in India, had revealed by analysis, that the mosquito-net is a co-polymer of poly-propylene and poly-ethylene, and the commercial prosthetic mesh used globally is polypropylene or proline.<sup>[7]</sup>

This discovery led to a spate of multi-center clinical trials in that country and the West African sub-region by Shillcutt *et al.*<sup>[5]</sup> that showed that the mesh is as effective in herniorrhaphy as the imported, commercial prosthetic mesh.

This assertion has been confirmed by other workers from the African and West African sub-region.<sup>[8,10,11]</sup> In addition, experimental studies on mice have demonstrated that implanted pieces of mosquito-net cloths in tissues made of polyester can

create an inflammatory reaction comparable to that created by the most sophisticated polypropylene mesh.<sup>[11,12]</sup>

In this study, we operated on 130 patients using the sterilized (autoclaved) mosquito-net mesh for a tension-free Lichtenstein herniorrhaphy [Figures 1-4]. The procedure was well tolerated by the patients with no immediate postoperative effects. Few complications were however recorded while patients were being followed-up at the SOPD and were treated conservatively. At 8 weeks after surgery, 10 patients (7.69%) had scrotal hematomas and 6 (4.61%) had superficial wound infections that resolved on conservative management. These findings are comparable with published studies by other workers; Shillcutt *et al.*<sup>[5]</sup> also using the sterilized mosquito-net mesh recorded 4.4% of hematoma and 1.7% of wound infections that also resolved through conservative treatment while working on 124 patients.

Even when compared with Lichtenstein repair, done with commercial prosthetic mesh in developed countries e.g. Scotland, 7% of their patients developed hematoma within 3 months after surgery<sup>[13]</sup> and 5–8% of the patients developed wound infections despite antibiotic prophylaxis.<sup>[4,13-15]</sup>

Most of our patients reported for follow-up between 6 weeks and 6 months only before being lost to follow-up. The reason for this may have been due to the fact that as there was no short-term complications, patient did not see the need to attend the SOPD. During this period however, no hernia recurrence or extrusion of the mesh was recorded in all our patients. This result is comparable with those of other workers using the mosquito-net mesh for tension-free herniorrhaphy from developing countries and Africa.<sup>[5,7,8,10]</sup>

The cost effectiveness of this material for hernia repair is not in doubt; the cost of a 15-m<sup>2</sup> nonchemically treated mosquito-net from the local market, is N2,000.00 (local currency) and a piece of mesh, measuring 10 cm × 8 cm (0.8 m<sup>2</sup>) would cost N1.60. This price, to every intent, cannot cause any dramatic rise in the total cost for a tension-free herniorrhaphy using this local prosthesis.

The clinical effectiveness of this material for herniorrhaphy is not in doubt. Also in a randomized double-blind study in Burkina Faso, Freudenberg *et al.*<sup>[11]</sup> had shown that there was no significant difference in the short-term clinical outcome of hernia treatment or surgeon's comfort in handling the mosquito-net mesh and the commercial mesh prosthesis. Furthermore, Tongaonkar *et al.*<sup>[16]</sup> has shown in their 10-year experience of using the mosquito-net prosthesis in hernia repair that the mesh has a long-term safety and effective property, provided it is adequately sterilized.

## CONCLUSION

This study has shown that the non-treated mosquito-net mesh is a very cost effective alternative to the commercial mesh in the developing countries in general and especially in Nigeria where patients bear the costs of all medi-care with no health insurance scheme in place. Also, the mesh has a proven low complication rate, a low short-term recurrence rate and a good safety profile.

We may suggest that the mesh be freely used in situations where the need of prosthesis is not negated.

## REFERENCES

- Adesunkanmi AR, Badmus TA, Ogundoyin O. Determinants of outcome of inguinal herniorrhaphy in Nigerian patients. *Ann Coll Surg Hong Kong* 2004;8:14-21.
- Robert JF Jr, Charles JF, Thomas HQ. Inguinal hernias. In: Brunicaudi FC, Anderson DK, Billiar TR, Duncan DL, Hunter JG, Pollock RE, editors. *Schwartz's Principles of Surgery*. 8<sup>th</sup> ed. USA: The McGraw-Hill Companies Inc.; 2005. p. 1353-74.
- Lichtenstein IL, Shulman AG, Amid PK, Montllor MM. The tension-free hernioplasty. *Am J Surg* 1989;157:188-93.
- Matyja A, Kubil W, Pach R. Assessment of inguinal hernia treatment results in patients operated on with mesh. *Videosurgery miniinv* 2010;5:27-34.
- Shillcutt SD, Clarke MG, Kingsnorth AN. Cost-effectiveness of groin hernia surgery in the Western Region of Ghana. *Arch Surg* 2010;145:954-61.
- Zollinger RM Jr, Zollinger RM Sr. Inguinal hernia: In: Bitans M, Smith J, Donner C, Codding M, editors. *Zollinger Atlas of Surgical operations*. 8<sup>th</sup> ed. Columbia: The McGraw-Hill; 2003. p. 424-7.
- Tongaonkar RR, Udwardia TE, Btrahma R. Preliminary multicentric trial of cheap indigenous mosquito-net cloth for tension-free hernia repair. *Indian J Surg* 2003;68:89-95.
- Alberto K, Daniel C, Oscar K. The use of mosquito - Net cloths as prosthesis in inguinal hernia repair: An experience in South Sudan. *Surg Sci* 2012;3:155-7.
- Stephenson BM, Kingsnorth AN. Safety and sterilization of mosquito net mesh for humanitarian inguinal hernioplasty. *World J Surg* 2011;35:1957-60.
- Clarke MG, Oppong C, Simmermacher R, Park K, Kurzer M, Vanotoo L, *et al.* The use of sterilised polyester mosquito net mesh for inguinal hernia repair in Ghana. *Hernia* 2009;13:155-9.
- Freudenberg S, Sano D, Ouangré E, Weiss C, Wilhelm TJ. Commercial mesh versus Nylon mosquito net for hernia repair. A randomized double-blind study in Burkina Faso. *World J Surg* 2006;30:1784-9.
- Klinge U, Klosterhalfen B, Müller M, Schumpelick V. Foreign body reaction to meshes used for the repair of abdominal wall hernias. *Eur J Surg* 1999;165:665-73.
- Hair A, Duffy K, McLean J, Taylor S, Smith H, Walker A, *et al.* Groin hernia repair in Scotland. *Br J Surg* 2000;87:1722-6.
- Bierca J, Kosim A, Kolodziejczak M, Zmora J, Kultys E. Effectiveness of Lichtenstein repairs in planned treatment of giant inguinal hernia-Own experience. *Wideochir Inne Tech Malo Inwazyjne* 2013;8:36-42.
- Taylor EW, Duffy K, Lee K, Hill R, Noone A, Macintyre I, *et al.* Surgical site infection after groin hernia repair. *Br J Surg* 2004;91:105-11.
- Tongaonkar RR, Sandra DL, Kingsnorth AN. Ten year personal experience of using Low Density Polyethylene (LDPE) mesh for surgery. *Open Access J* 2013;1, 5:11-3.

**How to cite this article:** Oribabor FO, Amao OA, Akanni SO, Fatidinu SO. The use of nontreated mosquito-net mesh cloth for a tension free inguinal hernia repair: Our experience. *Niger J Surg* 2015;21:48-51.

**Source of Support:** Nil, **Conflicts of Interest:** None declared.