

Single Case

Small-Bowel Obstruction Secondary to Ileal Trichobezoar in a Patient with Rapunzel Syndrome

Bertha E. García-Ramírez^a Carlos M. Nuño-Guzmán^{a, b}
Ricardo E. Zaragoza-Carrillo^a Hugo Salado-Rentería^a
Audrey Gómez-Abarca^a Jorge L. Corona^c

^aDepartment of General Surgery, Hospital Civil de Guadalajara “Fray Antonio Alcalde”, Guadalajara, Mexico; ^bDepartamento de Clínicas Quirúrgicas, Centro Universitario de Ciencias de la Salud, Universidad de Guadalajara, Guadalajara, Mexico; ^cDepartment of Radiology, Hospital Civil de Guadalajara “Fray Antonio Alcalde”, Guadalajara, Mexico

Keywords

Rapunzel syndrome · Trichobezoar · Gastric trichobezoar · Small-bowel trichobezoar · Intestinal obstruction · Case report

Abstract

Bezoars are conglomerations of undigested foreign material retained in the gastrointestinal tract. Trichobezoar is a compact conglomeration of swallowed hair and constitutes less than 6% of all bezoars. Their most frequent location is in the stomach but they may extend through the pylorus into the small bowel. This condition is known as Rapunzel syndrome. Many patients may remain asymptomatic or present a mild form of the disease characterized by abdominal pain, early satiety, nausea, and vomiting. Complications may manifest as gastric outlet obstruction or bleeding, and intestinal obstruction. A 15-year-old female patient presented with clinical findings of intestinal obstruction. The patient suffered from depressive and anxiety disorders and trichotillomania, although trichophagy could not be assured. Alopecia circumscripta and irregular hair length on the scalp were identified. A computed tomography (CT) scan showed two images highly suggestive of trichobezoars, one in the stomach and the second one causing obstruction at the ileocecal valve. At laparotomy, both a mobile gastric trichobezoar with a tail extending to the duodenum and a trichobezoar causing obstruction at the ileocecal valve were removed. The postoperative course was uneventful. The passage of a

detached trichobezoar fragment in a patient with Rapunzel syndrome may cause intestinal obstruction. CT is the preferred image modality for the evaluation of suspected trichobezoars in order to characterize their size and locations, the presence and level of obstruction, and complications such as ischemia or perforation. A case of small-bowel obstruction secondary to ileal trichobezoar in a patient with Rapunzel syndrome is herein reported.

© 2018 The Author(s)
Published by S. Karger AG, Basel

Introduction

Bezoars are conglomerations of undigested foreign material retained in the gastrointestinal tract. Such foreign material may be fibers and debris of plants, vegetables and fruits (phytobezoar), persimmons (diospyrobezoar), hair (trichobezoar), medications (pharmacobezoar), and milk protein (lactobezoar). Bezoars have been found in any portion of the gastrointestinal tract, but the stomach is the most common site. Bezoars have been reported in less than 0.5% of all esophagogastroduodenoscopies and may be the cause of small-bowel obstruction in 0.4–4.8% of the cases [1]. Phytobezoar is the most common form, while trichobezoars constitute less than 6% of all cases [2]. Many patients may be asymptomatic, but some bezoars may produce epigastric pain, early satiety, nausea, vomiting, and weight loss. Complications may manifest as gastric outlet obstruction or bleeding. Passage of a bezoar into the small bowel or large bowel may cause intestinal obstruction [3]. A case of small-bowel obstruction secondary to ileal trichobezoar in a patient with Rapunzel syndrome is herein described.

Case Presentation

A 15-year-old female patient presented to the emergency department of our hospital with generalized cramping abdominal pain, nausea, and vomiting up to 3–5 times a day, and constipation during the previous 5 days. She also referred decreased appetite and an 8-kg weight loss (12.3% of her total body weight) during the past 2 months. Her mother reported that the patient also suffered from trichotillomania during the past 2 years, although trichophagy could not be assured. The patient suffered from major depressive and anxiety disorders and was under treatment with fluoxetine during the past 2 years. On admission, physical examination showed a pale skin and signs of dehydration, a heart rate of 124 beats/min, a blood pressure of 100/60 mm Hg, a respiratory rate of 16 breaths/min, and a body temperature of 36.5°C. Three irregular patches of hair loss (alopecia) and irregular hair length on the right side of her scalp were identified. Her abdomen was distended, bowel sounds were hypoactive, with guarding in the upper abdomen and generalized tenderness, but no rebound was found. Blood count showed a hemoglobin level of 10.5 g/dL, a platelet count of 472×10^9 , and a white blood cell count of 18.7×10^9 , with a predominance of neutrophils (77.8%). Coagulation screening tests showed a prothrombin time of 11.9 s, activated partial thromboplastin time of 26.8 s, and an international normalized ratio of 1.09. Biochemical analysis showed a blood glucose of 82 mg/dL, serum creatinine of 0.68 mg/dL, total proteins 7.8 mg/dL, and serum albumin 4 mg/dL. After receiving intravenous crystalloids, a plain abdominal film was performed, which showed a distended and occupied stomach, dilated small-bowel loops and air-fluid levels, and distention of the distal ileum (Fig. 1a). An abdominal computed tomography (CT) scan showed gastric dilatation and a well-defined ovoid heterogeneous mass within the

stomach (Fig. 1b). Dilated small bowel loops proximal to a heterogeneous intraluminal mass located at the ileocecal valve was also shown (Fig. 1c). Both images were highly suggestive of trichobezoars. The patient underwent an emergency laparotomy. Gastric and small-bowel distention was evident. Through an anterior gastrotomy, a mobile gastric trichobezoar with a tail extending to the duodenum was removed (Fig. 2a). Extensive gastric mucosa erythema was observed. A second trichobezoar causing obstruction at the ileocecal valve was removed through an enterotomy (Fig. 2b). Primary closure was performed for both gastrotomy and enterotomy. After psychiatric consultation, the patient was discharged from the hospital at the 9th postoperative day, and after a 26-month follow-up, she remains under psychiatric treatment, with no recurrence of trichotillomania, trichophagy, or abdominal complaints.

Discussion

Trichobezoar is a compact conglomeration of swallowed hair. This rare condition is usually located in the stomach but it may extend through the pylorus into the small bowel and colon. Vaughan et al. [4] described this condition and named it Rapunzel syndrome. The resistance of human hair to digestion, the limited peristaltic propulsion due to its smooth surface, and the pyloric valve effect contribute to the accumulation of hair between the gastric mucosal folds and may assume the shape of the gastric lumen [5]. Occasionally, fragments of the hair conglomerate may become detached and migrate to the small bowel [6].

Trichobezoars are most commonly found in children and adolescents, but all age groups may be affected [3, 6]. Naik et al. [5] reported a mean age of 10.8 years, and 96% were female patients. Trichobezoars are the result of trichotillomania and trichophagia, commonly observed in young females with psychiatric disorders. Mental retardation has also been associated with trichobezoars [3, 6]. Severe psychiatric disorders have been reported only in a minority of cases [7].

Clinical manifestations are associated with the trichobezoar size. In early phases, many patients may remain asymptomatic. No pathognomonic signs or symptoms have been described. A mild form of the disease may be characterized by abdominal pain, early satiety, nausea, and vomiting, which has been observed in one-third of the patients [5]. This may lead to malnutrition and weight loss. Trichobezoar should be included in differential diagnosis in young females with nonspecific epigastric pain, fatigue, weight loss, and epigastric mass [6]. More severe manifestations of this entity depend on trichobezoar location. Gastric erosion and ulceration may lead to bleeding or perforation. A large trichobezoar may lead to gastric outlet obstruction [8, 9]. Intestinal obstruction in the terminal ileum is uncommon and may cause ischemia and perforation [10, 11]. Gastrointestinal bleeding has been described in 6% of the patients, and intestinal obstruction or perforation in 10% [12]. Overall, gastrointestinal obstruction has been documented in 26% of the patients, and peritonitis in 18% [5].

Plain abdominal films are nonspecific but may be useful to confirm a clinical diagnosis of gastrointestinal obstruction or perforation. Air accumulation in the trichobezoar may give a mottled appearance. Barium studies may show a stomach being occupied by a heterogeneous and mottled-appearing mass due to the absorption of contrast material by the trichobezoar. Barium studies may differentiate small-bowel obstruction caused by adhesions from obstruction secondary to a trichobezoar [6]. Ultrasound provides no pathognomonic signs, but a hyperechoic curvilinear dense strip at the anterior margin of the lesion associated with complete shadowing posteriorly has been described [13, 14].

Although CT scan is the preferred image study for the evaluation of suspected trichobezoars, most data are derived from case reports or from small proportions of patients in case series of different bezoar types. The CT image of a gastric trichobezoar is a hypodense and heterogeneous mass within the stomach with a mesh-like pattern, with oral contrast material sparse within the mass and surrounding it and containing a mottled air pattern [15–17]. Although small-bowel bezoar CT findings are not specific for trichobezoars, CT is superior to other radiologic modalities for bezoar diagnosis and differential diagnosis in small-bowel obstruction [18]. A CT scan showing a dilated small-bowel loop and a well-defined round or ovoid, heterogeneous intraluminal mass at the transition zone has been considered highly diagnostic [2, 18]. Small-bowel bezoars may be similar to small-bowel feces, but feces-like material occupies a longer dilated intestinal segment and is located proximal to the obstruction site, while a bezoar appears as a round or ovoid-shaped mass located at the obstruction site [18]. Multiplanar reformations can be obtained with multidetector row CT and increase the accuracy and confidence in transition zone location in mechanical small-bowel obstruction [19]. A CT scan is also useful to detect concomitant gastric and 1 or more small-bowel bezoars. The appearance of concentric whorls or small-rounded areas of hypodensity migrating from the stomach into the small bowel is suggestive of Rapunzel syndrome [1, 19]. Contrast-enhanced CT scans are particularly helpful to differentiate the bezoar from an intraluminal tumor and to detect intestinal ischemia. Various signs have been associated with ischemia, such as a thickened bowel wall, ascites, a trilaminar appearance of the bowel wall resulting from IV contrast enhancement of the mucosal and muscularis layers, plus submucosal edema (the “target” sign), poor or absent enhancement of the bowel wall on IV contrast-enhanced scans, pneumatosis intestinalis and gas in mesenteric or portal veins, tortuous engorged mesenteric vessels, and increased attenuation of the bowel wall on noncontrast scans [20]. Multiplanar reformations characterize the different types, sizes, and locations of the bezoars, the presence and level of obstruction, and complications [21]. Magnetic resonance imaging seems less useful than CT scans for the diagnosis of trichobezoar because the very low signal intensity may be easily confused with air [21].

Psychiatric evaluation and management when indicated are recommended, even prior to definite treatment if there are no signs of complication that require urgent management. Conservative management of trichobezoars has been associated with a poor outcome [5]. Trichobezoars are resistant to enzymatic degradation and medical treatment. Endoscopic extraction of trichobezoars is generally ineffective. The size and high density of the hair conglomerate limits endoscopic fragmentation. A minority of cases, mostly due to small gastric trichobezoars, have been successfully managed [1, 6]. Unfortunately, small gastric trichobezoars are uncommon. If a trichobezoar has been detected elsewhere in the gastrointestinal tract, endoscopy will also detect whether a gastric trichobezoar is present [3]. Endoscopy is also valuable when the diagnosis of gastric mass is unclear. When endoscopic removal is attempted, possible migration of fragments through the pylorus and subsequent intestinal obstruction must be considered [6].

Trichobezoars are most commonly removed by gastrotomy and/or enterotomy [5]. If ischemia or perforation is found, gastric and/or intestinal resection will be required. Erzurumlu et al. [2] reported that in patients who were surgically treated, gastrotomy and/or enterotomy were performed in 85.7%, while subtotal gastrectomy or intestinal resection was indicated in the remaining 14.3%. Most patients with trichobezoar are approached through laparotomy, which allows the examination of the stomach and intestines in order to detect and remove fragments and thus prevent intestinal obstruction [6]. Robles et al. [22] reported 3 cases of small-bowel obstruction secondary to a diospyrobezoar, which were managed with lapa-

roscopic surgery. Nirasawa et al. [23] performed a successful laparoscopic removal of a trichobezoar, which was approached and retrieved through a gastrotomy and removed via a subrapubic incision. Palanivelu et al. [24] reported the laparoscopic retrieval of concomitant gastric and ileum trichobezoars, which were removed through a minilaparotomy. In a review by Gorter et al. [6] laparotomy had a success rate of 99%, with a 12% complication rate, whereas laparoscopy was successful in 75% of the cases, with no complications. Horesh et al. [25] reported a 55% conversion rate to an open procedure after a laparoscopic approach and found no benefit in the complication rate, readmissions, and length of stay. Due to a high success rate, the low complication rate, and low complexity, and the ability to examine the gastrointestinal tract, the surgical approach through a laparotomy is still considered the treatment of choice for trichobezoars [6].

The case of Rapunzel syndrome and obstruction at the ileocecal valve secondary to a second trichobezoar herein reported represents a less common condition. Clinical presentation and trichotillomania in a patient suffering from major depressive and anxiety disorders were highly suggestive of a gastrointestinal obstruction secondary to a trichobezoar. CT findings were consistent with the clinical diagnosis and prompted surgical intervention. Despite the fact that the gastric trichobezoar was associated with a chronic condition, the ileocecal valve obstruction was acute and clinically more relevant. The obstructing trichobezoar could have been a detached fragment from the gastric trichobezoar, or less probably, a second primary trichobezoar. Psychiatric management of anxiety and depression are particularly important in order to reduce the risk of recurrence of trichotillomania and trichophagy.

A case of concomitant Rapunzel syndrome and ileal trichobezoar in a patient with small-bowel obstruction was herein reported.

Statement of Ethics

The authors have no ethical conflicts to disclose.

Disclosure Statement

Bertha E. García-Ramírez (author), Carlos M. Nuño-Guzmán, Ricardo E. Zaragoza-Carrillo, Hugo Salado-Rentería, Audrey Gómez-Abarca, and Jorge L. Corona (co-authors) have no conflicts of interest, sponsorship, or funding arrangements to declare.

References

- 1 Iwamuro M, Okada H, Matsueda K, Inaba T, Kusumoto C, Imagawa A, et al. Review of the diagnosis and management of gastrointestinal bezoars. *World J Gastrointest Endosc*. 2015 Apr;7(4):336–45.
- 2 Erzurumlu K, Malazgirt Z, Bektas A, Dervisoglu A, Polat C, Senyurek G, et al. Gastrointestinal bezoars: a retrospective analysis of 34 cases. *World J Gastroenterol*. 2005 Mar;11(12):1813–7.
- 3 O'Sullivan MJ, McGreal G, Walsh JG, Redmond HP. Trichobezoar. *J R Soc Med*. 2001 Feb;94(2):68–70.
- 4 Vaughan ED Jr, Sawyers JL, Scott HW Jr. The Rapunzel syndrome. An unusual complication of intestinal bezoar. *Surgery*. 1968 Feb;63(2):339–43.
- 5 Naik S, Gupta V, Naik S, Rangole A, Chaudhary AK, Jain P, et al. Rapunzel syndrome reviewed and redefined. *Dig Surg*. 2007;24(3):157–61.
- 6 Gorter RR, Kneepkens CM, Mattens EC, Aronson DC, Heij HA. Management of trichobezoar: case report and literature review. *Pediatr Surg Int*. 2010 May;26(5):457–63.
- 7 Barzilai M, Peled N, Soudack M, Siplovich L. [Trichobezoars]. *Harefuah*. 1998 Aug;135(3-4):97–101.

- 8 Nwankwo E, Daniele E, Woller E, Fitzwater J, McGill T, Brooks SE. Trichobezoar presenting as a gastric outlet obstruction: A case report. *Int J Surg Case Rep.* 2017;34:123–5.
- 9 Couceiro A, Viveiro C, Capelão G, Nobre J, Laureano M, Gonçalves I, et al. Trichobezoar - A Rare Cause of Abdominal Mass and Gastric Outlet Obstruction. *GE Port J Gastroenterol.* 2015 Oct;23(1):50–3.
- 10 Rattan KN, Yadav V, Yadav V, Singh J. Ileal Trichobezoar Presenting as Intestinal Obstruction and Peritonitis. *APSP J Case Rep.* 2017 Mar;8(2):11.
- 11 Goyal V, Goyal PK, Gupta M. A rare case of small bowel obstruction due to primary trichobezoar. *J Clin Diagn Res.* 2014 Mar;8(3):168–9.
- 12 Wadlington WB, Rose M, Holcomb GW Jr. Complications of trichobezoars: a 30-year experience. *South Med J.* 1992 Oct;85(10):1020–2.
- 13 McCracken S, Jongeward R, Silver TM, Jafri SZ. Gastric trichobezoar: sonographic findings. *Radiology.* 1986 Oct;161(1):123–4.
- 14 Malpani A, Ramani SK, Wolverson MK. Role of sonography in trichobezoars. *J Ultrasound Med.* 1988 Dec;7(12):661–3.
- 15 Navab F, Sabol J. Images in clinical medicine. Trichobezoars. *N Engl J Med.* 1997 Jun;336(24):1721.
- 16 West WM, Duncan ND. CT appearances of the Rapunzel syndrome: an unusual form of bezoar and gastrointestinal obstruction. *Pediatr Radiol* 1998 May;28(5):315–316.
- 17 Ripollés T, García-Aguayo J, Martínez MJ, Gil P. Gastrointestinal bezoars: sonographic and CT characteristics. *AJR Am J Roentgenol.* 2001 Jul;177(1):65–9.
- 18 Altintoprak F, Degirmenci B, Dikicier E, Cakmak G, Kivilcim T, Akbulut G, et al. CT findings of patients with small bowel obstruction due to bezoar: a descriptive study. *Sci World J.* 2013 Apr;2013:298392.
- 19 Hodel J, Zins M, Desmottes L, Boulay-Coletta I, Jullès MC, Nakache JP, et al. Location of the transition zone in CT of small-bowel obstruction: added value of multiplanar reformations. *Abdom Imaging.* 2009 Jan-Feb;34(1):35–41.
- 20 Maglinte DD, Heitkamp DE, Howard TJ, Kelvin FM, Lappas JC. Current concepts in imaging of small bowel obstruction. *Radiol Clin North Am.* 2003 Mar;41(2):263–83.
- 21 Sinzig M, Umschaden HW, Haselbach H, Illing P. Gastric trichobezoar with gastric ulcer: MR findings. *Pediatr Radiol.* 1998 May;28(5):296.
- 22 Robles R, Lujan JA, Parrilla P, Torralba JA, Escamilla C. Laparoscopic surgery in the treatment of small bowel obstruction by bezoar. *Br J Surg.* 1995 Apr;82(4):520.
- 23 Nirasawa Y, Mori T, Ito Y, Tanaka H, Seki N, Atomi Y. Laparoscopic removal of a large gastric trichobezoar. *J Pediatr Surg.* 1998 Apr;33(4):663–5.
- 24 Palanivelu C, Rangarajan M, Senthilkumar R, Madankumar MV. Trichobezoars in the stomach and ileum and their laparoscopy-assisted removal: a bizarre case. *Singapore Med J.* 2007 Feb;48(2):e37–9.
- 25 Horesh N, Rosin D, Dreznik Y, Amiel I, Jacoby H, Nadler R, et al. A single tertiary center 10-year experience in the surgical management of gastrointestinal bezoars. *J Laparoendosc Adv Surg Tech A.* 2018 Aug;28(8):967–971.

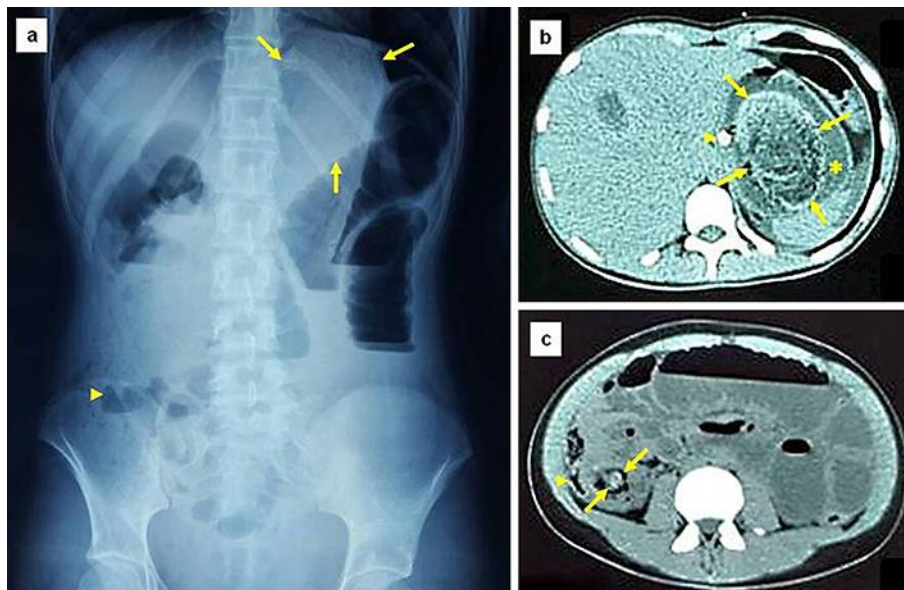


Fig. 1. **a** Plain abdominal film showing a distended and occupied stomach (arrows), dilated small bowel loops and air-fluid levels, and distension of distal ileum (arrowhead). **b** CT scan demonstrating a large ovoid heterogeneous mass within the gastric lumen (arrows), surrounded by gastric fluid (asterisk). The nasogastric tube is also shown (arrowhead). **c** CT scan also showing dilated small-bowel loops and air-fluid levels proximal to a heterogeneous intraluminal mass causing obstruction at the ileocecal valve (arrows). The cecum is shown displaced and compressed by the dilated ileum (arrowhead). Both intraluminal masses are suggestive of trichobezoars.

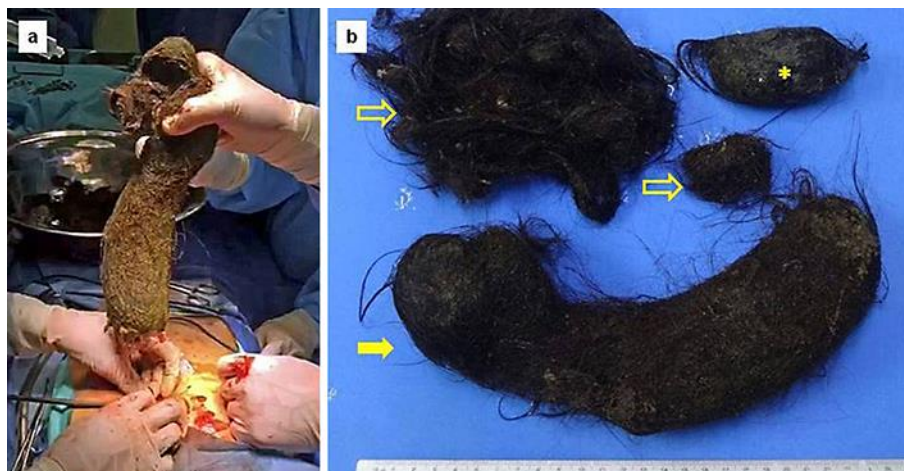

Fig. 2. **a** At gastrotomy, a 3-kg trichobezoar was removed. **b** The trichobezoar removed from the stomach (arrow) had a dense tail extending to the duodenum (hollow arrows). The trichobezoar removed from the ileocecal valve measured 7.5 × 4 cm (asterisk).