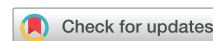

# Durable Response to Combined Dabrafenib and Trametinib in a Patient With BRAF K601E Mutation-Positive Lung Adenocarcinoma: A Case Report



Po-Lan Su, MD,<sup>a</sup> Chien-Yu Lin, MD,<sup>a</sup> Yi-Lin Chen, MS,<sup>b</sup> Wan-Li Chen, MS,<sup>b</sup> Chien-Chung Lin, MD, PhD,<sup>a,c,d</sup> Wu-Chou Su, MD<sup>c,e,f,\*</sup>

<sup>a</sup>Department of Internal Medicine, National Cheng Kung University Hospital, College of Medicine, National Cheng Kung University, Tainan, Taiwan

<sup>b</sup>Department of Pathology, National Cheng Kung University Hospital, College of Medicine, National Cheng Kung University, Tainan, Taiwan

<sup>c</sup>Institute of Clinical Medicine, National Cheng Kung University Hospital, College of Medicine, National Cheng Kung University, Tainan, Taiwan

<sup>d</sup>Department of Biochemistry and Molecular Biology, College of Medicine, National Cheng Kung University, Tainan, Taiwan

<sup>e</sup>Department of Oncology, National Cheng Kung University Hospital, College of Medicine, National Cheng Kung University, Tainan, Taiwan

<sup>f</sup>Center of Applied Nanomedicine, National Cheng Kung University, Tainan, Taiwan

Received 11 May 2021; revised 11 June 2021; accepted 23 June 2021

Available online - 3 July 2021

## ABSTRACT

Targeted therapy with combined dabrafenib and trametinib has been proven to provide clinical benefits in patients with NSCLC with a *BRAF* V600E mutation. Nevertheless, the treatment strategy for patients with NSCLC with *BRAF* non-V600E mutations remains limited. Here, we present a patient with NSCLC with a *BRAF* K601E mutation, a class II *BRAF* mutation, who had a durable response to targeted therapy with combined dabrafenib and trametinib.

© 2021 The Authors. Published by Elsevier Inc. on behalf of the International Association for the Study of Lung Cancer. This is an open access article under the CC BY-NC-ND license (<http://creativecommons.org/licenses/by-nc-nd/4.0/>).

**Keywords:** BRAF K601E mutation; Adenocarcinoma; Dabrafenib; Trametinib; Case report

## Introduction

*BRAF* mutations are rare driver oncogenes that were identified in 2% to 4% of patients with NSCLC. *BRAF* encodes a serine and threonine protein kinase that promotes cell survival and proliferation by means of the MAPK pathway. Targeted therapy with *BRAF* and MEK inhibitors, dabrafenib and trametinib, has been proven to be clinically effective for patients with a *BRAF* V600 mutation (class I *BRAF* mutation), which represents approximately half of *BRAF* mutations.<sup>1</sup> Nevertheless,

the treatment strategy for patients with *BRAF* non-V600 mutation remains limited.

The *BRAF* K601E mutation is a class II *BRAF* mutation that occurs in approximately 0.2% of patients with lung adenocarcinoma. It induces high intrinsic kinase activity by impairing its interaction with the phosphate-binding loop.<sup>2</sup> In vitro study has also revealed that class II *BRAF* mutations could also increase the activity of downstream MAPK pathway, including the activation of MEK and ERK.<sup>2</sup> Although trametinib provides clinical benefit in patients with *BRAF* K601E-mutant melanoma, the duration of response in a case report with *BRAF* K601E-mutant lung adenocarcinoma was only 4 months.<sup>3</sup>

\*Corresponding author.

Drs. PL Su and CY Lin contributed equally to this work.

**Disclosure:** The authors declare no conflict of interest.

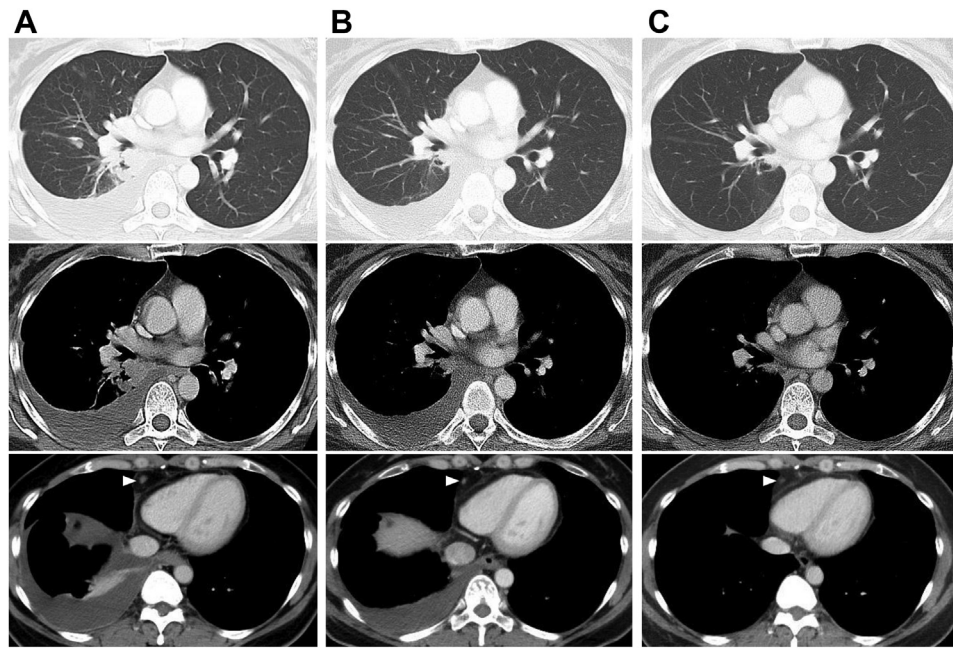
Address for correspondence: Wu-Chou Su, MD, Department of Oncology, National Cheng Kung University Hospital, College of Medicine, National Cheng Kung University, Number 138, Shengli Road, North District, Tainan City 704, Taiwan. E-mail: [sunnysu@mail.ncku.edu.tw](mailto:sunnysu@mail.ncku.edu.tw)

Cite this article as: Su PL, Lin CY, Chen YL, et al. Durable response to combined dabrafenib and trametinib in a patient with BRAF K601E mutation-positive lung adenocarcinoma: a case report. *JTO Clin Res Rep.* 2021;2:100202.

© 2021 The Authors. Published by Elsevier Inc. on behalf of the International Association for the Study of Lung Cancer. This is an open access article under the CC BY-NC-ND license (<http://creativecommons.org/licenses/by-nc-nd/4.0/>).

ISSN: 2666-3643

<https://doi.org/10.1016/j.jtocrr.2021.100202>



**Figure 1.** Chest CT scan results of the patient before and after targeted therapy with combined dabrafenib and trametinib. (A) Before treatment. (B) After 3 months of targeted therapy. (C) After 6 months of targeted therapy. The white arrowhead indicates the mediastinal lymph node (cardiophrenic lymph node). CT, computed tomography.

Here, we present the case of a patient with NSCLC with a *BRAF* K601E mutation who exhibited a durable response to targeted therapy with combined dabrafenib and trametinib.

## Case Presentation

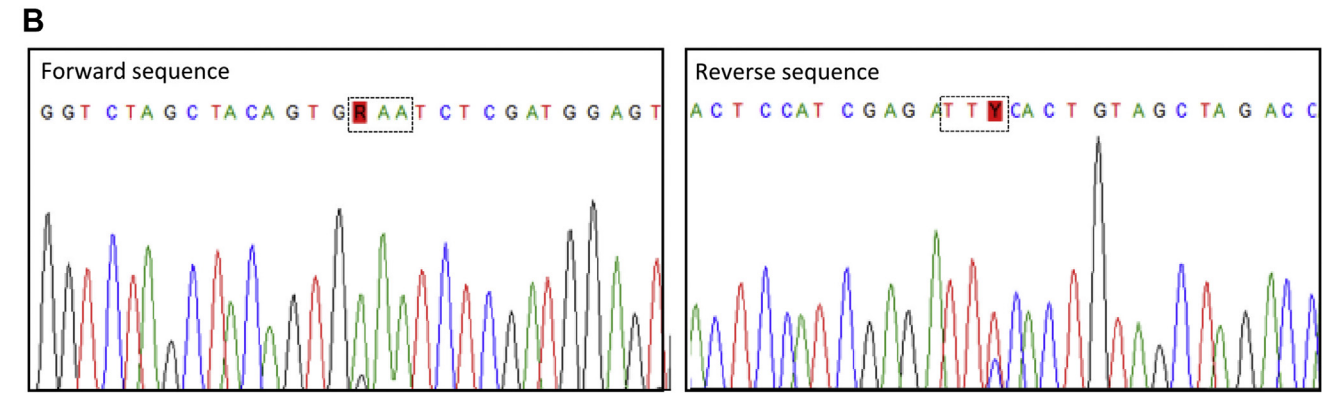
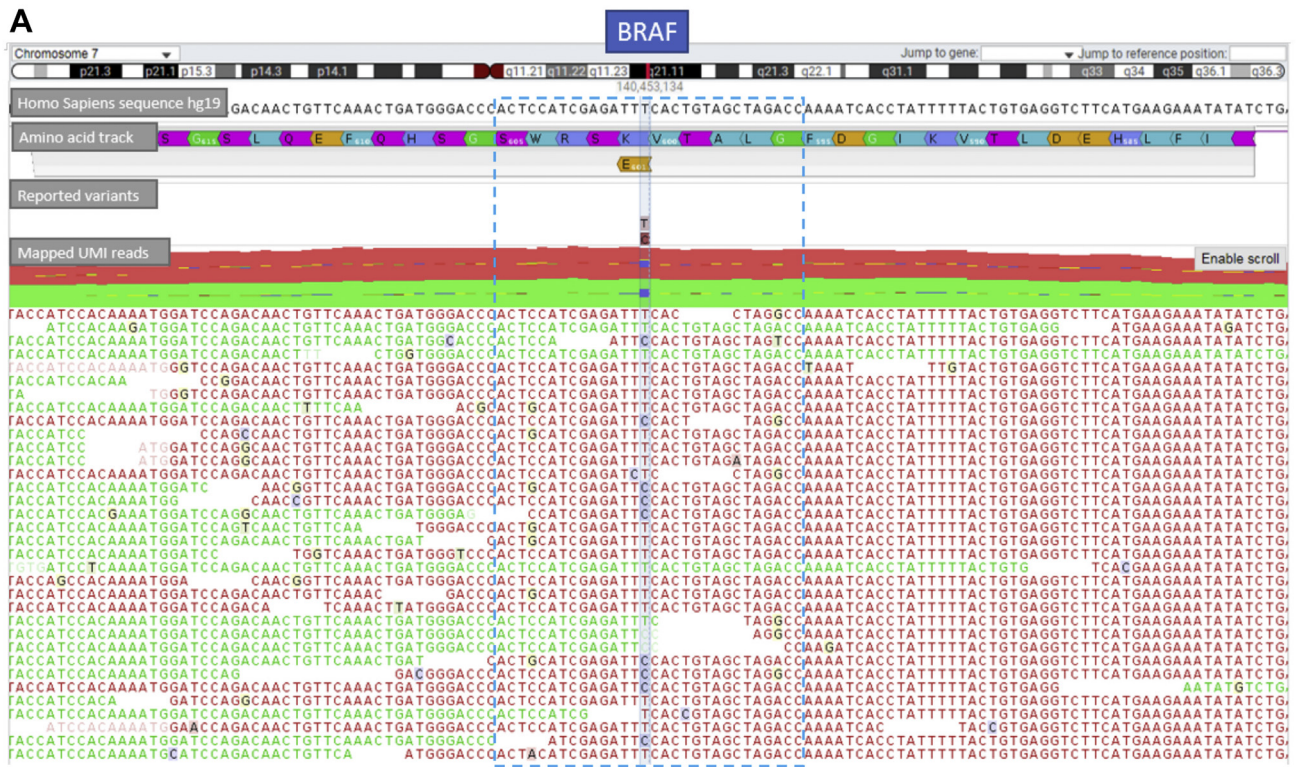
A previously healthy 43-year-old woman without a history of cigarette smoking presented with chronic nonproductive cough for half a year. Computed tomography (CT) scan of the chest revealed a right lower lung mass with right pleural dissemination and mediastinal lymph node enlargement (Fig. 1A). After biopsy by means of pleuroscopic examination, the pathologic workup result revealed adenocarcinoma, which expressed thyroid transcription factor-1 but not p40. On the basis of the clinical data, the patient was diagnosed with having stage IV lung adenocarcinoma.

We use the QIAGEN GeneReader next-generation sequencing system and QIAact Lung All-in-One assay, and we detected *BRAF* mutation (K601E) (Fig. 2A), *EGFR* amplification (copy number: 2.36), and *RICTOR* amplification (copy number: 2.74) (Table 1). The point mutation in the *BRAF* gene was further validated by forward and reverse sequencing using Sanger sequencing (Fig. 2B). No other genomic alterations were detected, including *EGFR*, *ALK* (immunohistochemistry), and *ROS1* (immunohistochemistry). Less than 1% of all tumor cells expressed programmed death-ligand 1. After three months of targeted therapy with combined dabrafenib

and trametinib, chest CT result revealed partial regression of the right lower lung tumor, in combination with regression of mediastinal lymphadenopathy and pleural effusion (without thoracentesis) (Fig. 1B). Her cough also resolved gradually. After 6 months, her chest CT scan result revealed near-total regression of the right lower lung tumor (Fig. 1C). The patient had received dabrafenib and trametinib for 9 months with a durable response. Only grade 1 skin rashes and grade 1 pyrexia developed, which were controlled using antihistamines and antipyretics. No newly onset cutaneous malignancies developed.

## Discussion

To the best of our knowledge, this is the first case demonstrating a near-complete and durable response to targeted therapy with combined dabrafenib and trametinib in a patient with *BRAF* K601E mutation. The K601E-mutated *BRAF* was activated as a dimer, which has been discovered to interfere with the binding ability of *BRAF* inhibitors, including dabrafenib and vemurafenib.<sup>4</sup> Given the activation of downstream signaling of the MAPK pathway in melanoma, several case reports on melanoma have a clinical response to the MEK inhibitor trametinib.<sup>4</sup> Nevertheless, in a case report of a patient with *BRAF* K601E mutation, the duration of response was only four months. Moreover, considerable trametinib-related adverse events led to dose reduction and interruption.<sup>3</sup>



**Figure 2.** Genomic sequencing data. (A) Next-generation sequencing of tissue from the pleural metastasis revealed a c.1801A>G (p.K601E) mutation (26.44%) in *BRAF* gene. (B) Sanger sequence confirmed a c.1801A>G (p.K601E) mutation in *BRAF* gene with forward and reverse sequencing.

In a patient-derived murine xenograft model of *BRAF* K601E-mutant melanoma, the targeted therapy with combined dabrafenib and trametinib provided higher tumor volume reduction and longer duration of response compared with trametinib monotherapy.<sup>5</sup> In addition,

the patient from whom the model was derived had a partial response after the targeted therapy with combined dabrafenib and trametinib.<sup>5</sup> In general, the use of trametinib and dabrafenib is not recommended in non-V600E because there are patients with NSCLC with

**Table 1. Results From NGS Panel Testing**

| Gene   | cDNA          | Amino Acid | Allele Frequency, % | Verdict    |
|--------|---------------|------------|---------------------|------------|
| BRAF   | c.1801A>G     | p.K601E    | 24.66               | Pathogenic |
| EGFR   | Amplification | —          | —                   | Pathogenic |
| RICTOR | Amplification | —          | —                   | Pathogenic |

Note: NGS DNA panel testing revealed wild-type sequences in hotspots of the following genes: *ALK*, *AKT1*, *DDR2*, *EGFR*, *ERBB2*, *ESR1*, *FGFR1*, *KRAS*, *KIT*, *MAP2K1*, *MET*, *NRAS*, *NTRK1*, *PDGFRA*, *PIK3CA*, *PTEN*, and *ROS1*.  
cDNA, complementary DNA; NGS, next-generation sequencing.

*BRAF* K601E mutation who did not respond to this combination.<sup>6,7</sup> Future clinical trials studying targeted therapy with combined dabrafenib and trametinib in patients with *BRAF* K601E mutation are warranted. There are ongoing clinical trials with the targeted therapy of combined *BRAF* inhibitors and MEK inhibitors in patients with *BRAF* V600E and non-V600E mutation-positive NSCLC and melanoma (ERCRAF study) ([ClinicalTrials.gov](https://clinicaltrials.gov/ct2/show/study/NCT02974725) identifier: NCT02974725) and in patients with advanced solid tumors with non-V600E *BRAF* mutations (BEAVER study) ([ClinicalTrials.gov](https://clinicaltrials.gov/ct2/show/study/NCT03839342) identifier: NCT03839342).

## Conclusion

We report a case of lung adenocarcinoma with a *BRAF* K601E mutation that responded to targeted therapy with combined dabrafenib and trametinib. This case reveals the potential clinical benefit of combined dabrafenib and trametinib in patients harboring the *BRAF* non-V600E mutation.

## CRedit Authorship Contribution Statement

**Po-Lan Su:** Conceptualization, Data curation, Formal analysis, Writing—original draft.

**Chien-Yu Lin:** Conceptualization, Writing—original draft.

**Yi-Lin Chen, Wan-Li Chen:** Conceptualization, Data curation, Methodology, Software.

**Chien-Chung Lin, Wu-Chou Su:** Conceptualization, Data curation, Formal analysis, Writing—review and editing.

## Acknowledgments

This research did not receive any specific grant from funding agencies in the public, commercial, or not-for-profit sectors. The patient involved in this case report gave her informed consent authorizing use and disclosure of her health information.

## References

1. Planchard D, Smit EF, Groen HJM, et al. Dabrafenib plus trametinib in patients with previously untreated BRAFV600E-mutant metastatic non-small-cell lung cancer: an open-label, phase 2 trial. *Lancet Oncol.* 2017;18:1307-1316.
2. Dankner M, Rose AAN, Rajkumar S, Siegel PM, Watson IR. Classifying BRAF alterations in cancer: new rational therapeutic strategies for actionable mutations. *Oncogene.* 2018;37:3183-3199.
3. Saalfeld FC, Wenzel C, Aust DE, Wermke M. Targeted therapy in BRAF p.K601E-driven NSCLC: case report and literature review. *JCO Precis Oncol.* 2020;4:1163-1166.
4. Menzer C, Menzies AM, Carlino MS, et al. Targeted therapy in advanced melanoma with rare BRAF mutations. *J Clin Oncol.* 2019;37:3142-3151.
5. Rogiers A, Thomas D, Vander Borght S, et al. Dabrafenib plus trametinib in BRAF K601E-mutant melanoma. *Br J Dermatol.* 2019;180:421-422.
6. Gaultschi O, Milia J, Cabarrou B, et al. Targeted therapy for patients with BRAF-mutant lung cancer: results from the European EURAF cohort. *J Thorac Oncol.* 2015;10:1451-1457.
7. Mazieres J, Cropet C, Montané L, et al. Vemurafenib in non-small-cell lung cancer patients with BRAF V600 and BRAF nonV600 mutations. *Ann Oncol.* 2020;31:289-294.